

# World Journal of *Clinical Cases*

*World J Clin Cases* 2021 July 26; 9(21): 5754-6177



## Contents

Thrice Monthly Volume 9 Number 21 July 26, 2021

## REVIEW

- 5754 Treatment strategies for hepatocellular carcinoma with extrahepatic metastasis  
*Long HY, Huang TY, Xie XY, Long JT, Liu BX*

## MINIREVIEWS

- 5769 Prevention of hepatitis B reactivation in patients requiring chemotherapy and immunosuppressive therapy  
*Shih CA, Chen WC*
- 5782 Research status on immunotherapy trials of gastric cancer  
*Liang C, Wu HM, Yu WM, Chen W*
- 5794 Therapeutic plasma exchange for hyperlipidemic pancreatitis: Current evidence and unmet needs  
*Zheng CB, Zheng ZH, Zheng YP*
- 5804 Essentials of thoracic outlet syndrome: A narrative review  
*Chang MC, Kim DH*

## ORIGINAL ARTICLE

## Case Control Study

- 5812 Soluble programmed death-1 is predictive of hepatitis B surface antigen loss in chronic hepatitis B patients after antiviral treatment  
*Tan N, Luo H, Kang Q, Pan JL, Cheng R, Xi HL, Chen HY, Han YF, Yang YP, Xu XY*

## Retrospective Cohort Study

- 5822 Tunneled biopsy is an underutilised, simple, safe and efficient method for tissue acquisition from subepithelial tumours  
*Koutsoumpas A, Perera R, Melton A, Kuker J, Ghosh T, Braden B*

## Retrospective Study

- 5830 Macular ganglion cell complex injury in different stages of anterior ischemic optic neuropathy  
*Zhang W, Sun XQ, Peng XY*
- 5840 Value of refined care in patients with acute exacerbation of chronic obstructive pulmonary disease  
*Na N, Guo SL, Zhang YY, Ye M, Zhang N, Wu GX, Ma LW*
- 5850 Facilitators and barriers to colorectal cancer screening in an outpatient setting  
*Samuel G, Kratzer M, Asagbra O, Kinderwater J, Poola S, Udom J, Lambert K, Mian M, Ali E*
- 5860 Development and validation of a prognostic nomogram for colorectal cancer after surgery  
*Li BW, Ma XY, Lai S, Sun X, Sun MJ, Chang B*

**Observational Study**

- 5873** Potential protein-phenotype correlation in three lipopolysaccharide-responsive beige-like anchor protein-deficient patients

*Tang WJ, Hu WH, Huang Y, Wu BB, Peng XM, Zhai XW, Qian XW, Ye ZQ, Xia HJ, Wu J, Shi JR*

- 5889** Quantification analysis of pleural line movement for the diagnosis of pneumothorax

*Xiao R, Shao Q, Zhao N, Liu F, Qian KJ*

**Prospective Study**

- 5900** Preprocedure ultrasound imaging combined with palpation technique in epidural labor analgesia

*Wu JP, Tang YZ, He LL, Zhao WX, An JX, Ni JX*

**Randomized Controlled Trial**

- 5909** Effects of perioperative rosuvastatin on postoperative delirium in elderly patients: A randomized, double-blind, and placebo-controlled trial

*Xu XQ, Luo JZ, Li XY, Tang HQ, Lu WH*

**SYSTEMATIC REVIEWS**

- 5921** Pain assessment and management in the newborn: A systematized review

*Garcia-Rodriguez MT, Bujan-Bravo S, Seijo-Bestilleiro R, Gonzalez-Martin C*

**META-ANALYSIS**

- 5932** Fatigue prevalence in men treated for prostate cancer: A systematic review and meta-analysis

*Luo YH, Yang YW, Wu CF, Wang C, Li WJ, Zhang HC*

**CASE REPORT**

- 5943** Diagnostic discrepancy between colposcopy and vaginoscopy: A case report

*Li Q, Zhang HW, Sui L, Hua KQ*

- 5948** Contrast enhanced ultrasound in diagnosing liver lesion that spontaneously disappeared: A case report

*Wang ZD, Haitham S, Gong JP, Pen ZL*

- 5955** COVID-19 patient with an incubation period of 27 d: A case report

*Du X, Gao Y, Kang K, Chong Y, Zhang ML, Yang W, Wang CS, Meng XL, Fei DS, Dai QQ, Zhao MY*

- 5963** Awake extracorporeal membrane oxygenation support for a critically ill COVID-19 patient: A case report

*Zhang JC, Li T*

- 5972** Meigs syndrome with pleural effusion as initial manifestation: A case report

*Hou YY, Peng L, Zhou M*

- 5980** Giant hemangioma of the caudate lobe of the liver with surgical treatment: A case report

*Wang XX, Dong BL, Wu B, Chen SY, He Y, Yang XJ*

- 5988** Anti-programmed cell death ligand 1-based immunotherapy in recurrent hepatocellular carcinoma with inferior vena cava tumor thrombus and metastasis: Three case reports  
*Liu SR, Yan Q, Lin HM, Shi GZ, Cao Y, Zeng H, Liu C, Zhang R*
- 5999** Minimal deviation adenocarcinoma with elevated CA19-9: A case report  
*Dong Y, Lv Y, Guo J, Sun L*
- 6005** Isolated fungus ball in a single cell of the left ethmoid roof: A case report  
*Zhou LQ, Li M, Li YQ, Wang YJ*
- 6009** Rare case of brucellosis misdiagnosed as prostate carcinoma with lumbar vertebra metastasis: A case report  
*Yan JF, Zhou HY, Luo SF, Wang X, Yu JD*
- 6017** Myeloid sarcoma of the colon as initial presentation in acute promyelocytic leukemia: A case report and review of the literature  
*Wang L, Cai DL, Lin N*
- 6026** Primary follicular lymphoma in the renal pelvis: A rare case report  
*Shen XZ, Lin C, Liu F*
- 6032** Rosai-Dorfman disease in the spleen of a pediatric patient: A case report  
*Ryu H, Hwang JY, Kim YW, Kim TU, Jang JY, Park SE, Yang EJ, Shin DH*
- 6041** Relapsed/refractory classical Hodgkin lymphoma effectively treated with low-dose decitabine plus tislelizumab: A case report  
*Ding XS, Mi L, Song YQ, Liu WP, Yu H, Lin NJ, Zhu J*
- 6049** Disseminated *Fusarium* bloodstream infection in a child with acute myeloid leukemia: A case report  
*Ning JJ, Li XM, Li SQ*
- 6056** Familial hemophagocytic lymphohistiocytosis type 2 in a female Chinese neonate: A case report and review of the literature  
*Bi SH, Jiang LL, Dai LY, Wang LL, Liu GH, Teng RJ*
- 6067** Usefulness of metagenomic next-generation sequencing in adenovirus 7-induced acute respiratory distress syndrome: A case report  
*Zhang XJ, Zheng JY, Li X, Liang YJ, Zhang ZD*
- 6073** Neurogenic orthostatic hypotension with Parkinson's disease as a cause of syncope: A case report  
*Li Y, Wang M, Liu XL, Ren YF, Zhang WB*
- 6081** SATB2-associated syndrome caused by a novel SATB2 mutation in a Chinese boy: A case report and literature review  
*Zhu YY, Sun GL, Yang ZL*
- 6091** Diagnosis and treatment discussion of congenital factor VII deficiency in pregnancy: A case report  
*Yang Y, Zeng YC, Rumende P, Wang CG, Chen Y*

- 6102** Unusual immunohistochemical “null” pattern of four mismatch repair proteins in gastric cancer: A case report  
*Yue M, Liu JY, Liu YP*
- 6110** Generalized periodontitis treated with periodontal, orthodontic, and prosthodontic therapy: A case report  
*Kaku M, Matsuda S, Kubo T, Shimoe S, Tsuga K, Kurihara H, Tanimoto K*
- 6125** Ligamentum flavum hematoma following a traffic accident: A case report  
*Yu D, Lee W, Chang MC*
- 6130** Oral cyclophosphamide-induced posterior reversible encephalopathy syndrome in a patient with ANCA-associated vasculitis: A case report  
*Kim Y, Kwak J, Jung S, Lee S, Jang HN, Cho HS, Chang SH, Kim HJ*
- 6138** Encapsulating peritoneal sclerosis in an AMA-M2 positive patient: A case report  
*Yin MY, Qian LJ, Xi LT, Yu YX, Shi YQ, Liu L, Xu CF*
- 6145** Multidisciplinary diagnostic dilemma in differentiating Madelung’s disease – the value of superb microvascular imaging technique: A case report  
*Seskute G, Dapkute A, Kausaite D, Strainiene S, Talijunas A, Butrimiene I*
- 6155** Complicated course of biliary inflammatory myofibroblastic tumor mimicking hilar cholangiocarcinoma: A case report and literature review  
*Strainiene S, Sedleckaite K, Jarasunas J, Savlan I, Stanaitis J, Stundiene I, Strainys T, Liakina V, Valantinas J*
- 6170** Fruquintinib beneficial in elderly patient with neoplastic pericardial effusion from rectal cancer: A case report  
*Zhang Y, Zou JY, Xu YY, He JN*

**ABOUT COVER**

Editorial Board Member of *World Journal of Clinical Cases*, Jae Gil Lee, MD, PhD, Professor, Surgeon, Department of Surgery, Yonsei University College of Medicine, Seoul 03722, South Korea. jakii@yuhs.ac

**AIMS AND SCOPE**

The primary aim of *World Journal of Clinical Cases* (WJCC, *World J Clin Cases*) is to provide scholars and readers from various fields of clinical medicine with a platform to publish high-quality clinical research articles and communicate their research findings online.

WJCC mainly publishes articles reporting research results and findings obtained in the field of clinical medicine and covering a wide range of topics, including case control studies, retrospective cohort studies, retrospective studies, clinical trials studies, observational studies, prospective studies, randomized controlled trials, randomized clinical trials, systematic reviews, meta-analysis, and case reports.

**INDEXING/ABSTRACTING**

The WJCC is now indexed in Science Citation Index Expanded (also known as SciSearch®), Journal Citation Reports/Science Edition, Scopus, PubMed, and PubMed Central. The 2021 Edition of Journal Citation Reports® cites the 2020 impact factor (IF) for WJCC as 1.337; IF without journal self cites: 1.301; 5-year IF: 1.742; Journal Citation Indicator: 0.33; Ranking: 119 among 169 journals in medicine, general and internal; and Quartile category: Q3. The WJCC's CiteScore for 2020 is 0.8 and Scopus CiteScore rank 2020: General Medicine is 493/793.

**RESPONSIBLE EDITORS FOR THIS ISSUE**

Production Editor: Ji-Hong Lin; Production Department Director: Xiang Li; Editorial Office Director: Jin-Li Wang.

**NAME OF JOURNAL**

*World Journal of Clinical Cases*

**ISSN**

ISSN 2307-8960 (online)

**LAUNCH DATE**

April 16, 2013

**FREQUENCY**

Thrice Monthly

**EDITORS-IN-CHIEF**

Dennis A Bloomfield, Sandro Vento, Bao-Gan Peng

**EDITORIAL BOARD MEMBERS**

<https://www.wjgnet.com/2307-8960/editorialboard.htm>

**PUBLICATION DATE**

July 26, 2021

**COPYRIGHT**

© 2021 Baishideng Publishing Group Inc

**INSTRUCTIONS TO AUTHORS**

<https://www.wjgnet.com/bpg/gerinfo/204>

**GUIDELINES FOR ETHICS DOCUMENTS**

<https://www.wjgnet.com/bpg/GerInfo/287>

**GUIDELINES FOR NON-NATIVE SPEAKERS OF ENGLISH**

<https://www.wjgnet.com/bpg/gerinfo/240>

**PUBLICATION ETHICS**

<https://www.wjgnet.com/bpg/GerInfo/288>

**PUBLICATION MISCONDUCT**

<https://www.wjgnet.com/bpg/gerinfo/208>

**ARTICLE PROCESSING CHARGE**

<https://www.wjgnet.com/bpg/gerinfo/242>

**STEPS FOR SUBMITTING MANUSCRIPTS**

<https://www.wjgnet.com/bpg/GerInfo/239>

**ONLINE SUBMISSION**

<https://www.f6publishing.com>



Prospective Study

# Preprocedure ultrasound imaging combined with palpation technique in epidural labor analgesia

Jian-Ping Wu, Yuan-Zhang Tang, Liang-Liang He, Wen-Xing Zhao, Jian-Xiong An, Jia-Xiang Ni

**ORCID number:** Jian-Ping Wu 0000-0002-8949-7417; Yuan-Zhang Tang 0000-0001-7714-6401; Liang-Liang He 0000-0002-1174-6938; Wen-Xing Zhao 0000-0001-8881-2588; Jian-Xiong An 0000-0002-1349-5511; Jia-Xiang Ni 0000-0003-4408-275X.

**Author contributions:** Wu JP conceived this study, collected the data, analyzed the formal, and drafted the manuscript; Tang YZ, He LL, and Zhao WX contributed to the investigation, methodology and writing, reviewing, and editing of the manuscript; An JX contributed to the project administration and writing, reviewing, and editing of the manuscript; Ni JX supervised the study and contributed to the project administration, resources, software and writing, reviewing, and editing of the manuscript; All authors proofread and approved the revised manuscript.

**Institutional review board**

**statement:** This study was reviewed and approved by the Aviation General Hospital of China Medical University Institutional Review Board.

**Clinical trial registration statement:**

The study is registered at Chinese Clinical Trial Registry, using identifier ChiCTR1800014782.

**Jian-Ping Wu, Yuan-Zhang Tang, Liang-Liang He, Jia-Xiang Ni,** Department of Pain Management, Xuanwu Hospital of Capital Medical University, Beijing 100053, China

**Jian-Ping Wu, Wen-Xing Zhao, Jian-Xiong An,** Department of Anesthesiology and Pain Medicine, Aviation General Hospital of China Medical University, Beijing Institute of Translational Medicine, Chinese Academy of Sciences, Beijing 100012, China

**Corresponding author:** Jia-Xiang Ni, MD, Chief Doctor, Director, Professor, Department of Pain Management, Xuanwu Hospital of Capital Medical University, No. 45 Changchun Street, Xicheng District, Beijing 100053, China. [nijiaxiang@263.net](mailto:nijiaxiang@263.net)

## Abstract

### BACKGROUND

For parturients with paroxysmal uterine contraction pain, rapid analgesia is needed. We used preprocedure ultrasound imaging combined with the palpation technique in epidural analgesia for labor, and evaluated the usefulness of this technique in epidural labor analgesia.

### AIM

To evaluate the usefulness of preprocedure ultrasound imaging in epidural analgesia for labor.

### METHODS

In this prospective randomized observational study, 72 parturients were assigned to two groups (combined or palpation group). The target interspace of all parturients was first identified by the palpation technique. Then in the combined group, preprocedure ultrasound imaging was used before epidural puncture. In the palpation group, only the traditional anatomical landmarks technique (palpation technique) was performed. The primary outcome was total duration of the epidural procedure (for the ultrasound group, the duration of the preprocedure ultrasound imaging was included). The secondary outcomes were the number of skin punctures, the success rate at first needle pass, the number of needle passes, the depth from the skin to epidural space, and the complications of the procedure.

### RESULTS

Total duration of the epidural procedure was similar between the two groups ( $406.5 \pm 92.15$  s in the combined group and  $380.03 \pm 128.2$  s in the palpation group;



**Informed consent statement:**

Informed written consent was obtained from every parturient.

**Conflict-of-interest statement:** No conflict-of-interest.

**Data sharing statement:** No additional data are available.

**CONSORT 2010 statement:** The authors have read the CONSORT 2010 statement, and the manuscript was prepared and revised according to the CONSORT 2010 statement.

**Open-Access:** This article is an open-access article that was selected by an in-house editor and fully peer-reviewed by external reviewers. It is distributed in accordance with the Creative Commons Attribution NonCommercial (CC BY-NC 4.0) license, which permits others to distribute, remix, adapt, build upon this work non-commercially, and license their derivative works on different terms, provided the original work is properly cited and the use is non-commercial. See: <http://creativecommons.org/licenses/by-nc/4.0/>

**Manuscript source:** Unsolicited manuscript

**Specialty type:** Anesthesiology

**Country/Territory of origin:** China

**Peer-review report's scientific quality classification**

Grade A (Excellent): 0  
Grade B (Very good): B  
Grade C (Good): 0  
Grade D (Fair): 0  
Grade E (Poor): 0

**Received:** February 25, 2021

**Peer-review started:** February 25, 2021

**First decision:** April 14, 2021

**Revised:** April 19, 2021

**Accepted:** April 26, 2021

**Article in press:** April 26, 2021

**Published online:** July 26, 2021

**P-Reviewer:** Mosquera-Klinger G

**S-Editor:** Wang JL

**L-Editor:** Filipodia

$P = 0.318$ ). A significant improvement was demonstrated for epidural puncture and catheterization in the combined group. The number of needle passes was 1.14 in the combined group and 1.72 in the palpation group ( $P = 0.001$ ). The number of skin puncture sites was 1.20 in the combined group and 1.25 in the palpation group ( $P = 0.398$ ). The success rate at first needle pass was 88.89% in the combined group and 66.67% in the palpation group ( $P = 0.045$ ).

**CONCLUSION**

This study demonstrated that the total duration of epidural procedures with preprocedure ultrasound imaging combined with the palpation technique was not longer than the traditional anatomical landmarks technique, which were performed by six experienced anesthesiologists in parturients with normal weights undergoing labor analgesia.

**Key Words:** Preprocedure ultrasound imaging; Epidural puncture; Epidural catheterization; Palpation technique; Labor analgesia

©The Author(s) 2021. Published by Baishideng Publishing Group Inc. All rights reserved.

**Core Tip:** This is the first study of preprocedure ultrasound imaging combined with the palpation technique in epidural labor analgesia. This combined technique increases the first-pass success rate of epidural catheterization but does not increase the total procedural time in labor analgesia.

**Citation:** Wu JP, Tang YZ, He LL, Zhao WX, An JX, Ni JX. Preprocedure ultrasound imaging combined with palpation technique in epidural labor analgesia. *World J Clin Cases* 2021; 9(21): 5900-5908

**URL:** <https://www.wjgnet.com/2307-8960/full/v9/i21/5900.htm>

**DOI:** <https://dx.doi.org/10.12998/wjcc.v9.i21.5900>

**INTRODUCTION**

Epidural analgesia can provide effective pain control in obstetrics[1], but the obesity and edema of parturients can increase challenges in performing the epidural puncture. For parturients with paroxysmal uterine contraction pain who opt to have labor pain relief, rapid analgesia is needed. Therefore, a rapid and effective epidural puncture is particularly important for parturients requiring labor analgesia.

Preprocedure ultrasound imaging can improve the safety and efficacy of epidural puncture especially in difficult cases[2-9], but it requires time and ultrasound imaging of the spine is more complex than imaging of other parts of the body; thus, clinical ultrasound measurement for labor analgesia is not frequently practiced[2].

In previous studies, preprocedure ultrasound imaging needs several steps. First, the paramedian sagittal oblique view was obtained to identify the sacrum, the five lumbar intervertebral spaces, and the target interspace[10,11]. Second, the transverse interlaminar view of the target interspace was obtained, the depth of the epidural space was measured, and the needle insertion point was marked[9,10]. This preprocedure ultrasound imaging needs some time. In our combined technique, first, the target interspace was obtained by landmark palpation. Second, the transverse interlaminar view of the target interspace was obtained, the depth of the epidural space was measured, and needle insertion point was marked. This technique needs less procedure time.

This study was conducted to compare the total duration of the epidural procedure (including the duration of preprocedure ultrasound imaging in the combined group), and the safety of the epidural procedure between the combined and palpation groups. We determined whether the combined technique increased the total duration of the epidural procedure and improved the success rate of epidural analgesia.



P-Editor: Wang LYT



## MATERIALS AND METHODS

This study was a prospective randomized controlled study. After obtaining approval from the institutional ethical committee, this study was conducted with healthy parturients admitted to the Department of Obstetrics and Gynecology. The study was conducted between January and May 2018 and reviewed and approved by the local university's institutional review board (IRB). All data collection and data management were conducted according to the IRB-approved protocol (ChiCTR1800014782). Informed written consent was obtained from every parturient.

### Parturients

The inclusion criteria were as follows: healthy pregnancy and singleton birth, age  $\geq 18$  and  $\leq 40$  years, American Society of Anesthesiologists physical status II or above, active labor (regular contractions and cervical dilation  $\geq 2$  cm), no history of caesarean for dystocia, absence of contraindications to epidural blockade, absence of previous analgesia with opioids, absence of cephalopelvic disproportion, and absence of psychopathological disorders and substance abuse.

The exclusion criteria were as follows: body mass index  $\geq 35$  kg/m<sup>2</sup>; patient refusal; pregnancy-induced hypertension; systemic hypertension; diabetes mellitus; heart disease; previous lower segment caesarean section; or any contraindication to neuraxial anesthesia such as coagulopathy, increased intracranial pressure, uncorrected hypovolemia, local skin infection, marked spinal deformity, or previous spinal surgery. Written informed consent was obtained from the parturient at the preanesthetic interview for delivery. Seventy-two parturients were randomly assigned to two groups (combined or palpation group) using a computer-generated table of random numbers. All epidurals were performed by six anesthesiologists (each anesthesiologist with approximately 300-500 obstetric palpation epidurals anesthesia and 50-100 obstetric ultrasound-assisted epidurals anesthesia). The primary and secondary outcome data were recorded by other investigators (nurses who assisted the anesthesiologist with preprocedural ultrasound imaging and epidural procedures).

### Preprocedure ultrasound imaging

Standard monitors were applied, and the parturient was placed in the left lateral position throughout the procedure. In two groups, the anatomical landmarks were the intercrystal (Tuffier) line, which was assumed to cross the L3-L4 interspace or L4 spinous process. The target interspace was the L3-L4 interspace. In the ultrasound group, preprocedure ultrasound imaging was used before epidural puncture. In the palpation group, the traditional palpation technique was performed.

In the combined group, a 2-5 MHz curved array probe was used for all cases using a three-step approach[12,13] (GE Healthcare, Chalfont St. Giles, United Kingdom). (1) The target interspace of the parturient was identified by the palpation technique. (2) The transverse interlaminar view of the target interspace and the best sonographic image was observed. The depth of the epidural space was measured (distance from the skin surface to the ventral aspect of the ligamentum flavum-dura mater complex). (3) The horizontal and vertical lines were marked at the midpoints of the probe's short and long sides, respectively[14], and the needle insertion point was marked at the intersection point of the two lines.

### Epidural puncture and catheterization

With proper aseptic and antiseptic precautions, the puncture site was infiltrated with lidocaine with an 18-gauge Tuohy needle (Perifix®; Braun, Melsungen, Germany) using the loss of resistance technique to air, and then a multi-hole epidural catheter was inserted at the L3-4 intervertebral space. In the combined group, the loss-of-resistance test was started when the travel distance of the epidural needle was 0.5 cm less than the pre-estimated depth.

The catheter was placed in the epidural space 3-4 cm in the cephalic direction. Then 3 mL of 1.5% lidocaine was administered to exclude intravenous or subarachnoid catheter placement. Next, a dose of 12 mL ropivacaine at a concentration of 0.094% was administered without opioids. Instructions for use of the patient-controlled epidural analgesia (PCEA) pump (Rehn Medtech Ltd., Jiangsu, China) were provided to the parturient after the epidural catheter was inserted. The instructions included specific directions to each woman to press the button whenever she began to feel discomfort, and to wait a few minutes in order to feel its analgesic effect. The setting of the PCEA was: bolus 6 mL, lockout 12 min, no background infusion[15]. Self-delivered boluses were infused at a standard delivery rate of 60 mL  $\times$  h<sup>-1</sup> (one bolus

per 6 min).

### Outcome measurements

In both groups, we measured the total time for the epidural procedures. For the combined group, this included the time for the ultrasound measurements, the epidural puncture and catheterization. For the palpation group, this only included the epidural puncture and catheterization procedures. Warm-up time of the ultrasonography was not evaluated[16]. The duration of procedures was recorded by other investigators (nurses who assisted the anesthesiologist).

We counted the success rate at the first needle pass, the number of needles passes, and the skin puncture sites. A needle pass meant advancement of the needle, and retracement of the puncture needle was counted as one needle pass. If the epidural space could not be punctured in the first puncture site, a neighboring vertebral interspace was selected. A successful puncture at the first needle pass means “direct access” after skin puncture[9].

The complications of the procedure such as unintentional dural and vascular punctures, nerve irritation, backache during the procedure, unilateral or patchy block and failed block were observed by the primary investigators (the anesthesiologist).

### Statistical analyses

The results are presented as the mean  $\pm$  SD and percentages. The  $\chi^2$  test was used to compare the categorical/dichotomous variables between the groups. A *t*-test was used to compare the means of the variables between the groups.  $P < 0.05$  was considered statistically significant. All analyses were carried out using SPSS 19.0 version (Statistical Package for the Social Sciences, Chicago, IL, United States).

## RESULTS

Seventy-six patients were assessed for eligibility. Three did not meet the inclusion criteria and one declined to participate. Data from 72 patients (36 in each group) were analyzed (Figure 1). The baseline characteristics of the patients were similar between two groups (Table 1).

The mean total duration of the epidural procedures was  $406.5 \pm 92.15$  s in the combined group and  $380.03 \pm 128.2$  s in the palpation group ( $P = 0.318$ ). The mean time for preprocedural ultrasound imaging in the combined group was  $85.83 \pm 3.92$  s (Table 2).

The number of needle passes was 1.14 in the combined group and 1.72 in the palpation group ( $P = 0.001$ ). The number of skin puncture sites was 1.20 in the combined group and 1.25 in the palpation group ( $P = 0.398$ ). The success rate at first needle pass was 88.89% in the combined group and 66.67% in the palpation group ( $P = 0.045$ ) (Table 3).

The rate of complications from the procedure (nerve irritation during the procedure, backache during the procedure, unintentional dural and vascular punctures, unilateral or patchy block and failed block) was low (Table 4). One unintentional dural puncture occurred in each group. There were 7 cases of unintentional vascular punctures (1 case in the combined group and 6 cases in the palpation group), 5 cases of nerve irritation during the procedure (1 case in the combined group and 4 cases in the palpation group), and 3 cases of backache during the procedure (1 case in the combined group and 2 cases in the palpation group). One case of unilateral block occurred in each group and a second epidural puncture was administered to the patients. There were no significant differences between the two groups regarding the rate of complications from the procedures (Table 4).

## DISCUSSION

This randomized controlled trial demonstrated no lengthening of the total duration of the epidural procedure with preprocedure ultrasound combined with the palpation technique, which was performed by six experienced anesthesiologists in parturients with normal weights undergoing labor analgesia. The total duration of the epidural procedure included the time for the ultrasound measurements, epidural puncture and catheterization in the combined group and only the epidural puncture and catheterization in palpation group. The total duration of the epidural procedure was com-

**Table 1 Patient baseline characteristics**

All parturient	Combined group (n = 36)	Palpation group (n = 36)	P value
Age (yr)	29.25 ± 3.05	29.39 ± 2.72	0.248
Height (cm)	162.06 ± 4.65	162.08 ± 5.04	0.507
Weight (kg)	72.56 ± 10.2	69.33 ± 7.96	0.645
BMI (kg/m <sup>2</sup> )	27.61 ± 3.59	26.37 ± 2.67	0.213
ASA classification	2.0 ± 0.61	2.0 ± 0.53	0.985

All values are expressed as the mean ± SD. No significant differences between the two groups. ASA: American Society of Anesthesiologists; BMI: Body mass index.

**Table 2 Duration of the procedure**

All parturients	Combined group (n = 36)	Palpation group (n = 36)	P value
Total duration of the epidural procedure(s)	406.5 ± 92.15	380.0 ± 128.2	0.318
Time to perform epidural puncture and catheterization procedure (s)	320.62 ± 87.33	380.0 ± 128.2	0.001 <sup>1</sup>
Time to perform ultrasound procedure (s)	85.83 ± 3.92	NA	NA

<sup>1</sup>Significant statistical analyses. All values expressed as the mean ± SD. There was no significant difference in duration of the total epidural procedure between the two groups.

**Table 3 Characteristics of the epidural procedure**

All parturient	Combined group (n = 36)	Palpation group (n = 36)	P value
Number of needle passes	1.14 ± 0.42	1.72 ± 0.94	0.001 <sup>1</sup>
Number of skin punctures	1.20 ± 0.12	1.25 ± 0.20	0.398
Success rate at the first needle pass	32 (88.89)	24 (66.67)	0.045 <sup>1</sup>
Depth from skin to epidural space	4.40 ± 0.45	4.41 ± 0.52	0.965

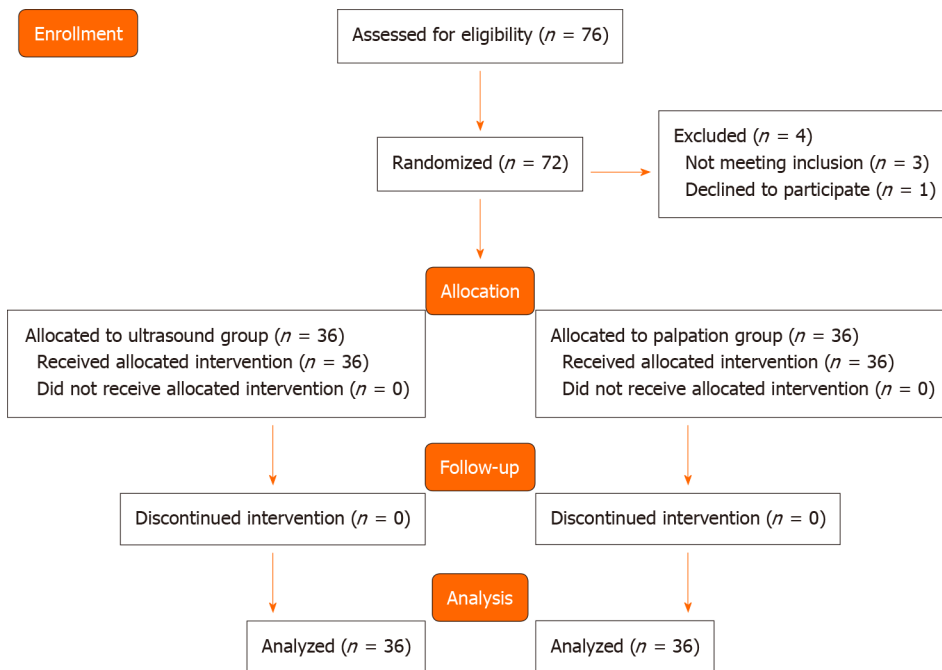
<sup>1</sup>Significant statistical analyses. Data are presented as the mean ± SD or n (%).

**Table 4 Complications of the procedure**

No. of patients with side effects	Combined group (n = 36)	Palpation group (n = 36)	P value
Vascular puncture	1	6	0.107
Dural puncture	1	1	0.754
Nerve irritation during the procedure	1	4	0.201
Backache during the procedure	1	2	0.555
Unilateral or patchy block	1	1	0.754
Failed block	1	2	0.555

Data are presented as a number. No significant difference between the two groups.

parable, 406 ± 92.14 s and 380.03 ± 18.27 s for the combined and palpation groups respectively ( $P = 0.053$ ). Tawfik *et al*[17] showed that there was a median 30 s reduction in the ultrasound group compared with the traditional palpation technique in parturients undergoing cesarean delivery; however, in that study, the duration of preprocedure ultrasound imaging was not recorded, and the total duration of the



**Figure 1 CONSORT flow diagram.** All 72 parturients were assigned to two groups and underwent epidural analgesia for labor.

epidural procedure in the two groups was not compared. In that study, time to perform the epidural puncture and catheterization was  $331.87 \pm 82.70$  s in the ultrasound group and  $385.47 \pm 135.87$  s in the palpation group ( $P < 0.05$ ). In our study, time to perform the epidural puncture and catheterization procedure was  $320.62 \pm 87.33$  s in the combined group and  $380.0 \pm 128.2$  s in the palpation group ( $P = 0.048$ ). Our outcomes were similar to that study considering the effects of preprocedure ultrasound on the duration of the epidural procedures. Ansari *et al*[11] found that preprocedure ultrasound imaging needed an additional 75 s compared to the traditional palpation technique in a population of 75 laboring women. The mean time to perform preprocedure ultrasound imaging in our study was  $85.83 \pm 3.91$  s. Our outcome was similar to that study regarding the mean time to perform preprocedure ultrasound imaging. Preprocedure ultrasound imaging requires time, but it can shorten the duration of the epidural puncture and catheterization procedure. In our study, using ultrasound did not lengthen the total procedural time from evaluating the puncture site to complete epidural catheterization compared with the traditional palpation technique.

Our study showed a significant improvement of the epidural puncture and catheterization procedures when using preprocedure ultrasound imaging combined with the palpation technique compared with the traditional palpation technique for labor analgesia. Our outcomes demonstrated significant differences of needle passes ( $1.14$  vs  $1.72$ , respectively;  $P = 0.001$ ) and first-pass success rate between the combined and palpation group ( $88.89\%$  vs  $66.67\%$ , respectively;  $P = 0.045$ ). A publication in 2016 based on two meta-analyses reported that the preprocedure spinal ultrasound increased the first-pass success rate compared with the traditional palpation technique [7]. Ansari *et al*[11] reported that the use of preprocedure ultrasound reduced the number of punctures and was associated with improved efficacy of the neuraxial block and higher patient satisfaction in obstetrics. Our outcome was similar to these studies, and demonstrated that preprocedure ultrasound imaging can facilitate epidural catheterization compared with the traditional palpation technique.

The mean depth from the skin to epidural space was  $4.40 \pm 0.45$  (3.3 to 5.8) cm in the combined group and  $4.41 \pm 0.52$  (3.1 to 5.7) in the palpation group ( $P = 0.965$ ). There were no significant differences between the two groups. The mean depth to the epidural space from the skin has been recorded as 4.6–5.3 cm in a Michigan parturient [18,19]; in this study, we found that the mean depth to the epidural space from the skin was 4.1–4.7 cm in a Beijing parturient.

In this study, the ultrasound was in the labor room and the anesthesiologist had experience of neuraxial block for more than 6 mo. We showed that using ultrasound did not lengthen the total duration of the epidural procedures compared with the traditional palpation technique, which were performed by three experienced

anesthesiologists in parturients with normal weights undergoing labor analgesia. Meanwhile, using ultrasound can improve the safety and efficacy of the epidural puncture, which is meaningful for parturients who need rapid and effective epidural puncture while the painful labor continues. It is also meaningful for the application of ultrasound in obstetrical analgesia.

There were three differences for our study compared with other previous studies. First, we recorded the time taken to perform the ultrasound imaging, the epidural puncture and catheterization in our study. Ansari *et al*[11] recorded the time from the time of skin puncture to the time of viewing cerebrospinal fluid between the landmark and the ultrasound groups in spinal anesthesia. Tawfik *et al*[17] recorded the median (range) duration of the epidural procedure in the ultrasound group and in the palpation group. In those studies, the total time for ultrasound imaging, the epidural puncture and catheterization were not recorded. The total procedural time could not be compared in these studies, but this total procedural time is important for the widespread use of ultrasound in obstetrical analgesia. Second, we excluded obese parturients. Many studies have shown that preprocedure ultrasound facilitates the epidural procedure and decreases the complication rate especially in obese parturients [4] or those with difficult landmarks[3]. This study excluded obese parturients to reduce the impact on results. Third, we did not analyze the difficulty level of palpable landmarks for parturients. The difficulty level of the palpable landmarks was associated with the experience of the anesthesiologist and the degree of obesity of the parturient.

Two limitations of this study are worth noting. First, the sample size was relatively small, and it was not sufficient to illustrate the differences in complications such as vascular puncture, dural puncture, and nerve irritation between the two groups. Second, maternal satisfaction was not assessed. The maternal satisfaction to epidural catheterization can show the superiority of preprocedure ultrasound measurement in epidural analgesia for labor[20].

## CONCLUSION

This study demonstrated no lengthening of the total duration of the epidural procedures with preprocedure ultrasound imaging combined with the palpation technique compared with traditional anatomical landmarks technique, which were performed by six experienced anesthesiologists in parturients with normal weights undergoing labor analgesia. A significant improvement in epidural puncture and catheterization with preprocedure ultrasound was demonstrated in this study. An actual clinical benefit was found for preprocedure ultrasound for epidural analgesia for labor.

## ARTICLE HIGHLIGHTS

### Research background

Rapid and effective epidural puncture is particularly important for parturients requiring labor analgesia.

### Research motivation

To determine whether the combined technique increases the total duration of the epidural procedure and improves the success rate of the epidural analgesia.

### Research objectives

Seventy-two parturient were assigned to two groups (combined or palpation group). All epidurals were performed by six anesthesiologists.

### Research methods

Preprocedure ultrasound imaging combined with palpation technique was used in this study.

### Research results

Total duration of the epidural procedure was similar between two groups. A significant improvement was demonstrated for epidural puncture and catheterization

in the combined group.

### Research conclusions

A significant improvement in epidural puncture and catheterization with preprocedure ultrasound was demonstrated.

### Research perspectives

Ultrasound-guided epidural puncture and catheterization should be studied in future.

## REFERENCES

- 1 **Marhofer P**, Willschke H, Kettner S. Current concepts and future trends in ultrasound-guided regional anesthesia. *Curr Opin Anaesthesiol* 2010; **23**: 632-636 [PMID: 20689408 DOI: 10.1097/ACO.0b013e32833e2891]
- 2 **Bhatia K**, Kochhar P, Clegg I, Maguire S. The availability and use of ultrasound in UK obstetric anaesthesia. *Int J Obstet Anesth* 2016; **25**: 91-92 [PMID: 26718699 DOI: 10.1016/j.ijoa.2015.10.001]
- 3 **Grau T**, Leipold RW, Conradi R, Martin E. Ultrasound control for presumed difficult epidural puncture. *Acta Anaesthesiol Scand* 2001; **45**: 766-771 [PMID: 11421838 DOI: 10.1034/j.1399-6576.2001.045006766.x]
- 4 **Wang Q**, Yin C, Wang TL. Ultrasound facilitates identification of combined spinal-epidural puncture in obese parturients. *Chin Med J (Engl)* 2012; **125**: 3840-3843 [PMID: 23106885]
- 5 **Sahin T**, Balaban O, Sahin L, Solak M, Tokar K. A randomized controlled trial of preinsertion ultrasound guidance for spinal anaesthesia in pregnancy: outcomes among obese and lean parturients: ultrasound for spinal anesthesia in pregnancy. *J Anesth* 2014; **28**: 413-419 [PMID: 24141882 DOI: 10.1007/s00540-013-1726-1]
- 6 **Yoshida T**, Shimizu H, Furutani K, Baba H. Unintentional epidural placement of a thoracic paravertebral catheter inserted using an ultrasound-guided technique: a case report. *J Anesth* 2016; **30**: 727-730 [PMID: 27040105 DOI: 10.1007/s00540-016-2170-9]
- 7 **Arzola C**. Preprocedure Ultrasonography Before Initiating a Neuraxial Anesthetic Procedure. *Anesth Analg* 2017; **124**: 712-713 [PMID: 27669557 DOI: 10.1213/ANE.0000000000001627]
- 8 **Perlas A**, Chaparro LE, Chin KJ. Lumbar Neuraxial Ultrasound for Spinal and Epidural Anesthesia: A Systematic Review and Meta-Analysis. *Reg Anesth Pain Med* 2016; **41**: 251-260 [PMID: 25493689 DOI: 10.1097/AAP.0000000000000184]
- 9 **Arzola C**, Mikhael R, Margarido C, Carvalho JC. Spinal ultrasound versus palpation for epidural catheter insertion in labour: A randomised controlled trial. *Eur J Anaesthesiol* 2015; **32**: 499-505 [PMID: 25036283 DOI: 10.1097/EJA.0000000000000119]
- 10 **Shaikh F**, Brzezinski J, Alexander S, Arzola C, Carvalho JC, Beyene J, Sung L. Ultrasound imaging for lumbar punctures and epidural catheterisations: systematic review and meta-analysis. *BMJ* 2013; **346**: f1720 [PMID: 23532866 DOI: 10.1136/bmj.f1720]
- 11 **Ansari T**, Yousef A, El Gamassy A, Fayed M. Ultrasound-guided spinal anaesthesia in obstetrics: is there an advantage over the landmark technique in patients with easily palpable spines? *Int J Obstet Anesth* 2014; **23**: 213-216 [PMID: 24768303 DOI: 10.1016/j.ijoa.2014.03.001]
- 12 **Ecimovic P**, Loughrey JP. Ultrasound in obstetric anaesthesia: a review of current applications. *Int J Obstet Anesth* 2010; **19**: 320-326 [PMID: 20605438 DOI: 10.1016/j.ijoa.2010.03.006]
- 13 **Balki M**, Lee Y, Halpern S, Carvalho JC. Ultrasound imaging of the lumbar spine in the transverse plane: the correlation between estimated and actual depth to the epidural space in obese parturients. *Anesth Analg* 2009; **108**: 1876-1881 [PMID: 19448216 DOI: 10.1213/ane.0b013e3181a323f6]
- 14 **Vezzani A**, Manca T, Brusasco C, Santori G, Cantadori L, Ramelli A, Gonzi G, Nicolini F, Gherli T, Corradi F. A randomized clinical trial of ultrasound-guided infra-clavicular cannulation of the subclavian vein in cardiac surgical patients: short-axis versus long-axis approach. *Intensive Care Med* 2017; **43**: 1594-1601 [PMID: 28289815 DOI: 10.1007/s00134-017-4756-6]
- 15 **Huang BW**, Huang Q, Liao JH. Optimum interval time of intermittent epidural bolus for labor analgesia. *Guangdong Yikexue Xuebao* 2018; **36**: 647-649
- 16 **Grau T**, Leipold RW, Conradi R, Martin E, Motsch J. Efficacy of ultrasound imaging in obstetric epidural anesthesia. *J Clin Anesth* 2002; **14**: 169-175 [PMID: 12031746 DOI: 10.1016/s0952-8180(01)00378-6]
- 17 **Tawfik MM**, Atallah MM, Elkharroutly WS, Allakkany NS, Abdelkhalik M. Does Preprocedural Ultrasound Increase the First-Pass Success Rate of Epidural Catheterization Before Cesarean Delivery? *Anesth Analg* 2017; **124**: 851-856 [PMID: 27183373 DOI: 10.1213/ANE.0000000000001325]
- 18 **Warman P**, Youngs P. An observational study of the relationship between lumbar epidural space depth and body mass index in Michigan parturients. *Int J Obstet Anesth* 2008; **17**: 283; author reply 283-283; author reply 284 [PMID: 18501585 DOI: 10.1016/j.ijoa.2008.01.014]
- 19 **Watts RW**. The influence of obesity on the relationship between body mass index and the distance to the epidural space from the skin. *Anaesth Intensive Care* 1993; **21**: 309-310 [PMID: 8342760 DOI: 10.1177/0310057X9302100309]



- 20 **Melese T**, Gebrehiwot Y, Bisetegn D, Habte D. Assessment of client satisfaction in labor and delivery services at a maternity referral hospital in Ethiopia. *Pan Afr Med J* 2014; **17**: 76 [PMID: 25018826 DOI: 10.11604/pamj.2014.17.76.3189]





Published by **Baishideng Publishing Group Inc**  
7041 Koll Center Parkway, Suite 160, Pleasanton, CA 94566, USA

**Telephone:** +1-925-3991568

**E-mail:** [bpgoffice@wjgnet.com](mailto:bpgoffice@wjgnet.com)

**Help Desk:** <https://www.f6publishing.com/helpdesk>

<https://www.wjgnet.com>

