

World Journal of *Clinical Cases*

World J Clin Cases 2021 July 26; 9(21): 5754-6177



Contents

Thrice Monthly Volume 9 Number 21 July 26, 2021

REVIEW

- 5754 Treatment strategies for hepatocellular carcinoma with extrahepatic metastasis
Long HY, Huang TY, Xie XY, Long JT, Liu BX

MINIREVIEWS

- 5769 Prevention of hepatitis B reactivation in patients requiring chemotherapy and immunosuppressive therapy
Shih CA, Chen WC
- 5782 Research status on immunotherapy trials of gastric cancer
Liang C, Wu HM, Yu WM, Chen W
- 5794 Therapeutic plasma exchange for hyperlipidemic pancreatitis: Current evidence and unmet needs
Zheng CB, Zheng ZH, Zheng YP
- 5804 Essentials of thoracic outlet syndrome: A narrative review
Chang MC, Kim DH

ORIGINAL ARTICLE

Case Control Study

- 5812 Soluble programmed death-1 is predictive of hepatitis B surface antigen loss in chronic hepatitis B patients after antiviral treatment
Tan N, Luo H, Kang Q, Pan JL, Cheng R, Xi HL, Chen HY, Han YF, Yang YP, Xu XY

Retrospective Cohort Study

- 5822 Tunneled biopsy is an underutilised, simple, safe and efficient method for tissue acquisition from subepithelial tumours
Koutsoumpas A, Perera R, Melton A, Kuker J, Ghosh T, Braden B

Retrospective Study

- 5830 Macular ganglion cell complex injury in different stages of anterior ischemic optic neuropathy
Zhang W, Sun XQ, Peng XY
- 5840 Value of refined care in patients with acute exacerbation of chronic obstructive pulmonary disease
Na N, Guo SL, Zhang YY, Ye M, Zhang N, Wu GX, Ma LW
- 5850 Facilitators and barriers to colorectal cancer screening in an outpatient setting
Samuel G, Kratzer M, Asagbra O, Kinderwater J, Poola S, Udom J, Lambert K, Mian M, Ali E
- 5860 Development and validation of a prognostic nomogram for colorectal cancer after surgery
Li BW, Ma XY, Lai S, Sun X, Sun MJ, Chang B

Observational Study

- 5873** Potential protein-phenotype correlation in three lipopolysaccharide-responsive beige-like anchor protein-deficient patients

Tang WJ, Hu WH, Huang Y, Wu BB, Peng XM, Zhai XW, Qian XW, Ye ZQ, Xia HJ, Wu J, Shi JR

- 5889** Quantification analysis of pleural line movement for the diagnosis of pneumothorax

Xiao R, Shao Q, Zhao N, Liu F, Qian KJ

Prospective Study

- 5900** Preprocedure ultrasound imaging combined with palpation technique in epidural labor analgesia

Wu JP, Tang YZ, He LL, Zhao WX, An JX, Ni JX

Randomized Controlled Trial

- 5909** Effects of perioperative rosuvastatin on postoperative delirium in elderly patients: A randomized, double-blind, and placebo-controlled trial

Xu XQ, Luo JZ, Li XY, Tang HQ, Lu WH

SYSTEMATIC REVIEWS

- 5921** Pain assessment and management in the newborn: A systematized review

Garcia-Rodriguez MT, Bujan-Bravo S, Seijo-Bestilleiro R, Gonzalez-Martin C

META-ANALYSIS

- 5932** Fatigue prevalence in men treated for prostate cancer: A systematic review and meta-analysis

Luo YH, Yang YW, Wu CF, Wang C, Li WJ, Zhang HC

CASE REPORT

- 5943** Diagnostic discrepancy between colposcopy and vaginoscopy: A case report

Li Q, Zhang HW, Sui L, Hua KQ

- 5948** Contrast enhanced ultrasound in diagnosing liver lesion that spontaneously disappeared: A case report

Wang ZD, Haitham S, Gong JP, Pen ZL

- 5955** COVID-19 patient with an incubation period of 27 d: A case report

Du X, Gao Y, Kang K, Chong Y, Zhang ML, Yang W, Wang CS, Meng XL, Fei DS, Dai QQ, Zhao MY

- 5963** Awake extracorporeal membrane oxygenation support for a critically ill COVID-19 patient: A case report

Zhang JC, Li T

- 5972** Meigs syndrome with pleural effusion as initial manifestation: A case report

Hou YY, Peng L, Zhou M

- 5980** Giant hemangioma of the caudate lobe of the liver with surgical treatment: A case report

Wang XX, Dong BL, Wu B, Chen SY, He Y, Yang XJ

- 5988** Anti-programmed cell death ligand 1-based immunotherapy in recurrent hepatocellular carcinoma with inferior vena cava tumor thrombus and metastasis: Three case reports
Liu SR, Yan Q, Lin HM, Shi GZ, Cao Y, Zeng H, Liu C, Zhang R
- 5999** Minimal deviation adenocarcinoma with elevated CA19-9: A case report
Dong Y, Lv Y, Guo J, Sun L
- 6005** Isolated fungus ball in a single cell of the left ethmoid roof: A case report
Zhou LQ, Li M, Li YQ, Wang YJ
- 6009** Rare case of brucellosis misdiagnosed as prostate carcinoma with lumbar vertebra metastasis: A case report
Yan JF, Zhou HY, Luo SF, Wang X, Yu JD
- 6017** Myeloid sarcoma of the colon as initial presentation in acute promyelocytic leukemia: A case report and review of the literature
Wang L, Cai DL, Lin N
- 6026** Primary follicular lymphoma in the renal pelvis: A rare case report
Shen XZ, Lin C, Liu F
- 6032** Rosai-Dorfman disease in the spleen of a pediatric patient: A case report
Ryu H, Hwang JY, Kim YW, Kim TU, Jang JY, Park SE, Yang EJ, Shin DH
- 6041** Relapsed/refractory classical Hodgkin lymphoma effectively treated with low-dose decitabine plus tislelizumab: A case report
Ding XS, Mi L, Song YQ, Liu WP, Yu H, Lin NJ, Zhu J
- 6049** Disseminated *Fusarium* bloodstream infection in a child with acute myeloid leukemia: A case report
Ning JJ, Li XM, Li SQ
- 6056** Familial hemophagocytic lymphohistiocytosis type 2 in a female Chinese neonate: A case report and review of the literature
Bi SH, Jiang LL, Dai LY, Wang LL, Liu GH, Teng RJ
- 6067** Usefulness of metagenomic next-generation sequencing in adenovirus 7-induced acute respiratory distress syndrome: A case report
Zhang XJ, Zheng JY, Li X, Liang YJ, Zhang ZD
- 6073** Neurogenic orthostatic hypotension with Parkinson's disease as a cause of syncope: A case report
Li Y, Wang M, Liu XL, Ren YF, Zhang WB
- 6081** SATB2-associated syndrome caused by a novel SATB2 mutation in a Chinese boy: A case report and literature review
Zhu YY, Sun GL, Yang ZL
- 6091** Diagnosis and treatment discussion of congenital factor VII deficiency in pregnancy: A case report
Yang Y, Zeng YC, Rumende P, Wang CG, Chen Y

- 6102** Unusual immunohistochemical “null” pattern of four mismatch repair proteins in gastric cancer: A case report
Yue M, Liu JY, Liu YP
- 6110** Generalized periodontitis treated with periodontal, orthodontic, and prosthodontic therapy: A case report
Kaku M, Matsuda S, Kubo T, Shimoe S, Tsuga K, Kurihara H, Tanimoto K
- 6125** Ligamentum flavum hematoma following a traffic accident: A case report
Yu D, Lee W, Chang MC
- 6130** Oral cyclophosphamide-induced posterior reversible encephalopathy syndrome in a patient with ANCA-associated vasculitis: A case report
Kim Y, Kwak J, Jung S, Lee S, Jang HN, Cho HS, Chang SH, Kim HJ
- 6138** Encapsulating peritoneal sclerosis in an AMA-M2 positive patient: A case report
Yin MY, Qian LJ, Xi LT, Yu YX, Shi YQ, Liu L, Xu CF
- 6145** Multidisciplinary diagnostic dilemma in differentiating Madelung’s disease – the value of superb microvascular imaging technique: A case report
Seskute G, Dapkute A, Kausaite D, Strainiene S, Talijunas A, Butrimiene I
- 6155** Complicated course of biliary inflammatory myofibroblastic tumor mimicking hilar cholangiocarcinoma: A case report and literature review
Strainiene S, Sedleckaite K, Jarasunas J, Savlan I, Stanaitis J, Stundiene I, Strainys T, Liakina V, Valantinas J
- 6170** Fruquintinib beneficial in elderly patient with neoplastic pericardial effusion from rectal cancer: A case report
Zhang Y, Zou JY, Xu YY, He JN

ABOUT COVER

Editorial Board Member of *World Journal of Clinical Cases*, Jae Gil Lee, MD, PhD, Professor, Surgeon, Department of Surgery, Yonsei University College of Medicine, Seoul 03722, South Korea. jakii@yuhs.ac

AIMS AND SCOPE

The primary aim of *World Journal of Clinical Cases* (WJCC, *World J Clin Cases*) is to provide scholars and readers from various fields of clinical medicine with a platform to publish high-quality clinical research articles and communicate their research findings online.

WJCC mainly publishes articles reporting research results and findings obtained in the field of clinical medicine and covering a wide range of topics, including case control studies, retrospective cohort studies, retrospective studies, clinical trials studies, observational studies, prospective studies, randomized controlled trials, randomized clinical trials, systematic reviews, meta-analysis, and case reports.

INDEXING/ABSTRACTING

The WJCC is now indexed in Science Citation Index Expanded (also known as SciSearch®), Journal Citation Reports/Science Edition, Scopus, PubMed, and PubMed Central. The 2021 Edition of Journal Citation Reports® cites the 2020 impact factor (IF) for WJCC as 1.337; IF without journal self cites: 1.301; 5-year IF: 1.742; Journal Citation Indicator: 0.33; Ranking: 119 among 169 journals in medicine, general and internal; and Quartile category: Q3. The WJCC's CiteScore for 2020 is 0.8 and Scopus CiteScore rank 2020: General Medicine is 493/793.

RESPONSIBLE EDITORS FOR THIS ISSUE

Production Editor: Ji-Hong Lin; Production Department Director: Xiang Li; Editorial Office Director: Jin-Lai Wang.

NAME OF JOURNAL

World Journal of Clinical Cases

ISSN

ISSN 2307-8960 (online)

LAUNCH DATE

April 16, 2013

FREQUENCY

Thrice Monthly

EDITORS-IN-CHIEF

Dennis A Bloomfield, Sandro Vento, Bao-Gan Peng

EDITORIAL BOARD MEMBERS

<https://www.wjgnet.com/2307-8960/editorialboard.htm>

PUBLICATION DATE

July 26, 2021

COPYRIGHT

© 2021 Baishideng Publishing Group Inc

INSTRUCTIONS TO AUTHORS

<https://www.wjgnet.com/bpg/gerinfo/204>

GUIDELINES FOR ETHICS DOCUMENTS

<https://www.wjgnet.com/bpg/GerInfo/287>

GUIDELINES FOR NON-NATIVE SPEAKERS OF ENGLISH

<https://www.wjgnet.com/bpg/gerinfo/240>

PUBLICATION ETHICS

<https://www.wjgnet.com/bpg/GerInfo/288>

PUBLICATION MISCONDUCT

<https://www.wjgnet.com/bpg/gerinfo/208>

ARTICLE PROCESSING CHARGE

<https://www.wjgnet.com/bpg/gerinfo/242>

STEPS FOR SUBMITTING MANUSCRIPTS

<https://www.wjgnet.com/bpg/GerInfo/239>

ONLINE SUBMISSION

<https://www.f6publishing.com>



Myeloid sarcoma of the colon as initial presentation in acute promyelocytic leukemia: A case report and review of the literature

Lei Wang, Da-Li Cai, Na Lin

ORCID number: Lei Wang 0000-0003-1075-0086; Da-Li Cai 0000-0003-2441-223X; Na Lin 0000-0002-6725-1205.

Author contributions: Wang L and Cai DL guided the diagnosis and treatment of this case; Wang L and Lin N reviewed all the related literature and analyzed the clinical data; Wang L drafted the manuscript; Lin N critically revised the manuscript; all authors read and approved the final manuscript.

Supported by the National Natural Science Foundation of China (General Program), No. 81170519.

Informed consent statement: Informed written consent was obtained from the patient for publication of this report and any accompanying images.

Conflict-of-interest statement: The authors declare that they have no conflict of interest to report.

CARE Checklist (2016) statement: The authors have read the CARE Checklist (2016), and the manuscript was prepared and revised according to the CARE Checklist (2016).

Open-Access: This article is an open-access article that was selected by an in-house editor and fully peer-reviewed by external

Lei Wang, Da-Li Cai, Na Lin, Department of Hematology, The First Affiliated Hospital of China Medical University, Shenyang 110001, Liaoning Province, China

Corresponding author: Na Lin, MD, Associate Professor, Department of Hematology, The First Affiliated Hospital of China Medical University, No. 155 Nanjing North Street, Shenyang 110001, Liaoning Province, China. salinaofcmu@163.com

Abstract

BACKGROUND

Myeloid sarcoma (MS) rarely occurs in acute promyelocytic leukemia (APL) at onset, but it can develop in relapse cases, especially after APL treated with all-trans retinoic acid (ATRA). Therefore little is known about the clinical features and suitable treatment for APL related MS due to the rarity of the disease, although this may be different from the treatment and prognosis of MS in the relapse stage. To our best knowledge, this is the second case report of APL initial presentation as colon MS.

CASE SUMMARY

A 77-year-old woman complained of intermittent right lower abdominal pain, black stool, and difficult defecation for 2 mo. Physical examination showed diffuse tenderness during deep palpation and an anemic appearance. Laboratory findings showed positivity for fecal occult blood testing; white blood cell count: $3.84 \times 10^9/L$; hemoglobin: 105 g/L; platelet count: $174 \times 10^9/L$; and negativity for tumor markers. Abdominal enhanced computed tomography showed a space occupying lesion in the colon (1.9 cm). Fibrocolonoscopy revealed a polypoid and ulcerated mass measuring 2.5 cm. The tumor was removed. To our surprise, MS was confirmed by immunohistochemistry. *PML/RAR α* fusion gene was detected in colon specimens by fluorescent *in situ* hybridization and real-time reverse transcription polymerase chain reaction, which was consistent with the bone marrow. She was diagnosed as having APL related MS. A smooth and unobstructed intestinal wall was found by fibrocolonoscopy, and continuous molecular remission was confirmed in both the bone marrow and colon after four courses of ATRA + arsenic trioxide (ATO). ATRA + ATO showed a favorable therapeutic response for both APL and MS.

CONCLUSION

Early use of ATRA can benefit APL patients, regardless of whether MS is the first or recurrent manifestation.

reviewers. It is distributed in accordance with the Creative Commons Attribution NonCommercial (CC BY-NC 4.0) license, which permits others to distribute, remix, adapt, build upon this work non-commercially, and license their derivative works on different terms, provided the original work is properly cited and the use is non-commercial. See: <http://creativecommons.org/licenses/by-nc/4.0/>

Manuscript source: Unsolicited manuscript

Specialty type: Medicine, general and internal

Country/Territory of origin: China

Peer-review report's scientific quality classification

Grade A (Excellent): 0
Grade B (Very good): 0
Grade C (Good): C
Grade D (Fair): 0
Grade E (Poor): 0

Received: January 31, 2021

Peer-review started: January 31, 2021

First decision: May 1, 2021

Revised: May 7, 2021

Accepted: May 26, 2021

Article in press: May 26, 2021

Published online: July 26, 2021

P-Reviewer: Nagahara H

S-Editor: Zhang H

L-Editor: Wang TQ

P-Editor: Liu JH



Key Words: Acute promyelocytic leukemia; Myeloid sarcoma; All-trans retinoic acid; Extramedullary disease; Colon; Fluorescent *in situ* hybridization; Case report

©The Author(s) 2021. Published by Baishideng Publishing Group Inc. All rights reserved.

Core Tip: Myeloid sarcoma (MS) rarely occurs in acute promyelocytic leukemia (APL) at onset. We report the second case of APL with colon MS as the initial presentation. *De novo* APL related MS is a very rare disease. Its clinical features and prognosis may be different from those of extramedullary disease, and the disease free survival may be shorter than MS occurring in APL relapse. To date, a total of 28 cases of APL with MS as the initial presentation have been reported worldwide. The tumor was removed. Continuous complete remission was achieved after the treatment of all-trans retinoic acid (ATRA) + arsenic trioxide (ATO). After radiotherapy or tumor resection, ATRA + ATO showed a favorable therapeutic response for both APL and MS.

Citation: Wang L, Cai DL, Lin N. Myeloid sarcoma of the colon as initial presentation in acute promyelocytic leukemia: A case report and review of the literature. *World J Clin Cases* 2021; 9(21): 6017-6025

URL: <https://www.wjgnet.com/2307-8960/full/v9/i21/6017.htm>

DOI: <https://dx.doi.org/10.12998/wjcc.v9.i21.6017>

INTRODUCTION

Myeloid sarcoma (MS) may exist as an independent tumor, or as an extramedullary disease (EMD) developing in patients with acute myeloid leukemia (AML)[1], especially M2, M4, and M5 subtypes. MS is an extramedullary tumor consisting of immature myeloid cells. It can occur in any part of the body, in particular the skin, bone, lymph nodes, soft tissue, testis, and gastrointestinal tract. MS may develop *de novo* or even concurrently with 3%-8% of AML patients. It may be the only initial manifestation of relapse in AML patients regardless of the examination results of blood and bone marrow. MS rarely occurs in acute promyelocytic leukemia (APL) at onset[2-4], but it can develop in relapse cases, especially after APL treated with all trans retinoic acid (ATRA)[5]. de Botton *et al*[3] have reported the association between treatment with ATRA and extramedullary relapses. What's more, *de novo* MS as the first manifestation of APL is really a rare event, which occurs in less than 1% of EMD cases[6,7]. Therefore, little is known about the clinical features and suitable treatment for APL related MS due to the rarity of the disease, although these may be different from those of MS in the relapse stage. To our best known, this is the second case of APL with colon MS as the initial presentation.

CASE PRESENTATION

Chief complaints

A 77-year-old woman complained of intermittent right lower abdominal pain, black stool, and difficult defecation for 2 mo.

History of present illness

The patient's uncomfortable symptoms started 2 mo ago, which had worsened over the last week.

History of past illness

The patient's medical history included diabetes and hypertension for 3 years.

Personal and family history

The patient's mother had a history of hypertension.

Physical examination

The patient's body temperature was 36.9 °C, tachycardia was 101 bpm, respiratory rate was 20 breaths/min, and blood pressure was 145/75 mmHg. Physical examination showed muscle tension, Murphy's sign and voiced mobility was negative, but diffuse tenderness during deep palpation and bowel sounds were observed 3 times per minute, together with an anemic appearance.

Laboratory examinations

Laboratory findings showed positivity for fecal occult blood testing; serum amylase: 29 U/L; serum lipase: 14.8 U/L; white blood cell (WBC) count: $3.84 \times 10^9/L$; hemoglobin: 105 g/L; platelet count: $174 \times 10^9/L$; and negativity for tumor markers.

Imaging examinations

Hepatomegaly and splenomegaly were not found by Doppler ultrasound of the abdomen. Abdominal enhanced computed tomography showed a space occupying lesion in the colon (1.9 cm), with obvious enhancement. Fibrocolonoscopy revealed a polypoid and ulcerated mass measuring 2.5 cm, with hyperemia and erosion of the ileocecal mucosa, irregular ulcer, uneven bottom, annular lesions in the mucosa, and moderate to severe inflammatory cell infiltration. Part of the tumor was removed for biopsy.

FINAL DIAGNOSIS

To our surprise, MS was confirmed by immunohistochemistry using a panel of myeloid cell surface marker antibodies, which revealed CK+, CD68+, CgA+, CD117+, and MPO+. The Ki67 index was 65%, and B-cell and T cell lymphomas were excluded by negative staining for CD20 and CD3. Subsequently, bone marrow aspiration revealed 68% of blasts, and the patient was diagnosed with APL based on the morphology (Figure 1A) and immunohistochemistry (CD33+, CD117+, CD13+, CD64+, MPO+, CD9+, CD34-, CD19-, CD10-, and cCD79a-) (Figure 1B). Cytogenetics revealed a karyotype with $t(15; 17)(q22; q21)$ (Figure 1C), and a real-time reverse transcription polymerase chain reaction assay showed a typical *PML/RARα* fusion, which further confirmed the diagnosis. Fluorescence *in situ* hybridization (FISH) using a *PML/RARα* dual-color, dual-fusion probe showed *PML/RARα* fusion signals (Figure 1D). *PML/RARα* fusion gene was also detected in colon specimens by FISH and real-time reverse transcription polymerase chain reaction (PCR), which was consistent with the bone marrow (Figure 1E). The final diagnosis was APL related MS (MS/APL).

TREATMENT

After two courses of ATRA + arsenic trioxide (ATO) treatment, the patient's symptoms improved, and laboratory examination showed improvement of anemia. PCR analysis for *PML/RARα* transcription and FISH using a *PML/RARα* dual-color, dual-fusion probe on bone marrow cells confirmed molecular remission. Meanwhile, colon ulcerative lesions improved significantly, as revealed by fibrocolonoscopy.

OUTCOME AND FOLLOW-UP

Continuous molecular remission was confirmed in both the bone marrow and colon. A smooth and unobstructed intestinal wall was found by fibrocolonoscopy without ulcer or polypoid masses after four courses of ATRA + ATO. ATRA + ATO showed a favorable therapeutic response for both APL and MS.

DISCUSSION

MS as an initial presentation of APL is an extremely rare event, and more than 95% of cases occur at the time of relapse, especially after ATRA treatment[8]. High WBC count is suggested as a risk factor[7]. ATRA enhances the migration and adhesion of

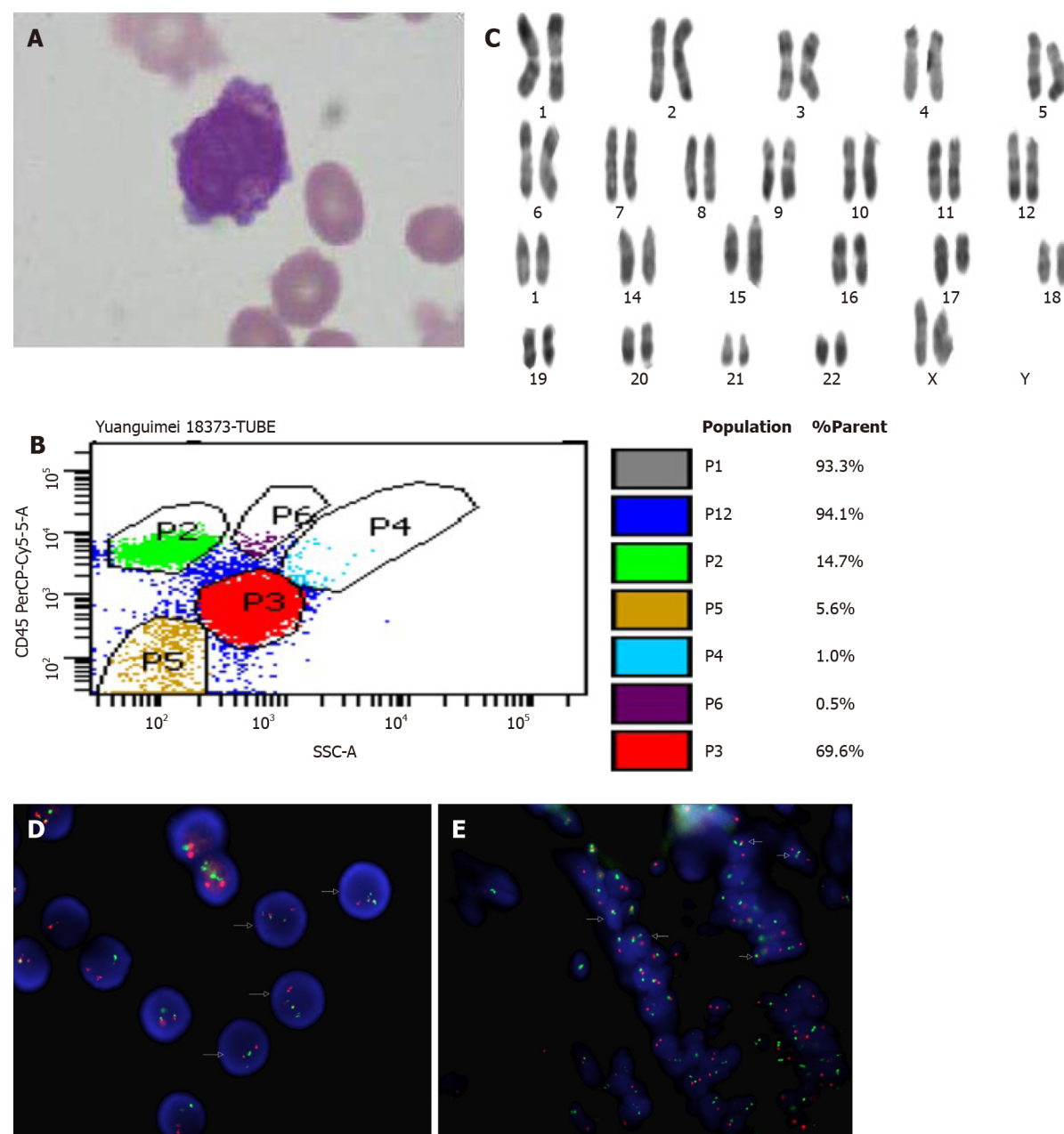


Figure 1 Laboratory examination results of this patient. A: Bone marrow morphology revealed 68% of abnormal promyelocyte cells (100 ×); B: Flow cytometric analysis of bone marrow cells showed a population of abnormal cells (P3: 69.6%); C: Karyotype of this patient: 46, XX, t(15; 17)(q22; q21); D: Fluorescence *in situ* hybridization (FISH) results in bone marrow cells at diagnosis showed *PML/RARα* fusion; E: FISH results in intestinal tissue cells at diagnosis showed *PML/RARα* fusion.

extramedullary tissues by increasing the adhesion molecules of leukemia cells *in vitro*, which explains why the number of patients with extramedullary relapse is increasing [9]. However, the risk of EMD after treatment with ATRA is not increased compared with chemotherapy alone in a large cohort study [10]. MS has the tendency to develop into AML, and most of the untreated MS cases transformed into acute leukemia within 6 mo. So comprehensive and careful examination of the bone marrow smear and biopsy is important for patients with MS in order to rule out bone marrow involvement [11,12]. However, *PML/RARα* fusion gene or characteristic chromosome translocation of MS could be detected in patients with a normal result of bone marrow smear and blood routine test. Once bone marrow is involved, it should be treated according to the workup of APL. For MS, surgical resection, radiotherapy, systemic chemotherapy, and hematopoietic stem cell transplantation are the main treatment methods [13]. For MS/APL, early use of ATRA can improve the prognosis, regardless of whether MS is the first or recurrent manifestation. A misdiagnosis of lymphoma may occur and diagnostic distinction can be difficult [14,15] in the isolated presentation of MS without any signs of leukemia. Tissue examination plays a very important role in

the diagnosis of MS, because some patients have no bone marrow involvement at the time of onset. When fresh tissue samples cannot be obtained, the cytogenetic abnormalities of fixed section and paraffin embedded section can be detected by FISH [16]. Once *PML/RAR α* fusion gene is found in *de novo* MS, it is recommended to use ATRA treatment and pay attention to monitoring the condition of peripheral blood and bone marrow.

De novo MS/APL is a very rare disease. Its clinical features and prognosis may be different from those of EMD, and the disease free survival may be shorter than MS occurring in APL relapse. To date, a total of 28 cases of APL with MS as the initial presentation have been reported worldwide (Table 1)[17-41]. The average age of onset was 35 (1-77) years, and sex-bias phenomenon (only 8 female) was difficult to explain due to the limited number of patients. The sites of *de novo* MS were widely distributed, and the most common sites were vertebra (6 cases) and extradural (6 cases), followed by the intestine, tongue, pelvis, skull, pleura, hip, mandible, spinal, humerus, tibia, femur, sternum, skin, mediastinal, thymus, cerebellum, and testicle. A single site was involved in most cases (16/28), and multiple site MS occurred in a few APL patients. Only one patient carried a complex karyotype, and *PML/RAR α* was detected in *de novo* MS/APL in 22 patients. Bone marrow involvement was found in most patients (18/28), and 6 of the remainders developed bone marrow involvement within 1-16 mo. Increased/decreased WBC count was only seen in nine cases, the remainders' (19/28) WBC count was normal at the time of onset. In addition, the coagulation dysfunction characteristic was observed in only six patients. The optimum therapy for MS/APL is also unclear. Twenty *de novo* MS/APL patients received ATRA with chemotherapy; 16 achieved complete remission (CR), two achieved PR, and the other two died of sepsis and cerebral hemorrhage, respectively. On the other hand, eight patients were treated only with chemotherapy without ATRA or ATO; two achieved CR, one achieved PR, and the remaining five died. The longest follow-up until now was 96 mo, and in this case, the patient was treated with radiotherapy + ATRA + chemotherapy, although radiotherapy or tumor resection together with ATRA and chemotherapy may improve the prognosis of MS/APL. MS/APL is a kind of disease with diverse clinical manifestations, molecular biology, and cytogenetics, is easily confused with stromal tumor, lymphoma, and carcinoma, and is therefore associated with a high misdiagnosis rate, poor prognosis, and high recurrence rate. Our patient complained of intermittent right lower abdominal pain, black stool, and difficult defecation, which reminded us of the possibility of gastrointestinal tumor. MS occurring in the gastrointestinal tract is relatively rare when MS occurs as the first presentation in acute promyelocytic leukemia, and only four cases have been described in the literature (Table 1, cases 25-27 and current case). Abdominal pain, change in bowel habit, and small bowel obstruction were the most common clinical presentation. In conclusion, gastrointestinal bleeding may result from coagulopathy disorders or serious thrombocytopenia caused by leukaemia, especially in APL patients, but the bleeding can also be the consequence of gastrointestinal MS. Therefore, gastrointestinal MS must be considered in those who present with black or bloody stool. However, prospective and large sample clinical trials are needed to determine the optimal treatment for MS/APL. Early recognition of this rare disease with timely treatment may improve the outcomes of patients.

CONCLUSION

To our knowledge, this is the second case report of APL with colon MS the initial presentation. *De novo* MS/APL is a very rare disease. Its clinical features and prognosis may be different from those of EMD in APL relapse. Once *PML/RAR α* fusion gene is found in *de novo* MS, it is recommended to use ATRA treatment and pay attention to monitoring the condition of peripheral blood and bone marrow. Early use of ATRA can benefit the APL patients, and radiotherapy or tumor resection together with ATRA and chemotherapy may improve the prognosis of MS/APL, regardless of whether MS is the first or recurrent manifestation.

Table 1 Clinical information of myeloid sarcoma as initial presentation in acute promyelocytic leukemia

Case	Age/sex	Location	Single or multiple sites	Chromosome	Gene	BM involvement	Progression to APL	Coagulation abnormality	WBC	Treatment	Prognosis	Ref.
1	55/M	Vertebra, extradural	Multiple	-	<i>PML/RARα</i>	No	No	No	Normal	ATRA, chemotherapy, radiation	CR (15 mo, ongoing)	Fiegl <i>et al</i> [17]
2	26/M	Vertebra, extradural	Multiple	<i>t</i> (15; 17)	<i>PML/RARα</i>	Yes	-	No	Low	ATRA, chemotherapy	CR (22 wk, ongoing)	Specchia <i>et al</i> [10]
3	61/F	Vertebra	Single	-	<i>PML/RARα</i>	No	No	-	-	Radiotherapy, ATRA, chemotherapy	CR (96 mo, ongoing)	Piñán <i>et al</i> [18]
4	52/F	Vertebra	Multiple	<i>t</i> (15; 17)	<i>PML/RARα</i>	Yes	-	No	Normal	ATRA, chemotherapy	CR (54 mo, ongoing)	Cornfield <i>et al</i> [19]
5	56/M	Vertebra	Single	<i>t</i> (15;17)	<i>PML/RARα</i>	Yes	-	No	Normal	ATRA, chemotherapy, ASCT, ATO	CR (24 mo, ongoing)	Shah <i>et al</i> [20]
6	50/F	Vertebra	Single	<i>t</i> (15; 17)	<i>PML/RARα</i>	Yes	-	-	Low	ATRA, ATO, chemotherapy	CR (44 d, ongoing)	Mori <i>et al</i> [21]
7	31/M	Extradural	Multiple	-	-	No	Yes (32 d)	Yes	Normal	Radiotherapy, ASCT	PR (23 mo, ongoing)	Zuible <i>et al</i> [22]
8	53/M	Extradural	Single	<i>t</i> (15; 17)	<i>PML/RARα</i>	Yes	-	Yes	Normal	Radiotherapy, ATRA, chemotherapy	No improvement, died of sepsis	Bittencourt <i>et al</i> [23]
9	18/M	Extradural	Multiple	<i>t</i> (15; 17)	-	No	Yes (10 mo)	No	Normal	Chemotherapy	CR (11mo, ongoing)	Savranlar <i>et al</i> [24]
10	27/M	Extradural	Single	<i>t</i> (15; 17)	<i>PML/RARα</i>	Yes	-	Yes	Normal	Tumor removed, ATRA, chemotherapy, radiotherapy	CR (293 d, ongoing)	Tosi <i>et al</i> [25]
11	4/M	Pelvis	Single	-	-	Yes	-	Yes	High	Chemotherapy	CR (14 mo, ongoing)	Belasco <i>et al</i> [26]
12	-/M	Skull, pleura, hip	Multiple	<i>t</i> (15; 17)	<i>PML/RARα</i>	No	No	-	Normal	ATRA, chemotherapy	CR (13 mo, ongoing)	Bobbio-Pallavicini <i>et al</i> [27]
13	16/F	Humerus, tibia, femur	Multiple	<i>t</i> (15; 17)	<i>PML/RARα</i>	Yes	-	No	Normal	ATRA, chemotherapy	CR (ongoing)	Fiegl <i>et al</i> [17]
14	1/M	Mandible	Single	-	<i>PML/RARα</i>	Yes	-	No	-	ATRA, chemotherapy	CR (12 mo, ongoing)	Yamashita <i>et al</i> [28]
15	50/M	Spinal	Multiple	(47, XY, +8, der (11; 22) (q10; q10), add (14) (q32), der (15) <i>t</i> (15; 17) (q22; q12), ider (17) (q10) <i>t</i> (15; 17))	<i>PML/RARα</i>	No	Yes (10 mo)	No	Normal	Chemotherapy	Died of a brain hemorrhage (40 mo)	Yamashita <i>et al</i> [29]

16	19/M	Sternum	Single	<i>t</i> (15; 17)	<i>PML/RARα</i>	No	No	No	Normal	Tumor removed, ATRA, chemotherapy	CR (24 wk, ongoing)	Thomas <i>et al</i> [30]
17	45/M	Tongue	Single	<i>t</i> (15; 17)	<i>PML/RARα</i>	Yes	-	-	High	ATRA, chemotherapy	CR (12 mo, ongoing)	Mohamedbhai <i>et al</i> [31]
18	35/M	Tongue	Single	<i>t</i> (15; 17)	<i>PML/RARα</i>	Yes	-	No	High	ATRA, chemotherapy	CR (ongoing)	Ignacio-Cconchoy <i>et al</i> [32]
19	34/M	Skin	Multiple	-	-	Yes	-	Yes	High	Chemotherapy	Died (1 mo)	Uematsu <i>et al</i> [33]
20	23/M	Mediastinal	Single	-	-	No	Yes (2 mo)	No	Normal	Radiotherapy, chemotherapy	Died of heart failure (14 mo)	Kubonishi <i>et al</i> [34]
21	21/M	Thymus	Multiple	-	-	Yes	-	No	High	Chemotherapy	Died (8 mo)	Ajarim <i>et al</i> [35]
22	27/m	Testicle	Multiple	-	<i>PML/RARα</i>	No	Yes (16 mo)	No	Normal	Radiotherapy, ATRA, chemotherapy	PR (16 mo, ongoing)	Gopal <i>et al</i> [36]
23	39/F	Cerebellum	Single	<i>t</i> (15; 17)	<i>PML/RARα</i>	Yes	-	Yes	High	Chemotherapy	Die of cerebral hemorrhage	Fukushima <i>et al</i> [37]
24	26/F	Ovary	Single	-	<i>PML/RARα</i>	No	Yes	No	Normal	Chemotherapy, ATRA	PR (43 mo, ongoing)	Wang <i>et al</i> [38]
25	17/F	Rectum	Single	<i>t</i> (15; 17)	<i>PML/RARα</i>	Yes	-	-	Normal	ATRA, chemotherapy	CR (48 mo, ongoing)	Benjazia <i>et al</i> [39]
26	66/M	Small intestine	Single	<i>t</i> (15; 17)	<i>PML/RARα</i>	Yes	-	No	Normal	ATRA, chemotherapy	Died of cerebral hemorrhage	Takeh <i>et al</i> [40]
27	29/M	Colon	Multiple	<i>t</i> (15; 17)	<i>PML/RARα</i>	Yes	-	No	Low	ATRA, chemotherapy	CR (2 mo, ongoing)	Damodar <i>et al</i> [41]
Current case	77/F	Colon	Single	<i>t</i> (15; 17)	<i>PML/RARα</i>	Yes	-	No	Normal	Tumor removed, ATRA, ATO	CR (6 mo, ongoing)	

ATRA: All-trans retinoic acid; ATO: Arsenic trioxide; ASCT: Autologous stem cell transplantation; CR: Complete remission; PR: Partial remission.

REFERENCES

- 1 **Polyatskin IL**, Artemyeva AS, Krivolapov YA. [Revised WHO classification of tumors of hematopoietic and lymphoid tissues, 2017 (4th edition):lymphoid tumors]. *Arkiv Patol* 2019; **81**: 59-65 [PMID: 31317932 DOI: 10.17116/patol20198103159]
- 2 **Wiernik PH**, De Bellis R, Muxi P, Dutcher JP. Extramedullary acute promyelocytic leukemia. *Cancer* 1996; **78**: 2510-2514 [PMID: 8952559 DOI: 10.1002/(sici)1097-0142(19961215)78:12<2510::aid-cnecr10>3.0.co;2-z]
- 3 **de Botton S**, Sanz MA, Chevret S, Dombret H, Martin G, Thomas X, Mediavilla JD, Recher C, Ades L, Quesnel B, Brault P, Fey M, Wandt H, Machover D, Guerci A, Maloisel F, Stoppa AM, Rayon C, Ribera JM, Chomienne C, Degos L, Fenaux P; European APL Group; PETHEMA Group.

- Extramedullary relapse in acute promyelocytic leukemia treated with all-trans retinoic acid and chemotherapy. *Leukemia* 2006; **20**: 35-41 [PMID: [16307026](#) DOI: [10.1038/sj.leu.2404006](#)]
- 4 **Weiss MA**, Warrell RP Jr. Two cases of extramedullary acute promyelocytic leukemia. Cytogenetics, molecular biology, and phenotypic and clinical studies. *Cancer* 1994; **74**: 1882-1886 [PMID: [8082094](#) DOI: [10.1002/1097-0142\(19941001\)74:7<1882::aid-cnrcr2820740709>3.0.co;2-w](#)]
 - 5 **Ganzel C**, Douer D. Extramedullary disease in APL: a real phenomenon to contend with or not? *Best Pract Res Clin Haematol* 2014; **27**: 63-68 [PMID: [24907018](#) DOI: [10.1016/j.beha.2014.04.001](#)]
 - 6 **Liso V**, Specchia G, Pogliani EM, Palumbo G, Mininni D, Rossi V, Teruzzi E, Mestice A, Coppi MR, Biondi A. Extramedullary involvement in patients with acute promyelocytic leukemia: a report of seven cases. *Cancer* 1998; **83**: 1522-1528 [PMID: [9781945](#) DOI: [10.1002/\(SICI\)1097-0142\(19981015\)83:8<1522::AID-CNCR6>3.0.CO;2-4](#)]
 - 7 **Vega-Ruiz A**, Faderl S, Estrov Z, Pierce S, Cortes J, Kantarjian H, Ravandi F. Incidence of extramedullary disease in patients with acute promyelocytic leukemia: a single-institution experience. *Int J Hematol* 2009; **89**: 489-496 [PMID: [19340529](#) DOI: [10.1007/s12185-009-0291-8](#)]
 - 8 **Kyaw TZ**, Maniam JA, Bee PC, Chin EF, Nadarajan VS, Shanmugam H, Kadir KA. Myeloid sarcoma: an unusual presentation of acute promyelocytic leukemia causing spinal cord compression. *Turk J Haematol* 2012; **29**: 278-282 [PMID: [24744674](#) DOI: [10.5505/tjh.2012.94809](#)]
 - 9 **Cunha De Santis G**, Tamarozzi MB, Sousa RB, Moreno SE, Secco D, Garcia AB, Lima AS, Faccioli LH, Falcão RP, Cunha FQ, Rego EM. Adhesion molecules and Differentiation Syndrome: phenotypic and functional analysis of the effect of ATRA, As2O3, phenylbutyrate, and G-CSF in acute promyelocytic leukemia. *Haematologica* 2007; **92**: 1615-1622 [PMID: [18055984](#) DOI: [10.3324/haematol.10607](#)]
 - 10 **Specchia G**, Lo Coco F, Vignetti M, Avvisati G, Fazi P, Albano F, Di Raimondo F, Martino B, Ferrara F, Selleri C, Liso V, Mandelli F. Extramedullary involvement at relapse in acute promyelocytic leukemia patients treated or not with all-trans retinoic acid: a report by the Gruppo Italiano Malattie Ematologiche dell'Adulto. *J Clin Oncol* 2001; **19**: 4023-4028 [PMID: [11600603](#) DOI: [10.1200/JCO.2001.19.20.4023](#)]
 - 11 **Tsimberidou AM**, Kantarjian HM, Estey E, Cortes JE, Verstovsek S, Faderl S, Thomas DA, Garcia-Manero G, Ferrajoli A, Manning JT, Keating MJ, Albitar M, O'Brien S, Giles FJ. Outcome in patients with nonleukemic granulocytic sarcoma treated with chemotherapy with or without radiotherapy. *Leukemia* 2003; **17**: 1100-1103 [PMID: [12764375](#) DOI: [10.1038/sj.leu.2402958](#)]
 - 12 **Avni B**, Rund D, Levin M, Grisariu S, Ben-Yehuda D, Bar-Cohen S, Paltiel O. Clinical implications of acute myeloid leukemia presenting as myeloid sarcoma. *Hematol Oncol* 2012; **30**: 34-40 [PMID: [21638303](#) DOI: [10.1002/hon.994](#)]
 - 13 **Shimizu H**, Saitoh T, Tanaka M, Mori T, Sakura T, Kawai N, Kanda Y, Nakaseko C, Yano S, Fujita H, Fujisawa S, Miyawaki S, Kanamori H, Okamoto S. Allogeneic hematopoietic stem cell transplantation for adult AML patients with granulocytic sarcoma. *Leukemia* 2012; **26**: 2469-2473 [PMID: [22699453](#) DOI: [10.1038/leu.2012.156](#)]
 - 14 **Worch J**, Ritter J, Frühwald MC. Presentation of acute promyelocytic leukemia as granulocytic sarcoma. *Pediatr Blood Cancer* 2008; **50**: 657-660 [PMID: [17437290](#) DOI: [10.1002/pbc.21190](#)]
 - 15 **Menasce LP**, Banerjee SS, Beckett E, Harris M. Extra-medullary myeloid tumour (granulocytic sarcoma) is often misdiagnosed: a study of 26 cases. *Histopathology* 1999; **34**: 391-398 [PMID: [10231412](#) DOI: [10.1046/j.1365-2559.1999.00651.x](#)]
 - 16 **Pileri SA**, Ascani S, Cox MC, Campidelli C, Bacci F, Piccioli M, Piccaluga PP, Agostinelli C, Asioli S, Novero D, Bisceglia M, Ponzoni M, Gentile A, Rinaldi P, Franco V, Vincelli D, Pileri A Jr, Gasbarra R, Falini B, Zinzani PL, Baccarani M. Myeloid sarcoma: clinico-pathologic, phenotypic and cytogenetic analysis of 92 adult patients. *Leukemia* 2007; **21**: 340-350 [PMID: [17170724](#) DOI: [10.1038/sj.leu.2404491](#)]
 - 17 **Fiegl M**, Rieger C, Braess J, Haferlach T, Schnittger S, Schoch C, Hiddemann W, Ostermann H. Isolated epidural chloroma with translocation t(15; 17) successfully treated with chemotherapy and all-trans-retinoic acid. *Br J Haematol* 2003; **122**: 688-689 [PMID: [12899728](#) DOI: [10.1046/j.1365-2141.2003.04490.x](#)]
 - 18 **Piñán MA**, Ardanaz MT, Guinea JM, García-Ruiz JC. Myeloid sarcoma preceding an acute promyelocytic leukaemia with neuromeningeal infiltration. *Ann Hematol* 2014; **93**: 339-340 [PMID: [23716188](#) DOI: [10.1007/s00277-013-1795-0](#)]
 - 19 **Cornfield D**, Gheith S, Barron L. Promyelocytic sarcoma presenting with spinal cord compression and treated successfully with surgical debulking and the PETHEMA regimen for acute promyelocytic leukemia. *Case Rep Clin Pathol* 2015; **2**: 12-16 [DOI: [10.5430/crcp.v2n3p12](#)]
 - 20 **Shah NN**, Stonecypher M, Gopal P, Luger S, Bagg A, Perl A. Acute promyelocytic leukemia presenting as a paraspinal mass. *J Community Support Oncol* 2016; **14**: 126-129 [PMID: [27058871](#) DOI: [10.12788/jcs.0220](#)]
 - 21 **Mori**, Shahram, Laloui, Lamia, Patel, Rushang D, Shen Q, Ahmed Wesam. Sternal Soft Tissue Mass as Initial Presentation in a Case of Acute Promyelocytic Leukemia (APL). *Biol Blood Marrow Transplant* 2017; **23**: S249 [DOI: [10.1016/j.bbmt.2016.12.415](#)]
 - 22 **Zuible A**, Aboud H, Nandi A, Powles R, Treleaven J. Extramedullary disease initially without bone marrow involvement in acute promyelocytic leukaemia. *Clin Lab Haematol* 1989; **11**: 288-289 [PMID: [2591162](#) DOI: [10.1111/j.1365-2257.1989.tb00223.x](#)]
 - 23 **Bittencourt H**, Teixeira Junior AL, Glória AB, Ribeiro AF, Fagundes EM. Acute promyelocytic leukemia presenting as an extradural mass. *Rev Bras Hematol Hemoter* 2011; **33**: 478-480 [PMID: [21638303](#) DOI: [10.1002/hon.994](#)]

- 23049367 DOI: [10.5581/1516-8484.20110126](https://doi.org/10.5581/1516-8484.20110126)]
- 24 **Savranlar A**, Ustündag Y, Ozer T, Bayraktaroglu T, Demircan N, Ozdemir H, Borazan A. A thoracic-epidural granulocytic sarcoma case that was diagnosed preceding the onset of and that recurred co-incidental to acute promyelocytic leukemia, which developed after surgical treatment. *Acta Med Okayama* 2004; **58**: 251-254 [PMID: [15666994](https://pubmed.ncbi.nlm.nih.gov/15666994/) DOI: [10.18926/AMO/32104](https://doi.org/10.18926/AMO/32104)]
 - 25 **Tosi A**, De Paoli A, Fava S, Luoni M, Sironi M, Tocci A, Assi A, Cassi E. Undifferentiated granulocytic sarcoma: a case with epidural onset preceding acute promyelocytic leukemia. *Haematologica* 1995; **80**: 44-46 [PMID: [7758990](https://pubmed.ncbi.nlm.nih.gov/7758990/)]
 - 26 **Belasco JB**, Bryan JH, McMillan CW. Acute promyelocytic leukemia presenting as a pelvic mass. *Med Pediatr Oncol* 1978; **4**: 289-295 [PMID: [281594](https://pubmed.ncbi.nlm.nih.gov/281594/) DOI: [10.1002/mpo.2950040403](https://doi.org/10.1002/mpo.2950040403)]
 - 27 **Bobbio-Pallavicini E**, Cannatelli G, Motta E, Grassi M, Bergamaschi G, Rosso R, Moroni M. Histologic diagnosis and precocious treatment in a case of isolated promyelocytic sarcoma. *Leukemia* 1998; **12**: 2035-2036 [PMID: [9844936](https://pubmed.ncbi.nlm.nih.gov/9844936/) DOI: [10.1038/sj.leu.2401227](https://doi.org/10.1038/sj.leu.2401227)]
 - 28 **Yamashita Y**, Isomura N, Hamasaki Y, Goto M. Case of pediatric acute promyelocytic leukemia presenting as extramedullary tumor of the mandible. *Head Neck* 2013; **35**: E310-E313 [PMID: [22972688](https://pubmed.ncbi.nlm.nih.gov/22972688/) DOI: [10.1002/hed.23163](https://doi.org/10.1002/hed.23163)]
 - 29 **Yamashita T**, Nishijima A, Noguchi Y, Narukawa K, Oshikawa G, Takano H. Acute promyelocytic leukemia presenting as recurrent spinal myeloid sarcomas 3 years before developing leukemia: A case report with review of literature. *Clin Case Rep* 2019; **7**: 316-321 [PMID: [30847197](https://pubmed.ncbi.nlm.nih.gov/30847197/) DOI: [10.1002/ccr3.1991](https://doi.org/10.1002/ccr3.1991)]
 - 30 **Thomas X**, Chelghoum Y. Promyelocytic sarcoma of the sternum: a case report and review of the literature. *Korean J Hematol* 2011; **46**: 52-56 [PMID: [21461306](https://pubmed.ncbi.nlm.nih.gov/21461306/) DOI: [10.5045/kjh.2011.46.1.52](https://doi.org/10.5045/kjh.2011.46.1.52)]
 - 31 **Mohamedbhai S**, Pule M, Conn B, Hopper C, Ramsay A, Khwaja A. Acute promyelocytic leukaemia presenting with a myeloid sarcoma of the tongue. *Br J Haematol* 2008; **141**: 565 [PMID: [18373707](https://pubmed.ncbi.nlm.nih.gov/18373707/) DOI: [10.1111/j.1365-2141.2008.07080.x](https://doi.org/10.1111/j.1365-2141.2008.07080.x)]
 - 32 **Ignacio-Cconchoy FL**, Benites-Zapata VA, Yanac-Avila RL, Vela-Velásquez CT. Myeloid sarcoma of the tongue as a first manifestation of acute promyelocytic leukemia: A case report. *Rep Pract Oncol Radiother* 2020; **25**: 174-177 [PMID: [32021572](https://pubmed.ncbi.nlm.nih.gov/32021572/) DOI: [10.1016/j.rpor.2019.12.026](https://doi.org/10.1016/j.rpor.2019.12.026)]
 - 33 **Uematsu I**, Wataya K, Kato K, Yoshimi H, Kubori S. [Case of acute promyelocytic leukemia with leukemia cutis]. *Naika* 1970; **26**: 357-362 [PMID: [5270916](https://pubmed.ncbi.nlm.nih.gov/5270916/)]
 - 34 **Kubonishi I**, Ohtsuki Y, Machida K, Agatsuma Y, Tokuoka H, Iwata K, Miyoshi I. Granulocytic sarcoma presenting as a mediastinal tumor. Report of a case and cytological and cytochemical studies of tumor cells in vivo and in vitro. *Am J Clin Pathol* 1984; **82**: 730-734 [PMID: [6594928](https://pubmed.ncbi.nlm.nih.gov/6594928/) DOI: [10.1093/ajcp/82.6.730](https://doi.org/10.1093/ajcp/82.6.730)]
 - 35 **Ajarim DS**, Santhosh-Kumar CR, Higgy KE, el Saghir NS, Almomen AK, Shipkey FD. Granulocytic sarcoma of the thymus in acute promyelocytic leukaemia. *Clin Lab Haematol* 1990; **12**: 97-99 [PMID: [2344722](https://pubmed.ncbi.nlm.nih.gov/2344722/) DOI: [10.1111/j.1365-2257.1990.tb01115.x](https://doi.org/10.1111/j.1365-2257.1990.tb01115.x)]
 - 36 **Gopal S**, Marcussen S, Dobin SM, Koss W, Donner LR. Primary myeloid sarcoma of the testicle with t(15;17). *Cancer Genet Cytogenet* 2005; **157**: 148-150 [PMID: [15721636](https://pubmed.ncbi.nlm.nih.gov/15721636/) DOI: [10.1016/j.cancergencyto.2004.06.010](https://doi.org/10.1016/j.cancergencyto.2004.06.010)]
 - 37 **Fukushima S**, Terasaki M, Tajima Y, Shigemori M. Granulocytic sarcoma: an unusual complication of acute promyelocytic leukemia causing cerebellar hemorrhage. Case report. *J Neurosurg* 2006; **105**: 912-915 [PMID: [17405265](https://pubmed.ncbi.nlm.nih.gov/17405265/) DOI: [10.3171/jns.2006.105.6.912](https://doi.org/10.3171/jns.2006.105.6.912)]
 - 38 **Wang X**, Liu H, Wu Z, Xu X, Chen X, Zhai Z, Sun Z. A case of acute promyelocytic leukemia presenting with a nonleukemic granulocytic sarcoma of the ovary, with subsequent development of acute myeloid leukemia associated with t(8;21). *Leuk Res* 2009; **33**: 580-582 [PMID: [18804280](https://pubmed.ncbi.nlm.nih.gov/18804280/) DOI: [10.1016/j.leukres.2008.08.008](https://doi.org/10.1016/j.leukres.2008.08.008)]
 - 39 **Benjazia E**, Khalifa M, Benabdelkader A, Laatiri A, Braham A, Letaief A, Bahri F. Granulocytic sarcoma of the rectum: Report of one case that presented with rectal bleeding. *World J Gastrointest Pathophysiol* 2010; **1**: 144-146 [PMID: [21607155](https://pubmed.ncbi.nlm.nih.gov/21607155/) DOI: [10.4291/wjgp.v1.i4.144](https://doi.org/10.4291/wjgp.v1.i4.144)]
 - 40 **Takeh H**, Farran M, Debaize JP. Granulocytic sarcoma (chloroma) of the small intestine. *Acta Chir Belg* 1999; **99**: 78-81 [PMID: [10352737](https://pubmed.ncbi.nlm.nih.gov/10352737/)]
 - 41 **Damodar S**, Prashantha B, Gangoli A, Gopalakrishnan G, Jayanthi KJ. Granulocytic sarcoma of colon in a patient with acute promyelocytic leukemia. *Indian J Hematol Blood Transfus* 2013; **29**: 152-154 [PMID: [24426361](https://pubmed.ncbi.nlm.nih.gov/24426361/) DOI: [10.1007/s12288-012-0152-0](https://doi.org/10.1007/s12288-012-0152-0)]



Published by **Baishideng Publishing Group Inc**
7041 Koll Center Parkway, Suite 160, Pleasanton, CA 94566, USA

Telephone: +1-925-3991568

E-mail: bpgoffice@wjgnet.com

Help Desk: <https://www.f6publishing.com/helpdesk>

<https://www.wjgnet.com>

