

# World Journal of *Clinical Cases*

*World J Clin Cases* 2021 August 6; 9(22): 6178-6581



## Contents

Thrice Monthly Volume 9 Number 22 August 6, 2021

## REVIEW

- 6178** COVID-19 infection and liver injury: Clinical features, biomarkers, potential mechanisms, treatment, and management challenges

*Sivandzadeh GR, Askari H, Safarpour AR, Ejtehad F, Raeis-Abdollahi E, Vaez Lari A, Abazari MF, Tarkesh F, Bagheri Lankarani K*

- 6201** Gastrointestinal manifestations of systemic sclerosis: An updated review

*Luquez-Mindiola A, Atuesta AJ, Gómez-Aldana AJ*

## MINIREVIEWS

- 6218** Mesenchymal stem cell-derived exosomes: An emerging therapeutic strategy for normal and chronic wound healing

*Zeng QL, Liu DW*

- 6234** Role of autophagy in cholangiocarcinoma: Pathophysiology and implications for therapy

*Ninfolle E, Pinto C, Benedetti A, Marziani M, Maroni L*

## ORIGINAL ARTICLE

## Case Control Study

- 6244** Risk factors for intussusception in children with Henoch-Schönlein purpura: A case-control study

*Zhao Q, Yang Y, He SW, Wang XT, Liu C*

## Retrospective Study

- 6254** Sequential therapy with combined trans-papillary endoscopic naso-pancreatic and endoscopic retrograde pancreatic drainage for pancreatic pseudocysts

*He YG, Li J, Peng XH, Wu J, Xie MX, Tang YC, Zheng L, Huang XB*

- 6268** Retrospective study of effect of whole-body vibration training on balance and walking function in stroke patients

*Xie L, Yi SX, Peng QF, Liu P, Jiang H*

- 6278** Risk factors for preoperative carcinogenesis of bile duct cysts in adults

*Wu X, Li BL, Zheng CJ, He XD*

- 6287** Diagnostic and prognostic value of secreted protein acidic and rich in cysteine in the diffuse large B-cell lymphoma

*Pan PJ, Liu JX*

- 6300** Jumbo cup in hip joint renovation may cause the center of rotation to increase

*Peng YW, Shen JM, Zhang YC, Sun JY, Du YQ, Zhou YG*

**Clinical Trials Study**

- 6308** Effect of exercise training on left ventricular remodeling in patients with myocardial infarction and possible mechanisms  
*Cai M, Wang L, Ren YL*

**Observational Study**

- 6319** Analysis of sleep characteristics and clinical outcomes of 139 adult patients with infective endocarditis after surgery  
*Hu XM, Lin CD, Huang DY, Li XM, Lu F, Wei WT, Yu ZH, Liao HS, Huang F, Huang XZ, Jia FJ*
- 6329** Health-related risky behaviors and their risk factors in adolescents with high-functioning autism  
*Sun YJ, Xu LZ, Ma ZH, Yang YL, Yin TN, Gong XY, Gao ZL, Liu YL, Liu J*
- 6343** Selection of internal fixation method for femoral intertrochanteric fractures using a finite element method  
*Mu JX, Xiang SY, Ma QY, Gu HL*

**META-ANALYSIS**

- 6357** Neoadjuvant chemotherapy for patients with resectable colorectal cancer liver metastases: A systematic review and meta-analysis  
*Zhang Y, Ge L, Weng J, Tuo WY, Liu B, Ma SX, Yang KH, Cai H*

**CASE REPORT**

- 6380** Ruptured intracranial aneurysm presenting as cerebral circulation insufficiency: A case report  
*Zhao L, Zhao SQ, Tang XP*
- 6388** Prostatic carcinosarcoma seven years after radical prostatectomy and hormonal therapy for prostatic adenocarcinoma: A case report  
*Huang X, Cai SL, Xie LP*
- 6393** Pyogenic arthritis, pyoderma gangrenosum, and acne syndrome in a Chinese family: A case report and review of literature  
*Lu LY, Tang XY, Luo GJ, Tang MJ, Liu Y, Yu XJ*
- 6403** Malaria-associated secondary hemophagocytic lymphohistiocytosis: A case report  
*Zhou X, Duan ML*
- 6410** Ileal hemorrhagic infarction after carotid artery stenting: A case report and review of the literature  
*Xu XY, Shen W, Li G, Wang XF, Xu Y*
- 6418** Inflammatory myofibroblastic tumor of the pancreatic neck: A case report and review of literature  
*Chen ZT, Lin YX, Li MX, Zhang T, Wan DL, Lin SZ*
- 6428** Management of heterotopic cesarean scar pregnancy with preservation of intrauterine pregnancy: A case report  
*Chen ZY, Zhou Y, Qian Y, Luo JM, Huang XF, Zhang XM*

- 6435** Manifestation of severe pneumonia in anti-PL-7 antisynthetase syndrome and B cell lymphoma: A case report  
*Xu XL, Zhang RH, Wang YH, Zhou JY*
- 6443** Disseminated infection by *Fusarium solani* in acute lymphocytic leukemia: A case report  
*Yao YF, Feng J, Liu J, Chen CF, Yu B, Hu XP*
- 6450** Primary hepatic neuroendocrine tumor – <sup>18</sup>F-fluorodeoxyglucose positron emission tomography/computed tomography findings: A case report  
*Rao YY, Zhang HJ, Wang XJ, Li MF*
- 6457** Malignant peripheral nerve sheath tumor in an elderly patient with superficial spreading melanoma: A case report  
*Yang CM, Li JM, Wang R, Lu LG*
- 6464** False positive anti-hepatitis A virus immunoglobulin M in autoimmune hepatitis/primary biliary cholangitis overlap syndrome: A case report  
*Yan J, He YS, Song Y, Chen XY, Liu HB, Rao CY*
- 6469** Successful totally laparoscopic right trihepatectomy following conversion therapy for hepatocellular carcinoma: A case report  
*Zhang JJ, Wang ZX, Niu JX, Zhang M, An N, Li PF, Zheng WH*
- 6478** Primary small cell esophageal carcinoma, chemotherapy sequential immunotherapy: A case report  
*Wu YH, Zhang K, Chen HG, Wu WB, Li XJ, Zhang J*
- 6485** Subdural fluid collection rather than meningitis contributes to hydrocephalus after cervical laminoplasty: A case report  
*Huang HH, Cheng ZH, Ding BZ, Zhao J, Zhao CQ*
- 6493** Phlegmonous gastritis developed during chemotherapy for acute lymphocytic leukemia: A case report  
*Saito M, Morioka M, Izumiyama K, Mori A, Ogasawara R, Kondo T, Miyajima T, Yokoyama E, Tanikawa S*
- 6501** Spinal epidural hematoma after spinal manipulation therapy: Report of three cases and a literature review  
*Liu H, Zhang T, Qu T, Yang CW, Li SK*
- 6510** Abdominal hemorrhage after peritoneal dialysis catheter insertion: A rare cause of luteal rupture: A case report  
*Gan LW, Li QC, Yu ZL, Zhang LL, Liu Q, Li Y, Ou ST*
- 6515** Concealed mesenteric ischemia after total knee arthroplasty: A case report  
*Zhang SY, He BJ, Xu HH, Xiao MM, Zhang JJ, Tong PJ, Mao Q*
- 6522** Chylothorax following posterior low lumbar fusion surgery: A case report  
*Huang XM, Luo M, Ran LY, You XH, Wu DW, Huang SS, Gong Q*
- 6531** Non-immune hydrops fetalis: Two case reports  
*Maranto M, Cigna V, Orlandi E, Cucinella G, Lo Verso C, Duca V, Picciotto F*

- 6538** Bystander effect and abscopal effect in recurrent thymic carcinoma treated with carbon-ion radiation therapy: A case report  
*Zhang YS, Zhang YH, Li XJ, Hu TC, Chen WZ, Pan X, Chai HY, Ye YC*
- 6544** Management of an intracranial hypotension patient with diplopia as the primary symptom: A case report  
*Wei TT, Huang H, Chen G, He FF*
- 6552** Spontaneous rupture of adrenal myelolipoma as a cause of acute flank pain: A case report  
*Kim DS, Lee JW, Lee SH*
- 6557** Neonatal necrotizing enterocolitis caused by umbilical arterial catheter-associated abdominal aortic embolism: A case report  
*Huang X, Hu YL, Zhao Y, Chen Q, Li YX*
- 6566** Primary mucosa-associated lymphoid tissue lymphoma in the midbrain: A case report  
*Zhao YR, Hu RH, Wu R, Xu JK*
- 6575** Extensive cutaneous metastasis of recurrent gastric cancer: A case report  
*Chen JW, Zheng LZ, Xu DH, Lin W*

**ABOUT COVER**

Editorial Board Member of *World Journal of Clinical Cases*, Salma Ahi, MD, Assistant Professor, Research Center for Noncommunicable Diseases, Jahrom University of Medical Sciences, Jahrom 193, Iran. salmaahi.61@gmail.com

**AIMS AND SCOPE**

The primary aim of *World Journal of Clinical Cases* (WJCC, *World J Clin Cases*) is to provide scholars and readers from various fields of clinical medicine with a platform to publish high-quality clinical research articles and communicate their research findings online.

WJCC mainly publishes articles reporting research results and findings obtained in the field of clinical medicine and covering a wide range of topics, including case control studies, retrospective cohort studies, retrospective studies, clinical trials studies, observational studies, prospective studies, randomized controlled trials, randomized clinical trials, systematic reviews, meta-analysis, and case reports.

**INDEXING/ABSTRACTING**

The WJCC is now indexed in Science Citation Index Expanded (also known as SciSearch®), Journal Citation Reports/Science Edition, Scopus, PubMed, and PubMed Central. The 2021 Edition of Journal Citation Reports® cites the 2020 impact factor (IF) for WJCC as 1.337; IF without journal self cites: 1.301; 5-year IF: 1.742; Journal Citation Indicator: 0.33; Ranking: 119 among 169 journals in medicine, general and internal; and Quartile category: Q3. The WJCC's CiteScore for 2020 is 0.8 and Scopus CiteScore rank 2020: General Medicine is 493/793.

**RESPONSIBLE EDITORS FOR THIS ISSUE**

**Production Editor:** Yan-Xia Xing; **Production Department Director:** Yun-Jie Ma; **Editorial Office Director:** Jin-Lei Wang.

**NAME OF JOURNAL**

*World Journal of Clinical Cases*

**ISSN**

ISSN 2307-8960 (online)

**LAUNCH DATE**

April 16, 2013

**FREQUENCY**

Thrice Monthly

**EDITORS-IN-CHIEF**

Dennis A Bloomfield, Sandro Vento, Bao-Gan Peng

**EDITORIAL BOARD MEMBERS**

<https://www.wjgnet.com/2307-8960/editorialboard.htm>

**PUBLICATION DATE**

August 6, 2021

**COPYRIGHT**

© 2021 Baishideng Publishing Group Inc

**INSTRUCTIONS TO AUTHORS**

<https://www.wjgnet.com/bpg/gerinfo/204>

**GUIDELINES FOR ETHICS DOCUMENTS**

<https://www.wjgnet.com/bpg/GerInfo/287>

**GUIDELINES FOR NON-NATIVE SPEAKERS OF ENGLISH**

<https://www.wjgnet.com/bpg/gerinfo/240>

**PUBLICATION ETHICS**

<https://www.wjgnet.com/bpg/GerInfo/288>

**PUBLICATION MISCONDUCT**

<https://www.wjgnet.com/bpg/gerinfo/208>

**ARTICLE PROCESSING CHARGE**

<https://www.wjgnet.com/bpg/gerinfo/242>

**STEPS FOR SUBMITTING MANUSCRIPTS**

<https://www.wjgnet.com/bpg/GerInfo/239>

**ONLINE SUBMISSION**

<https://www.f6publishing.com>

## Retrospective Study

## Jumbo cup in hip joint renovation may cause the center of rotation to increase

Ya-Wen Peng, Jun-Min Shen, Yan-Chao Zhang, Jing-Yang Sun, Yin-Qiao Du, Yong-Gang Zhou

**ORCID number:** Ya-Wen Peng 0000-0002-5485-1201; Jun-Min Shen 0000-0001-5052-1363; Yan-Chao Zhang 0000-0003-2136-8544; Jing-Yang Sun 0000-0002-9370-8213; Yin-Qiao Du 0000-0002-7460-4101; Yong-Gang Zhou 0000-0002-7304-4691.

**Author contributions:** Peng YW and Shen JM design the experiment; Zhang YC drafted the work, Sun JY, Du YQ and Zhou YG collected the data; Peng YW and Shen JM analyzed and interpreted data, Peng YW, Shen JM and Zhang YC wrote the article.

**Institutional review board**

**statement:** The study was reviewed and approved by the Chinese People's Liberation Army General Hospital Institutional Review Board.

**Informed consent statement:** All study participants, or their legal guardian, provided informed written consent prior to study enrollment.

**Conflict-of-interest statement:** The authors declare that there is no conflict of interest.

**Data sharing statement:** No additional data are available.

**Open-Access:** This article is an open-access article that was

Ya-Wen Peng, Jun-Min Shen, Yan-Chao Zhang, Jing-Yang Sun, Yin-Qiao Du, Yong-Gang Zhou, Department of Orthopedics, The First Medical Centre, Chinese People's Liberation Army General Hospital, Beijing 100853, China

**Corresponding author:** Yong-Gang Zhou, MD, PhD, Doctor, Department of Orthopedics, The First Medical Centre, Chinese People's Liberation Army General Hospital, No. 28 Fuxing Road, Haidian District, Beijing 100853, China. [ygzhou301@163.com](mailto:ygzhou301@163.com)

## Abstract

## BACKGROUND

Utilizing the large jumbo cup in revision total hip arthroplasty is an effective approach to cure many lacunar and segmental peripheral bone defects. However, with the use of the jumbo cup, the center of the hip joint may become elevated relative to the primary acetabulum, and the diameter of the large cup is greater.

## AIM

To study the height and the significance of the elevation of the hip joint center.

## METHODS

Eighty-eight patients matched the criteria for this condition and were included in the study. The center height of the hip joint was measured relative to the opposite normal hip joint. The diameter of the jumbo cup was measured and checked according to operation notes, and the diameter of the jumbo cup was measured with a prosthesis label. Then, the horizontal and vertical centers of rotation were measured on the surgical side and opposite side. The average center height of the hip joint on the renovated side and the opposite side and the position of the hip cup relative to the teardrop were compared using a paired *t*-test.

## RESULTS

Radiometric analysis showed that the average hip joint center was elevated by 7.6 mm. The rotational center height delta of the renovated hip was  $7.6 \pm 5.6$  mm, and there was an obvious difference between the two groups ( $P = 0.00$ ). The difference in horizontal distance was  $0.5 \pm 5.1$  mm ( $-11.5$  - $14.0$  mm), and there was no obvious difference between the two groups ( $P = 0.38$ ). According to the foreign standard, the rotational center height delta of the renovated hip was  $7.5 \pm 6.2$  mm, and there was a significant difference between the two groups ( $P = 0.00$ ). There was no obvious difference between the domestic and foreign standards ( $P > 0.05$ ) between the two groups.



selected by an in-house editor and fully peer-reviewed by external reviewers. It is distributed in accordance with the Creative Commons Attribution NonCommercial (CC BY-NC 4.0) license, which permits others to distribute, remix, adapt, build upon this work non-commercially, and license their derivative works on different terms, provided the original work is properly cited and the use is non-commercial. See: <http://creativecommons.org/licenses/by-nc/4.0/>

**Manuscript source:** Unsolicited manuscript

**Specialty type:** Orthopedics

**Country/Territory of origin:** China

**Peer-review report's scientific quality classification**

Grade A (Excellent): 0  
Grade B (Very good): 0  
Grade C (Good): C  
Grade D (Fair): 0  
Grade E (Poor): 0

**Received:** May 15, 2021

**Peer-review started:** May 15, 2021

**First decision:** May 23, 2021

**Revised:** May 24, 2021

**Accepted:** May 27, 2021

**Article in press:** May 27, 2021

**Published online:** August 6, 2021

**P-Reviewer:** Goudeau YR

**S-Editor:** Wang JL

**L-Editor:** Filipodia

**P-Editor:** Yuan YY



## CONCLUSION

The application of the jumbo cup elevates the rotational center of the hip joint, but it is feasible and effective to use the jumbo cup.

**Key Words:** Hip revision surgery; Jumbo cup; Center of rotation; Hip joint renovation; Hip joint

©The Author(s) 2021. Published by Baishideng Publishing Group Inc. All rights reserved.

**Core Tip:** In this study, we discuss the application of the jumbo cup *via* observing how high the elevation of the center of the hip joint is and its significance in imaging X-rays, and came to the conclusion: The application of the jumbo cup elevates the rotational center of the hip joint, but it is feasible and effective to use the jumbo cup.

**Citation:** Peng YW, Shen JM, Zhang YC, Sun JY, Du YQ, Zhou YG. Jumbo cup in hip joint renovation may cause the center of rotation to increase. *World J Clin Cases* 2021; 9(22): 6300-6307

**URL:** <https://www.wjgnet.com/2307-8960/full/v9/i22/6300.htm>

**DOI:** <https://dx.doi.org/10.12998/wjcc.v9.i22.6300>

## INTRODUCTION

Boneless, cement-coated, giant cups (jumbo cups) and bolt-fixed revision total hip arthroplasty (THA) are valid technologies for curing most failed acetabular components with cavities or subtle segmental bone defects[1-3]. In revision THA, giant, hemispheric, boneless concrete acetabular cups (jumbo cups) generally have excellent outcomes in durability and versatility in dealing with cavities or subtle segmental bone defects[1-3]. Compared with other acetabulum renovations, there are several advantages to the use of jumbo cups. First, they offer a large contact area between the principal bone and the surface of porous implants, which is good for reliable biological fixation[4]. Moreover, this method can utilize hemispheric surgical techniques.

Reamer and screw fixation are similar applications in initial THA. However, many bone defects we often confront can be filled by transplanting large acetabular cups and spongy bone, and we sometimes do not need large amounts of allogeneic bone transplantation and reinforcer. A giant cup (jumbo cup) provides a substitute method for filling bone defects and acetabular cavities, which involves the placing of a cup to fill defects in the acetabulum (high hip center) or using a hunch in the anatomical acetabulum[5].

However, to suit implants that are usually larger than the primary acetabulum, the jumbo cup technique requires reaming and preparation of the surface of the acetabulum. Compared with the primary acetabulum, the diameter of the jumbo cup is greater, which may cause elevation of the center of the hip joint. This issue is related to changes in hip biomechanics and hip instability[6-8].

Leg length discrepancy is not uncommon after revision THA. However, unlike primary THA, limb shortening is more common than lengthening during revision THA, which can be related to cup positioning[9].

In the present study, there is clinical verification of the computer simulation research. We discuss the application of the jumbo cup through observations based on the height of the elevation of the center of the hip joint and its significance (about limb shortening or not) in imaging X-rays.

## MATERIALS AND METHODS

### General information

**Inclusion criteria:** One hip joint was normal, another underwent revision hip arthroplasty, and the diameter of the jumbo cup was no less than 64 mm in males and 60 mm



in females and had no heel or reinforcer.

**Exclusion criteria:** (1) The diameter of the jumbo cup was less than 64 mm in males and 60 mm in females; (2) The other hip joint had abnormalities, such as avascular necrosis, or integration; (3) Revision of total hip arthroplasty; (4) The use of a heel or reinforcer; and (5) A jumbo cup was placed with a high center of rotation on the renovated side.

**Eighty-eight patients met the study criteria:** 44 were males and 44 were females. The average age was  $61 \pm 11$  years (range from 32-85 years), the average height was  $165.1 \pm 7.8$  cm (range from 146-182 cm), and the average weight was  $70.8 \pm 13.5$  kg (range from 43 -100 kg). We analyzed the images with Medcare software to measure the height and horizontal distance of the bilateral hip joint rotational center, including the abduction angle by utilizing this software.

### Materials used

Prostheses were mainly from Pinnacle, with Gription Acetabular Cups from DePuy Orthopedics, Inc., acetabular cups from Zimmer Inc., America, and Cementless Hip Prostheses (CombiCups PF and TOPII) from Waldemar Link.

### Measurement methods

All imaging measurements were performed by one experimenter. All imaging was conducted 1 wk after the operation (Figure 1), and measurements were taken with orthotopic X-ray of the pelvis using MedCare software. The main results were compared with those of the opposite side hip joint to assess vertical and horizontal differences between the hip joint centers. To identify the location of the rotational center, we drew a circle in the jumbo and opposite side hip joints, and these circles were aligned with the edge of the acetabulum. The center of this circle was assumed to be the hip joint center (Figure 2). The center height of the hip joint was estimated by measuring the height of the vertical line from the lower edge of the acetabular tear to the center of the hip joint. We could carry out measurements in the hip joint of the jumbo cup side and opposite side, and the difference in the vertical position of the center of the two hips was seen as the measurement of the upward movement of the center of the hip at the jumbo cup side. The lower edge of the acetabular teardrop was used as a reference point for measurement in that teardrop as an independent anatomical structure whose vertical position is not substantially affected by the rotation of the pelvis.

### Data reconciliation

To determine how much of the vertical change in the center of the revision hip was due to the placement of the prosthesis above the teardrop line, the straight-line distance from the jumbo cup to the teardrop line was measured (Figure 3). This was deemed the elevation of the center of the hip joint for the placement of the cup above the site originally planned. If the lower lip of the giant cup was under the teardrop line, then the cup was given a negative number. Since the position of the lower edge of the cup body is also affected by the abduction angle, the normal position of the cup should be at a 45° abduction angle.

The diameter of the jumbo cup was measured and checked according to the operation notes and using a prosthesis label. Then, the horizontal and vertical centers of rotation (H-COR and V-COR) were measured on the surgical side and opposite side. The average center height of the hip joint on the renovated side and the opposite side and the position of the hip cup relative to the teardrop were compared using a paired *t*-test.

## RESULTS

The X-ray imaging analysis showed that our jumbo cup technique elevated the center of the hip joint. The average hip joint rotational center height of the jumbo cup was  $23.0 \pm 6.1$  mm (males = 22.1 mm, females = 24.0 mm). The average hip joint opposite side rotational center height was  $15.4 \pm 3.4$  mm (males = 15.3 mm, females = 15.5 mm). This approach produced an average hip joint rotational center height difference of 7.6 mm. The horizontal distance of the jumbo cup was  $36.4 \pm 4.6$  mm (25.3-48.6 mm). The horizontal distance on the opposite side was  $35.9 \pm 4.4$  mm (28.0-47.6 mm). The difference in horizontal distance in the renovated hip joint was  $0.5 \pm 5.1$  mm (-11.5-14.0

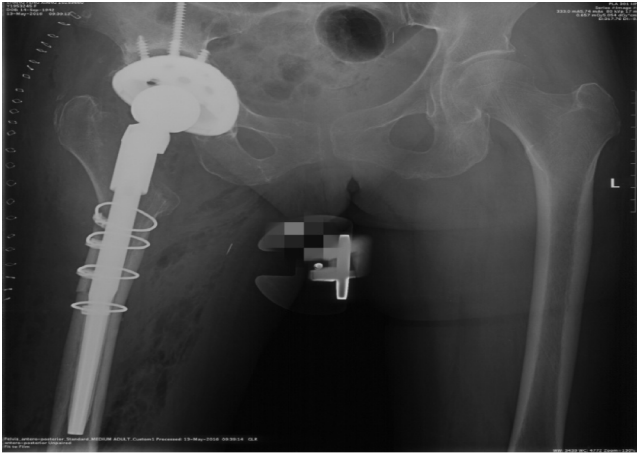


Figure 1 Postoperative reexamination of jumbo cup.

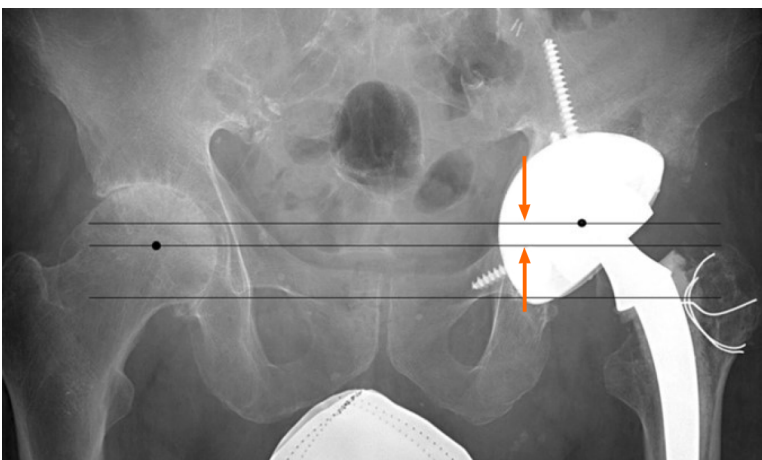


Figure 2 The center of this circle was assumed to be the hip joint center[11]. After the left revision total hip arthroplasty obtained anteroposterior pelvic radiographs with a giant cup showed that the revision cup was larger than the contralateral acetabulum. The teardrop line intersects the lower edge of the cup, indicating that jumbo cup is placed in planned position that the lower edge of cup at the lower edge of acetabulum. The medium line is parallel to the lower edge of teardrop line and intersects center of right hip. The upper end line parallel to the tear drop line intersects center of the left giant cup. The distance (arrows) between two lines is labeled as elevated height of rotating center occurred in applying jumbo cup.

mm). The average abduction angle of the horizontal distance in the renovated hip joint was  $40.6^\circ \pm 6.9^\circ$  ( $28.1^\circ$ - $63.0^\circ$ , Table 1).

The results of the paired *t* test showed that the height difference of the rotational center of renovated hip joints was  $7.6 \pm 5.6$  mm, and that there was an obvious difference between the two groups ( $P = 0.00$ ); however, the difference in horizontal distance was  $0.5 \pm 5.1$  mm ( $-11.5$ - $14.0$  mm), and there was no obvious difference between the two groups ( $P = 0.38$ , Table 2).

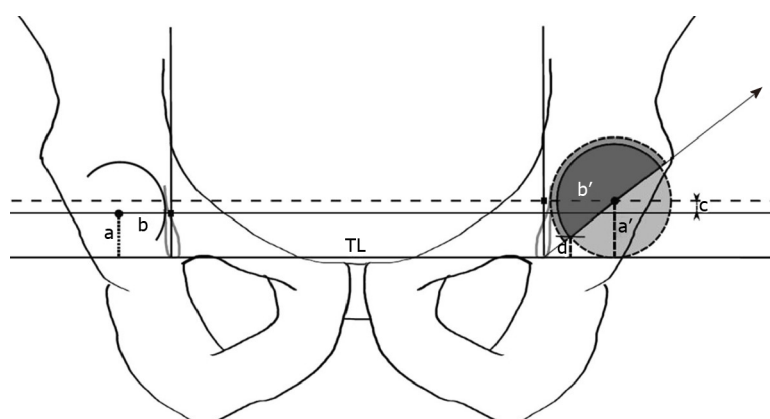
According to European and American definitions of the jumbo cup criteria, we performed the statistical analysis again for patients who met the criteria, which resulted in a total of 88 patients (88 hips) in this study; a total of 54 patients (54 cases; 25 males and 29 females) met the criteria for reanalysis. The average hip joint rotational center height of the jumbo cup was  $23.2 \pm 6.6$  mm (males = 21.0 mm, females = 25.0 mm). The average hip joint rotational center height of the opposite side was  $15.7 \pm 3.4$  mm (males = 15.7 mm, females = 15.7 mm). The results of this analysis showed an average hip joint rotational center height difference, and we found that the difference between the two groups was  $7.5 \pm 6.2$  mm ( $-6.6$ - $19.5$  mm). The horizontal distance of the jumbo cup was  $36.8 \pm 4.5$  mm ( $26.4$ - $48.6$  mm), and the horizontal distance on the opposite side was  $36.0 \pm 4.0$  mm ( $28.1$ - $46.3$  mm). The difference in horizontal distance in the renovated hip joint was  $0.8 \pm 5.0$  mm ( $-11.5$ - $13.7$  mm). The average abduction angle of the horizontal distance in the renovated hip joint was  $41.2^\circ \pm 7.0^\circ$  ( $28.1^\circ$ - $61.5^\circ$ ). The height difference in the rotational center of the renovated hip joint was  $7.5 \pm 6.2$  mm, and there was an obvious difference between the two groups (paired *t* test  $P =$

**Table 1 Measured values and mean values**

	Maximum values	Minimum values	Mean values
Diameter of acetabular cup (mm)	60.00	72.00	65.0000
Height of rotating center (mm)	5.60	39.80	23.0273
Height of contralateral rotating center (mm)	5.60	24.70	15.4011
Differences (mm)	-6.60	19.50	7.6261
Horizontal distance of jumbo cup (mm)	25.30	48.60	36.4398
Contralateral horizontal distance (mm)	28.00	47.60	35.9398
Differences (mm)	-11.50	14.00	0.5000
Abduction angle (°)	28.10	63.00	40.6011

**Table 2 Significant difference of rotating center in revision hip**

	Mean values	SD	t	Degree of freedom	Significance (two tail)
Differences of vertical height	7.62614	5.58741	12.804	87	0.000
Differences of horizontal height	0.50000	5.07586	0.924	87	0.358



**Figure 3** The X-ray photogrammetry used to determine relative center elevation and upper cup position of the hip joint is shown[11]. TL: Teardrop line; a': Center height of hip joint of jumbo cup; a: Center height of hip joint offside; b': Horizontal distance between teardrop and teardrop line and center line of jumbo cup hip; b: Horizontal distance between vertical line crossed teardrop and center of contralateral hip joint; c: The amount of elevation of center of hip joint (a'-a); d: The amount of elevation of center of hip joint due to the upper acetabular cup.

0.00); however, the difference in horizontal distance was  $0.8 \pm 5.0$  mm (-11.5-13.7 mm), and there was no obvious difference between the two groups ( $P = 0.26$ , Table 3).

There were no significant differences between the domestic and foreign standards (Table 4).

## DISCUSSION

Compared with other methods of acetabulum renovation, there are many advantages in applying the jumbo cup such as a large contact area between the principal bone and the surface of porous implants, which is good for reliable biological fixation. The jumbo cup also permits relatively direct and repeatable hemispheric surgical techniques with reaming and screw fixation at the same time. However, to suit hemispheric implants that are usually larger than the primary acetabulum, the jumbo cup technique requires preparation of the surface of the acetabulum, which may cause elevation of the center of the hip joint. The secondary cause is reaming in a dominant direction and placing the cup body above its intended position and/or causing the cup radius to increase geometrically. The diameter of jumbo cup is larger than that of the

**Table 3 Significant analysis of foreign standard groups**

	Mean values	SD	t	Degree of freedom	Significance (two tail)
Differences of vertical height	7.50926	6.24353	8.838	53	0.000
Differences of horizontal height	0.76667	4.96030	1.136	53	0.261

**Table 4 Comparison of domestic and foreign standards**

	The test of variance equivalence		Mean isotropic t-test		
	F	Significance	t	Degree of freedom	Significance (two tail)
Differences of height					
Assumed equivariance	988	0.322	0.116	140	0.908
No assumed equivariance			0.113	102.772	0.911
Differences of horizon					
Assumed equivariance	0	0.997	-0.307	140	0.76
No assumed equivariance			-0.308	114.256	0.758

primary acetabulum. Reaming in an upward direction may lead to the cup body being over the anatomical acetabulum, which causes elevation of the center of the hip joint. Moreover, using a large acetabular cup may cause elevation of the center of the hip joint due to the larger radius of the jumbo cup.

A vertical hip center shift during revision THA may result in leg length discrepancies, altered hip biomechanics, and soft tissue laxity. A retrospective study involving 79 THA revisions by Dou *et al*[9] showed that acetabular cup placement contributes to hip center elevation and leg length discrepancies after revision THA. In addition to its role in leg length changes, an elevated hip center can result in suboptimum biomechanics of the hip. Delp *et al*[8] showed that superolateral placement of the hip center (2 cm superior and 2 cm lateral) decreases the moment arms of the hip abductors by an average of 28%, thus reducing force-generating capacity. Lachiewicz *et al*[10] reported a dislocation rate of 10% after jumbo cup revision THA, which was the most common complication observed in their series. Hip center elevation in jumbo cup revision THA, as we observed, may be one of several factors that contribute to soft tissue laxity and hip instability. To compensate for an elevated hip center, appropriate adjustments on the femoral side can be made to increase leg length and/or offset.

Despite the elevation of the rotational center of the hip joint, it was not sufficient to match the definition of a high rotational center, the elevation was a minimal. Although Nwankwo *et al*[11] and others found that the average rotational center rose 11 mm in their study, the rise in the average rotational center was only 7.5 mm in our study. These values represent excellent outcomes in numerous research reports regarding the placement of jumbo cups with high rotational centers in treating lateral acetabular defects[12-15]. Kelley[16]'s study of 23 jumbo cups placed with a high rotational center did not show loosening at an average of 35 mo of follow-up. In the longer series reported by Dearborn *et al*[17], there was only a 6% rate of mechanical loosening with a mean follow-up of 10.4 years. Utilizing a high center of the hip joint has a negative influence on the function of the abductor muscles, and differences in mean limb length were reduced after femoral reconstruction. This finding suggests that increasing the length of the femoral head may help to avoid limb shortening when using jumbo cup technology in revision THA. Some authors have reported encouraging clinical results with jumbo cups[10,18-21].

There are some limitations in our research design. There were deviations in the measurements from radiographic plain films. Measurements were made from specific anatomical marks used by an observer in every patient to reduce measurement errors. However, we were unable to identify accurately the reliability of the measurement techniques because there were no repeatability tests of intra-observer and inter-observer variability included in the study. We also did not utilize an established taxonomy to quantify acetabular lesions in this series of patients.

## CONCLUSION

Based on our findings, we suggest that applying a jumbo cup in revision THA increases the height of the rotational center of the hip joint, but it is feasible and effective to utilize jumbo cups in revision THA with a limited height.

## ARTICLE HIGHLIGHTS

### Research background

Utilizing the large jumbo cup in revision total hip arthroplasty (THA) is an effective approach to cure many lacunar and segmental peripheral bone defects. However, with the use of the jumbo cup, the center of the hip joint may become elevated relative to the primary acetabulum, and the diameter of the large cup is greater.

### Research motivation

In order to explore the height and significance of X-rays used to study the height of the hip joint center, as a guide for clinical work.

### Research objectives

X-rays were applied to study the height and the significance of the elevation of the hip joint center.

### Research methods

Eighty-eight patients were included in the study. The center height of the hip joint was measured relative to the opposite normal hip joint. The diameter of the jumbo cup was measured and checked according to operation notes, and the diameter of the jumbo cup was measured with a prosthesis label.

### Research results

Radiometric analysis showed that the average hip joint center was elevated by 7.6 mm. The rotational center height delta of the renovated hip was  $7.6 \pm 5.6$  mm, and there was an obvious difference between the two groups. For the difference in horizontal distance, there was no obvious difference between the two groups. The rotational center height delta of the renovated hip was  $7.5 \pm 6.2$  mm, and there was a significant difference between the two groups.

### Research conclusions

The application of the jumbo cup elevates the rotational center of the hip joint, but it is feasible and effective to use the jumbo cup.

### Research perspectives

Applying a jumbo cup in revision THA increases the height of the rotational center of the hip joint, but it is feasible and effective to utilize jumbo cups in revision THA with a limited height.

## REFERENCES

- 1 Dearborn JT, Harris WH. Acetabular revision arthroplasty using so-called jumbo cementless components: an average 7-year follow-up study. *J Arthroplasty* 2000; **15**: 8-15 [PMID: 10654456 DOI: 10.1016/s0883-5403(00)90999-9]
- 2 Patel JV, Masonis JL, Bourne RB, Rorabeck CH. The fate of cementless jumbo cups in revision hip arthroplasty. *J Arthroplasty* 2003; **18**: 129-133 [PMID: 12629600 DOI: 10.1054/arth.2003.50038]
- 3 Whaley AL, Berry DJ, Harmsen WS. Extra-large uncemented hemispherical acetabular components for revision total hip arthroplasty. *J Bone Joint Surg Am* 2001; **83**: 1352-1357 [PMID: 11568198 DOI: 10.2106/00004623-200109000-00010]
- 4 Jasty M. Jumbo cups and morsalized graft. *Orthop Clin North Am* 1998; **29**: 249-254 [PMID: 9553570 DOI: 10.1016/s0030-5898(05)70323-0]
- 5 Brooks PJ. The jumbo cup: the 95% solution. *Orthopedics* 2008; **31**: 913, 915 [PMID: 18814612 DOI: 10.3928/01477447-20080901-04]
- 6 Vasavada AN, Delp SL, Maloney WJ, Schurman DJ, Zajac FE. Compensating for changes in muscle length in total hip arthroplasty. Effects on the moment generating capacity of the muscles. *Clin*

- Orthop Relat Res* 1994; 121-133 [PMID: 8168289 DOI: 10.1097/00003086-199405000-00020]
- 7 **Tanzer M.** Role and results of the high hip center. *Orthop Clin North Am* 1998; **29**: 241-247 [PMID: 9553569 DOI: 10.1016/s0030-5898(05)70322-9]
- 8 **Delp SL,** Wixson RL, Komattu AV, Kocmond JH. How superior placement of the joint center in hip arthroplasty affects the abductor muscles. *Clin Orthop Relat Res* 1996; 137-146 [PMID: 8653946 DOI: 10.1097/00003086-199607000-00022]
- 9 **Dou Y,** Zhou Y, Tang Q, Yang D, Liu J. Leg-length discrepancy after revision hip arthroplasty: are modular stems superior? *J Arthroplasty* 2013; **28**: 676-679 [PMID: 23142440 DOI: 10.1016/j.arth.2012.08.009]
- 10 **Lachiewicz PF,** Soileau ES. Fixation, survival, and dislocation of jumbo acetabular components in revision hip arthroplasty. *J Bone Joint Surg Am* 2013; **95**: 543-548 [PMID: 23515989 DOI: 10.2106/JBJS.L.00758]
- 11 **Nwankwo CD,** Ries MD. Do jumbo cups cause hip center elevation in revision THA? *Clin Orthop Relat Res* 2014; **472**: 2793-2798 [PMID: 24744132 DOI: 10.1007/s11999-014-3632-8]
- 12 **Shen J,** Sun J, Ma H, Du Y, Li T, Zhou Y. High Hip Center Technique in Total Hip Arthroplasty for Crowe Type II-III Developmental Dysplasia: Results of Midterm Follow-up. *Orthop Surg* 2020; **12**: 1245-1252 [PMID: 32776482 DOI: 10.1111/os.12756]
- 13 **Montalti M,** Castagnini F, Giardina F, Tassinari E, Biondi F, Toni A. Cementless Total Hip Arthroplasty in Crowe III and IV Dysplasia: High Hip Center and Modular Necks. *J Arthroplasty* 2018; **33**: 1813-1819 [PMID: 29500091 DOI: 10.1016/j.arth.2018.01.041]
- 14 **Galea VP,** Laaksonen I, Donahue GS, Fukui K, Kaneuji A, Malchau H, Bragdon C. Developmental Dysplasia Treated With Cementless Total Hip Arthroplasty Utilizing High Hip Center Reconstruction: A Minimum 13-Year Follow-up Study. *J Arthroplasty* 2018; **33**: 2899-2905 [PMID: 29803578 DOI: 10.1016/j.arth.2018.04.037]
- 15 **Chen M,** Luo ZL, Wu KR, Zhang XQ, Ling XD, Shang XF. Cementless Total Hip Arthroplasty With a High Hip Center for Hartofilakidis Type B Developmental Dysplasia of the Hip: Results of Midterm Follow-Up. *J Arthroplasty* 2016; **31**: 1027-1034 [PMID: 26712347 DOI: 10.1016/j.arth.2015.11.009]
- 16 **Kelley SS.** High hip center in revision arthroplasty. *J Arthroplasty* 1994; **9**: 503-510 [PMID: 7807108 DOI: 10.1016/0883-5403(94)90097-3]
- 17 **Dearborn JT,** Harris WH. High placement of an acetabular component inserted without cement in a revision total hip arthroplasty. Results after a mean of ten years. *J Bone Joint Surg Am* 1999; **81**: 469-480 [PMID: 10225792 DOI: 10.2106/00004623-199904000-00004]
- 18 **Zhang J,** Huang Y, Zhou B, Zhou Y. Mid-Term Follow-Up of Acetabular Revision Arthroplasty Using Jumbo Cups. *Orthop Surg* 2019; **11**: 811-818 [PMID: 31549788 DOI: 10.1111/os.12522]
- 19 **von Roth P,** Abdel MP, Harmsen WS, Berry DJ. Uncemented jumbo cups for revision total hip arthroplasty: a concise follow-up, at a mean of twenty years, of a previous report. *J Bone Joint Surg Am* 2015; **97**: 284-287 [PMID: 25695978 DOI: 10.2106/JBJS.N.00798]
- 20 **Moon JK,** Ryu J, Kim Y, Yang JH, Hwang KT, Kim YH. Acetabular revision arthroplasty using press-fitted jumbo cups: an average 10-year follow-up study. *Arch Orthop Trauma Surg* 2019; **139**: 1149-1160 [PMID: 31187257 DOI: 10.1007/s00402-019-03214-7]
- 21 **Gustke KA,** Levering MF, Miranda MA. Use of jumbo cups for revision of acetabulae with large bony defects. *J Arthroplasty* 2014; **29**: 199-203 [PMID: 23993345 DOI: 10.1016/j.arth.2012.11.010]





Published by **Baishideng Publishing Group Inc**  
7041 Koll Center Parkway, Suite 160, Pleasanton, CA 94566, USA

**Telephone:** +1-925-3991568

**E-mail:** [bpgoffice@wjgnet.com](mailto:bpgoffice@wjgnet.com)

**Help Desk:** <https://www.f6publishing.com/helpdesk>

<https://www.wjgnet.com>

