

World Journal of *Clinical Cases*

World J Clin Cases 2021 August 6; 9(22): 6178-6581



Contents

Thrice Monthly Volume 9 Number 22 August 6, 2021

REVIEW

- 6178** COVID-19 infection and liver injury: Clinical features, biomarkers, potential mechanisms, treatment, and management challenges

Sivandzadeh GR, Askari H, Safarpour AR, Ejtehad F, Raeis-Abdollahi E, Vaez Lari A, Abazari MF, Tarkesh F, Bagheri Lankarani K

- 6201** Gastrointestinal manifestations of systemic sclerosis: An updated review

Luquez-Mindiola A, Atuesta AJ, Gómez-Aldana AJ

MINIREVIEWS

- 6218** Mesenchymal stem cell-derived exosomes: An emerging therapeutic strategy for normal and chronic wound healing

Zeng QL, Liu DW

- 6234** Role of autophagy in cholangiocarcinoma: Pathophysiology and implications for therapy

Ninfolle E, Pinto C, Benedetti A, Marziani M, Maroni L

ORIGINAL ARTICLE

Case Control Study

- 6244** Risk factors for intussusception in children with Henoch-Schönlein purpura: A case-control study

Zhao Q, Yang Y, He SW, Wang XT, Liu C

Retrospective Study

- 6254** Sequential therapy with combined trans-papillary endoscopic naso-pancreatic and endoscopic retrograde pancreatic drainage for pancreatic pseudocysts

He YG, Li J, Peng XH, Wu J, Xie MX, Tang YC, Zheng L, Huang XB

- 6268** Retrospective study of effect of whole-body vibration training on balance and walking function in stroke patients

Xie L, Yi SX, Peng QF, Liu P, Jiang H

- 6278** Risk factors for preoperative carcinogenesis of bile duct cysts in adults

Wu X, Li BL, Zheng CJ, He XD

- 6287** Diagnostic and prognostic value of secreted protein acidic and rich in cysteine in the diffuse large B-cell lymphoma

Pan PJ, Liu JX

- 6300** Jumbo cup in hip joint renovation may cause the center of rotation to increase

Peng YW, Shen JM, Zhang YC, Sun JY, Du YQ, Zhou YG

Clinical Trials Study

- 6308** Effect of exercise training on left ventricular remodeling in patients with myocardial infarction and possible mechanisms
Cai M, Wang L, Ren YL

Observational Study

- 6319** Analysis of sleep characteristics and clinical outcomes of 139 adult patients with infective endocarditis after surgery
Hu XM, Lin CD, Huang DY, Li XM, Lu F, Wei WT, Yu ZH, Liao HS, Huang F, Huang XZ, Jia FJ
- 6329** Health-related risky behaviors and their risk factors in adolescents with high-functioning autism
Sun YJ, Xu LZ, Ma ZH, Yang YL, Yin TN, Gong XY, Gao ZL, Liu YL, Liu J
- 6343** Selection of internal fixation method for femoral intertrochanteric fractures using a finite element method
Mu JX, Xiang SY, Ma QY, Gu HL

META-ANALYSIS

- 6357** Neoadjuvant chemotherapy for patients with resectable colorectal cancer liver metastases: A systematic review and meta-analysis
Zhang Y, Ge L, Weng J, Tuo WY, Liu B, Ma SX, Yang KH, Cai H

CASE REPORT

- 6380** Ruptured intracranial aneurysm presenting as cerebral circulation insufficiency: A case report
Zhao L, Zhao SQ, Tang XP
- 6388** Prostatic carcinosarcoma seven years after radical prostatectomy and hormonal therapy for prostatic adenocarcinoma: A case report
Huang X, Cai SL, Xie LP
- 6393** Pyogenic arthritis, pyoderma gangrenosum, and acne syndrome in a Chinese family: A case report and review of literature
Lu LY, Tang XY, Luo GJ, Tang MJ, Liu Y, Yu XJ
- 6403** Malaria-associated secondary hemophagocytic lymphohistiocytosis: A case report
Zhou X, Duan ML
- 6410** Ileal hemorrhagic infarction after carotid artery stenting: A case report and review of the literature
Xu XY, Shen W, Li G, Wang XF, Xu Y
- 6418** Inflammatory myofibroblastic tumor of the pancreatic neck: A case report and review of literature
Chen ZT, Lin YX, Li MX, Zhang T, Wan DL, Lin SZ
- 6428** Management of heterotopic cesarean scar pregnancy with preservation of intrauterine pregnancy: A case report
Chen ZY, Zhou Y, Qian Y, Luo JM, Huang XF, Zhang XM

- 6435** Manifestation of severe pneumonia in anti-PL-7 antisynthetase syndrome and B cell lymphoma: A case report
Xu XL, Zhang RH, Wang YH, Zhou JY
- 6443** Disseminated infection by *Fusarium solani* in acute lymphocytic leukemia: A case report
Yao YF, Feng J, Liu J, Chen CF, Yu B, Hu XP
- 6450** Primary hepatic neuroendocrine tumor – ¹⁸F-fluorodeoxyglucose positron emission tomography/computed tomography findings: A case report
Rao YY, Zhang HJ, Wang XJ, Li MF
- 6457** Malignant peripheral nerve sheath tumor in an elderly patient with superficial spreading melanoma: A case report
Yang CM, Li JM, Wang R, Lu LG
- 6464** False positive anti-hepatitis A virus immunoglobulin M in autoimmune hepatitis/primary biliary cholangitis overlap syndrome: A case report
Yan J, He YS, Song Y, Chen XY, Liu HB, Rao CY
- 6469** Successful totally laparoscopic right trihepatectomy following conversion therapy for hepatocellular carcinoma: A case report
Zhang JJ, Wang ZX, Niu JX, Zhang M, An N, Li PF, Zheng WH
- 6478** Primary small cell esophageal carcinoma, chemotherapy sequential immunotherapy: A case report
Wu YH, Zhang K, Chen HG, Wu WB, Li XJ, Zhang J
- 6485** Subdural fluid collection rather than meningitis contributes to hydrocephalus after cervical laminoplasty: A case report
Huang HH, Cheng ZH, Ding BZ, Zhao J, Zhao CQ
- 6493** Phlegmonous gastritis developed during chemotherapy for acute lymphocytic leukemia: A case report
Saito M, Morioka M, Izumiyama K, Mori A, Ogasawara R, Kondo T, Miyajima T, Yokoyama E, Tanikawa S
- 6501** Spinal epidural hematoma after spinal manipulation therapy: Report of three cases and a literature review
Liu H, Zhang T, Qu T, Yang CW, Li SK
- 6510** Abdominal hemorrhage after peritoneal dialysis catheter insertion: A rare cause of luteal rupture: A case report
Gan LW, Li QC, Yu ZL, Zhang LL, Liu Q, Li Y, Ou ST
- 6515** Concealed mesenteric ischemia after total knee arthroplasty: A case report
Zhang SY, He BJ, Xu HH, Xiao MM, Zhang JJ, Tong PJ, Mao Q
- 6522** Chylothorax following posterior low lumbar fusion surgery: A case report
Huang XM, Luo M, Ran LY, You XH, Wu DW, Huang SS, Gong Q
- 6531** Non-immune hydrops fetalis: Two case reports
Maranto M, Cigna V, Orlandi E, Cucinella G, Lo Verso C, Duca V, Picciotto F

- 6538** Bystander effect and abscopal effect in recurrent thymic carcinoma treated with carbon-ion radiation therapy: A case report
Zhang YS, Zhang YH, Li XJ, Hu TC, Chen WZ, Pan X, Chai HY, Ye YC
- 6544** Management of an intracranial hypotension patient with diplopia as the primary symptom: A case report
Wei TT, Huang H, Chen G, He FF
- 6552** Spontaneous rupture of adrenal myelolipoma as a cause of acute flank pain: A case report
Kim DS, Lee JW, Lee SH
- 6557** Neonatal necrotizing enterocolitis caused by umbilical arterial catheter-associated abdominal aortic embolism: A case report
Huang X, Hu YL, Zhao Y, Chen Q, Li YX
- 6566** Primary mucosa-associated lymphoid tissue lymphoma in the midbrain: A case report
Zhao YR, Hu RH, Wu R, Xu JK
- 6575** Extensive cutaneous metastasis of recurrent gastric cancer: A case report
Chen JW, Zheng LZ, Xu DH, Lin W

ABOUT COVER

Editorial Board Member of *World Journal of Clinical Cases*, Salma Ahi, MD, Assistant Professor, Research Center for Noncommunicable Diseases, Jahrom University of Medical Sciences, Jahrom 193, Iran. salmaahi.61@gmail.com

AIMS AND SCOPE

The primary aim of *World Journal of Clinical Cases* (WJCC, *World J Clin Cases*) is to provide scholars and readers from various fields of clinical medicine with a platform to publish high-quality clinical research articles and communicate their research findings online.

WJCC mainly publishes articles reporting research results and findings obtained in the field of clinical medicine and covering a wide range of topics, including case control studies, retrospective cohort studies, retrospective studies, clinical trials studies, observational studies, prospective studies, randomized controlled trials, randomized clinical trials, systematic reviews, meta-analysis, and case reports.

INDEXING/ABSTRACTING

The WJCC is now indexed in Science Citation Index Expanded (also known as SciSearch®), Journal Citation Reports/Science Edition, Scopus, PubMed, and PubMed Central. The 2021 Edition of Journal Citation Reports® cites the 2020 impact factor (IF) for WJCC as 1.337; IF without journal self cites: 1.301; 5-year IF: 1.742; Journal Citation Indicator: 0.33; Ranking: 119 among 169 journals in medicine, general and internal; and Quartile category: Q3. The WJCC's CiteScore for 2020 is 0.8 and Scopus CiteScore rank 2020: General Medicine is 493/793.

RESPONSIBLE EDITORS FOR THIS ISSUE

Production Editor: Yan-Xia Xing; **Production Department Director:** Yun-Jie Ma; **Editorial Office Director:** Jin-Lei Wang.

NAME OF JOURNAL

World Journal of Clinical Cases

ISSN

ISSN 2307-8960 (online)

LAUNCH DATE

April 16, 2013

FREQUENCY

Thrice Monthly

EDITORS-IN-CHIEF

Dennis A Bloomfield, Sandro Vento, Bao-Gan Peng

EDITORIAL BOARD MEMBERS

<https://www.wjgnet.com/2307-8960/editorialboard.htm>

PUBLICATION DATE

August 6, 2021

COPYRIGHT

© 2021 Baishideng Publishing Group Inc

INSTRUCTIONS TO AUTHORS

<https://www.wjgnet.com/bpg/gerinfo/204>

GUIDELINES FOR ETHICS DOCUMENTS

<https://www.wjgnet.com/bpg/GerInfo/287>

GUIDELINES FOR NON-NATIVE SPEAKERS OF ENGLISH

<https://www.wjgnet.com/bpg/gerinfo/240>

PUBLICATION ETHICS

<https://www.wjgnet.com/bpg/GerInfo/288>

PUBLICATION MISCONDUCT

<https://www.wjgnet.com/bpg/gerinfo/208>

ARTICLE PROCESSING CHARGE

<https://www.wjgnet.com/bpg/gerinfo/242>

STEPS FOR SUBMITTING MANUSCRIPTS

<https://www.wjgnet.com/bpg/GerInfo/239>

ONLINE SUBMISSION

<https://www.f6publishing.com>



Malaria-associated secondary hemophagocytic lymphohistiocytosis: A case report

Xiao Zhou, Mei-Li Duan

ORCID number: Xiao Zhou 0000-0003-1352-2871; Mei-Li Duan 0000-0001-5947-4938.

Author contributions: Duan ML developed the treatment strategies for the patient; Zhou X administered the treatments and read the literature; Zhou X was a major contributor in writing the manuscript; all authors issued final approval for the version to be submitted.

Informed consent statement:

Informed written consent was obtained from the patient for publication of this report and any accompanying images.

Conflict-of-interest statement: The authors declare that they have no conflict of interest.

CARE Checklist (2016) statement:

The authors have read the CARE Checklist (2016), and the manuscript was prepared and revised according to the CARE Checklist (2016).

Open-Access: This article is an open-access article that was selected by an in-house editor and fully peer-reviewed by external reviewers. It is distributed in accordance with the Creative Commons Attribution NonCommercial (CC BY-NC 4.0) license, which permits others to

Xiao Zhou, Mei-Li Duan, Department of Critical Care Medicine, Beijing Friendship Hospital, Capital Medical University, Beijing 100054, China

Corresponding author: Mei-Li Duan, MD, PhD, Chief Doctor, Professor, Department of Critical Care Medicine, Beijing Friendship Hospital, Capital Medical University, No. 95 Yong'an Road, Xicheng District, Beijing 100054, China. dmeili@ccmu.edu.cn

Abstract

BACKGROUND

Malaria-associated secondary hemophagocytic lymphohistiocytosis (HLH) is rare. Moreover, the literature on malaria-associated HLH is sparse, and there are no similar cases reported in China.

CASE SUMMARY

We report the case of a 29-year-old woman with unexplained intermittent fever who was admitted to our hospital due to an unclear diagnosis. The patient concealed her history of travel to Nigeria before onset. We made a diagnosis of malaria-associated secondary HLH. The treatment strategy for this patient included treatment of the inciting factor (artemether for 9 d followed by artemisinin for 5 d), the use of immunosuppressants (steroids, intravenous immunoglobulin) and supportive care. The patient was discharged in normal physical condition after 25 d of intensive care. No relapses were documented on follow-up at six months and 1 year.

CONCLUSION

Early diagnosis of the primary disease along with timely intervention and a multidisciplinary approach can help patients achieve a satisfactory outcome.

Key Words: Fever; Malaria; Hemophagocytic lymphohistiocytosis; Secondary; Case report

©The Author(s) 2021. Published by Baishideng Publishing Group Inc. All rights reserved.

Core Tip: We found an unexpected association between malaria and hemophagocytic lymphohistiocytosis (HLH) in this case. Literature on malaria-associated HLH is sparse. There are no similar cases reported in China. In this case, we made the diagnosis based on HLH-2004 criteria and adopted new biomarkers to make the

distribute, remix, adapt, build upon this work non-commercially, and license their derivative works on different terms, provided the original work is properly cited and the use is non-commercial. See: <http://creativecommons.org/licenses/by-nc/4.0/>

Manuscript source: Unsolicited manuscript

Specialty type: Critical care medicine

Country/Territory of origin: China

Peer-review report's scientific quality classification

Grade A (Excellent): 0
Grade B (Very good): B
Grade C (Good): 0
Grade D (Fair): 0
Grade E (Poor): 0

Received: January 24, 2021

Peer-review started: January 24, 2021

First decision: March 8, 2021

Revised: March 12, 2021

Accepted: May 8, 2021

Article in press: May 8, 2021

Published online: August 6, 2021

P-Reviewer: Vyshka G

S-Editor: Ma YJ

L-Editor: Webster JR

P-Editor: Liu JH



diagnosis of HLH. Through multidisciplinary treatment, the patient was discharged in normal physical condition. This case highlights the importance of early diagnosis and timely therapy of the primary disease to secondary HLH.

Citation: Zhou X, Duan ML. Malaria-associated secondary hemophagocytic lymphohistiocytosis: A case report. *World J Clin Cases* 2021; 9(22): 6403-6409

URL: <https://www.wjgnet.com/2307-8960/full/v9/i22/6403.htm>

DOI: <https://dx.doi.org/10.12998/wjcc.v9.i22.6403>

INTRODUCTION

Hemophagocytic lymphohistiocytosis (HLH) is a systemic disorder caused by immune dysregulation that occurs in primary and secondary forms. Secondary HLH refers to cases caused by infections, malignancy and autoimmune diseases. HLH secondary to infections can occur with viral, bacterial, fungal or parasitic infections[1]. Malaria is rarely reported to cause HLH. We report the case of a 29-year-old woman with fever, hepatosplenomegaly, pancytopenia, high serum ferritin, hypertriglyceridemia, hypofibrinogenemia and bone marrow hemophagocytosis, consistent with hemophagocytic syndrome. *Plasmodium falciparum* (*P. falciparum*) was identified on a peripheral blood smear. Rapid recovery was observed after treatment with antimalarial medications, immunomodulatory therapy and supportive care.

CASE PRESENTATION

Chief complaints

A 29-year-old woman was admitted to the hospital due to intermittent fever for 12 d.

History of present illness

The patient had an unexplained fever (Tmax 41°C), chills and anorexia after a 14 d trip to Sokoto State, Nigeria in September 2018. However, the patient concealed her travel history while visiting the local hospital. She was diagnosed with pneumonia and received antibiotic treatment. With poor response to antibacterial treatment, the patient developed nausea, vomiting, upper abdominal pain, respiratory distress and oliguria. Further investigations showed negativity for Epstein-Barr virus (EBV) DNA but positivity for EBV-IgM. Bone marrow biopsy revealed hemophagocytosis. The patient was suspected to have EBV-related HLH, and was transferred to our hospital for emergency treatment.

History of past illness

The patient had no previous medical history.

Personal and family history

No notable personal or family history.

Physical examination

Physical examination revealed blood pressure of 105/64 mmHg, wet rales in the lower lung and upper abdominal tenderness.

Laboratory examinations

Blood tests showed cytopenia, increased liver transaminases, increased bilirubin, hypertriglyceridemia, increased serum ferritin, soluble CD25 (sCD25) level of 21574 pg/mL and negative results for natural killer cell (NK cell) activity. Tests for EBV and cytomegalovirus DNA were negative. There was no evidence of a tumor.

Imaging examinations

Abdominal ultrasonography and computed tomography (CT) showed splenomegaly (Figure 1).

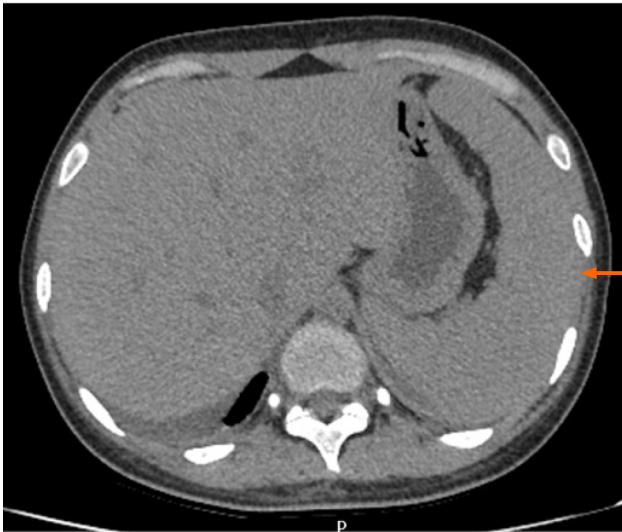

Figure 1 Abdominal computed tomography showed hepatosplenomegaly (orange arrow).

Microbiological identification of the causative agent

A peripheral blood smear showed *P. falciparum* (Figure 2A), which was determined to have a 3D7 genotype. Bone marrow aspiration showed the presence of hemophagocytosis (Figure 3)

MULTIDISCIPLINARY EXPERT CONSULTATION

Department of Tropical Diseases, Beijing Friendship Hospital, Capital Medical University

This patient has a clear diagnosis of malaria and should be treated.

Department of Hematology, Beijing Friendship Hospital, Capital Medical University

Considering HLH secondary to the malaria, the primary disease should be treated first, and immune-related treatment should be given at the same time.

Department of Critical Care Medicine, Beijing Friendship Hospital, Capital Medical University

This patient suffered from multiple organ dysfunction and should be monitored and treated in the Department of Critical Care Medicine.

FINAL DIAGNOSIS

The final diagnosis in this patient was malaria-associated secondary HLH.

TREATMENT

The treatment regimen for malaria included artemether at 80 mg q12 h for 4 d and then 80 mg qd for 5 d, which was changed to dihydroartemisinin and piperaquine phosphate 2 tablets qd for 5 d. At the same time, the patient received methylprednisolone 80 mg qd for 4 d. As we considered the HLH to be secondary to malaria, we treated the primary disease and administered intravenous immunoglobulin (IVIG) for 5 d (total dose of 2 g/kg).

Subsequently, the patient developed multiorgan dysfunction in critical care medicine. She exhibited acute kidney injury (creatinine 569 $\mu\text{mol/L}$ with oliguria), acute liver injury, acute respiratory distress syndrome ($\text{PaO}_2/\text{FiO}_2$ 100 mmHg) and coagulopathy and was treated with continuous renal replacement therapy, high-flow nasal cannula oxygen therapy (HFNC), blood transfusion and nutritional support in

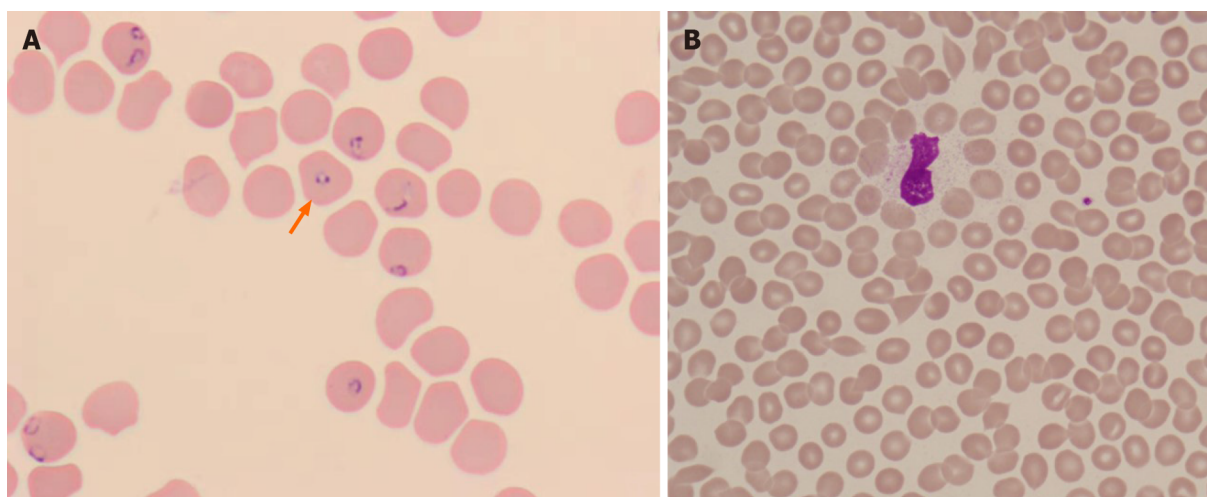


Figure 2 Peripheral blood smear. A: Hemophagocytes with malarial gametocytes (orange arrow); B: No plasmodium was found.

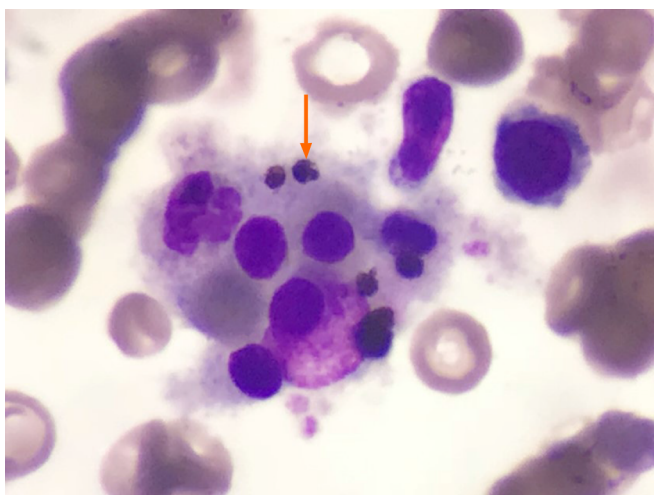


Figure 3 Bone marrow aspiration showed the presence of hemophagocytosis (orange arrow).

the critical care unit. After 7 d of organ support treatment, the patient's respiratory and renal function recovered to normal, and her liver-enzyme and bilirubin levels decreased.

OUTCOME AND FOLLOW-UP

After 7 d of treatment, no *P. falciparum* was found in the peripheral blood smear (Figure 2B), and tests for malarial antigens were negative. The patient's condition improved gradually, and her clinical and laboratory manifestations were normalized (Table 1). She was discharged in normal physical condition after 25 d. No relapses were documented at the six-month and 1-year follow-up.

DISCUSSION

Malaria is a mosquito-borne infectious disease that is caused by a parasitic protozoan of the genus *Plasmodium* and has diverse clinical manifestations[2]. The epidemiological history is important for diagnosis. Therefore, we should obtain a thorough and detailed medical history. The diagnosis of malaria was based on a peripheral blood smear and/or rapid diagnostic tests for malarial antigens. Artemisinin is mainly used in the treatment of malaria. Our patient was treated with artemether and

Table 1 The change in clinical and laboratory manifestations before and after treatment

	Reference range	Before treatment	7 d after treatment	14 d after treatment
Temperature (°C)	36-37	Tmax 39.8	No fever	No fever
White blood cells ($\times 10^9/L$)	3.50-9.50	2.88	3.78	4.33
Neutrophils ($\times 10^9/L$)	1.8-6.3	1.31	2.15	2.00
Hemoglobin (g/L)	115-150	49	108	93
Platelet count ($\times 10^9/L$)	125-350	50	112	151
Reticulocytes ($\times 10^{12}/L$)	0.0140-0.0900	0.1443	0.2269	0.0902
Indirect bilirubin ($\mu\text{mol}/L$)	0.00-12.00	15.44	16.09	8.59
Triglyceride (mmol/L)	0.57-1.70	2.45	2.42	2.23
Ferritin (ng/mL)	11.00-306.00	1989.00	1730	1516
Fibrinogen (ng/mL)	1.70-4.00	1.41	1.31	1.63
NK-cell activity		Negative		-
sCD25 (pg/mL)		21574		4775
Spleen ultrasonography	Length 8.5 ± 1.0 cm	14.2		-
	Thickness 2.8 ± 0.5 cm	3.8		3.4

sCD25: Soluble CD25; NK cell: Natural killer cell.

dihydroartemisinin because the effect of dihydroartemisinin is 5 times more potent against malaria than artemisinin[3]. She subsequently took oral dihydroartemisinin and piperazine phosphate. There are also reports of oral doxycycline treatment in the literature.

HLH, a life-threatening disease associated with excessive stimulation of tissue macrophages[4], occurs in primary and secondary forms. Primary HLH is mostly recognized in childhood, whereas the secondary form can occur at any age. Secondary HLH refers to cases caused by infections, malignancy and autoimmune diseases. HLH secondary to infections can occur with viral, bacterial, fungal or parasitic infections; viral infections, especially those caused by EBV, are the most common. The clinical and laboratory manifestations of HLH include fever, splenomegaly, neurologic dysfunction, coagulopathy, liver dysfunction, cytopenia, hypertriglyceridemia, hyperferritinemia, hemophagocytosis, and diminished NK-cell activity. In fact, the clinical manifestations of HLH lack specificity. The severity is related to the levels of immune cell activation and cytokines. Currently, we make the diagnosis based on HLH-2004 criteria[5] (Table 2). Hemophagocytosis cannot be used as a necessary condition to exclude or diagnose HLH. The sensitivity of hemophagocytosis in the diagnosis of HLH is approximately 60%. HLH cannot be excluded in the absence of hemophagocytosis. The sensitivity of ferritin $> 500 \mu\text{g}/L$ in the diagnosis of HLH is 84%. Serum ferritin $< 500 \mu\text{g}/L$ has a negative evaluative significance for the diagnosis of HLH. NK-cell activity is a landmark diagnostic indicator that is irreversible in primary HLH but can be recovered in secondary HLH. The reference range varies depending on the detection method. sCD25 is the most useful marker of inflammation, which reflects the excessive immune activation status of patients. The literature shows that elevated sCD25 in children has a sensitivity of 76.2% and a specificity of 98.2% for the diagnosis of HLH[6]. The treatment strategy for secondary HLH includes supportive care, treatment of inciting factors and the use of immunosuppressants (steroids, IVIG and other immunosuppressive drugs).

Malaria as a cause of secondary HLH is rare. We reviewed the related literature, and fewer than 20 cases have been reported[7-14]. There are no similar cases reported in China. The reason for this is that on the one hand, China is not a malaria-endemic area, and on the other hand, some cases have not been recognized and diagnosed. The types of malarial parasites that cause secondary HLH are *P. falciparum* and *P. vivax*[7,13], with *P. falciparum* accounting for most of these cases. The pathogenesis is not yet clear but may be related to immune dysfunction caused by falciparum malaria. Whether the pathogenic mechanisms of the different types of Plasmodium are different still needs further study.

Table 2 Diagnosis of hemophagocytic lymphohistiocytosis-2004 criteria

The diagnosis of HLH can be established if either condition 1 or condition 2 below is fulfilled

(1) A molecular diagnosis consistent with HLH

(2) Diagnostic criteria for HLH fulfilled (five out of the eight criteria below)

(A) Initial diagnostic criteria (to be evaluated in all patients with HLH)

Fever

Splenomegaly

Cytopenia (affecting ≥ 2 of 3 lineages in the peripheral blood):

Hemoglobin < 90 g/L (in infants < 4 wk: hemoglobin < 100 g/L)

Platelets $< 100 \times 10^9$ /L

Neutrophils $< 1.0 \times 10^9$ /L

Hypertriglyceridemia and/or hypofibrinogenemia:

Fasting triglycerides ≥ 3.0 mmol/L (*i.e.*, ≥ 265 mg/dL)

Fibrinogen ≤ 1.5 g/L

Hemophagocytosis in bone marrow or spleen or lymph nodes

No evidence of malignancy

(B) New diagnostic criteria

Low or absent NK-cell activity (according to local laboratory reference)

Ferritin ≥ 500 μ g/L

Soluble CD25 (*i.e.*, soluble IL-2 receptor) ≥ 2400 U/mL

HLH: Hemophagocytic lymphohistiocytosis.

In this case, the patient had fever and gastrointestinal symptoms, such as fatigue, anorexia, nausea, and vomiting, but no enlarged lymph nodes, rash, bleeding or neurologic dysfunction. Although NK-cell activity was negative, the diagnosis of HLH clearly met seven out of the eight HLH-2004 criteria. However, in most cases reported in the literature, NK-cell activity and sCD25 antigen levels were not available. Thanks to the new diagnostic markers, the patient was timely diagnosed. In addition, intensive care unit intervention played a valuable role in the patient's recovery. No deaths due to malaria-associated HLH have been reported. Our patient also had a good prognosis.

CONCLUSION

In conclusion, malaria-associated secondary HLH is rare. If the patient has fever, splenomegaly and an elevated ferritin level, HLH should be highly suspected, and relevant examinations should be conducted. Early diagnosis of the primary disease along with timely intervention and a multidisciplinary approach can help patients achieve a satisfactory outcome.

ACKNOWLEDGEMENTS

The authors express special thanks to Dr. Wang Lei and Dr. Jia-Ning Chen, who guided this work.

REFERENCES

- 1 Ramos-Casals M, Brito-Zerón P, López-Guillermo A, Khamashta MA, Bosch X. Adult

- haemophagocytic syndrome. *Lancet* 2014; **383**: 1503-1516 [PMID: 24290661 DOI: 10.1016/S0140-6736(13)61048-X]
- 2 **Weeratunga P**, Rathnayake G, Sivashangar A, Karunanayake P, Gnanathanan A, Chang T. Plasmodium falciparum and Mycoplasma pneumoniae co-infection presenting with cerebral malaria manifesting orofacial dyskinesia and haemophagocytic lymphohistiocytosis. *Malar J* 2016; **15**: 461 [PMID: 27609213 DOI: 10.1186/s12936-016-1517-x]
 - 3 **Zhang H**, Zhou F, Wang Y, Xie H, Luo S, Meng L, Su B, Ye Y, Wu K, Xu Y, Gong X. Eliminating Radiation Resistance of Non-Small Cell Lung Cancer by Dihydroartemisinin Through Abrogating Immunity Escaping and Promoting Radiation Sensitivity by Inhibiting PD-L1 Expression. *Front Oncol* 2020; **10**: 595466 [PMID: 33194761 DOI: 10.3389/fonc.2020.595466]
 - 4 **Klein E**, Ronez E. Peripheral hemophagocytosis in malaria infection. *Blood* 2012; **119**: 910 [PMID: 22389905 DOI: 10.1182/blood-2011-02-336420]
 - 5 **Henter JI**, Horne A, Aricó M, Egeler RM, Filipovich AH, Imashuku S, Ladisch S, McClain K, Webb D, Winiarski J, Janka G. HLH-2004: Diagnostic and therapeutic guidelines for hemophagocytic lymphohistiocytosis. *Pediatr Blood Cancer* 2007; **48**: 124-131 [PMID: 16937360 DOI: 10.1002/pbc.21039]
 - 6 **Wang Y**, Liu D, Zhu G, Yin C, Sheng G, Zhao X. [Significance of soluble CD163 and soluble CD25 in diagnosis and treatment of children with hemophagocytic lymphohistiocytosis]. *Zhonghua Er Ke Za Zhi* 2015; **53**: 824-829 [PMID: 26758320]
 - 7 **Bhagat M**, Kanhere S, Kadakia Affiliation When The Manuscript Was Written Department Of Paediatrics K J Somaiya Medical College And Hospital Mumbai India P, Phadke V, George R, Chaudhari K. Haemophagocytic lymphohistiocytosis: a cause of unresponsive malaria in a 5-year-old girl. *Paediatr Int Child Health* 2014; 2046905514Y0000000163 [PMID: 25410687 DOI: 10.1080/20469047.2015.1109227]
 - 8 **Amireh S**, Shaaban H, Guron G. Severe Plasmodium vivax cerebral malaria complicated by hemophagocytic lymphohistiocytosis treated with artesunate and doxycycline. *Hematol Oncol Stem Cell Ther* 2018; **11**: 34-37 [PMID: 27514010 DOI: 10.1016/j.hemonc.2016.06.001]
 - 9 **Bae E**, Jang S, Park CJ, Chi HS. Plasmodium vivax malaria-associated hemophagocytic lymphohistiocytosis in a young man with pancytopenia and fever. *Ann Hematol* 2011; **90**: 491-492 [PMID: 20721557 DOI: 10.1007/s00277-010-1042-x]
 - 10 **Santos JA**, Neves JF, Venâncio P, Gouveia C, Varandas L. Hemophagocytic lymphohistiocytosis secondary to Falciparum malaria in a 5 year-old boy. *Ann Hematol* 2015; **94**: 161-163 [PMID: 24880248 DOI: 10.1007/s00277-014-2118-9]
 - 11 **Selvarajan D**, Sundaravel S, Alagusundaramoorthy SS, Jacob A. Hemophagocytic lymphohistiocytosis with concurrent malarial infection. *BMJ Case Rep* 2017; **2017** [PMID: 28784903 DOI: 10.1136/bcr-2017-221159]
 - 12 **Harioly Nirina MOM**, Raheritiana TM, Harioly Nirina MOJ, Rasolonjatovo AS, Rakoto Alson AO, Rasamindrakotroka A. [Hemophagocytic lymphohistiocytosis associated with Plasmodium falciparum]. *Med Mal Infect* 2017; **47**: 569-570 [PMID: 28844807 DOI: 10.1016/j.medmal.2017.07.005]
 - 13 **Niang A**, Niang SE, Ka el HF, Ka MM, Diouf B. Collapsing glomerulopathy and haemophagocytic syndrome related to malaria: a case report. *Nephrol Dial Transplant* 2008; **23**: 3359-3361 [PMID: 18676345 DOI: 10.1093/ndt/gfn427]
 - 14 **Vinoth PN**, Thomas KA, Selvan SM, Suman DF, Scott JX. Hemophagocytic syndrome associated with Plasmodium falciparum infection. *Indian J Pathol Microbiol* 2011; **54**: 594-596 [PMID: 21934231 DOI: 10.4103/0377-4929.85105]



Published by **Baishideng Publishing Group Inc**
7041 Koll Center Parkway, Suite 160, Pleasanton, CA 94566, USA

Telephone: +1-925-3991568

E-mail: bpgoffice@wjgnet.com

Help Desk: <https://www.f6publishing.com/helpdesk>

<https://www.wjgnet.com>

