

# World Journal of *Clinical Cases*

*World J Clin Cases* 2021 August 6; 9(22): 6178-6581



### REVIEW

- 6178** COVID-19 infection and liver injury: Clinical features, biomarkers, potential mechanisms, treatment, and management challenges

*Sivandzadeh GR, Askari H, Safarpour AR, Ejtehad F, Raeis-Abdollahi E, Vaez Lari A, Abazari MF, Tarkesh F, Bagheri Lankarani K*

- 6201** Gastrointestinal manifestations of systemic sclerosis: An updated review

*Luquez-Mindiola A, Atuesta AJ, Gómez-Aldana AJ*

### MINIREVIEWS

- 6218** Mesenchymal stem cell-derived exosomes: An emerging therapeutic strategy for normal and chronic wound healing

*Zeng QL, Liu DW*

- 6234** Role of autophagy in cholangiocarcinoma: Pathophysiology and implications for therapy

*Ninfolle E, Pinto C, Benedetti A, Marziani M, Maroni L*

### ORIGINAL ARTICLE

#### Case Control Study

- 6244** Risk factors for intussusception in children with Henoch-Schönlein purpura: A case-control study

*Zhao Q, Yang Y, He SW, Wang XT, Liu C*

#### Retrospective Study

- 6254** Sequential therapy with combined trans-papillary endoscopic naso-pancreatic and endoscopic retrograde pancreatic drainage for pancreatic pseudocysts

*He YG, Li J, Peng XH, Wu J, Xie MX, Tang YC, Zheng L, Huang XB*

- 6268** Retrospective study of effect of whole-body vibration training on balance and walking function in stroke patients

*Xie L, Yi SX, Peng QF, Liu P, Jiang H*

- 6278** Risk factors for preoperative carcinogenesis of bile duct cysts in adults

*Wu X, Li BL, Zheng CJ, He XD*

- 6287** Diagnostic and prognostic value of secreted protein acidic and rich in cysteine in the diffuse large B-cell lymphoma

*Pan PJ, Liu JX*

- 6300** Jumbo cup in hip joint renovation may cause the center of rotation to increase

*Peng YW, Shen JM, Zhang YC, Sun JY, Du YQ, Zhou YG*

**Clinical Trials Study**

- 6308** Effect of exercise training on left ventricular remodeling in patients with myocardial infarction and possible mechanisms  
*Cai M, Wang L, Ren YL*

**Observational Study**

- 6319** Analysis of sleep characteristics and clinical outcomes of 139 adult patients with infective endocarditis after surgery  
*Hu XM, Lin CD, Huang DY, Li XM, Lu F, Wei WT, Yu ZH, Liao HS, Huang F, Huang XZ, Jia FJ*
- 6329** Health-related risky behaviors and their risk factors in adolescents with high-functioning autism  
*Sun YJ, Xu LZ, Ma ZH, Yang YL, Yin TN, Gong XY, Gao ZL, Liu YL, Liu J*
- 6343** Selection of internal fixation method for femoral intertrochanteric fractures using a finite element method  
*Mu JX, Xiang SY, Ma QY, Gu HL*

**META-ANALYSIS**

- 6357** Neoadjuvant chemotherapy for patients with resectable colorectal cancer liver metastases: A systematic review and meta-analysis  
*Zhang Y, Ge L, Weng J, Tuo WY, Liu B, Ma SX, Yang KH, Cai H*

**CASE REPORT**

- 6380** Ruptured intracranial aneurysm presenting as cerebral circulation insufficiency: A case report  
*Zhao L, Zhao SQ, Tang XP*
- 6388** Prostatic carcinosarcoma seven years after radical prostatectomy and hormonal therapy for prostatic adenocarcinoma: A case report  
*Huang X, Cai SL, Xie LP*
- 6393** Pyogenic arthritis, pyoderma gangrenosum, and acne syndrome in a Chinese family: A case report and review of literature  
*Lu LY, Tang XY, Luo GJ, Tang MJ, Liu Y, Yu XJ*
- 6403** Malaria-associated secondary hemophagocytic lymphohistiocytosis: A case report  
*Zhou X, Duan ML*
- 6410** Ileal hemorrhagic infarction after carotid artery stenting: A case report and review of the literature  
*Xu XY, Shen W, Li G, Wang XF, Xu Y*
- 6418** Inflammatory myofibroblastic tumor of the pancreatic neck: A case report and review of literature  
*Chen ZT, Lin YX, Li MX, Zhang T, Wan DL, Lin SZ*
- 6428** Management of heterotopic cesarean scar pregnancy with preservation of intrauterine pregnancy: A case report  
*Chen ZY, Zhou Y, Qian Y, Luo JM, Huang XF, Zhang XM*

- 6435** Manifestation of severe pneumonia in anti-PL-7 antisynthetase syndrome and B cell lymphoma: A case report  
*Xu XL, Zhang RH, Wang YH, Zhou JY*
- 6443** Disseminated infection by *Fusarium solani* in acute lymphocytic leukemia: A case report  
*Yao YF, Feng J, Liu J, Chen CF, Yu B, Hu XP*
- 6450** Primary hepatic neuroendocrine tumor – <sup>18</sup>F-fluorodeoxyglucose positron emission tomography/computed tomography findings: A case report  
*Rao YY, Zhang HJ, Wang XJ, Li MF*
- 6457** Malignant peripheral nerve sheath tumor in an elderly patient with superficial spreading melanoma: A case report  
*Yang CM, Li JM, Wang R, Lu LG*
- 6464** False positive anti-hepatitis A virus immunoglobulin M in autoimmune hepatitis/primary biliary cholangitis overlap syndrome: A case report  
*Yan J, He YS, Song Y, Chen XY, Liu HB, Rao CY*
- 6469** Successful totally laparoscopic right trihepatectomy following conversion therapy for hepatocellular carcinoma: A case report  
*Zhang JJ, Wang ZX, Niu JX, Zhang M, An N, Li PF, Zheng WH*
- 6478** Primary small cell esophageal carcinoma, chemotherapy sequential immunotherapy: A case report  
*Wu YH, Zhang K, Chen HG, Wu WB, Li XJ, Zhang J*
- 6485** Subdural fluid collection rather than meningitis contributes to hydrocephalus after cervical laminoplasty: A case report  
*Huang HH, Cheng ZH, Ding BZ, Zhao J, Zhao CQ*
- 6493** Phlegmonous gastritis developed during chemotherapy for acute lymphocytic leukemia: A case report  
*Saito M, Morioka M, Izumiyama K, Mori A, Ogasawara R, Kondo T, Miyajima T, Yokoyama E, Tanikawa S*
- 6501** Spinal epidural hematoma after spinal manipulation therapy: Report of three cases and a literature review  
*Liu H, Zhang T, Qu T, Yang CW, Li SK*
- 6510** Abdominal hemorrhage after peritoneal dialysis catheter insertion: A rare cause of luteal rupture: A case report  
*Gan LW, Li QC, Yu ZL, Zhang LL, Liu Q, Li Y, Ou ST*
- 6515** Concealed mesenteric ischemia after total knee arthroplasty: A case report  
*Zhang SY, He BJ, Xu HH, Xiao MM, Zhang JJ, Tong PJ, Mao Q*
- 6522** Chylothorax following posterior low lumbar fusion surgery: A case report  
*Huang XM, Luo M, Ran LY, You XH, Wu DW, Huang SS, Gong Q*
- 6531** Non-immune hydrops fetalis: Two case reports  
*Maranto M, Cigna V, Orlandi E, Cucinella G, Lo Verso C, Duca V, Picciotto F*

- 6538** Bystander effect and abscopal effect in recurrent thymic carcinoma treated with carbon-ion radiation therapy: A case report  
*Zhang YS, Zhang YH, Li XJ, Hu TC, Chen WZ, Pan X, Chai HY, Ye YC*
- 6544** Management of an intracranial hypotension patient with diplopia as the primary symptom: A case report  
*Wei TT, Huang H, Chen G, He FF*
- 6552** Spontaneous rupture of adrenal myelolipoma as a cause of acute flank pain: A case report  
*Kim DS, Lee JW, Lee SH*
- 6557** Neonatal necrotizing enterocolitis caused by umbilical arterial catheter-associated abdominal aortic embolism: A case report  
*Huang X, Hu YL, Zhao Y, Chen Q, Li YX*
- 6566** Primary mucosa-associated lymphoid tissue lymphoma in the midbrain: A case report  
*Zhao YR, Hu RH, Wu R, Xu JK*
- 6575** Extensive cutaneous metastasis of recurrent gastric cancer: A case report  
*Chen JW, Zheng LZ, Xu DH, Lin W*

**ABOUT COVER**

Editorial Board Member of *World Journal of Clinical Cases*, Salma Ahi, MD, Assistant Professor, Research Center for Noncommunicable Diseases, Jahrom University of Medical Sciences, Jahrom 193, Iran. salmaahi.61@gmail.com

**AIMS AND SCOPE**

The primary aim of *World Journal of Clinical Cases* (WJCC, *World J Clin Cases*) is to provide scholars and readers from various fields of clinical medicine with a platform to publish high-quality clinical research articles and communicate their research findings online.

WJCC mainly publishes articles reporting research results and findings obtained in the field of clinical medicine and covering a wide range of topics, including case control studies, retrospective cohort studies, retrospective studies, clinical trials studies, observational studies, prospective studies, randomized controlled trials, randomized clinical trials, systematic reviews, meta-analysis, and case reports.

**INDEXING/ABSTRACTING**

The WJCC is now indexed in Science Citation Index Expanded (also known as SciSearch®), Journal Citation Reports/Science Edition, Scopus, PubMed, and PubMed Central. The 2021 Edition of Journal Citation Reports® cites the 2020 impact factor (IF) for WJCC as 1.337; IF without journal self cites: 1.301; 5-year IF: 1.742; Journal Citation Indicator: 0.33; Ranking: 119 among 169 journals in medicine, general and internal; and Quartile category: Q3. The WJCC's CiteScore for 2020 is 0.8 and Scopus CiteScore rank 2020: General Medicine is 493/793.

**RESPONSIBLE EDITORS FOR THIS ISSUE**

Production Editor: Yan-Xia Xing; Production Department Director: Yun-Jie Ma; Editorial Office Director: Jin-Lei Wang.

**NAME OF JOURNAL**

*World Journal of Clinical Cases*

**ISSN**

ISSN 2307-8960 (online)

**LAUNCH DATE**

April 16, 2013

**FREQUENCY**

Thrice Monthly

**EDITORS-IN-CHIEF**

Dennis A Bloomfield, Sandro Vento, Bao-Gan Peng

**EDITORIAL BOARD MEMBERS**

<https://www.wjgnet.com/2307-8960/editorialboard.htm>

**PUBLICATION DATE**

August 6, 2021

**COPYRIGHT**

© 2021 Baishideng Publishing Group Inc

**INSTRUCTIONS TO AUTHORS**

<https://www.wjgnet.com/bpg/gerinfo/204>

**GUIDELINES FOR ETHICS DOCUMENTS**

<https://www.wjgnet.com/bpg/GerInfo/287>

**GUIDELINES FOR NON-NATIVE SPEAKERS OF ENGLISH**

<https://www.wjgnet.com/bpg/gerinfo/240>

**PUBLICATION ETHICS**

<https://www.wjgnet.com/bpg/GerInfo/288>

**PUBLICATION MISCONDUCT**

<https://www.wjgnet.com/bpg/gerinfo/208>

**ARTICLE PROCESSING CHARGE**

<https://www.wjgnet.com/bpg/gerinfo/242>

**STEPS FOR SUBMITTING MANUSCRIPTS**

<https://www.wjgnet.com/bpg/GerInfo/239>

**ONLINE SUBMISSION**

<https://www.f6publishing.com>

# Management of an intracranial hypotension patient with diplopia as the primary symptom: A case report

Ting-Ting Wei, Hua Huang, Gang Chen, Fei-Fang He

**ORCID number:** Ting-Ting Wei 0000-0002-5540-8391; Hua Huang 0000-0002-1866-0010; Gang Chen 0000-0002-8359-7417; Fei-Fang He 0000-0002-5009-3968.

**Author contributions:** Wei TT and Chen G reviewed the literature and contributed to manuscript drafting; Huang H and He FF analyzed, interpreted the imaging findings, and drafted the manuscript; Wei TT, Huang H, He FF, and Chen G were responsible for the revision of the manuscript for important intellectual content; All authors issued final approval for the version to be submitted.

**Informed consent statement:**

Informed written consent was obtained from the patient for publication of this report and any accompanying images.

**Conflict-of-interest statement:** The authors declare that there is no conflict of interest in this article.

**CARE Checklist (2016) statement:**

The authors have read the CARE Checklist (2016), and the manuscript was prepared and revised according to the CARE Checklist (2016).

**Open-Access:** This article is an open-access article that was selected by an in-house editor and fully peer-reviewed by external

**Ting-Ting Wei, Gang Chen,** Department of Anesthesiology, Sir Run Run Shaw Hospital, School of Medicine, Zhejiang University, Hangzhou 310003, Zhejiang Province, China

**Hua Huang, Fei-Fang He,** Department of Pain Management, Sir Run Run Shaw Hospital, School of Medicine, Zhejiang University, Hangzhou 310003, Zhejiang Province, China

**Corresponding author:** Gang Chen, PhD, Chief Doctor, Department of Anesthesiology, Sir Run Run Shaw Hospital, School of Medicine, Zhejiang University, No. 3 Qingchun Road, Hangzhou 310003, Zhejiang Province, China. [chengang120@zju.edu.cn](mailto:chengang120@zju.edu.cn)

## Abstract

### BACKGROUND

Intracranial hypotension (IH) is a disorder involving cerebrospinal fluid (CSF) hypovolemia due to spontaneous or traumatic spinal CSF leakage and is easily being misdiagnosed or missed, especially in these patients without the prototypical manifestation of an orthostatic headache. At present, the management of IH with both cranial nerve VI palsy and bilateral subdural hematomas (SDHs) is still unclear.

### CASE SUMMARY

A 67-year-old male Chinese patient complained of diplopia on the left side for one and a half mo. Computed tomography revealed bilateral SDHs and a midline shift. However, neurotrophic drugs were not effective, and 3 d after admission, he developed a non-orthostatic headache and neck stiffness. Enhanced magnetic resonance imaging revealed dural enhancement as an additional feature, and IH was suspected. Magnetic resonance myelography was then adopted and showed CSF leakage at multiple sites in the spine, confirming the diagnosis of having IH. The patient fully recovered following multiple targeted epidural blood patch (EBP) procedures.

### CONCLUSION

IH is a rare disease, and to the best of our knowledge, IH with diplopia as its initial and primary symptom has never been reported. In this study, we also elucidated that it could be safe and effective to treat IH patients with associated cranial nerve VI palsy and bilateral SDHs using repeated EBP therapy.

**Key Words:** Cranial nerve VI palsy; Epidural blood patch; Intracranial hypotension; Subdural hematoma; Case report



reviewers. It is distributed in accordance with the Creative Commons Attribution NonCommercial (CC BY-NC 4.0) license, which permits others to distribute, remix, adapt, build upon this work non-commercially, and license their derivative works on different terms, provided the original work is properly cited and the use is non-commercial. See: <http://creativecommons.org/licenses/by-nc/4.0/>

**Manuscript source:** Unsolicited manuscript

**Specialty type:** Medicine, research and experimental

**Country/Territory of origin:** China

**Peer-review report's scientific quality classification**

Grade A (Excellent): 0  
Grade B (Very good): B  
Grade C (Good): 0  
Grade D (Fair): 0  
Grade E (Poor): 0

**Received:** April 11, 2021

**Peer-review started:** April 20, 2021

**First decision:** May 11, 2021

**Revised:** May 18, 2021

**Accepted:** May 26, 2021

**Article in press:** May 26, 2021

**Published online:** August 6, 2021

**P-Reviewer:** Chrastina J

**S-Editor:** Fan JR

**L-Editor:** Filipodia

**P-Editor:** Li JH



©The Author(s) 2021. Published by Baishideng Publishing Group Inc. All rights reserved.

**Core Tip:** Intracranial hypotension (IH) is an uncommon disorder of cerebrospinal fluid (CSF) hypovolemia due to spontaneous or iatrogenic spinal CSF leakage, and is easily being misdiagnosed or missed as it can be associated with a large diversity of clinical signs. To the best of our knowledge, this is the first case in the literature describing a patient of having IH with diplopia as his initial and primary complaint, and demonstrating the efficacy of repeated epidural blood patch therapy in managing a patient with multiple sites of CSF leakage in the spine complicated with cranial nerve VI injury and subdural hematomas.

**Citation:** Wei TT, Huang H, Chen G, He FF. Management of an intracranial hypotension patient with diplopia as the primary symptom: A case report. *World J Clin Cases* 2021; 9(22): 6544-6551

**URL:** <https://www.wjgnet.com/2307-8960/full/v9/i22/6544.htm>

**DOI:** <https://dx.doi.org/10.12998/wjcc.v9.i22.6544>

## INTRODUCTION

Intracranial hypotension (IH) is a disease being recognized with increasing frequency and is caused by decreased intracranial pressure (ICP), usually due to cerebral spinal fluid (CSF) leakage[1]. This case report describes the case of a 67-year-old male with diplopia as his primary symptom; the diagnosis of IH was missed until CSF leakage in the spine was found on magnetic resonance myelography (MRM), and the patient was successfully managed by multiple epidural blood patch (EBP) procedures. This is the first case to describe a patient with IH with diplopia as his initial and chief complaint and discuss the efficacy of using repeated EBP therapy to treat a patient with IH complicated with cranial nerve VI palsy and subdural hematomas (SDHs).

## CASE PRESENTATION

### Chief complaints

A 67-year-old Asian man complained of diplopia on the left side.

### History of present illness

The patient's symptom started one and a half mo prior to presentation. However, after half a mo of conservative treatment for paralytic strabismus, his symptom did not improve.

### History of past illness

The patient had a history of type 2 diabetes for 15 years, with well-controlled glucose. He suffered a stroke 10 years ago without sequelae and took sitagliptin regularly afterwards.

### Personal and family history

No smoking or drinking history, and no similar family history were noted.

### Physical examination

Physical examination revealed left lateral gaze palsy and horizontal diplopia, consisting of left abducens nerve paralysis, as well as weaker strength in the left upper limb (motor strength score of 4) and a positive Babinski sign.

### Laboratory examinations

Blood analysis revealed an elevated total cholesterol of 5.57 mmol/L and a very low density lipoprotein of 0.96 mmol/L. The electrocardiogram showed a first-degree atrioventricular block and a conduction block in the left forearm. The microprotein level in CSF obtained from a lumbar puncture performed 2 wk after the third EBP



treatment was 950 mg/L. The Pandy test was positive. The ICP was normal.

### Imaging examinations

The initial plain computed tomography (CT) scan revealed SDH, which resulted in referral of the patient to the Neurosurgery Department (Figure 1A). The patient suffered a sudden severe non-orthostatic headache with neck stiffness on day 3 after admission. Enhanced magnetic resonance imaging (MRI) of his head revealed dural enhancement as an additional feature (Figure 1B and C). He was then suspected of having IH. MRM was utilized and showed multiple sites of CSF leakage in the spine, confirming the diagnosis of IH (Figure 2).

---

## MULTIDISCIPLINARY EXPERT CONSULTATION

Fei-Fang He, MD, Professor and Chief, Department of Pain Management, Sir Run Run Shaw Hospital, School of Medicine, Zhejiang University. Yi-Rong Wang, MD, PhD, Professor and Chief, Department of Neurosurgery, Sir Run Run Shaw Hospital, School of Medicine, Zhejiang University

Since CSF leakage in the spine was confirmed and the patient had a stable condition, EBP therapy could be performed first.

---

## FINAL DIAGNOSIS

The final diagnosis of this case was IH complicated with cranial nerve VI palsy and SDHs.

---

## TREATMENT

He was treated with bed rest, hydration, neurotrophic drugs for treating cranial nerve VI palsy, cholesterol lowering and glycemic control medication after the confirmation of having IH. On day 15 after his admission, the patient underwent the first EBP procedure. An 18-G needle was inserted into his epidural space at the T2/3 level, and 21 mL of autologous peripheral venous blood was infused. The second EBP treatment was performed on day 22 after considering the progression of the SDHs, with 21 mL of blood being infused at the T8/9 level. According to the MRM results on day 30, the third EBP procedure was performed on day 32 using 22 mL of blood at the T5/6 level. He accepted the same drug treatment after each EBP procedure.

---

## OUTCOME AND FOLLOW-UP

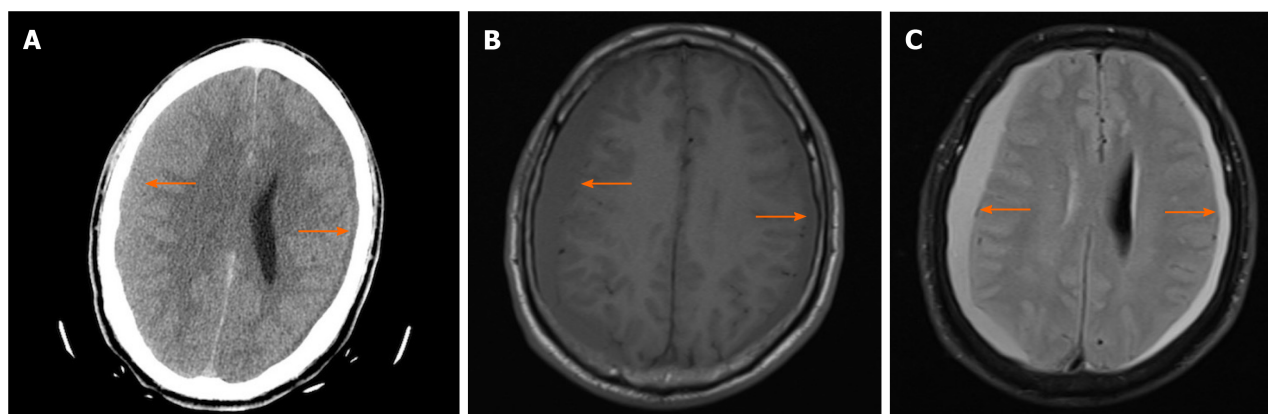
After the first EBP therapy, his headache and neck stiffness were markedly alleviated. On day 21, the follow-up CT revealed bilateral SDHs with greater density volume than the previous SDHs (Figure 3A). However, he had no complaints other than diplopia. This was followed by the second EBP therapy on day 22. The MRM of the spinal column on day 30 revealed a similar scan with no obvious decrease in CSF leakage (Figure 3B and C). Accordingly, the third EBP procedure was performed on day 32. To evaluate the curative efficacy of EBP therapy, CT myelography was employed on day 57 and showed no evident CSF leakage (Figure 3D). His symptom of diplopia was relieved 3 wk after the third EBP therapy. Over a follow-up period of 6 mo, none of the symptoms recurred, suggesting a favorable recovery.

Figure 4 summarizes the key events of this case report chronologically.

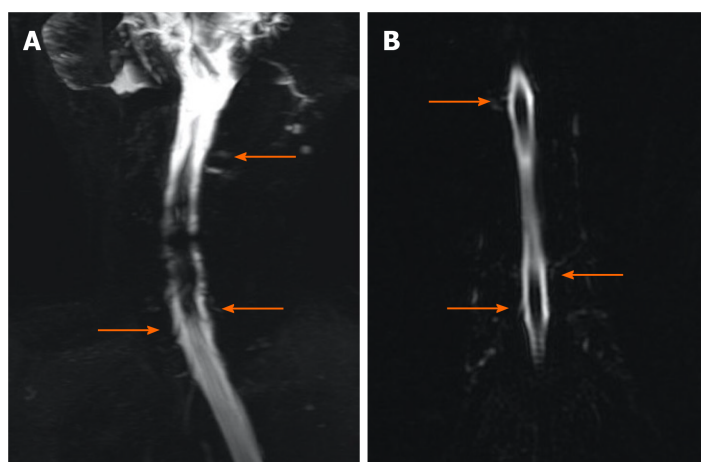
---

## DISCUSSION

IH is a disorder of CSF hypovolemia due to spontaneous or traumatic spinal CSF leakage. The most common symptom of IH is a headache. The characteristic headache is orthostatic, aggravating in the upright posture and alleviating in the supine position [2]. In this patient, diplopia presented as the initial and primary complaint; it should be noted that this is the first reported case with this feature, which delayed making the



**Figure 1 Axial brain image acquired before suspicion of having intracranial hypotension.** A: Axial computed tomography image shows left-sided subdural effusion, right-sided subdural hematoma (orange arrows), compression of the right ventricle and midline shift on day 1; B: Axial T1-weighted magnetic resonance imaging (MRI) with gadolinium enhancement reveals diffuse pachymeningeal thickening and subdural hematomas (SDHs) on both sides on day 3 (orange arrows); C: Axial T2-weighted MRI with gadolinium enhancement reveals SDHs with high signal in the same area on day 3 (orange arrows).

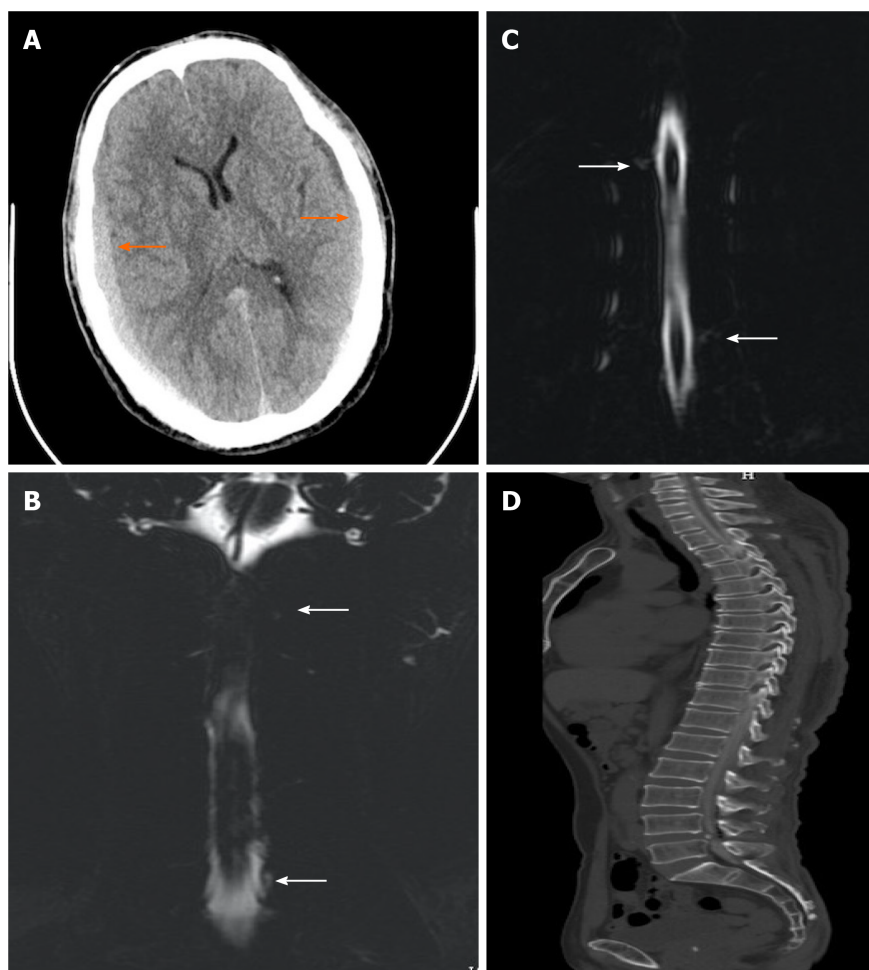


**Figure 2 Magnetic resonance myelography imaging of the spine performed before epidural blood patch therapy.** A: Magnetic resonance myelography (MRM) shows multiple sites of cerebrospinal fluid (CSF) leakage at cervicothoracic junctions on day 9 (orange arrows); B: MRM shows multiple sites of CSF leakage in the thoracic region on day 9 (orange arrows).

correct diagnosis and increased the difficulty of proper therapy. In this case, horizontal diplopia, which was worse in one direction of lateral gaze, occurred with an abduction deficit and presented as esodeviation. Possible etiologies of abduction deficits include conditions affecting the pons, cranial nerve VI, neuromuscular junctions, and extraocular muscles[3]. Specifically, this patient's diplopia was attributed to cranial nerve VI palsy derived from continuous CSF leakage. The sixth cranial nerve is the most frequently injured because of its long intracranial path. MRI has shown that continuous CSF leakage leads to IH with descent of the brain, causing traction of the sixth nerve and subsequent symptoms[4].

The presence of SDH was another characteristic feature in this case. SDH is a severe complication of IH that may lead to neurological deficits and can be life-threatening [5]. SDH associated with IH is considered to be secondary to the collapse of the intrathecal space due to CSF leakage[6]. The reported incidence of SDH among spontaneous IH patients ranges from 16% to 57%, prevailing in males[7], whereas spontaneous IH without SDH is predominant in females and the average onset age of spontaneous IH with SDH is 44.9 years[8,9].

The association between SDH and abducens nerve palsy is rarely mentioned in the literature. These two complications were related to descent of the brain, causing traction of cranial nerves with a long intracranial course and on intracranial vessels. This traction leads to the avulsion of dural veins and subsequent subdural bleeding [10].



**Figure 3 Images of the brain and spine acquired after the epidural blood patch therapy.** A: Axial computed tomography (CT) image shows bilateral subdural hematomas with greater density and volume than the previous hematomas on day 21 after the first epidural blood patch (EBP) therapy (orange arrows); B: Magnetic resonance myelography (MRM) shows multiple sites of cerebrospinal fluid (CSF) leakage at cervicothoracic junctions on day 30 after the second EBP therapy (white arrows); C: MRM shows multiple sites of CSF leakage in the thoracic region on day 30 after the second EBP therapy (white arrows); D: Sagittal CT myelography imaging of the entire spine reveals no obvious CSF leakage on day 57 after the third EBP therapy.

MRI has facilitated the recognition of IH. The typical imaging features of IH on MRI include subdural fluid collections, engorgement of venous structures, pachymeningeal enhancement, pituitary hyperemia and sagging of the brain. Although not as conclusive as MRI, CT can be of significant diagnostic value in detecting SDH, particularly in the emergency department setting[11]. In this case, repeated CT was used to detect SDH and monitor the intracranial lesions, facilitating the diagnosis and treatment of IH. If there is a high clinical suspicion of IH but normal MRI or CT findings, radioisotope cisternography or CT myelography may be the next modality of choice to pinpoint sites of CSF leakage. Furthermore, MRM is a developing cutting-edge technology that was used in our case, serving as an alternative to CT myelography. This male patient presented with diplopia and a non-orthostatic headache. MRM of the entire spinal column revealed multiple sites of CSF leakage, and brain CT showed bilateral SDHs. Hence, the diagnosis of IH complicated with cranial nerve VI paralysis and SDHs was clear in this patient.

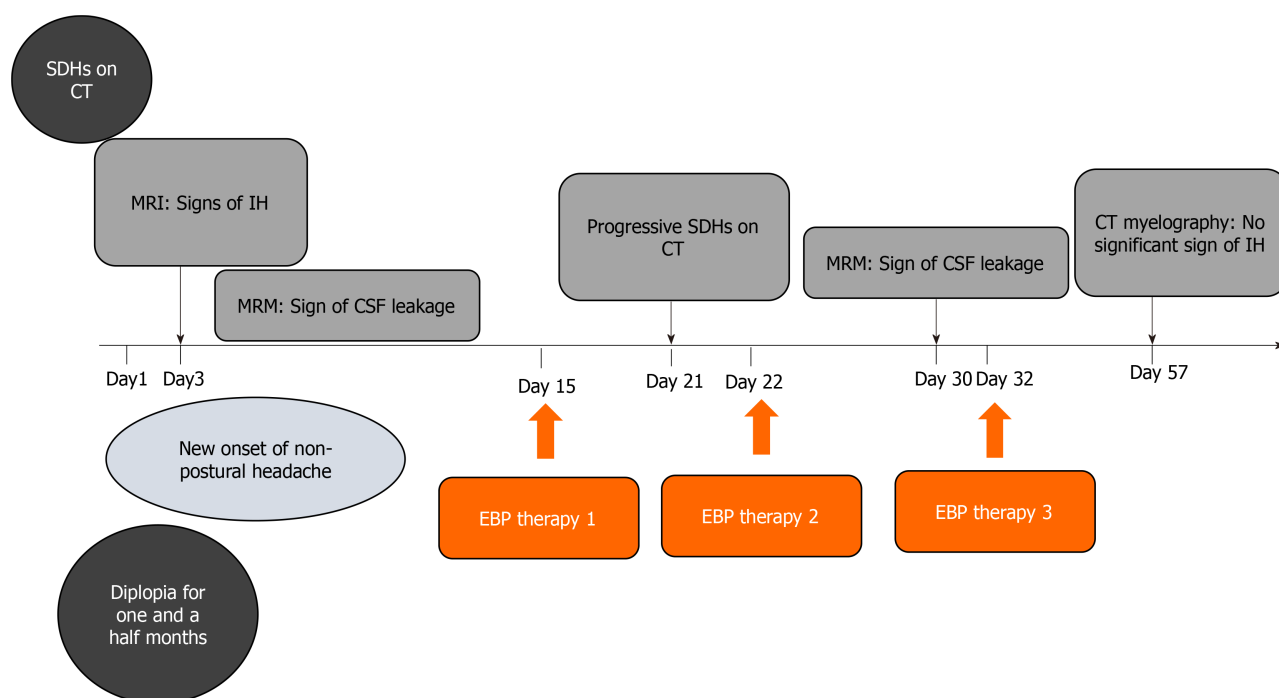
The treatment strategy for IH consists of conservative schemes such as bed rest, intravenous hydration, caffeine intake and invasive therapies, including EBP therapy and surgery. However, there is a lack of systematic studies on therapeutic methods and outcomes in IH patients with both cranial nerve VI palsy and SDH. We provide a review of published reports describing IH as an explicit cause of SDH and abducens nerve paralysis (Table 1). As shown in the chart, conservative treatment always fails to yield persistent improvement in such patients, and currently, whether to perform surgical SDH evacuation or EBP therapy as the initial procedure is still controversial [12,13]. Through the review of those reports above and other published reports, we believe that IH patients with both SDH and cranial nerve injury require emergency surgery under the following conditions: Moderate to large hematoma causing brain

**Table 1** Summary of reported cases of intracranial hypotension with subdural hematoma and diplopia

Case No.	Ref.	Age in yr/sex	Presenting symptoms			Positive imaging findings	Subdural hematoma eva. and outcome	IH treatment	Outcome
			Postural headache	Diplopia	Consciousness disturbance				
1	Takahashi <i>et al</i> [6], 2016	49/M	√	√	√	BSDH, DME, DOCT, NOC	√ × 2, trans imp	EBP × 2	Near FR
2	Veeravagu <i>et al</i> [17], 2013	36/M	√	√	√	Spur, DME, DOOC, SOT, Large BSDH, MS	√ + osteophyte repair	EBP, trans imp	Near FR
3	Fiala <i>et al</i> [12], 2012	28 /F	√	√		BSDH, thrombosis after EBP <sup>1</sup>		EBP × 1	FR
4	Slowinski <i>et al</i> [20], 2003	38 /F	√	√		Thick BSDH	√		FR
5	Whiteley <i>et al</i> [13], 2003	62/M	√	√	√	Large BSDH, DME	√ × 2, trans imp	EBP × 1	FR
6	Velarde <i>et al</i> [10], 2000	58/M	√	√		Thin BSDH		EBP × 1	FR
7	Welch <i>et al</i> [22], 1959	69/M	NP H/A	√	√	NA	√ <sup>2</sup>		Dead

<sup>1</sup>Low molecular heparin therapy after epidural blood patch.<sup>2</sup>Bilateral subdural blood was found during the operation.

BSDH: Bilateral subdural hematomas; DME: Diffuse meningeal enhancement; DOCT: Descent of the cerebellar tonsil; DOOC: Draping of the optic chiasm; EBP: Epidural blood patch; Eva: Evacuation; F: Female; FR: Full recovery; IH: Intracranial hypotension; M: Male; MS: Midline shift; NA: Not available; NOC: Narrowing of the cistern; NP H/A: Non-positional headache; SDH: Subdural hematoma; SOT: Sagging of the tons; trans imp: Transiently improved.

**Figure 4** shows the medical history chronologically. CSF: Cerebrospinal fluid; CT: Computed tomography; EBP: Epidural blood patch; IH: Intracranial hypotension; MRI: Magnetic resonance imaging; MRM: Magnetic resonance myelography; SDH: Subdural hematoma.

hernia and neurological deterioration[14], failure to improve after applying the Trendelenburg position in comatose SDH patients with a mass effect and pupil dilation[6], and progressive SDH or rapid cognitive deterioration after EBP therapy[15, 16]. Furthermore, surgical repair is indispensable in patients with evidence of cranial

or spinal anatomic abnormalities (*i.e.* osteophytes, arachnoid cyst congenital abnormalities, *etc.*) to prevent the recurrence of IH[9,17]. In terms of this case, we gave preference to repeated EBP therapy due to these reasons. First, EBP therapy is proven to be effective in relieving symptoms in 90% of cases, and if symptoms can be ameliorated after EBP therapy, even a thick SDH could resolve spontaneously[18,19]. Second, conservative treatment failed in our patient, and although the follow-up CT image showed SDH progression after the first EBP procedure, his symptoms did not worsen. We decided to perform a second EBP procedure in consideration of his stable conditions and multiple sites of CSF leakage. In addition, although we found a case of recovery after surgical evacuation without EBP therapy[20], many authors believe that empirical EBP therapy after surgical evacuation could treat the underlying cause of SDH and therefore minimize the risk of relapse[5,6,21]. Moreover, our literature search yielded a report of mortality after surgery and mentioned the possibility of pneumonia and cerebral infarction as postoperative complications[22]. Loya *et al*[5] summarized that in most cases, surgical correction is not inevitable and may bring about deteriorated outcomes[5]. Thus, EBP therapy may be a priority since it is much safer, with less adverse reactions. Last, compared with injecting blood into multiple targeted sites of CSF leakage at one time, putting the patient at a risk of deterioration after EBP therapy due to ICP elevation[16], it is safer to perform repeated targeted EBP procedures after some interval of time with careful follow-up.

## CONCLUSION

When a patient presents with diplopia and SDH on CT, the clinician should perform a comprehensive examination to search for even subtle evidence of IH. Once IH is confirmed, EBP therapy may be a priority in such patients, except under emergency conditions necessitating surgical evacuation.

## ACKNOWLEDGEMENTS

The authors thank Zhong-Feng Niu for assistance with figure preparation.

## REFERENCES

- 1 Santos JP, Silva AM, Velasco RM, Freitas MJ. Lumbar epidural blood patch for the treatment of spontaneous intracranial hypotension. *J Clin Anesth* 2020; **60**: 11 [PMID: 31437588 DOI: 10.1016/j.jclinane.2019.08.014]
- 2 Spears RC. Low-pressure/spinal fluid leak headache. *Curr Pain Headache Rep* 2014; **18**: 425 [PMID: 24760494 DOI: 10.1007/s11916-014-0425-4]
- 3 Malloy KA, Chigbu DI. Ocular manifestations uncover chronic subdural hematoma secondary to abuse. *Optometry* 2010; **81**: 61-70 [PMID: 20152779 DOI: 10.1016/j.optm.2009.10.011]
- 4 Pannullo SC, Reich JB, Krol G, Deck MD, Posner JB. MRI changes in intracranial hypotension. *Neurology* 1993; **43**: 919-926 [PMID: 8492946 DOI: 10.1212/wnl.43.5.919]
- 5 Loya JJ, Mindea SA, Yu H, Venkatasubramanian C, Chang SD, Burns TC. Intracranial hypotension producing reversible coma: a systematic review, including three new cases. *J Neurosurg* 2012; **117**: 615-628 [PMID: 22725982 DOI: 10.3171/2012.4.JNS112030]
- 6 Takahashi K, Mima T, Akiba Y. Chronic Subdural Hematoma Associated with Spontaneous Intracranial Hypotension: Therapeutic Strategies and Outcomes of 55 Cases. *Neurol Med Chir (Tokyo)* 2016; **56**: 69-76 [PMID: 26489406 DOI: 10.2176/nmc.oe.2015-0032]
- 7 Hashizume K, Watanabe K, Kawaguchi M, Fujiwara A, Furuya H. Evaluation on a clinical course of subdural hematoma in patients undergoing epidural blood patch for spontaneous cerebrospinal fluid leak. *Clin Neurol Neurosurg* 2013; **115**: 1403-1406 [PMID: 23462186 DOI: 10.1016/j.clineuro.2013.01.022]
- 8 Chung SJ, Lee JH, Kim SJ, Kwun BD, Lee MC. Subdural hematoma in spontaneous CSF hypovolemia. *Neurology* 2006; **67**: 1088-1089 [PMID: 17000987 DOI: 10.1212/01.wnl.0000237338.44702.61]
- 9 Yoon SH, Chung YS, Yoon BW, Kim JE, Paek SH, Kim DG. Clinical experiences with spontaneous intracranial hypotension: a proposal of a diagnostic approach and treatment. *Clin Neurol Neurosurg* 2011; **113**: 373-379 [PMID: 21292390 DOI: 10.1016/j.clineuro.2010.12.015]
- 10 Velarde CA, Zuniga RE, Leon RF, Abram SE. Cranial nerve palsy and intracranial subdural hematoma following implantation of intrathecal drug delivery device. *Reg Anesth Pain Med* 2000; **25**: 76-78 [PMID: 10660246 DOI: 10.1016/s1098-7339(00)80016-4]



- 11 **Schievink WI.** Spontaneous spinal cerebrospinal fluid leaks. *Cephalalgia* 2008; **28**: 1345-1356 [DOI: [10.1111/j.1468-2982.2008.01776.x](https://doi.org/10.1111/j.1468-2982.2008.01776.x)]
- 12 **Fiala A, Furgler G, Baumgartner E, Paal P.** Delayed subdural haematoma complicated by abducens nerve palsy and cortical vein thrombosis after obstetric epidural anaesthesia. *Br J Anaesth* 2012; **108**: 705-706 [PMID: [22419635](https://pubmed.ncbi.nlm.nih.gov/22419635/) DOI: [10.1093/bja/aes089](https://doi.org/10.1093/bja/aes089)]
- 13 **Whiteley W, Al-Shahi R, Myles L, Lueck CJ.** Spontaneous intracranial hypotension causing confusion and coma: a headache for the neurologist and the neurosurgeon. *Br J Neurosurg* 2003; **17**: 456-458 [PMID: [14635752](https://pubmed.ncbi.nlm.nih.gov/14635752/) DOI: [10.1080/02688690310001611251](https://doi.org/10.1080/02688690310001611251)]
- 14 **Bullock MR, Chesnut R, Ghajar J, Gordon D, Hartl R, Newell DW, Servadei F, Walters BC, Wilberger JE; Surgical Management of Traumatic Brain Injury Author Group.** Surgical management of acute subdural hematomas. *Neurosurgery* 2006; **58**: S16-24; discussion S1 [PMID: [16710968](https://pubmed.ncbi.nlm.nih.gov/16710968/)]
- 15 **Takeuchi S, Takasato Y, Masaoka H, Hayakawa T, Otani N, Yoshino Y, Yatsushige H, Sugawara T.** Progressive subdural hematomas after epidural blood patch for spontaneous intracranial hypotension. *J Anesth* 2010; **24**: 315-316 [PMID: [20127121](https://pubmed.ncbi.nlm.nih.gov/20127121/) DOI: [10.1007/s00540-009-0853-1](https://doi.org/10.1007/s00540-009-0853-1)]
- 16 **Matsuoka K, Nakai E, Kawanishi Y, Kadota T, Fukuda H, Ueba T.** Acute Deterioration in a Patient with Bilateral Chronic Subdural Hematomas Associated with Intracranial Hypotension Treated with an Epidural Blood Patch. *World Neurosurg* 2020; **141**: 331-334 [PMID: [32522646](https://pubmed.ncbi.nlm.nih.gov/32522646/) DOI: [10.1016/j.wneu.2020.05.254](https://doi.org/10.1016/j.wneu.2020.05.254)]
- 17 **Veeravagu A, Gupta G, Jiang B, Berta SC, Mindea SA, Chang SD.** Spontaneous intracranial hypotension secondary to anterior thoracic osteophyte: Resolution after primary dural repair via posterior approach. *Int J Surg Case Rep* 2013; **4**: 26-29 [PMID: [23108168](https://pubmed.ncbi.nlm.nih.gov/23108168/) DOI: [10.1016/j.ijscr.2012.06.009](https://doi.org/10.1016/j.ijscr.2012.06.009)]
- 18 **Groen RJ, Hoogland PV.** Spontaneous intracranial hypotension. *J Neurosurg* 2010; **113**: 685-8; author reply 688 [PMID: [20597599](https://pubmed.ncbi.nlm.nih.gov/20597599/) DOI: [10.3171/2010.4.JNS10480](https://doi.org/10.3171/2010.4.JNS10480)]
- 19 **Schievink WI.** Spontaneous spinal cerebrospinal fluid leaks and intracranial hypotension. *JAMA* 2006; **295**: 2286-2296 [PMID: [16705110](https://pubmed.ncbi.nlm.nih.gov/16705110/) DOI: [10.1001/jama.295.19.2286](https://doi.org/10.1001/jama.295.19.2286)]
- 20 **Slowinski J, Szydlak W, Sanetra A, Kaminska I, Mrowka R.** Bilateral chronic subdural hematomas with neurologic symptoms complicating spinal anesthesia. *Reg Anesth Pain Med* 2003; **28**: 347-350 [PMID: [12945031](https://pubmed.ncbi.nlm.nih.gov/12945031/) DOI: [10.1016/s1098-7339\(03\)00180-9](https://doi.org/10.1016/s1098-7339(03)00180-9)]
- 21 **Wan Y, Xie J, Xie D, Xue Z, Wang Y, Yang S.** Clinical characteristics of 15 cases of chronic subdural hematomas due to spontaneous intracranial hypotension with spinal cerebrospinal fluid leak. *Acta Neurol Belg* 2016; **116**: 509-512 [PMID: [26769700](https://pubmed.ncbi.nlm.nih.gov/26769700/) DOI: [10.1007/s13760-016-0597-2](https://doi.org/10.1007/s13760-016-0597-2)]
- 22 **WELCH K.** Subdural hematoma following spinal anesthesia. *AMA Arch Surg* 1959; **79**: 49-51 [PMID: [13660599](https://pubmed.ncbi.nlm.nih.gov/13660599/) DOI: [10.1001/archsurg.1959.04320070053009](https://doi.org/10.1001/archsurg.1959.04320070053009)]





Published by **Baishideng Publishing Group Inc**  
7041 Koll Center Parkway, Suite 160, Pleasanton, CA 94566, USA

**Telephone:** +1-925-3991568

**E-mail:** [bpgoffice@wjgnet.com](mailto:bpgoffice@wjgnet.com)

**Help Desk:** <https://www.f6publishing.com/helpdesk>

<https://www.wjgnet.com>

