


# World Journal of *Clinical Cases*

*World J Clin Cases* 2021 August 16; 9(23): 6582-6963



## OPINION REVIEW

- 6582 COVID-19 pandemic, as experienced in the surgical service of a district hospital in Spain

*Pérez Lara FJ, Jimenez Martinez MB, Pozo Muñoz F, Fontalba Navas A, Garcia Cisneros R, Garcia Larrosa MJ, Garcia Delgado I, Callejon Gil MDM*

## REVIEW

- 6591 Beta-carotene and its protective effect on gastric cancer

*Chen QH, Wu BK, Pan D, Sang LX, Chang B*

- 6608 Liver transplantation during global COVID-19 pandemic

*Alfishawy M, Nso N, Nassar M, Ariyaratnam J, Bhuiyan S, Siddiqui RS, Li M, Chung H, Al Balakosy A, Alqassieh A, Fülöp T, Rizzo V, Daoud A, Soliman KM*

- 6624 Nonalcoholic fatty pancreas disease: An emerging clinical challenge

*Zhang CL, Wang JJ, Li JN, Yang Y*

## MINIREVIEWS

- 6639 Novel mechanism of hepatobiliary system damage and immunoglobulin G4 elevation caused by *Clonorchis sinensis* infection

*Zhang XH, Huang D, Li YL, Chang B*

- 6654 Intestinal microbiota participates in nonalcoholic fatty liver disease progression by affecting intestinal homeostasis

*Zhang Y, Li JX, Zhang Y, Wang YL*

- 6663 Theory and reality of antivirals against SARS-CoV-2

*Zhao B, Yang TF, Zheng R*

- 6674 Acute acalculous cholecystitis due to infectious causes

*Markaki I, Konsoula A, Markaki L, Spornovasilis N, Papadakis M*

## ORIGINAL ARTICLE

## Case Control Study

- 6686 Innate immunity – the hallmark of *Helicobacter pylori* infection in pediatric chronic gastritis

*Meliş LE, Mărginean CO, Săsară MO, Mocan S, Ghiga DV, Bogliş A, Duicu C*

## Retrospective Study

- 6698 Effects on newborns of applying bupivacaine combined with different doses of fentanyl for cesarean section

*Wang Y, Liu WX, Zhou XH, Yang M, Liu X, Zhang Y, Hai KR, Ye QS*

- 6705** Awake fiberoptic intubation and use of bronchial blockers in ankylosing spondylitis patients  
*Yang SZ, Huang SS, Yi WB, Lv WW, Li L, Qi F*
- 6717** Efficacy of different antibiotics in treatment of children with respiratory mycoplasma infection  
*Zhang MY, Zhao Y, Liu JF, Liu GP, Zhang RY, Wang LM*
- 6725** Expression of caspase-3 and hypoxia inducible factor 1 $\alpha$  in hepatocellular carcinoma complicated by hemorrhage and necrosis  
*Liang H, Wu JG, Wang F, Chen BX, Zou ST, Wang C, Luo SW*
- 6734** Increased morbidity and mortality of hepatocellular carcinoma patients in lower cost of living areas  
*Sempokuya T, Patel KP, Azawi M, Ma J, Wong LL*

**SYSTEMATIC REVIEWS**

- 6747** Safety of pancreatic surgery with special reference to antithrombotic therapy: A systematic review of the literature  
*Fujikawa T, Naito S*
- 6759** What paradigm shifts occurred in the management of acute diverticulitis during the COVID-19 pandemic? A scoping review  
*Gallo G, Ortenzi M, Grossi U, Di Tanna GL, Pata F, Guerrieri M, Sammarco G, Di Saverio S*

**CASE REPORT**

- 6768** Pylephlebitis — a rare complication of a fish bone migration mimicking metastatic pancreatic cancer: A case report  
*Bezerra S, França NJ, Mineiro F, Capela G, Duarte C, Mendes AR*
- 6775** Solitary seminal vesicle metastasis from ileal adenocarcinoma presenting with hematospermia: A case report  
*Cheng XB, Lu ZQ, Lam W, Yiu MK, Li JS*
- 6781** Hepatic abscess caused by esophageal foreign body misdiagnosed as cystadenocarcinoma by magnetic resonance imaging: A case report  
*Pan W, Lin LJ, Meng ZW, Cai XR, Chen YL*
- 6789** 2+0 CYP21A2 deletion carrier — a limitation of the genetic testing and counseling: A case report  
*Xi N, Song X, Wang XY, Qin SF, He GN, Sun LL, Chen XM*
- 6798** Psoriasis treatment using minimally manipulated umbilical cord-derived mesenchymal stem cells: A case report  
*Ahn H, Lee SY, Jung WJ, Pi J, Lee KH*
- 6804** Double intussusception in a teenage child with Peutz-Jeghers syndrome: A case report  
*Chiew J, Sambanthan ST, Mahendran HA*

- 6810** Nedaplatin-induced syndrome of inappropriate secretion of antidiuretic hormone: A case report and review of the literature  
*Tian L, He LY, Zhang HZ*
- 6816** Nasal metastases from neuroblastoma-a rare entity: Two case reports  
*Zhang Y, Guan WB, Wang RF, Yu WW, Jiang RQ, Liu Y, Wang LF, Wang J*
- 6824** Nocardiosis with diffuse involvement of the pleura: A case report  
*Wang P, Yi ML, Zhang CZ*
- 6832** Prenatal diagnosis of triphalangeal thumb-polysyndactyly syndrome by ultrasonography combined with genetic testing: A case report  
*Zhang SJ, Lin HB, Jiang QX, He SZ, Lyu GR*
- 6839** Blue LED as a new treatment to vaginal stenosis due pelvic radiotherapy: Two case reports  
*Barros D, Alvares C, Alencar T, Baqueiro P, Marianno A, Alves R, Lenzi J, Rezende LF, Lordelo P*
- 6846** Diverse microbiota in palatal radicular groove analyzed by Illumina sequencing: Four case reports  
*Tan XL, Chen X, Fu YJ, Ye L, Zhang L, Huang DM*
- 6858** Autism with dysphasia accompanied by mental retardation caused by *FOXP1* exon deletion: A case report  
*Lin SZ, Zhou XY, Wang WQ, Jiang K*
- 6867** *FGFR2-TSC22D1*, a novel *FGFR2* fusion gene identified in a patient with colorectal cancer: A case report  
*Kao XM, Zhu X, Zhang JL, Chen SQ, Fan CG*
- 6872** Trismus originating from rare fungal myositis in pterygoid muscles: A case report  
*Bi L, Wei D, Wang B, He JF, Zhu HY, Wang HM*
- 6879** Retroperitoneal laparoscopic partial nephrectomy for unilateral synchronous multifocal renal carcinoma with different pathological types: A case report  
*Xiao YM, Yang SK, Wang Y, Mao D, Duan FL, Zhou SK*
- 6886** Diffuse large B cell lymphoma originating from the maxillary sinus with skin metastases: A case report and review of literature  
*Usuda D, Izumida T, Terada N, Sangen R, Higashikawa T, Sekiguchi S, Tanaka R, Suzuki M, Hotchi Y, Shimozawa S, Tokunaga S, Osugi I, Katou R, Ito S, Asako S, Takagi Y, Mishima K, Kondo A, Mizuno K, Takami H, Komatsu T, Oba J, Nomura T, Sugita M, Kasamaki Y*
- 6900** Manifestation of acute peritonitis and pneumonedema in scrub typhus without eschar: A case report  
*Zhou XL, Ye QL, Chen JQ, Li W, Dong HJ*
- 6907** Uterine tumor resembling an ovarian sex cord tumor: A case report and review of literature  
*Zhou FF, He YT, Li Y, Zhang M, Chen FH*
- 6916** Dopamine agonist responsive burning mouth syndrome: Report of eight cases  
*Du QC, Ge YY, Xiao WL, Wang WF*

- 6922** Complete withdrawal of glucocorticoids after dupilumab therapy in allergic bronchopulmonary aspergillosis: A case report  
*Nishimura T, Okano T, Naito M, Tsuji C, Iwanaka S, Sakakura Y, Yasuma T, Fujimoto H, D'Alessandro-Gabazza CN, Oomoto Y, Kobayashi T, Gabazza EC, Ibata H*
- 6929** Sirolimus treatment for neonate with blue rubber bleb nevus syndrome: A case report  
*Yang SS, Yang M, Yue XJ, Tou JF*
- 6935** Combined thoracoscopic and laparoscopic approach to remove a large retroperitoneal compound paraganglioma: A case report  
*Liu C, Wen J, Li HZ, Ji ZG*
- 6943** Menetrier's disease and differential diagnosis: A case report  
*Wang HH, Zhao CC, Wang XL, Cheng ZN, Xie ZY*
- 6950** Post-salpingectomy interstitial heterotopic pregnancy after *in vitro* fertilization and embryo transfer: A case report  
*Wang Q, Pan XL, Qi XR*
- 6956** Ulnar nerve injury associated with displaced distal radius fracture: Two case reports  
*Yang JJ, Qu W, Wu YX, Jiang HJ*

**ABOUT COVER**

Editorial Board Member of *World Journal of Clinical Cases*, Luigi Valentino Berra, MD, Assistant Professor, Neurosurgeon, Department of Neurosurgery, Policlinico Umberto I - Sapienza Università di Roma, Roma 00161, Italy. luigivbe@tin.it

**AIMS AND SCOPE**

The primary aim of *World Journal of Clinical Cases* (WJCC, *World J Clin Cases*) is to provide scholars and readers from various fields of clinical medicine with a platform to publish high-quality clinical research articles and communicate their research findings online.

WJCC mainly publishes articles reporting research results and findings obtained in the field of clinical medicine and covering a wide range of topics, including case control studies, retrospective cohort studies, retrospective studies, clinical trials studies, observational studies, prospective studies, randomized controlled trials, randomized clinical trials, systematic reviews, meta-analysis, and case reports.

**INDEXING/ABSTRACTING**

The WJCC is now indexed in Science Citation Index Expanded (also known as SciSearch®), Journal Citation Reports/Science Edition, Scopus, PubMed, and PubMed Central. The 2021 Edition of Journal Citation Reports® cites the 2020 impact factor (IF) for WJCC as 1.337; IF without journal self cites: 1.301; 5-year IF: 1.742; Journal Citation Indicator: 0.33; Ranking: 119 among 169 journals in medicine, general and internal; and Quartile category: Q3. The WJCC's CiteScore for 2020 is 0.8 and Scopus CiteScore rank 2020: General Medicine is 493/793.

**RESPONSIBLE EDITORS FOR THIS ISSUE**

Production Editor: Jia-Hui Li; Production Department Director: Xiang Li; Editorial Office Director: Jin-Lei Wang.

**NAME OF JOURNAL**

*World Journal of Clinical Cases*

**ISSN**

ISSN 2307-8960 (online)

**LAUNCH DATE**

April 16, 2013

**FREQUENCY**

Thrice Monthly

**EDITORS-IN-CHIEF**

Dennis A Bloomfield, Sandro Vento, Bao-Gan Peng

**EDITORIAL BOARD MEMBERS**

<https://www.wjnet.com/2307-8960/editorialboard.htm>

**PUBLICATION DATE**

August 16, 2021

**COPYRIGHT**

© 2021 Baishideng Publishing Group Inc

**INSTRUCTIONS TO AUTHORS**

<https://www.wjnet.com/bpg/gerinfo/204>

**GUIDELINES FOR ETHICS DOCUMENTS**

<https://www.wjnet.com/bpg/GerInfo/287>

**GUIDELINES FOR NON-NATIVE SPEAKERS OF ENGLISH**

<https://www.wjnet.com/bpg/gerinfo/240>

**PUBLICATION ETHICS**

<https://www.wjnet.com/bpg/GerInfo/288>

**PUBLICATION MISCONDUCT**

<https://www.wjnet.com/bpg/gerinfo/208>

**ARTICLE PROCESSING CHARGE**

<https://www.wjnet.com/bpg/gerinfo/242>

**STEPS FOR SUBMITTING MANUSCRIPTS**

<https://www.wjnet.com/bpg/GerInfo/239>

**ONLINE SUBMISSION**

<https://www.f6publishing.com>





## Psoriasis treatment using minimally manipulated umbilical cord-derived mesenchymal stem cells: A case report

Hyunjun Ahn, Sang Yeon Lee, Won-Ju Jung, Jia Pi, Kye-Ho Lee

**ORCID number:** Hyunjun Ahn 0000-0002-5550-8325; Sang Yeon Lee 0000-0003-4394-6958; Won-Ju Jung 0000-0002-4966-3118; Jia Pi 0000-0001-7322-4003; Kye-Ho Lee 0000-0001-8241-6402.

**Author contributions:** Ahn H, Lee SY, Jung WJ and Lee KH designed the reports; Ahn H, Pi J and Jung WJ collected the patient's clinical data; Ahn H, Pi J and Jung WJ analyzed the data; Ahn H and Pi J wrote the manuscript; Lee KH provided professional advice and revised the manuscript; all authors issued final approval for the version to be submitted.

**Informed consent statement:** The patient involved in this study gave his written informed consent authorizing disclosure of his protected health information.

**Conflict-of-interest statement:** All authors have no conflicts of interest to declare.

**CARE Checklist (2016) statement:** The authors have read the CARE Checklist (2016), and the manuscript was prepared and revised according to the CARE Checklist (2016).

**Open-Access:** This article is an open-access article that was selected by an in-house editor and fully peer-reviewed by external

Hyunjun Ahn, Sang Yeon Lee, Jia Pi, Kye-Ho Lee, bio Beauty&Health Company (bBHC)-Stem Cell Treatment and Research Institute (STRI), Seoul 04420, South Korea

Hyunjun Ahn, Department of Functional Genomics, University of Science and Technology KRIIBB School, Deajeon 34113, South Korea

Won-Ju Jung, Stem Cell Treatment, 97.7 B&H Clinic, Seoul 04420, South Korea

**Corresponding author:** Kye-Ho Lee, PhD, Stem Cell Research, STRI, 72 UNvillage-gil Yongsan-gu, Seoul 04420, South Korea. [sylee@stc365.com](mailto:sylee@stc365.com)

### Abstract

#### BACKGROUND

Psoriasis is a chronic autoimmune disease that usually manifests as a red scaly epidermis, induration, and hyperproliferation of basal keratinocytes. About 2% of the world's population suffers from psoriasis but there are no clear therapeutics yet. Recently, mesenchymal stem cells (MSCs) have been regarded as a therapeutic alternative for autoimmune diseases, as they possess immunosuppressive effects without risks. Human umbilical cord-derived MSCs effectively regulate immune cells and are characterized by low immunogenicity, which has many advantages in treating immune diseases.

#### CASE SUMMARY

The patient was a 47-year-old male, diagnosed with psoriasis in 1995. He had received various treatments for 25 years, but the psoriatic condition was not significantly improved. He was given three rounds of minimally manipulated umbilical cord-derived MSCs over 2 wk. The erythema gradually disappeared. Three months after the 1<sup>st</sup> round, all erythema completely disappeared, and the psoriasis did not recur.

#### CONCLUSION

Minimally manipulated umbilical cord-derived MSC transplantation can potentially treat patients who suffer from psoriasis.

**Key Words:** Psoriasis; Umbilical cord-derived mesenchymal stem cells; Allogenic; Cell therapy; Minimal manipulation; Case report

©The Author(s) 2021. Published by Baishideng Publishing Group Inc. All rights reserved.

reviewers. It is distributed in accordance with the Creative Commons Attribution NonCommercial (CC BY-NC 4.0) license, which permits others to distribute, remix, adapt, build upon this work non-commercially, and license their derivative works on different terms, provided the original work is properly cited and the use is non-commercial. See: <http://creativecommons.org/licenses/by-nc/4.0/>

**Manuscript source:** Unsolicited manuscript

**Specialty type:** Medicine, research and experimental

**Country/Territory of origin:** South Korea

**Peer-review report's scientific quality classification**

Grade A (Excellent): 0  
Grade B (Very good): 0  
Grade C (Good): C, C  
Grade D (Fair): 0  
Grade E (Poor): 0

**Received:** January 13, 2021

**Peer-review started:** January 13, 2021

**First decision:** May 11, 2021

**Revised:** May 24, 2021

**Accepted:** July 6, 2021

**Article in press:** July 6, 2021

**Published online:** August 16, 2021

**P-Reviewer:** Leung PC, Onsun N

**S-Editor:** Gao CC

**L-Editor:** A

**P-Editor:** Ma YJ



**Core Tip:** In recent decades, interest in biomedical applications of mesenchymal stem cells (MSCs) has increased due to their anti-inflammatory, immunosuppressive, and immunomodulatory abilities. MSCs have been used to study a variety of human diseases without side effects. The human umbilical cord is an excellent source of MSCs. We sought to improve a patient's psoriatic condition by using minimally manipulated umbilical cord-derived MSCs. In this case study, we report the efficacy of the minimally manipulated umbilical cord-derived MSC therapy to treat a patient with psoriasis.

**Citation:** Ahn H, Lee SY, Jung WJ, Pi J, Lee KH. Psoriasis treatment using minimally manipulated umbilical cord-derived mesenchymal stem cells: A case report. *World J Clin Cases* 2021; 9(23): 6798-6803

**URL:** <https://www.wjgnet.com/2307-8960/full/v9/i23/6798.htm>

**DOI:** <https://dx.doi.org/10.12998/wjcc.v9.i23.6798>

## INTRODUCTION

Psoriasis is an incurable autoimmune disease exhibiting a wide spectrum of clinical symptoms. Psoriasis typically presents with a red scaly epidermis, induration, and hyperproliferation of basal keratinocytes[1]. This serious skin condition most commonly occurs on the head, upper limbs, hands, trunk, and lower limbs, though it can appear on any location. About 2% of the world's population suffers from psoriasis [1]. Despite the wide variety of treatment options available to treat psoriasis, there are currently no definitive treatment methods[2-4]. Therefore, there is a need for a treatment method that can replace the existing treatment methods.

Previous studies about the effectiveness of mesenchymal stem cells (MSCs) for patients with autoimmune diseases showed positive results because they have anti-inflammation and immunomodulation[5-8]. For this reason, studies using MSCs to treat psoriasis have been conducted[9-12]. As a result, the possibility of treating psoriasis using MSCs has been demonstrated. Previous case reports have shown that psoriasis did not recur after MSC treatment[11,12].

In this study, we present a safer and more effective treatment method than previous studies. It is well known that genetic mutations and aging-related modifications increase as the MSCs are cultured[13-15]. These results show the increasing occurrence of various risks, including tumor formation, and decreasing treatment effect. Therefore, we treated psoriasis using uncultured, minimally manipulated umbilical cord-derived (MM-UC)-MSCs. We evaluated the severity of psoriasis in the patient using the Psoriasis Area and Severity Index (PASI) and Dermatology Life Quality Index (DLQI)[16]. As a result of three rounds of MM-UC-MSCs transplantation, the PASI and DLQI score of the patient decreased from 9.9 to 1.7 and from 27 to 3, respectively. We confirmed that there were no side effects and no relapse during the 5-mo follow-up period. Therefore, in this case study, we report the efficacy of MM-UC-MSC therapy for a psoriasis patient.

## CASE PRESENTATION

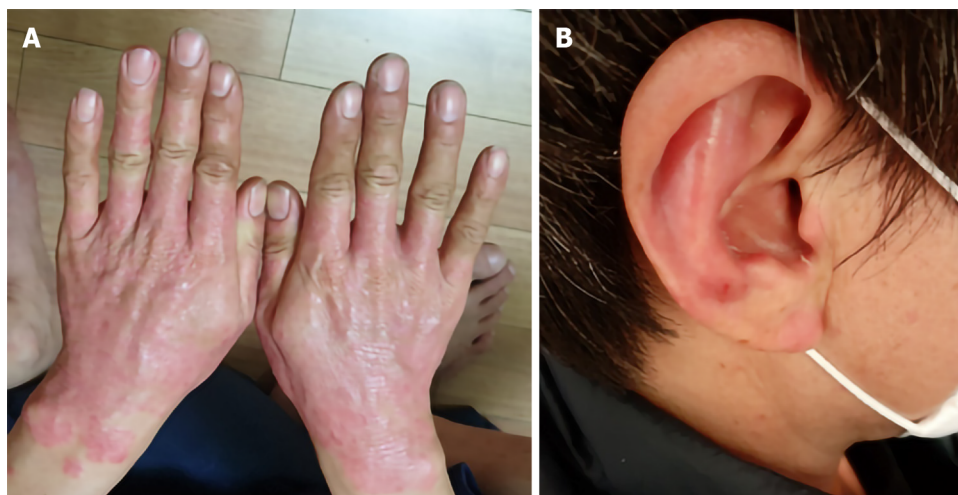### Chief complaints

On April 1, 2020, a 47-year-old man, suffering from psoriasis, visited our clinic. The patient had inflammation on the fingers, the backs of the hands, both wrists, and both ears. Erythema was widely spread on both hands, all fingers, and both wrists. Erythema was also found on the inside of the auricle and on the lower part of the earlobe (Figure 1A and B). Also, he complained of itchiness.

### History of present illness

He had been diagnosed with psoriasis in 1995. Subsequently, over the next 25 years, he had received herbal treatment, dermatological laser treatment, and drug treatment.





**Figure 1 Psoriasis lesion sites before treatment.** A: The psoriasis lesion sites on the hands and wrists before transplantation of minimally manipulated umbilical cord-derived mesenchymal stem cells (MM-UC-MSCs); B: The ear before transplantation of MM-UC-MSCs.

### ***History of past illness***

The patient has been no specific disease excepted psoriasis.

### ***Personal and family history***

The patient had no diseases personal and family histories.

### ***Physical examination***

When the patient visited the hospital, the lesion area was spread over several parts of the body.

### ***Laboratory examinations***

The severity of psoriasis was evaluated using the PASI and DLQI at the time of the patient's visit. The PASI and DLQI scores were 9.9 and 27, respectively.

---

## **FINAL DIAGNOSIS**

The patient was diagnosed with psoriasis based on the PASI score and previous diagnosis results.

---

## **TREATMENT**

### ***UC procurement***

Disinfected UCs were donated by the Obstetrics and Gynecology Department at Lynn Woman's Hospital. Informed consent was obtained from the mothers donating the umbilical cord. Seven blood and urine tests were performed on the mothers to confirm the safety of the UCs. These tests included assessment for hepatitis B surface antigen, hepatitis B surface antibody, hepatitis C antigen, hepatitis C antibody, human immunodeficiency virus, syphilis rapid plasma reagin, and human T-cell lymphotropic virus type I and II antibody.

### ***Isolation, quality evaluation, and preparation of MM-UC-MSCs***

The donated UCs were isolated, evaluated, and prepared as described in our former work[8,17]. Briefly, the UC tissues were ground and treated with a mixture of collagenase and hyaluronidase. After filtration, the cells were immediately frozen at -197 °C. Each UC produced  $2.5-7.0 \times 10^8$  cells. MSC expression was confirmed by detection of the markers CD73 (78.68%), CD90 (94.25%), and CD105 (93.72%) using a CyFlow® Cube 6 (Sysmex, Lincolnshire, IL, United States) and FCS Express 5 software (De Novo Software, Glendale, CA, United States). These expression markers were similar to our previous results of CD73 (70%-80%), CD90 (90%-100%), and CD105

(90%-100%). We also confirmed that the extracted cells are safe cells free from contamination by microorganisms or adventitious viruses (data not shown).

For local transplantation, the isolated cells were used at a concentration of  $1 \times 10^6$  cells/mL in 0.9% physiological saline. For intravenous transplantation, cells were used at a concentration of  $3 \times 10^6$  cells/mL in 0.9% physiological saline.

### Treatment

In the 1<sup>st</sup> round, the injection solution containing MM-UC-MSCs was transplanted intravenously and by local transplantation on April 1, 2020. For intravenous transplantation, a 10-mL injection solution containing MM-UC-MSCs was mixed with 100 mL of 0.9% sodium chloride injection, USP. Then, the 110 mL mixture was intravenously transplanted for 1-1.5 h. Immediately after the transplant was over, the same process was repeated once more. In the case of local transplantation, 12 Ultra-Fine™ II Insulin Syringes containing the injection solution were prepared. Each syringe containing the injection solution was injected in and around the lesion, at 2 cm intervals with 0.25 mL. The injected volume of injection solution for each hand and wrist was 4 mL, for each ear was 1 mL, and for the face was 2 mL. The 2<sup>nd</sup> and 3<sup>rd</sup> rounds were local transplantation only and were performed each at 1 wk intervals.

## OUTCOME AND FOLLOW-UP

At the 1<sup>st</sup> hospital visit on April 1, 2020, the severity of psoriasis was diagnosed using PASI and DLQI. The PASI score was 9.9. The extent of psoriasis was determined to be not severe, but the DLQI score was 27, indicating that the skin disease had an enormous influence on daily life. The PASI and DLQI score of the patient decreased from 9.9 to 1.7 and from 27 to 3, respectively, after 122 d from the 1<sup>st</sup> transplantation (Figure 2).

The erythema on both hands was slightly reduced, especially around the wrist area at day 7 after the 1<sup>st</sup> transplantation (Figure 3A). Itching also decreased, and exfoliation increased. After the 1<sup>st</sup> transplantation, the erythema gradually disappeared, and all erythema was almost resolved at day 122 after the 1<sup>st</sup> transplantation. Ultimately, the erythema was not observed on either hand, any fingers, or either wrist (Figure 3B). It was also confirmed that erythema of the ears was significantly reduced (Figure 3C).

### Report of side effects

The patient reported having experienced no adverse reactions or side effects, including dermatitis, fever, chills, or nausea.

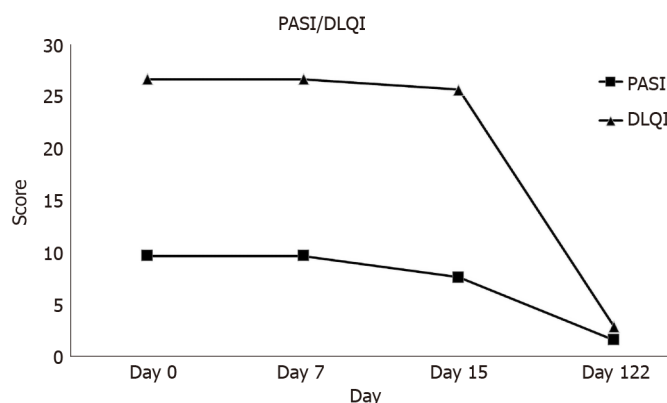
## DISCUSSION

Psoriasis is one of the autoimmune diseases that can reduced a patient's quality of life [2]. Currently, there is no adequate treatment for psoriasis[2-4]. Therefore, there is a need for a new treatment method for psoriasis.

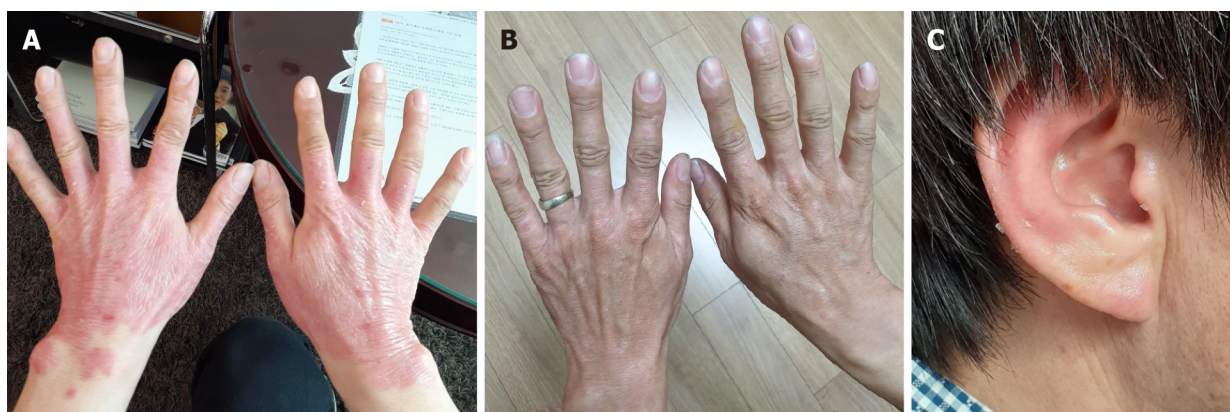
Previous studies have shown that MSCs may be a new alternative to psoriasis treatment[9-12]. However, previous studies have used cultured MSCs. It is well known that genetic mutations and aging-related modifications increase as the MSCs are cultured[13-15]. This results in an increase in the occurrence of various risks, including tumor formation and decreasing the treatment effect.

Here, we describe a case of psoriasis treated using MM-UC-MSCs. The MM-UC-MSCs safer materials than cultured MSCs because MM-UC-MSCs have few genetic mutations by expansion in vitro. Also, the MM-UC-MSCs are expected to be more effective materials than cultured MSCs because of no aging-related modifications[13-15]. The patient was transplanted with the MSCs three times at 1-wk intervals. The patient had not received any other therapies during or after the MM-UC-MSCs treatment. Gradual clearing of the erythema was observed 122 d from the 1<sup>st</sup> treatment. Follow-up for 5 mo showed the patient's psoriasis lesions to be mostly cleared. Interestingly, there was no significant change after the 1<sup>st</sup> and 2<sup>nd</sup> treatments. This result is hypothesized to be due to the time required for transplanted MM-UC-MSCs to engraft and function.

In general, treatment for psoriasis is aimed at a 75% improvement based on the PASI score[16]. In addition, there is a strong correlation between the PASI score, which represents severity of psoriasis, and the DLQI score, which represents quality of life.



**Figure 2 Graph for Psoriasis Area and Severity Index and Dermatology Life Quality Index score change in a patient with psoriasis according to the procedure outcomes.** DLQI: Dermatology Life Quality Index; PASI: Psoriasis Area and Severity Index.



**Figure 3 Visible changes at the lesion sites on the patient during and after treatment.** A and B: The erythema changes of both hands and wrist observed at day 15 (A) and day 122 (B) after the 1<sup>st</sup> transplant; C: The erythema of the ear lesion site at day 122 after the 1<sup>st</sup> transplant.

Therefore, a reduction in the PASI score of 75% or more can significantly improve the quality of life of the treated patient, which means that the treatment method is highly effective. In this study, the PASI score of the psoriasis patient treated by MM-UC-MSC transplantation decreased from 9.9 to 1.7 at day 122 after the 1<sup>st</sup> transplantation. During this period, the patient's DLQI score dropped from 27 to 3, confirming a significant improvement in quality of life as well.

In this patient, treatment of psoriasis by MM-UC-MSC transplantation was safe and effective. However, further studies should be performed in a larger number of patients with psoriasis and for a longer follow-up time to confirm our observations.

## CONCLUSION

Based on the PASI and DLQI scores, MM-UC-MSC transplantation had a great effect on treating psoriasis. After 5 mo, psoriasis did not recur and the patient did not report any side effects. Clinical trials with more patients and a longer follow-up time are needed before introducing this method as a safe and efficient psoriasis treatment.

## REFERENCES

- 1 Nestle FO, Kaplan DH, Barker J. Psoriasis. *N Engl J Med* 2009; **361**: 496-509 [PMID: 19641206 DOI: 10.1056/NEJMra0804595]
- 2 Greaves MW, Weinstein GD. Treatment of psoriasis. *N Engl J Med* 1995; **332**: 581-588 [PMID: 7838193 DOI: 10.1056/NEJM199503023320907]
- 3 Winterfield LS, Menter A, Gordon K, Gottlieb A. Psoriasis treatment: current and emerging directed therapies. *Ann Rheum Dis* 2005; **64** Suppl 2: ii87-90; discussion ii91 [PMID: 15708946 DOI: 10.1136/ard.2005.051187]

- 10.1136/ard.2004.032276]
- 4 **Radi G**, Campanati A, Diotallevi F, Bianchelli T, Offidani A. Novel Therapeutic Approaches and Targets for Treatment of Psoriasis. *Curr Pharm Biotechnol* 2021; **22**: 7-31 [PMID: [32598253](#) DOI: [10.2174/1389201021666200629150231](#)]
  - 5 **Deuse T**, Stubbendorff M, Tang-Quan K, Phillips N, Kay MA, Eiermann T, Phan TT, Volk HD, Reichenspurner H, Robbins RC, Schrepfer S. Immunogenicity and immunomodulatory properties of umbilical cord lining mesenchymal stem cells. *Cell Transplant* 2011; **20**: 655-667 [PMID: [21054940](#) DOI: [10.3727/096368910X536473](#)]
  - 6 **Le Blanc K**, Ringdén O. Immunomodulation by mesenchymal stem cells and clinical experience. *J Intern Med* 2007; **262**: 509-525 [PMID: [17949362](#) DOI: [10.1111/j.1365-2796.2007.01844.x](#)]
  - 7 **Song N**, Scholtemeijer M, Shah K. Mesenchymal Stem Cell Immunomodulation: Mechanisms and Therapeutic Potential. *Trends Pharmacol Sci* 2020; **41**: 653-664 [PMID: [32709406](#) DOI: [10.1016/j.tips.2020.06.009](#)]
  - 8 **Ahn H**, Lee SY, Jung WJ, Lee KH. Alopecia treatment using minimally manipulated human umbilical cord-derived mesenchymal stem cells: Three case reports and review of literature. *World J Clin Cases* 2021; **9**: 3741-3751 [PMID: [34046478](#) DOI: [10.12998/wjcc.v9.i15.3741](#)]
  - 9 **Owczarczyk-Saczonek A**, Krajewska-Włodarczyk M, Kruszevska A, Placek W, Maksymowicz W, Wojtkiewicz J. Stem Cells as Potential Candidates for Psoriasis Cell-Replacement Therapy. *Int J Mol Sci* 2017; **18** [PMID: [29053579](#) DOI: [10.3390/ijms18102182](#)]
  - 10 **Paganelli A**, Tarentini E, Benassi L, Kaleci S, Magnoni C. Mesenchymal stem cells for the treatment of psoriasis: a comprehensive review. *Clin Exp Dermatol* 2020; **45**: 824-830 [PMID: [32386432](#) DOI: [10.1111/ced.14269](#)]
  - 11 **Chen H**, Niu JW, Ning HM, Pan X, Li XB, Li Y, Wang DH, Hu LD, Sheng HX, Xu M, Zhang L, Zhang B. Treatment of Psoriasis with Mesenchymal Stem Cells. *Am J Med* 2016; **129**: e13-e14 [PMID: [26582058](#) DOI: [10.1016/j.amjmed.2015.11.001](#)]
  - 12 **Wang SG**, Hsu NC, Wang SM, Wang FN. Successful Treatment of Plaque Psoriasis with Allogeneic Gingival Mesenchymal Stem Cells: A Case Study. *Case Rep Dermatol Med* 2020; **2020**: 4617520 [PMID: [32280547](#) DOI: [10.1155/2020/4617520](#)]
  - 13 **Zhao J**, Wang J, Dang J, Zhu W, Chen Y, Zhang X, Xie J, Hu B, Huang F, Sun B, Bellanti JA, Zheng SG. A preclinical study-systemic evaluation of safety on mesenchymal stem cells derived from human gingiva tissue. *Stem Cell Res Ther* 2019; **10**: 165 [PMID: [31196163](#) DOI: [10.1186/s13287-019-1262-5](#)]
  - 14 **Bao X**, Wang J, Zhou G, Aszodi A, Schönlitzer V, Scherthan H, Atkinson MJ, Rosemann M. Extended in vitro culture of primary human mesenchymal stem cells downregulates Brca1-related genes and impairs DNA double-strand break recognition. *FEBS Open Bio* 2020; **10**: 1238-1250 [PMID: [32333827](#) DOI: [10.1002/2211-5463.12867](#)]
  - 15 **Liu J**, Ding Y, Liu Z, Liang X. Senescence in Mesenchymal Stem Cells: Functional Alterations, Molecular Mechanisms, and Rejuvenation Strategies. *Front Cell Dev Biol* 2020; **8**: 258 [PMID: [32478063](#) DOI: [10.3389/fcell.2020.00258](#)]
  - 16 **Mattei PL**, Corey KC, Kimball AB. Psoriasis Area Severity Index (PASI) and the Dermatology Life Quality Index (DLQI): the correlation between disease severity and psychological burden in patients treated with biological therapies. *J Eur Acad Dermatol Venereol* 2014; **28**: 333-337 [PMID: [23425140](#) DOI: [10.1111/jdv.12106](#)]
  - 17 **Tong CK**, Vellamy S, Tan BC, Abdullah M, Vidyadaran S, Seow HF, Ramasamy R. Generation of mesenchymal stem cell from human umbilical cord tissue using a combination enzymatic and mechanical disassociation method. *Cell Biol Int* 2011; **35**: 221-226 [PMID: [20946106](#) DOI: [10.1042/CBI20100326](#)]



Published by **Baishideng Publishing Group Inc**  
7041 Koll Center Parkway, Suite 160, Pleasanton, CA 94566, USA

**Telephone:** +1-925-3991568

**E-mail:** [bpgoffice@wjgnet.com](mailto:bpgoffice@wjgnet.com)

**Help Desk:** <https://www.f6publishing.com/helpdesk>

<https://www.wjgnet.com>

