


# World Journal of *Clinical Cases*

*World J Clin Cases* 2021 August 16; 9(23): 6582-6963



### OPINION REVIEW

- 6582 COVID-19 pandemic, as experienced in the surgical service of a district hospital in Spain

*Pérez Lara FJ, Jimenez Martinez MB, Pozo Muñoz F, Fontalba Navas A, Garcia Cisneros R, Garcia Larrosa MJ, Garcia Delgado I, Callejon Gil MDM*

### REVIEW

- 6591 Beta-carotene and its protective effect on gastric cancer

*Chen QH, Wu BK, Pan D, Sang LX, Chang B*

- 6608 Liver transplantation during global COVID-19 pandemic

*Alfishawy M, Nso N, Nassar M, Ariyaratnam J, Bhuiyan S, Siddiqui RS, Li M, Chung H, Al Balakosy A, Alqassieh A, Fülöp T, Rizzo V, Daoud A, Soliman KM*

- 6624 Nonalcoholic fatty pancreas disease: An emerging clinical challenge

*Zhang CL, Wang JJ, Li JN, Yang Y*

### MINIREVIEWS

- 6639 Novel mechanism of hepatobiliary system damage and immunoglobulin G4 elevation caused by *Clonorchis sinensis* infection

*Zhang XH, Huang D, Li YL, Chang B*

- 6654 Intestinal microbiota participates in nonalcoholic fatty liver disease progression by affecting intestinal homeostasis

*Zhang Y, Li JX, Zhang Y, Wang YL*

- 6663 Theory and reality of antivirals against SARS-CoV-2

*Zhao B, Yang TF, Zheng R*

- 6674 Acute acalculous cholecystitis due to infectious causes

*Markaki I, Konsoula A, Markaki L, Spornovasilis N, Papadakis M*

### ORIGINAL ARTICLE

#### Case Control Study

- 6686 Innate immunity – the hallmark of *Helicobacter pylori* infection in pediatric chronic gastritis

*Meliş LE, Mărginean CO, Săsară MO, Mocan S, Ghiga DV, Bogliş A, Duicu C*

#### Retrospective Study

- 6698 Effects on newborns of applying bupivacaine combined with different doses of fentanyl for cesarean section

*Wang Y, Liu WX, Zhou XH, Yang M, Liu X, Zhang Y, Hai KR, Ye QS*

- 6705** Awake fiberoptic intubation and use of bronchial blockers in ankylosing spondylitis patients  
*Yang SZ, Huang SS, Yi WB, Lv WW, Li L, Qi F*
- 6717** Efficacy of different antibiotics in treatment of children with respiratory mycoplasma infection  
*Zhang MY, Zhao Y, Liu JF, Liu GP, Zhang RY, Wang LM*
- 6725** Expression of caspase-3 and hypoxia inducible factor 1 $\alpha$  in hepatocellular carcinoma complicated by hemorrhage and necrosis  
*Liang H, Wu JG, Wang F, Chen BX, Zou ST, Wang C, Luo SW*
- 6734** Increased morbidity and mortality of hepatocellular carcinoma patients in lower cost of living areas  
*Sempokuya T, Patel KP, Azawi M, Ma J, Wong LL*

**SYSTEMATIC REVIEWS**

- 6747** Safety of pancreatic surgery with special reference to antithrombotic therapy: A systematic review of the literature  
*Fujikawa T, Naito S*
- 6759** What paradigm shifts occurred in the management of acute diverticulitis during the COVID-19 pandemic? A scoping review  
*Gallo G, Ortenzi M, Grossi U, Di Tanna GL, Pata F, Guerrieri M, Sammarco G, Di Saverio S*

**CASE REPORT**

- 6768** Pylephlebitis — a rare complication of a fish bone migration mimicking metastatic pancreatic cancer: A case report  
*Bezerra S, França NJ, Mineiro F, Capela G, Duarte C, Mendes AR*
- 6775** Solitary seminal vesicle metastasis from ileal adenocarcinoma presenting with hematospermia: A case report  
*Cheng XB, Lu ZQ, Lam W, Yiu MK, Li JS*
- 6781** Hepatic abscess caused by esophageal foreign body misdiagnosed as cystadenocarcinoma by magnetic resonance imaging: A case report  
*Pan W, Lin LJ, Meng ZW, Cai XR, Chen YL*
- 6789** 2+0 CYP21A2 deletion carrier — a limitation of the genetic testing and counseling: A case report  
*Xi N, Song X, Wang XY, Qin SF, He GN, Sun LL, Chen XM*
- 6798** Psoriasis treatment using minimally manipulated umbilical cord-derived mesenchymal stem cells: A case report  
*Ahn H, Lee SY, Jung WJ, Pi J, Lee KH*
- 6804** Double intussusception in a teenage child with Peutz-Jeghers syndrome: A case report  
*Chiew J, Sambanthan ST, Mahendran HA*

- 6810** Nedaplatin-induced syndrome of inappropriate secretion of antidiuretic hormone: A case report and review of the literature  
*Tian L, He LY, Zhang HZ*
- 6816** Nasal metastases from neuroblastoma-a rare entity: Two case reports  
*Zhang Y, Guan WB, Wang RF, Yu WW, Jiang RQ, Liu Y, Wang LF, Wang J*
- 6824** Nocardiosis with diffuse involvement of the pleura: A case report  
*Wang P, Yi ML, Zhang CZ*
- 6832** Prenatal diagnosis of triphalangeal thumb-polysyndactyly syndrome by ultrasonography combined with genetic testing: A case report  
*Zhang SJ, Lin HB, Jiang QX, He SZ, Lyu GR*
- 6839** Blue LED as a new treatment to vaginal stenosis due pelvic radiotherapy: Two case reports  
*Barros D, Alvares C, Alencar T, Baqueiro P, Marianno A, Alves R, Lenzi J, Rezende LF, Lordelo P*
- 6846** Diverse microbiota in palatal radicular groove analyzed by Illumina sequencing: Four case reports  
*Tan XL, Chen X, Fu YJ, Ye L, Zhang L, Huang DM*
- 6858** Autism with dysphasia accompanied by mental retardation caused by *FOXP1* exon deletion: A case report  
*Lin SZ, Zhou XY, Wang WQ, Jiang K*
- 6867** *FGFR2-TSC22D1*, a novel *FGFR2* fusion gene identified in a patient with colorectal cancer: A case report  
*Kao XM, Zhu X, Zhang JL, Chen SQ, Fan CG*
- 6872** Trismus originating from rare fungal myositis in pterygoid muscles: A case report  
*Bi L, Wei D, Wang B, He JF, Zhu HY, Wang HM*
- 6879** Retroperitoneal laparoscopic partial nephrectomy for unilateral synchronous multifocal renal carcinoma with different pathological types: A case report  
*Xiao YM, Yang SK, Wang Y, Mao D, Duan FL, Zhou SK*
- 6886** Diffuse large B cell lymphoma originating from the maxillary sinus with skin metastases: A case report and review of literature  
*Usuda D, Izumida T, Terada N, Sangen R, Higashikawa T, Sekiguchi S, Tanaka R, Suzuki M, Hotchi Y, Shimoizawa S, Tokunaga S, Osugi I, Katou R, Ito S, Asako S, Takagi Y, Mishima K, Kondo A, Mizuno K, Takami H, Komatsu T, Oba J, Nomura T, Sugita M, Kasamaki Y*
- 6900** Manifestation of acute peritonitis and pneumonedema in scrub typhus without eschar: A case report  
*Zhou XL, Ye QL, Chen JQ, Li W, Dong HJ*
- 6907** Uterine tumor resembling an ovarian sex cord tumor: A case report and review of literature  
*Zhou FF, He YT, Li Y, Zhang M, Chen FH*
- 6916** Dopamine agonist responsive burning mouth syndrome: Report of eight cases  
*Du QC, Ge YY, Xiao WL, Wang WF*

- 6922** Complete withdrawal of glucocorticoids after dupilumab therapy in allergic bronchopulmonary aspergillosis: A case report  
*Nishimura T, Okano T, Naito M, Tsuji C, Iwanaka S, Sakakura Y, Yasuma T, Fujimoto H, D'Alessandro-Gabazza CN, Oomoto Y, Kobayashi T, Gabazza EC, Ibata H*
- 6929** Sirolimus treatment for neonate with blue rubber bleb nevus syndrome: A case report  
*Yang SS, Yang M, Yue XJ, Tou JF*
- 6935** Combined thoracoscopic and laparoscopic approach to remove a large retroperitoneal compound paraganglioma: A case report  
*Liu C, Wen J, Li HZ, Ji ZG*
- 6943** Menetrier's disease and differential diagnosis: A case report  
*Wang HH, Zhao CC, Wang XL, Cheng ZN, Xie ZY*
- 6950** Post-salpingectomy interstitial heterotopic pregnancy after *in vitro* fertilization and embryo transfer: A case report  
*Wang Q, Pan XL, Qi XR*
- 6956** Ulnar nerve injury associated with displaced distal radius fracture: Two case reports  
*Yang JJ, Qu W, Wu YX, Jiang HJ*

**ABOUT COVER**

Editorial Board Member of *World Journal of Clinical Cases*, Luigi Valentino Berra, MD, Assistant Professor, Neurosurgeon, Department of Neurosurgery, Policlinico Umberto I - Sapienza Università di Roma, Roma 00161, Italy. luigivbe@tin.it

**AIMS AND SCOPE**

The primary aim of *World Journal of Clinical Cases* (WJCC, *World J Clin Cases*) is to provide scholars and readers from various fields of clinical medicine with a platform to publish high-quality clinical research articles and communicate their research findings online.

WJCC mainly publishes articles reporting research results and findings obtained in the field of clinical medicine and covering a wide range of topics, including case control studies, retrospective cohort studies, retrospective studies, clinical trials studies, observational studies, prospective studies, randomized controlled trials, randomized clinical trials, systematic reviews, meta-analysis, and case reports.

**INDEXING/ABSTRACTING**

The WJCC is now indexed in Science Citation Index Expanded (also known as SciSearch®), Journal Citation Reports/Science Edition, Scopus, PubMed, and PubMed Central. The 2021 Edition of Journal Citation Reports® cites the 2020 impact factor (IF) for WJCC as 1.337; IF without journal self cites: 1.301; 5-year IF: 1.742; Journal Citation Indicator: 0.33; Ranking: 119 among 169 journals in medicine, general and internal; and Quartile category: Q3. The WJCC's CiteScore for 2020 is 0.8 and Scopus CiteScore rank 2020: General Medicine is 493/793.

**RESPONSIBLE EDITORS FOR THIS ISSUE**

Production Editor: Jia-Hui Li; Production Department Director: Xiang Li; Editorial Office Director: Jin-Lei Wang.

**NAME OF JOURNAL**

*World Journal of Clinical Cases*

**ISSN**

ISSN 2307-8960 (online)

**LAUNCH DATE**

April 16, 2013

**FREQUENCY**

Thrice Monthly

**EDITORS-IN-CHIEF**

Dennis A Bloomfield, Sandro Vento, Bao-Gan Peng

**EDITORIAL BOARD MEMBERS**

<https://www.wjgnet.com/2307-8960/editorialboard.htm>

**PUBLICATION DATE**

August 16, 2021

**COPYRIGHT**

© 2021 Baishideng Publishing Group Inc

**INSTRUCTIONS TO AUTHORS**

<https://www.wjgnet.com/bpg/gerinfo/204>

**GUIDELINES FOR ETHICS DOCUMENTS**

<https://www.wjgnet.com/bpg/gerinfo/287>

**GUIDELINES FOR NON-NATIVE SPEAKERS OF ENGLISH**

<https://www.wjgnet.com/bpg/gerinfo/240>

**PUBLICATION ETHICS**

<https://www.wjgnet.com/bpg/gerinfo/288>

**PUBLICATION MISCONDUCT**

<https://www.wjgnet.com/bpg/gerinfo/208>

**ARTICLE PROCESSING CHARGE**

<https://www.wjgnet.com/bpg/gerinfo/242>

**STEPS FOR SUBMITTING MANUSCRIPTS**

<https://www.wjgnet.com/bpg/gerinfo/239>

**ONLINE SUBMISSION**

<https://www.f6publishing.com>



## Blue LED as a new treatment to vaginal stenosis due pelvic radiotherapy: Two case reports

Daniela Barros, Cecília Alvares, Teresa Alencar, Priscila Baqueiro, Augusto Marianno, Rafael Alves, Juliana Lenzi, Laura Ferreira Rezende, Patricia Lordelo

**ORCID number:** Daniela Barros 0000-0002-8218-9972; Cecília Alvares 0000-0003-2176-2250; Teresa Alencar 0000-0003-0149-2396; Priscila Baqueiro 0000-0003-1041-7371; Augusto Marianno 0000-0003-1255-1996; Rafael Alves 0000-0002-3601-1620; Juliana Lenzi 0000-0002-9454-0440; Laura Ferreira Rezende 0000-0002-3714-1558; Patricia Lordelo 0000-0002-5487-3080.

**Author contributions:** Barros D, Alencar T, Alvares C and Lordelo P contributed equally to this work; Barros D, Alencar T, Alvares C and Lordelo P drafted the manuscript; Baqueiro P, Marianno A and Alves R contributed to data acquisition; Barros D, Alencar T, Alvares C, Lordelo P, Lenzi J and Rezende LF contributed to data analysis and interpretation; all authors have read and approve the final manuscript.

**Informed consent statement:** All study participants provided informed written consent prior to study enrollment. We will be in accordance with Good Clinical Practice Guidelines and Declaration of Helsinki.

**Conflict-of-interest statement:** Lordelo P: Since she was the developers of the LED equipment (patent number INPI: BR 10 2017 026980 9), used in the present

Daniela Barros, Oncology Department, Hospital Santa Izabel, Salvador 40290-000, Brazil

Daniela Barros, Cecília Alvares, Teresa Alencar, Priscila Baqueiro, Augusto Marianno, Rafael Alves, Patricia Lordelo, Pelvic Floor Care Center (CAAP) and Postgraduate, Bahiana School of Medicine and Public Health, Salvador 40290-000, Brazil

Daniela Barros, Oncology Department, NOB/ Grupo Oncoclinicas, Salvador 40290-000, Brazil

Juliana Lenzi, Laura Ferreira Rezende, Pelvic Floor Care Center (CAAP), University Center of the Associated Teaching Faculties, Campinas 40000000, Brazil

Patricia Lordelo, Physiotherapy, Instituto Patricia Lordelo - IPL, Salvador 40290-000, Brazil

**Corresponding author:** Patricia Lordelo, PhD, Associate Professor, Physiotherapist, Postdoc, Pelvic Floor Care Center (CAAP) and Postgraduate, Bahiana School of Medicine and Public Health, Av Dom João VI, 256, Brotas, Salvador 40290-000, Brazil. [pvslordelo@hotmail.com](mailto:pvslordelo@hotmail.com)

### Abstract

#### BACKGROUND

Currently, the advancement cancer treatment technology improves overall survival, however, adverse events are still a challenge for health professional. Genitourinary syndrome of menopause and vaginal stenosis are conditions that impact the quality of life of patients undergoing radiotherapy. We present two such cases in patients with previous cervical and endometrial cancer. These conditions were handled with an innovative method using an energy-based device with blue light emitting diode for concomitant vaginal and vulvar irradiation. Positive impact in clinical findings, cytologic changes, and referred symptoms were documented.

#### CASE SUMMARY

One patient diagnosed with vaginal severe vaginal stenosis with previous cervix cancer treatment and other patient diagnosed with mild stenosis with severe dyspareunia and recent endometrium cancer treatment were considered for vulvovaginal treatment with weekly blue led device and closely evaluated with repeated validated questionnaires and cytological samples.

#### CONCLUSION

This innovative technique showed an improvement in all areas of the examiner's

study. It should be noted that the technology has already been transferred to the responsible industry. All other authors declare that there is no conflict.

#### CARE Checklist (2016) statement:

The authors have read the CARE Checklist (2016), and the manuscript was prepared and revised according to the CARE Checklist (2016).

**Open-Access:** This article is an open-access article that was selected by an in-house editor and fully peer-reviewed by external reviewers. It is distributed in accordance with the Creative Commons Attribution NonCommercial (CC BY-NC 4.0) license, which permits others to distribute, remix, adapt, build upon this work non-commercially, and license their derivative works on different terms, provided the original work is properly cited and the use is non-commercial. See: <http://creativecommons.org/licenses/by-nc/4.0/>

**Manuscript source:** Unsolicited manuscript

**Specialty type:** Oncology

**Country/Territory of origin:** Brazil

#### Peer-review report's scientific quality classification

Grade A (Excellent): 0  
Grade B (Very good): 0  
Grade C (Good): C  
Grade D (Fair): 0  
Grade E (Poor): 0

**Received:** February 22, 2021

**Peer-review started:** February 22, 2021

**First decision:** April 14, 2021

**Revised:** April 19, 2021

**Accepted:** July 13, 2021

**Article in press:** July 13, 2021

**Published online:** August 16, 2021

**P-Reviewer:** Cassell III AK

**S-Editor:** Yan JP

**L-Editor:** A

**P-Editor:** Wang LL



criteria, the cytological criteria, and most bothered symptoms.

**Key Words:** Radiotherapy; Atrophic vaginitis; Vaginal diseases; Laser therapy; Semiconductor diode lasers; Nonhormonal vaginal therapy; Case report

©The Author(s) 2021. Published by Baishideng Publishing Group Inc. All rights reserved.

**Core Tip:** Vaginal stenosis brings a negative impact on patients' quality of life, with permanent discomfort for cancer survivors. Energy based devices have emerged as non-hormonal treatments for vaginal disease. We present two cases of an innovative technique to treat this post radiotherapy complication.

**Citation:** Barros D, Alvares C, Alencar T, Baqueiro P, Marianno A, Alves R, Lenzi J, Rezende LF, Lordelo P. Blue LED as a new treatment to vaginal stenosis due pelvic radiotherapy: Two case reports. *World J Clin Cases* 2021; 9(23): 6839-6845

**URL:** <https://www.wjgnet.com/2307-8960/full/v9/i23/6839.htm>

**DOI:** <https://dx.doi.org/10.12998/wjcc.v9.i23.6839>

## INTRODUCTION

Pelvic radiotherapy is one of the fundamental strategies for gynecologic cancer control. However, despite all the stated benefits and technical advances as preservation of normal structures with intensity-modulated radiation therapy, a large portion of patients present long-term adverse events such as vaginal stenosis and secondary genitourinary syndrome of menopause (GSM)[1,2].

The pathophysiology of radiotherapy's secondary tissue damage is complex and is related to the process of disruption of tissue repair usually observed as disorderly deposition of the extracellular matrix, consequently fibrosis, and vascular disorders. Vaginal stenosis is a common complication that may occur in up to 50%-60% of women after 3 years of follow-up after a gynecologic cancer treated with radiotherapy [3].

Currently, a standardized method to prevent and treat long-term complications is not available. Hence, it is reasonable to keep searching for new effective non-drug and non-invasive therapeutic approaches. Recently, photobiomodulation therapy with lasers have demonstrated a definitive place in the treatment of vaginal diseases such GSM. However, it is a high-cost modality and still widely unavailable[4]. Photobiomodulation represents a potential emerging modality to change the management of tecidual disruptions, knowing that the blue LED has a repairing effect, feasible, and safe[5,6]. We proposed this innovative feature in the management of two cases of GSM after pelvic radiotherapy for gynecological cancer control. The objective of this study is to describe modifications in clinical features related to vaginal stenosis, sexual function, and quality of life. The case was conducted as part of a pilot study to calibrate a clinical trial, which was approved by the Ethics Committee with the No. CAAE-70078717.4.00005544, registered in ClinicalTrial.com with the No. NCT03833726, and performed after obtaining signatures on a consent form.

## CASE PRESENTATION

### Chief complaints

**Case 1:** A 58-year-old Caucasian woman, single, retired, with urinary and gynecological complaints started after previous cancer treatment.

**Case 2:** A 68-year-old woman with the chief complaint of dyspareunia with inability to maintain sexual intercourse.

### History of present illness

**Case 1:** Patient demonstrated previous medical history of perineoplasty surgery in 1993 and vaginal delivery with forceps, and developed histologically proven

squamous cell carcinoma of the cervix in 2003 (IIB, grade 2-International Federation of Gynecology and Obstetrics, FIGO 2002). For this neoplasm she received concurrent chemo- and non-conformal radiotherapy to 4500 cGy in 28 fractions from 60Co beams, with parallel-opposed fields, followed by two fractions of high-dose rate brachytherapy of 600cGy. In the following year, the patient underwent radical hysterectomy surgery due to persistent disease, with a ureter lesion during the procedure requiring a double-J stent.

**Case 2:** Patient presented a past medical history of menopause 15 years previously and histologically proven endometrioid adenocarcinoma of the uterus grade 1, IB (FIGO, 2009) treated in 2016 with radical hysterectomy and salpingo-oophorectomy followed by adjuvant pelvic intensity-modulated radiotherapy of 45 Gy in 25 fractions. In 2018, the patient was referred for pelvic physiotherapy due to urinary incontinence with evidence of detrusor hyperactivity, despite appropriate adherence, evaluated by urodynamic study. After that, in 2019, the patient developed severe complaints of pruritus, vaginal dryness and dyspareunia which affected her sexual activity and quality of life, despite the use of lubricants and polyethylene glycol moisturizers.

### **History of past illness**

**Case 1:** Only 10 years later, patient underwent ureter reimplantation, when mixed urinary incontinence was treated with pelvic physiotherapy and drug treatment composed of estradiol and testosterone vaginal gel and anticholinergics. The patient did not show good response to the treatment and abandoned the follow up. In 2017, the patient presented with severe complaints of vaginal dryness, pelvic pain, and pruritus and revealed the inability to have sexual intercourse since cancer diagnosis.

**Case 2:** There are no history of past illness in the case 2.

### **Personal and family history**

**Case 1:** There was no relevant family history of comorbidities.

**Case 2:** There was no relevant family history of cancer or other comorbidities.

### **Physical examination**

**Case 1:** During gynecological examination, extensive scarring of the left outer lip, atrophic aspect of the vulva, pale vaginal mucous membrane, and severe dryness with painful digital exam with vaginal stenosis grade 3 (Figure 1).

**Case 2:** During gynecological examination it was possible to observe an atrophic aspect of the vulva, pale vaginal mucous and a mild vaginal dryness and mild vaginal stenosis, unable to use a vaginal speculum, but possible two-finger touch.

### **Laboratory examinations**

**Case 1:** No additional laboratory evaluation was necessary.

**Case 2:** No additional laboratory evaluation was necessary and the patient presented normal tumor markers among the oncological follow-up exams.

### **Imaging examinations**

**Case 1:** No additional imaging evaluation was necessary.

**Case 2:** No additional imaging evaluation was necessary for the current diagnosis or decision regarding treatment, however, the patient had pelvic magnetic resonance imaging, in less than 3 mo without evidence of collections or recurrence of the neoplasm.

---

## **FINAL DIAGNOSIS**

---

### **Case 1**

Considering the clinical complaints and physical examination findings, the final diagnoses were vaginal stenosis and menopausal genitourinary syndrome, changes triggered by previous radiotherapy.

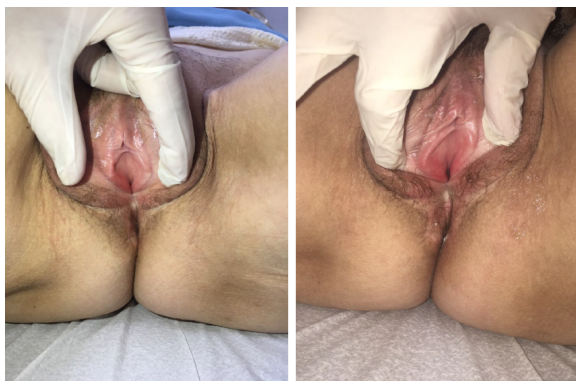

Figure 1 Pelvic inspection before and after 5 sessions of treatment (case 1).

### Case 2

The patient diagnosed with vaginal stenosis and menopausal genitourinary syndrome, changes triggered by previous radiotherapy urinary incontinence associated with detrusor hyperactivity.

---

## TREATMENT

### Case 1

The patient was treated with 10 sessions of intravaginal and extravaginal blue LED; each session was of 8 min and a wavelength of  $405 \pm 5$  nm, 30 W of power, and  $0.000773 \text{ W/cm}^2$  of irradiance with a blue LED, Energy model, DGM was used. The device was positioned in the dorsal recumbent position (Figure 2).

### Case 2

A smaller number of sessions has been proposed due to the lower severity of the condition compared to the first case and then, the patient was similarly treated with 5 sessions of intravaginal and extravaginal blue LED for 8 min each.

---

## OUTCOME AND FOLLOW-UP

### Case 1

The assessment of response to treatment was carried out through physical examination, vaginal maturation cell index[7,8], vaginal index of health[9], visual analogue scale[10], Female Sexual Function Index (FSFI)[11], and Likert scale of satisfaction, with documented improvement as seen in Table 1.

Reassessments and clinical follow-up were performed weekly during treatment with the physical examination and through standardized questionnaires, 1 wk after completion and after 1 mo.

### Case 2

Treatment outcomes were evaluated with the same resources as the previous patient, (physical examination, vaginal maturation cell index, vaginal index of health, visual analogue scale, FSFI, and Likert scale of satisfaction), and the results are presented in Table 1.

Revaluation was performed at the same time frame, after one month with reduction of dyspareunia and return of sexual intercourse.

---

## DISCUSSION

The anatomical and functional long-term sequelae of radiotherapy can be noticed by vascularity and lubrication reduction, loss of tissue elasticity, attenuation of the density of the vaginal wall, atrophy of the internal and external genitalia, and retraction of the vaginal introitus. Multiple mechanisms are involved in the emergence

**Table 1 Parameters of response to LED treatment**

	Case 1		Case 2	
	Previous	Post-treatment	Previous	Post-treatment
VIH	7	12	11	13
MCI	51	58.5	0	60
VAS-dryness	9	1	10	4
VAS-pruritus	9	1	0	0
VAS-burning	9	2	0	0
FSFI	12.5	21.4	14.9	16.4
Subscales				
Desire	3	3.6	2.4	2.4
Excitation	2.7	8.7	2.4	2.4
Lubrication	1.2	2.7	3.3	2.4
Orgasm	4.4	2	2.8	2.8
Satisfaction	1.2	1.6	2.4	3.6
Pain	0	2.8	1.6	2.8
Likert	-	5	-	5

Likert Scale of Satisfaction (0-5). VIH: Vaginal Index of Health (5-25); MCI: Maturation Cell Index (0-100, considering 0-49 severe atrophy, 50-64 discrete atrophy, > 65 normal); VAS: Visual analogue scale (0-10); FSFI: Female Sexual Function Index (2-36).

**Figure 2 Blue LED device, Energy model (DGM Eletronica®, Brazil).**

of this condition, such as fibrous effect and estrogen deprivation when the ovaries are in the field of radiotherapy, when concomitant chemotherapy is performed and affects gonadal functionality, or when oophorectomy is performed[1,2].

These changes have a negative impact on patients' quality of life, with permanent discomfort for cancer survivors, and are also most commonly associated with sexual dysfunction, dyspareunia, and post-coital bleeding[3,12]. Local measures such as the use of lubricants and moisturizers bring temporary and insignificant relief, with immediate benefit regression[4,12,13].

Extracavitary and intracavitary lasers, which emit light in a convergent and punctual manner, are currently available in some centers; however, protocols are yet to be established regarding the ideal duration of each session, number of sessions, and intervals between sessions[12,13].

Several studies have been conducted to investigate the cellular and molecular events that explain the effects of light and its various wavelength spectra on organic systems; although they have not been fully elucidated, it is postulated that these effects originate from absorption by endogenous chromophores, leading to an increase in the synthesis of adenosine triphosphates, cyclic adenosine monophosphates, nitric oxide,

and calcium ion[14].

Additionally, there is also a growing interest in opsins (OPN), which are potential photoreceptors for absorption in the visible violet-blue range (420 nm to 440 nm) present in the epidermis and human facial and abdominal dermis in situ and also expressed in newly regenerated tissue after the wound; moreover, they appear to be largely responsible for triggering cell signaling and the potential regenerative effect. Similarly, the decrease in OPNs leads to a reduction in the early differentiation of keratinocytes after irradiation with blue light, suggesting that OPNs are necessary for the restoration of epithelial tissue barrier function.

In addition, OPNs influence the intracellular redox state by modulating the tissue repair process, assisting in the modulation of fibroblasts and production of collagen, which suggests its potential in the prevention and treatment of tissue fibrosis[14,15].

The 405 nm blue LED has already been studied in tissues with histological similarity to the genital region, such as in gastric and oral mucosa, with circulatory and regenerative benefits demonstrated by several authors, including pain improvement and inflammatory process resolution[16,17]. Oh *et al*[5] demonstrated blue LED at a wavelength of 450 nm and power of 6.3 mW/cm<sup>2</sup> for 30 min inhibited the migration and invasion of cancer cells with anti-metastatic and anti-proliferative effects on spontaneous lung metastases in mice.

Pavie *et al*[6] demonstrated the safety of LED on normal vaginal mucosa, demonstrating safety and good tolerance with no adverse events. This opened up perspectives for the use of blue LED for other disorders.

A recent study conducted by García *et al*[18] used LED in three colors and wavelengths alternately (blue-415 nm, red-660 nm, and infrared-850 nm) to treat 30 pre- and post-menopausal women with symptoms of vaginal dryness related to vaginal atrophy. After 12 sessions (divided into two applications per week, of three min each), they observed increases in the vaginal health index, FSFI questionnaire, vascularity, tissue thickness, and urethra-vaginal distance, which reflected a reduction in tissue laxity.

The patients in the present cases treated with this innovative technique showed an improvement in all areas of the examiner's criteria as genital pale or erythema, vaginal dryness and fragility, the cytological criteria, and those referred by the patients. The patients did not report any discomfort during the application, and they did not have any short-term adverse effects. Since the nature of the biological effects of blue light photobiomodulation (PBM) on cells still lacks comprehensive research, the underlying signaling and differences between blue light PBM and others wavelengths remain elusive. Understanding the function and relationship of different photoreceptors and their response to specific light parameters will lead to the development of reliable, light-based therapies for the healing of skin wounds.

## CONCLUSION

In conclusion, intravaginal blue LED treatment demonstrated a promising tolerance and potential to become the treatment option for long-term sequelae in cancer survivors with apparent low toxicity. Clinical trials are required to evaluate late safety and efficacy in patients with restricted therapeutic arsenal.

## REFERENCES

- 1 Simonds H. Long Term Complications of Pelvic Radiotherapy. *South Afr Gynecol Oncol* 2010; **2**: 62-65
- 2 Vistad I, Cvancarova M, Fosså SD, Kristensen GB. Postradiotherapy morbidity in long-term survivors after locally advanced cervical cancer: how well do physicians' assessments agree with those of their patients? *Int J Radiat Oncol Biol Phys* 2008; **71**: 1335-1342 [PMID: 18355976 DOI: 10.1016/j.ijrobp.2007.12.030]
- 3 Damast S, Jeffery DD, Son CH, Hasan Y, Carter J, Lindau ST, Jhingran A. Literature Review of Vaginal Stenosis and Dilator Use in Radiation Oncology. *Pract Radiat Oncol* 2019; **9**: 479-491 [PMID: 31302301 DOI: 10.1016/j.prro.2019.07.001.]
- 4 Arunkalaivanan A, Kaur H, Onuma O. Laser therapy as a treatment modality for genitourinary syndrome of menopause: a critical appraisal of evidence. *Int Urogynecol J* 2017; **28**: 681-685 [PMID: 28154914 DOI: 10.1007/s00192-017-3282-y]
- 5 Oh PS, Kim HS, Kim EM, Hwang H, Ryu HH, Lim S, Sohn MH, Jeong HJ. Inhibitory effect of blue light emitting diode on migration and invasion of cancer cells. *J Cell Physiol* 2017; **232**: 3444-3453

- [PMID: [28098340](#) DOI: [10.1002/jcp.25805](#)]
- 6 **Pavie MC**, Robatto M, Bastos M, Tozetto S, Boas AV, Vitale SG, Lordelo P. Blue light-emitting diode in healthy vaginal mucosa-a new therapeutic possibility. *Lasers Med Sci* 2019; **34**: 921-927 [PMID: [30406341](#) DOI: [10.1007/s10103-018-2678-3](#)]
  - 7 **Nilsson K**, Risberg B, Heimer G. The vaginal epithelium in the postmenopause--cytology, histology and pH as methods of assessment. *Maturitas* 1995; **21**: 51-56 [PMID: [7731384](#) DOI: [10.1016/0378-5122\(94\)00863-3](#)]
  - 8 **Hess R**, Austin RM, Dillon S, Chang CC, Ness RB. Vaginal maturation index self-sample collection in mid-life women: acceptability and correlation with physician-collected samples. *Menopause* 2008; **15**: 726-729 [PMID: [18427354](#) DOI: [10.1097/gme.0b013e31816c5541](#)]
  - 9 **Greendale GA**, Zibecchi L, Petersen L, Ouslander JG, Kahn B, Ganz PA. Development and validation of a physical examination scale to assess vaginal atrophy and inflammation. *Climacteric* 1999; **2**: 197-204 [PMID: [11910597](#) DOI: [10.3109/13697139909038062](#)]
  - 10 **Simon JA**, Archer DF, Kagan R, Bernick B, Graham S, Constantine GD, Mirkin S. Visual improvements in vaginal mucosa correlate with symptoms of VVA: data from a double-blind, placebo-controlled trial. *Menopause* 2017; **24**: 1003-1010 [PMID: [28419068](#) DOI: [10.1097/GME.0000000000000880](#)]
  - 11 **Hentschel H**, Alberton DL, Sawdy RJ, Capp E, Goldim JR, Passos EP. Sexual function in women from infertile couples and in women seeking surgical sterilization. *J Sex Marital Ther* 2008; **34**: 107-114 [PMID: [18224546](#) DOI: [10.1080/00926230701636171](#)]
  - 12 **Chism LA**, Magnan MA. Talking to cancer survivors about dyspareunia and self-management. *Nursing* 2017; **47**: 24-29 [PMID: [28863037](#) DOI: [10.1097/01.NURSE.0000524751.97634.65](#)]
  - 13 **Huffman LB**, Hartenbach EM, Carter J, Rash JK, Kushner DM. Maintaining sexual health throughout gynecologic cancer survivorship: A comprehensive review and clinical guide. *Gynecol Oncol* 2016; **140**: 359-368 [PMID: [26556768](#) DOI: [10.1016/j.ygyno.2015.11.010](#)]
  - 14 **de Freitas LF**, Hamblin MR. Proposed Mechanisms of Photobiomodulation or Low-Level Light Therapy. *IEEE J Sel Top Quantum Electron* 2016; **22** [PMID: [28070154](#) DOI: [10.1109/JSTQE.2016.2561201](#)]
  - 15 **Vladimirov YA**, Osipov AN, Klebanov GI. Photobiological principles of therapeutic applications of laser radiation. *Biochemistry (Mosc)* 2004; **69**: 81-90 [PMID: [14972023](#) DOI: [10.1023/b:biry.0000016356.93968.7e](#)]
  - 16 **de Carvalho FB**, Andrade AS, Rasquin LC, de Castro IV, Cangussu MC, Pinheiro AL, dos Santos JN. Effect of laser ( $\lambda$  660 nm) and LED ( $\lambda$  630 nm) photobiomodulation on formocresol-induced oral ulcers: a clinical and histological study on rodents. *Lasers Med Sci* 2015; **30**: 389-396 [PMID: [25354753](#) DOI: [10.1007/s10103-014-1680-7](#)]
  - 17 **Takada A**, Matsushita K, Horioka S, Furuichi Y, Sumi Y. Bactericidal effects of 310 nm ultraviolet light-emitting diode irradiation on oral bacteria. *BMC Oral Health* 2017; **17**: 96 [PMID: [28587675](#) DOI: [10.1186/s12903-017-0382-5](#)]
  - 18 **García PN**, Elias JA, Parada JG, Lucíañez DZ, Pinto H. Management of Vaginal Atrophy with Intravaginal Light-Emitting Diodes (LEDs). *IJOGR* 2018; **5**: 632-636



Published by **Baishideng Publishing Group Inc**  
7041 Koll Center Parkway, Suite 160, Pleasanton, CA 94566, USA

**Telephone:** +1-925-3991568

**E-mail:** [bpgoffice@wjgnet.com](mailto:bpgoffice@wjgnet.com)

**Help Desk:** <https://www.f6publishing.com/helpdesk>

<https://www.wjgnet.com>

