


# World Journal of *Clinical Cases*

*World J Clin Cases* 2021 August 16; 9(23): 6582-6963



## Contents

Thrice Monthly Volume 9 Number 23 August 16, 2021

## OPINION REVIEW

- 6582 COVID-19 pandemic, as experienced in the surgical service of a district hospital in Spain

*Pérez Lara FJ, Jimenez Martinez MB, Pozo Muñoz F, Fontalba Navas A, Garcia Cisneros R, Garcia Larrosa MJ, Garcia Delgado I, Callejon Gil MDM*

## REVIEW

- 6591 Beta-carotene and its protective effect on gastric cancer

*Chen QH, Wu BK, Pan D, Sang LX, Chang B*

- 6608 Liver transplantation during global COVID-19 pandemic

*Alfishawy M, Nso N, Nassar M, Ariyaratnam J, Bhuiyan S, Siddiqui RS, Li M, Chung H, Al Balakosy A, Alqassieh A, Fülöp T, Rizzo V, Daoud A, Soliman KM*

- 6624 Nonalcoholic fatty pancreas disease: An emerging clinical challenge

*Zhang CL, Wang JJ, Li JN, Yang Y*

## MINIREVIEWS

- 6639 Novel mechanism of hepatobiliary system damage and immunoglobulin G4 elevation caused by *Clonorchis sinensis* infection

*Zhang XH, Huang D, Li YL, Chang B*

- 6654 Intestinal microbiota participates in nonalcoholic fatty liver disease progression by affecting intestinal homeostasis

*Zhang Y, Li JX, Zhang Y, Wang YL*

- 6663 Theory and reality of antivirals against SARS-CoV-2

*Zhao B, Yang TF, Zheng R*

- 6674 Acute acalculous cholecystitis due to infectious causes

*Markaki I, Konsoula A, Markaki L, Spornovasilis N, Papadakis M*

## ORIGINAL ARTICLE

## Case Control Study

- 6686 Innate immunity – the hallmark of *Helicobacter pylori* infection in pediatric chronic gastritis

*Meliş LE, Mărginean CO, Săsară MO, Mocan S, Ghiga DV, Bogliş A, Duicu C*

## Retrospective Study

- 6698 Effects on newborns of applying bupivacaine combined with different doses of fentanyl for cesarean section

*Wang Y, Liu WX, Zhou XH, Yang M, Liu X, Zhang Y, Hai KR, Ye QS*

- 6705** Awake fiberoptic intubation and use of bronchial blockers in ankylosing spondylitis patients  
*Yang SZ, Huang SS, Yi WB, Lv WW, Li L, Qi F*
- 6717** Efficacy of different antibiotics in treatment of children with respiratory mycoplasma infection  
*Zhang MY, Zhao Y, Liu JF, Liu GP, Zhang RY, Wang LM*
- 6725** Expression of caspase-3 and hypoxia inducible factor 1 $\alpha$  in hepatocellular carcinoma complicated by hemorrhage and necrosis  
*Liang H, Wu JG, Wang F, Chen BX, Zou ST, Wang C, Luo SW*
- 6734** Increased morbidity and mortality of hepatocellular carcinoma patients in lower cost of living areas  
*Sempokuya T, Patel KP, Azawi M, Ma J, Wong LL*

**SYSTEMATIC REVIEWS**

- 6747** Safety of pancreatic surgery with special reference to antithrombotic therapy: A systematic review of the literature  
*Fujikawa T, Naito S*
- 6759** What paradigm shifts occurred in the management of acute diverticulitis during the COVID-19 pandemic? A scoping review  
*Gallo G, Ortenzi M, Grossi U, Di Tanna GL, Pata F, Guerrieri M, Sammarco G, Di Saverio S*

**CASE REPORT**

- 6768** Pylephlebitis — a rare complication of a fish bone migration mimicking metastatic pancreatic cancer: A case report  
*Bezerra S, França NJ, Mineiro F, Capela G, Duarte C, Mendes AR*
- 6775** Solitary seminal vesicle metastasis from ileal adenocarcinoma presenting with hematospermia: A case report  
*Cheng XB, Lu ZQ, Lam W, Yiu MK, Li JS*
- 6781** Hepatic abscess caused by esophageal foreign body misdiagnosed as cystadenocarcinoma by magnetic resonance imaging: A case report  
*Pan W, Lin LJ, Meng ZW, Cai XR, Chen YL*
- 6789** 2+0 CYP21A2 deletion carrier — a limitation of the genetic testing and counseling: A case report  
*Xi N, Song X, Wang XY, Qin SF, He GN, Sun LL, Chen XM*
- 6798** Psoriasis treatment using minimally manipulated umbilical cord-derived mesenchymal stem cells: A case report  
*Ahn H, Lee SY, Jung WJ, Pi J, Lee KH*
- 6804** Double intussusception in a teenage child with Peutz-Jeghers syndrome: A case report  
*Chiew J, Sambanthan ST, Mahendran HA*

- 6810** Nedaplatin-induced syndrome of inappropriate secretion of antidiuretic hormone: A case report and review of the literature  
*Tian L, He LY, Zhang HZ*
- 6816** Nasal metastases from neuroblastoma-a rare entity: Two case reports  
*Zhang Y, Guan WB, Wang RF, Yu WW, Jiang RQ, Liu Y, Wang LF, Wang J*
- 6824** Nocardiosis with diffuse involvement of the pleura: A case report  
*Wang P, Yi ML, Zhang CZ*
- 6832** Prenatal diagnosis of triphalangeal thumb-polysyndactyly syndrome by ultrasonography combined with genetic testing: A case report  
*Zhang SJ, Lin HB, Jiang QX, He SZ, Lyu GR*
- 6839** Blue LED as a new treatment to vaginal stenosis due pelvic radiotherapy: Two case reports  
*Barros D, Alvares C, Alencar T, Baqueiro P, Marianno A, Alves R, Lenzi J, Rezende LF, Lordelo P*
- 6846** Diverse microbiota in palatal radicular groove analyzed by Illumina sequencing: Four case reports  
*Tan XL, Chen X, Fu YJ, Ye L, Zhang L, Huang DM*
- 6858** Autism with dysphasia accompanied by mental retardation caused by *FOXP1* exon deletion: A case report  
*Lin SZ, Zhou XY, Wang WQ, Jiang K*
- 6867** *FGFR2-TSC22D1*, a novel *FGFR2* fusion gene identified in a patient with colorectal cancer: A case report  
*Kao XM, Zhu X, Zhang JL, Chen SQ, Fan CG*
- 6872** Trismus originating from rare fungal myositis in pterygoid muscles: A case report  
*Bi L, Wei D, Wang B, He JF, Zhu HY, Wang HM*
- 6879** Retroperitoneal laparoscopic partial nephrectomy for unilateral synchronous multifocal renal carcinoma with different pathological types: A case report  
*Xiao YM, Yang SK, Wang Y, Mao D, Duan FL, Zhou SK*
- 6886** Diffuse large B cell lymphoma originating from the maxillary sinus with skin metastases: A case report and review of literature  
*Usuda D, Izumida T, Terada N, Sangen R, Higashikawa T, Sekiguchi S, Tanaka R, Suzuki M, Hotchi Y, Shimoizawa S, Tokunaga S, Osugi I, Katou R, Ito S, Asako S, Takagi Y, Mishima K, Kondo A, Mizuno K, Takami H, Komatsu T, Oba J, Nomura T, Sugita M, Kasamaki Y*
- 6900** Manifestation of acute peritonitis and pneumonedema in scrub typhus without eschar: A case report  
*Zhou XL, Ye QL, Chen JQ, Li W, Dong HJ*
- 6907** Uterine tumor resembling an ovarian sex cord tumor: A case report and review of literature  
*Zhou FF, He YT, Li Y, Zhang M, Chen FH*
- 6916** Dopamine agonist responsive burning mouth syndrome: Report of eight cases  
*Du QC, Ge YY, Xiao WL, Wang WF*

- 6922** Complete withdrawal of glucocorticoids after dupilumab therapy in allergic bronchopulmonary aspergillosis: A case report  
*Nishimura T, Okano T, Naito M, Tsuji C, Iwanaka S, Sakakura Y, Yasuma T, Fujimoto H, D'Alessandro-Gabazza CN, Oomoto Y, Kobayashi T, Gabazza EC, Ibata H*
- 6929** Sirolimus treatment for neonate with blue rubber bleb nevus syndrome: A case report  
*Yang SS, Yang M, Yue XJ, Tou JF*
- 6935** Combined thoracoscopic and laparoscopic approach to remove a large retroperitoneal compound paraganglioma: A case report  
*Liu C, Wen J, Li HZ, Ji ZG*
- 6943** Menetrier's disease and differential diagnosis: A case report  
*Wang HH, Zhao CC, Wang XL, Cheng ZN, Xie ZY*
- 6950** Post-salpingectomy interstitial heterotopic pregnancy after *in vitro* fertilization and embryo transfer: A case report  
*Wang Q, Pan XL, Qi XR*
- 6956** Ulnar nerve injury associated with displaced distal radius fracture: Two case reports  
*Yang JJ, Qu W, Wu YX, Jiang HJ*

**ABOUT COVER**

Editorial Board Member of *World Journal of Clinical Cases*, Luigi Valentino Berra, MD, Assistant Professor, Neurosurgeon, Department of Neurosurgery, Policlinico Umberto I - Sapienza Università di Roma, Roma 00161, Italy. luigivbe@tin.it

**AIMS AND SCOPE**

The primary aim of *World Journal of Clinical Cases* (WJCC, *World J Clin Cases*) is to provide scholars and readers from various fields of clinical medicine with a platform to publish high-quality clinical research articles and communicate their research findings online.

WJCC mainly publishes articles reporting research results and findings obtained in the field of clinical medicine and covering a wide range of topics, including case control studies, retrospective cohort studies, retrospective studies, clinical trials studies, observational studies, prospective studies, randomized controlled trials, randomized clinical trials, systematic reviews, meta-analysis, and case reports.

**INDEXING/ABSTRACTING**

The WJCC is now indexed in Science Citation Index Expanded (also known as SciSearch®), Journal Citation Reports/Science Edition, Scopus, PubMed, and PubMed Central. The 2021 Edition of Journal Citation Reports® cites the 2020 impact factor (IF) for WJCC as 1.337; IF without journal self cites: 1.301; 5-year IF: 1.742; Journal Citation Indicator: 0.33; Ranking: 119 among 169 journals in medicine, general and internal; and Quartile category: Q3. The WJCC's CiteScore for 2020 is 0.8 and Scopus CiteScore rank 2020: General Medicine is 493/793.

**RESPONSIBLE EDITORS FOR THIS ISSUE**

Production Editor: Jia-Hui Li; Production Department Director: Xiang Li; Editorial Office Director: Jin-Lei Wang.

**NAME OF JOURNAL**

*World Journal of Clinical Cases*

**ISSN**

ISSN 2307-8960 (online)

**LAUNCH DATE**

April 16, 2013

**FREQUENCY**

Thrice Monthly

**EDITORS-IN-CHIEF**

Dennis A Bloomfield, Sandro Vento, Bao-Gan Peng

**EDITORIAL BOARD MEMBERS**

<https://www.wjnet.com/2307-8960/editorialboard.htm>

**PUBLICATION DATE**

August 16, 2021

**COPYRIGHT**

© 2021 Baishideng Publishing Group Inc

**INSTRUCTIONS TO AUTHORS**

<https://www.wjnet.com/bpg/gerinfo/204>

**GUIDELINES FOR ETHICS DOCUMENTS**

<https://www.wjnet.com/bpg/GerInfo/287>

**GUIDELINES FOR NON-NATIVE SPEAKERS OF ENGLISH**

<https://www.wjnet.com/bpg/gerinfo/240>

**PUBLICATION ETHICS**

<https://www.wjnet.com/bpg/GerInfo/288>

**PUBLICATION MISCONDUCT**

<https://www.wjnet.com/bpg/gerinfo/208>

**ARTICLE PROCESSING CHARGE**

<https://www.wjnet.com/bpg/gerinfo/242>

**STEPS FOR SUBMITTING MANUSCRIPTS**

<https://www.wjnet.com/bpg/GerInfo/239>

**ONLINE SUBMISSION**

<https://www.f6publishing.com>





## Autism with dysphasia accompanied by mental retardation caused by *FOXP1* exon deletion: A case report

Shuang-Zhu Lin, Xin-Yu Zhou, Wan-Qi Wang, Kai Jiang

**ORCID number:** Shuang-Zhu Lin 0000-0001-5333-2138; Xin-Yu Zhou 0000-0003-0604-5480; Wan-Qi Wang 0000-0002-8247-7616; Kai Jiang 0000-0002-0194-9934.

**Author contributions:** Lin SZ and Zhou XY collected and analyzed all clinical data and wrote the manuscript; Lin SZ, Zhou XY, and Wang WQ substantially participated in drafting and revising the important intellectual content of the manuscript; All authors have read and approved the final manuscript.

**Supported by** Natural Science Foundation of Jilin Province, No. 20200201486JC.

**Informed consent statement:** The study participant had provided informed written consent prior to study enrollment.

**Conflict-of-interest statement:** All authors report no conflict of interest.

**CARE Checklist (2016) statement:** The authors have read the CARE Checklist (2016), and the manuscript was prepared and revised according to the CARE Checklist (2016).

**Open-Access:** This article is an open-access article that was selected by an in-house editor and

Shuang-Zhu Lin, Xin-Yu Zhou, Kai Jiang, Department of Diagnosis and Treatment Center for Children, First Affiliated Hospital to Changchun University of Chinese Medicine, Changchun 130021, Jilin Province, China

Wan-Qi Wang, Changchun University of Chinese Medicine, Changchun 130021, Jilin Province, China

**Corresponding author:** Kai Jiang, MD, Professor, Department of Diagnosis and Treatment Center for Children, First Affiliated Hospital to Changchun University of Chinese Medicine, No. 1478 Gongnong Road, Chaoyang District, Changchun 130021, Jilin Province, China. 2835221172@qq.com

### Abstract

#### BACKGROUND

Forkhead box protein 1 (*FOXP1*) (OMIM: 605515) at chromosomal region 3p14.1 plays an important regulatory role in cell development and functions by regulating genetic expression. Earlier studies have suggested that *FOXP1*, an oncogene, is capable of initiating tumorigenicity depending on the cell type. *FOXP1* also plays an important role in regulating the cell development and functions of the immune system, *e.g.*, regulating B-cell maturation and mononuclear phagocyte differentiation, and in the occurrence and development of various immune diseases. The mRNA of this gene is widely expressed in humans, and its differential expression is related to numerous diseases.

#### CASE SUMMARY

A 5-year-old boy mainly presented with attention deficit and hyperactivity disorder and developmental retardation accompanied by gait instability and abnormal facial features (low-set ears). DNA samples were extracted from the child's and his parents' peripheral blood to detect whole-exome sequences and whole-genome copy number variations. Results revealed heterozygous deletions of exon 6-21 of *FOXP1* gene in the child. Physical examination upon admission showed that the child was generally in good condition, had a moderate nutritional status, a slightly slow response to external stimuli, equally large and equally round bilateral pupils, was sensitive to light reflection, and had poor eye contact and joint attention. He had no meaningful utterance and could not pronounce words properly. He was able to use gestures to simply express his thoughts, to perform simple actions, and to listen to instructions. He had no rash, cafe-au-lait macules, or depigmentation spots. He had thick black hair and low-set

fully peer-reviewed by external reviewers. It is distributed in accordance with the Creative Commons Attribution NonCommercial (CC BY-NC 4.0) license, which permits others to distribute, remix, adapt, build upon this work non-commercially, and license their derivative works on different terms, provided the original work is properly cited and the use is non-commercial. See: <http://creativecommons.org/licenses/by-nc/4.0/>

**Manuscript source:** Unsolicited manuscript

**Specialty type:** Medicine, research and experimental

**Country/Territory of origin:** China

**Peer-review report's scientific quality classification**

Grade A (Excellent): 0  
Grade B (Very good): 0  
Grade C (Good): 0  
Grade D (Fair): 0  
Grade E (Poor): 0

**Received:** March 18, 2021

**Peer-review started:** March 18, 2021

**First decision:** May 11, 2021

**Revised:** May 24, 2021

**Accepted:** June 15, 2021

**Article in press:** June 15, 2021

**Published online:** August 16, 2021

**P-Reviewer:** Iourov I

**S-Editor:** Fan JR

**L-Editor:** Filipodia

**P-Editor:** Li JH



ears. He had highly sensitive skin, especially on his face and palms. He had no abnormal palm fingerprint. Cardiopulmonary and abdominal examinations revealed no abnormalities. He had normal limb muscle strength and tension. He showed normal tendon reflexes of both knees. His bilateral Babinski and meningeal irritation signs were negative. He had a normal male vulva.

## CONCLUSION

We report the characteristic features of autism with dysphasia accompanied by mental retardation caused by *FOXP1* exon deletion. This study provides a molecular basis for etiological diagnosis and treatment of the child, as well as for genetic counseling for the pedigree.

**Key Words:** Mental retardation; Developmental retardation; *FOXP1*; Genetic expression; Case report

©The Author(s) 2021. Published by Baishideng Publishing Group Inc. All rights reserved.

**Core Tip:** We report the characteristic features of autism with dysphasia accompanied by mental retardation caused by *FOXP1* exon deletion. In this case, the *FOXP1* gene of the child had a heterozygous deletion variation, and the mutation site was heterozygous deletion in exon 6-21. This study provides a molecular basis for etiological diagnosis and treatment of the child, as well as for genetic counseling for the pedigree.

**Citation:** Lin SZ, Zhou XY, Wang WQ, Jiang K. Autism with dysphasia accompanied by mental retardation caused by *FOXP1* exon deletion: A case report. *World J Clin Cases* 2021; 9(23): 6858-6866

**URL:** <https://www.wjgnet.com/2307-8960/full/v9/i23/6858.htm>

**DOI:** <https://dx.doi.org/10.12998/wjcc.v9.i23.6858>

## INTRODUCTION

Mental retardation accompanied by dysphasia in the absence or presence of autism (OMIM: 613670) is a developmental disease that manifests as mild to moderate mental retardation, dysphasia, and autism. This disease is clinically manifested by systemic developmental retardation, delay in walking and language, and behavior disorders including irritability, attention deficit and hyperactivity disorder (ADHD), aggression and stiff behavior. The occurrence of this disease is mainly affected by various factors such as heredity, immunity, and history of medications during pregnancy. Clinically, there are no specific drugs to treat this disease, and the normal physiological functions of a child can be primarily improved with combined training.

*Forkhead box protein 1* (*FOXP1*) (OMIM: 605515) at chromosomal region 3p14.1 plays an important regulatory role in cell development and functions by regulating genetic expression. *FOXP1*, an oncogene, is capable of initiating tumorigenicity depending on the cell type[1-3]. *FOXP1* also plays an important role in regulating the cell development and functions of the immune system, *e.g.*, regulating B-cell maturation and mononuclear phagocyte differentiation, and in the occurrence and development of various immune diseases[4,5]. The mRNA of this gene is widely expressed in humans, and its differential expression is related to numerous diseases. Therefore, diseases related to mutations at the genetic locus must be diagnosed in the early phase to be able to treat them in a timely manner.

## CASE PRESENTATION

### Chief complaints

A 5-year-old boy presented mainly with ADHD and developmental retardation accompanied by gait instability and abnormal facial features (low-set ears). DNA samples were extracted from the child's and his parents' peripheral blood to detect



whole-exome sequences and whole-genome copy number variations (CNVs). The results revealed heterozygous deletions of exon 6-21 of *FOXP1* gene in the child.

### ***History of present illness***

In 2018, a 3-year-old boy presented to our hospital with a 3-year history of developmental retardation. Since birth, the child had lagged behind in development; he had progressive improvements, could not pronounce words properly, could not utter any meaningful sentences, had symptoms of ADHD, and could perform only simple actions. The child learned to sit when he was aged approximately 9 mo. He could crawl when he was 1-year-old and only learned to walk independently when he was 2-years-old. He was admitted to our hospital for etiological diagnosis and treatment. Now, the child has ADHD, developmental retardation, gait instability, and low-set ears.

### ***History of past illness***

The child was his parents' first. He was delivered by cesarean section at term, with a birth weight of 3.35 kg and a body length of 50 cm. He had no birth trauma or puerperal tetany, but he had a history of amniotic infection and jaundice for 1 mo. No obvious reason could be proposed for his developmental retardation with progressive improvements. The child had a normal diet without preferences. Hydrocephalus and atrial septal defect were revealed during prenatal examination at 32 wk.

### ***Personal and family history***

The parents were in good health, and they denied consanguineous marriage and a history of familial inherited diseases.

### ***Physical examination***

Physical examination upon admission showed that the child was generally in good condition, had a moderate nutritional status, a slightly slow response to external stimuli, equally large and equally round bilateral pupils, was sensitive to light reflection, and had poor eye contact and joint attention. He had no meaningful utterance and could not pronounce words properly. He was able to use gestures to simply express his thoughts, to perform simple actions, and to listen to instructions. He had no rash, café-au-lait macules, or depigmentation spots. He had thick black hair and low-set ears. He had highly sensitive skin, especially on his face and palms. He had no abnormal palm fingerprint. Cardiopulmonary and abdominal examinations revealed no abnormalities. He had normal limb muscle strength and tension. He showed normal tendon reflexes of both knees. His bilateral Babinski and meningeal irritation signs were negative. He had a normal male vulva.

He exhibited restricted interest in common things and even had imaginary play with toys as a substitute for real things. He was capable of sitting and walking independently. He could pinch small pills with his thumb and forefinger and unscrew bottle caps. He could doodle with a pen in hand and build three layers of blocks. He showed uncoordinated walking movements. He was observed to easily fall. He was incapable of running, jumping.

### ***Laboratory examinations***

Auxiliary examinations were conducted. Head magnetic resonance imaging on September 3, 2018 revealed slight dilatation of the right ventricle, with inborn anomalies considered. Vacuole turcica electrocardiography showed trace tricuspid regurgitation (with physiological considerations).

### ***Imaging examinations***

Cardiac function and electroencephalography (EEG) found no abnormalities.

### ***Further diagnostic work-up***

Before treatment, the patient was rated according to the Autism Behavior Checklist (ABC), Gesell Developmental Schedules, and S-S Language Delay Assessment. He had an ABC score of 67 points on August 16, 2018. According to S-S Language Delay Assessment, the patient was categorized as Class I, with language delay, and the development level was about 2.0–2.5-years-old. According to Gesell Developmental Schedules, the patients had an adaptive development quotient of 44.13, with his language and personal-social skills severely lagging behind, and his other skills were moderately lagging behind.

The patient was preliminarily diagnosed with autism with dysphasia accompanied by mental retardation on the basis of his clinical manifestations and laboratory results. After regular rehabilitation treatment and functional exercises, his abilities in various fields developed: He could maintain eye contact; he could flexibly communicate every day using different sentence patterns; he could clearly articulate every note, although his speech was a little slow; he could perform two-step actions; and he could play simple drama games with adults familiar to him to reproduce life scenes, as well as perform parallel plays with peers without understanding the rules of the games. He is now capable of running, jumping, alternating his feet while going up and down the stairs, ride a scooter, build nine layers of blocks, and imitate circles, squares and crosses.

## MULTIDISCIPLINARY EXPERT CONSULTATION

In 2020, whole-exome sequencing (WES) and whole-genome sequencing analysis of CNVs were performed at our hospital to seek genetic counseling and clarify the etiology of the child's condition.

With the consent of the child's guardian, 2 mL peripheral blood was extracted for genomic DNA analysis. WES and whole-genome sequencing analysis of CNVs were done by MGExome. The distribution frequency of mutation sites of the genetic variations detected were referred to 1000 Genomes, ESP6500 (NHLBI Exome Sequencing Project), The Exome Aggregation Consortium (EXAC) and EXAC-EXAC data on about 4000 East Asians. The reported pathogenic loci were confirmed by referring to the Human Gene Mutation Database (<http://www.hgmd.cf.ac.uk>) and the Online Mendelian Inheritance in Man (<http://omim.org>). The pathogenicity of the variants was evaluated in accordance with the Guideline for Interpretation of Sequence Variants[6] published by the American College of Medical Genetics and Genomics (ACMG).

WES revealed a heterozygous deletion mutation in *FOXP1* of the child, and this mutation was located at exons 6-21 and indicated a heterozygous deletion (Figure 1). This mutation was a zero effect (exon deletion) that may have resulted in loss of function of the gene. Moreover, the frequency of the mutation was negative relative to normal. Hence, it was a low-frequency mutation. However, as revealed by the pedigree, no mutation at the locus of the child's father or mother was found (Figure 2). Thus, this mutation was spontaneous. According to the ACMG Guidelines, it was a pathogenic variant. No obvious genetic abnormalities were found in the CNV results.

## FINAL DIAGNOSIS

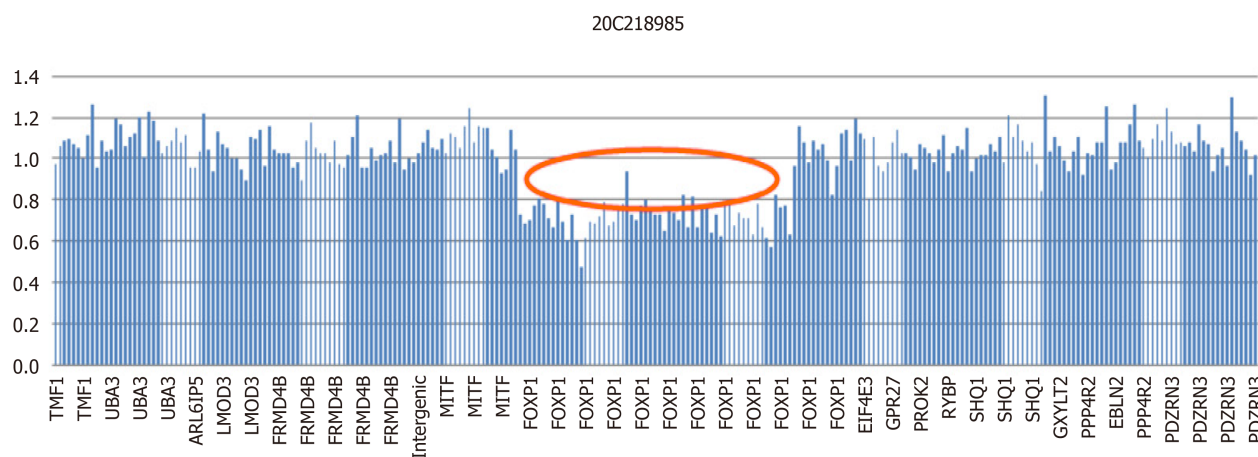
The final diagnosis of the presented case is autism with dysphasia accompanied by mental retardation due to the heterozygous deletions of exon 6-21 of *FOXP1* gene.

## TREATMENT

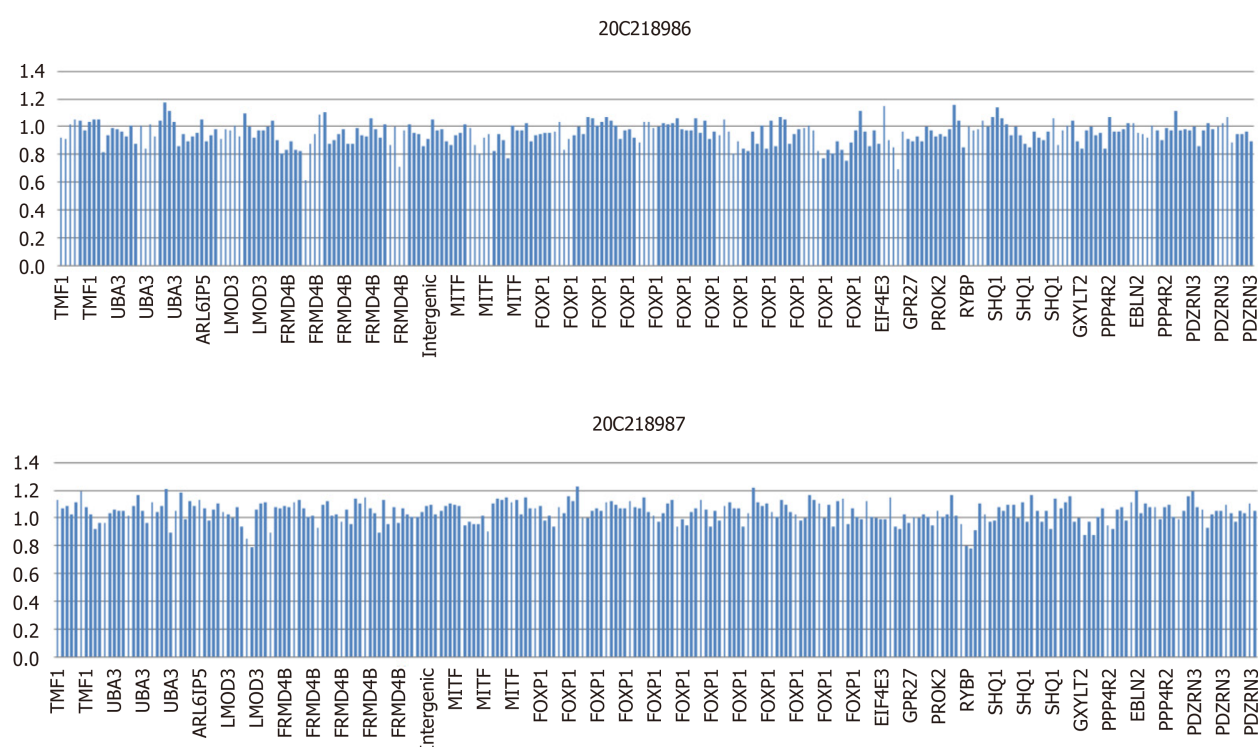
The patient, since his diagnosis, has been undergoing related speech and motor rehabilitation training in the hospital.

## OUTCOME AND FOLLOW-UP

After treatment, the patient remained in Class I of S-S Language Delay Assessment on March 5, 2019: Language delay was still observed, and his developmental level was about 2.0-2.5-years-old. According to Gesell Developmental Schedules, his adaptive development quotient increased to 49.46 on March 6, 2019. His adaptability and personal-social skills were moderately lagging behind, and his other skills remained slightly lagging behind.



**Figure 1** Heterozygous deletion mutations found at exons 6–21 in the child as revealed by whole-exome sequencing.



**Figure 2** No anomalies were found at exons 6–21 in the child's parents as revealed by whole-exome sequencing.

## DISCUSSION

*FOXP1* mutations may cause mental retardation accompanied by dysphasia in the absence or the presence of autism. *FOXP1* mutations are manifested by dysphasia, motor retardation, mental retardation, stereotyped behaviors, hyperactivity, facial changes, heterotropia, nystagmus and obesity, with clinical symptoms progressing slowly but not affecting life expectancy. The child was diagnosed with autism with dysphasia accompanied by mental retardation because of *FOXP1* mutations and the corresponding clinical manifestations with a better prognosis.

The FOX genome is a large and highly conservative family of transcription factors. FOX, a subfamily of the FOX family, has four members, namely, FOX1–FOX4, which not only maintain a high degree of conservatism in structure but also participate in different developmental processes, such as neural development related to language and cognition, the formation and development of organs, such as the heart and lungs, and the development of the immune system[7-10].

As a member of the FOXP family, *FOXP1* is widely and abundantly expressed in normal tissues early in the embryo. Banham *et al*[2,4] obtained a full-length cDNA encoding *FOXP1*, which is characterized by a DNA domain with a length of 100 amino acids and an evolutionarily conserved DNA domain called the forkhead or the forkhead/ winged helix domain. Members of the FOXP subfamily have several atypical features in the FOX protein: The forkhead domain is located near the carboxyl terminal region, contains leucine zipper motifs that promote the homodimerization and heterodimerization of FOXP, and has a highly selective tissue- and cell type-specific activity.

In this case, the *FOXP1* gene of the child had a heterozygous deletion variation, and the mutation site was heterozygous deletion in exons 6-21. Since the detection method was second generation WES, the regional deletion fracture could only be determined according to the region of exon captured by the gene. Therefore, we could only ascertain that the approximate location of the gene deletion in children was about 345 kb, the maximum deleted region is chr3: 71003864-71349076.

A total of 15 cases with *FOXP1* mutations have been reported to date[11-20]. Eight cases had partial gene deletions, six had abnormal amino acid synthesis caused by base mutations, and one had abnormal amino acid synthesis and expression with a base (T) added (Table 1). Noticeable facial changes were observed in 10 of the reported cases and conduct disorders in 7 cases. No study has reported that *FOXP1* mutations affect the lifespan of the patients; however, according to previous reports, this gene may have a tendency.

The closest patient to this case was a girl with a 390-kb deletion of exons 4-14 of her *FOXP1* gene. As in this case, no abnormality was found in either parent[14]. The patient was not able to say words until she was 3-years-old, and since then she has been able to respond to language, but this response is mostly repeated language content, rather than language to answer questions. Despite the behavioral characteristics of autism, the patient had stereotyped behavior, compulsive behavior, hyperactivity, and was not diagnosed with autism.

Previous reports have shown that FOXP1 and FOXP2 (OMIM :605317) are closely related[13,19]. Both of them are homeostructures sharing similar amino terminal domains, and active in the foregut and brain in human development. The lack of FOXP1 and FOXP2 can be seen in the delay of language development (such as vocal retardation, dysarthria, grammatical monotony, *etc.*)[11], but FOXP2-related cases tend to describe the facial muscle fine motor dysfunction (such as lip, tongue muscle, *etc.*), whose variants are often accompanied by language expression and receptivity abnormalities, while FOXP1 tend to affect the nerves of children and lead to language retardation.

Analysis of the condition of the present case and those previously reported suggested that a certain correlation may exist between the *FOXP1* mutation site and clinical phenotypes. Fifteen cases had dysgnosia, bradykinesia, and cognitive modifiability that affected motor development. However, compared with the abnormal expression caused by base mutation, patients with gene interruption are more likely to show more severe language and motor retardation, accompanied by limb deformities and organic lesions.

In children with facial changes, they often have the same type of performance: Giant malformation, wide eye distance, excessive strabismus, and wide nose tip[13,19]. In this case, the ear position of the child was slightly lower and there was a typical facial change. In some of the patients who had provided the relevant examination, some of the results showed abnormal structural development such as periventricular white matter, but there was no nervous system examination and EEG was abnormal. In this case, there was hydrocephalus during pregnancy. Postnatal examination showed that the right ventricle was dilated, and vacuolar sella and EEG were not abnormal. This may be related to the abnormal expression of *FOXP1* gene deletion.

In addition to the motor retardation, some patients reported decreased muscle tension and referred to gait abnormalities in phenotypic description[20]. In this case, the children also had abnormal gait (such as walking instability, easy to fall), and achieved more obvious improvement after rehabilitation, which suggests that our timely and early intervention can improve the living standards of patients.

According to previous reports, children with clinical manifestations, such as dyskinesia, developmental retardation, dysphasia, cognitive modifiability and facial changes (low-set ears), meet the diagnostic criteria for phenotypic changes of mental retardation accompanied by dysphasia in the absence or the presence of autism. Notably, the illness episodes of Asian populations have never been defined or described in previously reported cases. Hence, the present case may provide new insights into the illness episodes and manifestations of a different race. Our clinical

Table 1 Summarize the medical records reported in the past

Time of Publication	Age of the patient	Mutations in the positioning	Nucleic acid change	Amino acid change	Form of mutation	Language barrier	Motor retardation	Time to sit alone	Time to walk alone	Change in perception	Time to speak word	Face change	Stereotyped behavior
2009	23 mo	Chr3:71164161-71958845				+	+	15 mo	18 mo	+	23 mo	+	NA
2010	3 yr and 10 mo	Chr3:70549923-71618670			Missing	+	+	NA	16 mo	NA	41 mo	+	NA
2010	7 yr	Chr3:70807767-71305965			Missing	+	+	NA	24 mo	+	42 mo	NA	NA
	5 yr and 6 mo	Chr3:71021785	c.1573C>T	p.R525	Variation	+	+	12 mo	36 mo	+	42 mo	+	NA
	6 yr	Chr3:tel:70341246-70341247 and cen:71388173-71388174			Missing	+	+	8 mo	24 mo	+	42 mo	+	NA
2010	15 yr and 11 mo	Chr3:71114875-71504640/exons4-14			Missing	+	+	NA	18-20 mo	+	3 yr	NA	+
	9 yr and 11 mo	3p14.1	c.1573C>T	p.R525X	Variation	+	+	NA	18-20 mo	+	6 yr	NA	+
2011	NA	Chr3:71132860	+T	p.Ala339SerfsX4	Insert	+	+	NA	NA	+	NA	NA	+
2012	NA	Chr3:62133183-71072125			Missing	+	+	NA	NA	+	NA	NA	NA
2013	7 yr	Chr3:71041636-71229421			Missing	+	+	1 yr	25 mo	+	52 mo	+	NA
2015	14 yr	Chr3:71027059-71027060	c.1267-1268		Missing	+	+	+	13 mo	+	20 mo	+	+
2014	2 yr	Chr3:71021758	c.1600T>C	p.W534R	Variation	NA	NA	NA	NA	NA	NA	+	NA
2016	11 yr	Chr3:71026829	c.1393A>G	p.R465G	Variation	+	+	NA	21 mo	+	NA	+	+
	7 yr	Chr3:71021818	c.1540C>T	p.R514C	Variation	+	+	NA	17 mo	+	NA	+	+
	15 yr	Chr3:71027010	c.1317C>G	p.Y439	Variation	+	+	NA	21 mo	+	NA	+	+
This case	5 yr	3p14.1,exons6-21			Missing	+	+	9 mo	2 yr	+	NA	+	+

+: Positive result; -: Negative; NA: Not detected.

assessment of patients helps to describe the core phenotype of *FOXP1*-related disorders, which may contribute to disease identification.



## CONCLUSION

In this study, WES was conducted to resolve three aspects. First, the etiology was established to clarify the genetic causes of the disease; this information is useful in genetic counseling. Second, genotype analysis is helpful to guide clinical treatment and prognosis evaluation, and modern rehabilitation training, such as educational intervention, behavior modification, speech therapy and sensory integration training, are conducive to early intervention and improvement in the quality of life of patients. Finally, the discovery of a new *FOXP1* mutation with heterozygous deletions at exons 6–21 enriches our understanding of the *FOXP1* mutation spectrum. The results of the present study suggest that investigation of intelligence development cannot be neglected for children with clinical manifestations of dysphasia and motor retardation. In such a case, the possibility of *FOXP1* mutation should be raised.

## ACKNOWLEDGEMENTS

We would like to thank the child and his family members for agreeing to participate in this study.

## REFERENCES

- 1 **Wang B**, Lin D, Li C, Tucker P. Multiple domains define the expression and regulatory properties of Foxp1 forkhead transcriptional repressors. *J Biol Chem* 2003; **278**: 24259–24268 [PMID: [12692134](#) DOI: [10.1074/jbc.M207174200](#)]
- 2 **Banham AH**, Beasley N, Campo E, Fernandez PL, Fidler C, Gatter K, Jones M, Mason DY, Prime JE, Trounboff P, Wood K, Cordell JL. The FOXP1 winged helix transcription factor is a novel candidate tumor suppressor gene on chromosome 3p. *Cancer Res* 2001; **61**: 8820–8829 [PMID: [11751404](#)]
- 3 **Streubel B**, Vinatzer U, Lamprecht A, Raderer M, Chott A. T(3;14)(p14.1;q32) involving IGH and FOXP1 is a novel recurrent chromosomal aberration in MALT lymphoma. *Leukemia* 2005; **19**: 652–658 [PMID: [15703784](#) DOI: [10.1038/sj.leu.2403644](#)]
- 4 **Banham AH**, Connors JM, Brown PJ, Cordell JL, Ott G, Sreenivasan G, Farinha P, Horsman DE, Gascoyne RD. Expression of the FOXP1 transcription factor is strongly associated with inferior survival in patients with diffuse large B-cell lymphoma. *Clin Cancer Res* 2005; **11**: 1065–1072 [PMID: [15709173](#)]
- 5 **Hu H**, Wang B, Borde M, Nardone J, Maika S, Allred L, Tucker PW, Rao A. Foxp1 is an essential transcriptional regulator of B cell development. *Nat Immunol* 2006; **7**: 819–826 [PMID: [16819554](#) DOI: [10.1038/ni1358](#)]
- 6 **Richards S**, Aziz N, Bale S, Bick D, Das S, Gastier-Foster J, Grody WW, Hegde M, Lyon E, Spector E, Voelkerding K, Rehml HL; ACMG Laboratory Quality Assurance Committee. Standards and guidelines for the interpretation of sequence variants: a joint consensus recommendation of the American College of Medical Genetics and Genomics and the Association for Molecular Pathology. *Genet Med* 2015; **17**: 405–424 [PMID: [25741868](#) DOI: [10.1038/gim.2015.30](#)]
- 7 **Brunkow ME**, Jeffery EW, Hjerrild KA, Paepers B, Clark LB, Yasayko SA, Wilkinson JE, Galas D, Ziegler SF, Ramsdell F. Disruption of a new forkhead/winged-helix protein, scurfy, results in the fatal lymphoproliferative disorder of the scurfy mouse. *Nat Genet* 2001; **27**: 68–73 [PMID: [11138001](#) DOI: [10.1038/83784](#)]
- 8 **Enard W**, Przeworski M, Fisher SE, Lai CS, Wiebe V, Kitano T, Monaco AP, Pääbo S. Molecular evolution of FOXP2, a gene involved in speech and language. *Nature* 2002; **418**: 869–872 [PMID: [12192408](#) DOI: [10.1038/nature01025](#)]
- 9 **Shu W**, Lu MM, Zhang Y, Tucker PW, Zhou D, Morrissey EE. Foxp2 and Foxp1 cooperatively regulate lung and esophagus development. *Development* 2007; **134**: 1991–2000 [PMID: [17428829](#) DOI: [10.1242/dev.02846](#)]
- 10 **Wang B**, Weidenfeld J, Lu MM, Maika S, Kuziel WA, Morrissey EE, Tucker PW. Foxp1 regulates cardiac outflow tract, endocardial cushion morphogenesis and myocyte proliferation and maturation. *Development* 2004; **131**: 4477–4487 [PMID: [15342473](#) DOI: [10.1242/dev.01287](#)]
- 11 **Pariani MJ**, Spencer A, Graham JM Jr, Rimoin DL. A 785kb deletion of 3p14.1p13, including the FOXP1 gene, associated with speech delay, contractures, hypertonia and blepharophimosis. *Eur J Med Genet* 2009; **52**: 123–127 [PMID: [19332160](#) DOI: [10.1016/j.ejmg.2009.03.012](#)]
- 12 **Carr CW**, Moreno-De-Luca D, Parker C, Zimmerman HH, Ledbetter N, Martin CL, Dobyns WB, Abdul-Rahman OA. Chiari I malformation, delayed gross motor skills, severe speech delay, and epileptiform discharges in a child with FOXP1 haploinsufficiency. *Eur J Hum Genet* 2010; **18**: 1216–1220 [PMID: [20571508](#) DOI: [10.1038/ejhg.2010.96](#)]
- 13 **Horn D**, Kapeller J, Rivera-Brugués N, Moog U, Lorenz-Depiereux B, Eck S, Hempel M,

- Wagenstaller J, Gawthrop A, Monaco AP, Bonin M, Riess O, Wohlleber E, Illig T, Bezzina CR, Franke A, Spranger S, Villavicencio-Lorini P, Seifert W, Rosenfeld J, Klopocki E, Rappold GA, Strom TM. Identification of FOXP1 deletions in three unrelated patients with mental retardation and significant speech and language deficits. *Hum Mutat* 2010; **31**: E1851-E1860 [PMID: [20848658](#) DOI: [10.1002/humu.21362](#)]
- 14 **Hamdan FF**, Daoud H, Rochefort D, Piton A, Gauthier J, Langlois M, Foomani G, Dobrzyniecka S, Krebs MO, Joobor R, Lafrenière RG, Lacaille JC, Motttron L, Drapeau P, Beauchamp MH, Phillips MS, Fombonne E, Rouleau GA, Michaud JL. De novo mutations in FOXP1 in cases with intellectual disability, autism, and language impairment. *Am J Hum Genet* 2010; **87**: 671-678 [PMID: [20950788](#) DOI: [10.1016/j.ajhg.2010.09.017](#)]
- 15 **O'Roak BJ**, Deriziotis P, Lee C, Vives L, Schwartz JJ, Girirajan S, Karakoc E, Mackenzie AP, Ng SB, Baker C, Rieder MJ, Nickerson DA, Bernier R, Fisher SE, Shendure J, Eichler EE. Exome sequencing in sporadic autism spectrum disorders identifies severe de novo mutations. *Nat Genet* 2011; **43**: 585-589 [PMID: [21572417](#) DOI: [10.1038/ng.835](#)]
- 16 **Talkowski ME**, Rosenfeld JA, Blumenthal I, Pillalamarri V, Chiang C, Heilbut A, Ernst C, Hanscom C, Rossin E, Lindgren AM, Pereira S, Ruderfer D, Kirby A, Ripke S, Harris DJ, Lee JH, Ha K, Kim HG, Solomon BD, Gropman AL, Lucente D, Sims K, Ohsumi TK, Borowsky ML, Loranger S, Quade B, Lage K, Miles J, Wu BL, Shen Y, Neale B, Shaffer LG, Daly MJ, Morton CC, Gusella JF. Sequencing chromosomal abnormalities reveals neurodevelopmental loci that confer risk across diagnostic boundaries. *Cell* 2012; **149**: 525-537 [PMID: [22521361](#) DOI: [10.1016/j.cell.2012.03.028](#)]
- 17 **Le Fevre AK**, Taylor S, Malek NH, Horn D, Carr CW, Abdul-Rahman OA, O'Donnell S, Burgess T, Shaw M, Gecz J, Bain N, Fagan K, Hunter MF. FOXP1 mutations cause intellectual disability and a recognizable phenotype. *Am J Med Genet A* 2013; **161A**: 3166-3175 [PMID: [24214399](#) DOI: [10.1002/ajmg.a.36174](#)]
- 18 **Srivastava S**, Cohen JS, Vernon H, Barañano K, McClellan R, Jamal L, Naidu S, Fatemi A. Clinical whole exome sequencing in child neurology practice. *Ann Neurol* 2014; **76**: 473-483 [PMID: [25131622](#) DOI: [10.1002/ana.24251](#)]
- 19 **Lozano R**, Vano A, Lozano C, Fisher SE, Deriziotis P. A de novo FOXP1 variant in a patient with autism, intellectual disability and severe speech and language impairment. *Eur J Hum Genet* 2015; **23**: 1702-1707 [PMID: [25853299](#) DOI: [10.1038/ejhg.2015.66](#)]
- 20 **Sollis E**, Graham SA, Vano A, Froehlich H, Vreeburg M, Dimitropoulou D, Gilissen C, Pfundt R, Rappold GA, Brunner HG, Deriziotis P, Fisher SE. Identification and functional characterization of de novo FOXP1 variants provides novel insights into the etiology of neurodevelopmental disorder. *Hum Mol Genet* 2016; **25**: 546-557 [PMID: [26647308](#) DOI: [10.1093/hmg/ddv495](#)]



Published by **Baishideng Publishing Group Inc**  
7041 Koll Center Parkway, Suite 160, Pleasanton, CA 94566, USA

**Telephone:** +1-925-3991568

**E-mail:** [bpgoffice@wjgnet.com](mailto:bpgoffice@wjgnet.com)

**Help Desk:** <https://www.f6publishing.com/helpdesk>

<https://www.wjgnet.com>

