

World Journal of *Clinical Cases*

World J Clin Cases 2021 August 26; 9(24): 6964-7291



Contents

Thrice Monthly Volume 9 Number 24 August 26, 2021

OPINION REVIEW

- 6964 Reconsideration of recurrence and metastasis in colorectal cancer
Wang R, Su Q, Yan ZP

MINIREVIEWS

- 6969 Multiple immune function impairments in diabetic patients and their effects on COVID-19
Lu ZH, Yu WL, Sun Y
- 6979 Discontinuation of antiviral therapy in chronic hepatitis B patients
Medas R, Liberal R, Macedo G

ORIGINAL ARTICLE

Case Control Study

- 6987 Textural differences based on apparent diffusion coefficient maps for discriminating pT3 subclasses of rectal adenocarcinoma
Lu ZH, Xia KJ, Jiang H, Jiang JL, Wu M

Retrospective Cohort Study

- 6999 Cost-effective screening using a two-antibody panel for detecting mismatch repair deficiency in sporadic colorectal cancer
Kim JB, Kim YI, Yoon YS, Kim J, Park SY, Lee JL, Kim CW, Park IJ, Lim SB, Yu CS, Kim JC

Retrospective Study

- 7009 Novel model combining contrast-enhanced ultrasound with serology predicts hepatocellular carcinoma recurrence after hepatectomy
Tu HB, Chen LH, Huang YJ, Feng SY, Lin JL, Zeng YY
- 7022 Influence of volar margin of the lunate fossa fragment fixation on distal radius fracture outcomes: A retrospective series
Meng H, Yan JZ, Wang B, Ma ZB, Kang WB, Liu BG
- 7032 Case series of COVID-19 patients from the Qinghai-Tibetan Plateau Area in China
Li JJ, Zhang HQ, Li PJ, Xin ZL, Xi AQ, Zhuo-Ma, Ding YH, Yang ZP, Ma SQ
- 7043 Patients' awareness about their own breast cancer characteristics
Geng C, Lu GJ, Zhu J, Li YY
- 7053 Fracture risk assessment in children with benign bone lesions of long bones
Li HB, Ye WS, Shu Q

SYSTEMATIC REVIEWS

- 7062** Mothers' experiences of neonatal intensive care: A systematic review and implications for clinical practice
Wang LL, Ma JJ, Meng HH, Zhou J

META-ANALYSIS

- 7073** *Helicobacter pylori* infection and peptic ulcer disease in cirrhotic patients: An updated meta-analysis
Wei L, Ding HG

CASE REPORT

- 7085** Tuberous sclerosis complex-lymphangiomyomatosis involving several visceral organs: A case report
Chen HB, Xu XH, Yu CG, Wan MT, Feng CL, Zhao ZY, Mei DE, Chen JL
- 7092** Long-term survivor of metastatic squamous-cell head and neck carcinoma with occult primary after cetuximab-based chemotherapy: A case report
Große-Thie C, Maletzki C, Junghanss C, Schmidt K
- 7099** Genetic mutations associated with sensitivity to neoadjuvant chemotherapy in metastatic colon cancer: A case report and review of literature
Zhao L, Wang Q, Zhao SD, Zhou J, Jiang KW, Ye YJ, Wang S, Shen ZL
- 7110** Coexistence of cervical extramedullary plasmacytoma and squamous cell carcinoma: A case report
Zhang QY, Li TC, Lin J, He LL, Liu XY
- 7117** Reconstruction of the chest wall after resection of malignant peripheral nerve sheath tumor: A case report
Guo X, Wu WM, Wang L, Yang Y
- 7123** A rare occurrence of a hereditary Birt-Hogg-Dubé syndrome: A case report
Lu YR, Yuan Q, Liu J, Han X, Liu M, Liu QQ, Wang YG
- 7133** Late-onset Leigh syndrome without delayed development in China: A case report
Liang JM, Xin CJ, Wang GL, Wu XM
- 7139** New mechanism of partial duplication and deletion of chromosome 8: A case report
Jiang Y, Tang S, He F, Yuan JX, Zhang Z
- 7146** S-1 plus temozolomide as second-line treatment for neuroendocrine carcinoma of the breast: A case report
Wang X, Shi YF, Duan JH, Wang C, Tan HY
- 7154** Minimally invasive treatment of hepatic hemangioma by transcatheter arterial embolization combined with microwave ablation: A case report
Wang LZ, Wang KP, Mo JG, Wang GY, Jin C, Jiang H, Feng YF
- 7163** Progressive disfiguring facial masses with pupillary axis obstruction from Morbihan syndrome: A case report
Zhang L, Yan S, Pan L, Wu SF

- 7169** Idiopathic basal ganglia calcification associated with new *MYORG* mutation site: A case report
Fei BN, Su HZ, Yao XP, Ding J, Wang X
- 7175** Geleophysic dysplasia caused by a mutation in *FBN1*: A case report
Tao Y, Wei Q, Chen X, Nong GM
- 7181** Combined laparoscopic-endoscopic approach for gastric glomus tumor: A case report
Wang WH, Shen TT, Gao ZX, Zhang X, Zhai ZH, Li YL
- 7189** Aspirin-induced long-term tumor remission in hepatocellular carcinoma with adenomatous polyposis coli stop-gain mutation: A case report
Lin Q, Bai MJ, Wang HF, Wu XY, Huang MS, Li X
- 7196** Prenatal diagnosis of isolated lateral facial cleft by ultrasonography and three-dimensional printing: A case report
Song WL, Ma HO, Nan Y, Li YJ, Qi N, Zhang LY, Xu X, Wang YY
- 7205** Therapy-related myeloid leukemia during erlotinib treatment in a non-small cell lung cancer patient: A case report
Koo SM, Kim KU, Kim YK, Uh ST
- 7212** Pediatric schwannoma of the tongue: A case report and review of literature
Yun CB, Kim YM, Choi JS, Kim JW
- 7218** Status epilepticus as a complication after COVID-19 mRNA-1273 vaccine: A case report
Šin R, Štruncová D
- 7224** Successful outcome of retrograde pancreatojejunostomy for chronic pancreatitis and infected pancreatic cysts: A case report
Kimura K, Adachi E, Toyohara A, Omori S, Ezaki K, Ihara R, Higashi T, Ohgaki K, Ito S, Maehara SI, Nakamura T, Maehara Y
- 7231** Incidentally discovered asymptomatic splenic hamartoma misdiagnosed as an aneurysm: A case report
Cao XF, Yang LP, Fan SS, Wei Q, Lin XT, Zhang XY, Kong LQ
- 7237** Secondary peripheral T-cell lymphoma and acute myeloid leukemia after Burkitt lymphoma treatment: A case report
Huang L, Meng C, Liu D, Fu XJ
- 7245** Retroperitoneal bronchogenic cyst in suprarenal region treated by laparoscopic resection: A case report
Wu LD, Wen K, Cheng ZR, Alwalid O, Han P
- 7251** Coexistent vestibular schwannoma and meningioma in a patient without neurofibromatosis: A case report and review of literature
Zhao LY, Jiang YN, Wang YB, Bai Y, Sun Y, Li YQ
- 7261** Thoracoabdominal duplication with hematochezia as an onset symptom in a baby: A case report
Yang SB, Yang H, Zheng S, Chen G

- 7269** Dental management of a patient with Moebius syndrome: A case report
Chen B, Li LX, Zhou LL
- 7279** Epidural gas-containing pseudocyst leading to lumbar radiculopathy: A case report
Chen Y, Yu SD, Lu WZ, Ran JW, Yu KX
- 7285** Regression of intervertebral disc calcification combined with ossification of the posterior longitudinal ligament: A case report
Wang XD, Su XJ, Chen YK, Wang WG

ABOUT COVER

Editorial Board Member of *World Journal of Clinical Cases*, Vijaykumar Chava, MD, Professor, Department of Periodontology, Narayana Dental College and Hospital, Nellore 524003, Andhra Pradesh, India.
chava7@hotmail.com

AIMS AND SCOPE

The primary aim of *World Journal of Clinical Cases* (WJCC, *World J Clin Cases*) is to provide scholars and readers from various fields of clinical medicine with a platform to publish high-quality clinical research articles and communicate their research findings online.

WJCC mainly publishes articles reporting research results and findings obtained in the field of clinical medicine and covering a wide range of topics, including case control studies, retrospective cohort studies, retrospective studies, clinical trials studies, observational studies, prospective studies, randomized controlled trials, randomized clinical trials, systematic reviews, meta-analysis, and case reports.

INDEXING/ABSTRACTING

The WJCC is now indexed in Science Citation Index Expanded (also known as SciSearch®), Journal Citation Reports/Science Edition, Scopus, PubMed, and PubMed Central. The 2021 Edition of Journal Citation Reports® cites the 2020 impact factor (IF) for WJCC as 1.337; IF without journal self cites: 1.301; 5-year IF: 1.742; Journal Citation Indicator: 0.33; Ranking: 119 among 169 journals in medicine, general and internal; and Quartile category: Q3. The WJCC's CiteScore for 2020 is 0.8 and Scopus CiteScore rank 2020: General Medicine is 493/793.

RESPONSIBLE EDITORS FOR THIS ISSUE

Production Editor: Ji-Hong Lin; Production Department Director: Yun-Jie Ma; Editorial Office Director: Jin-Lei Wang.

NAME OF JOURNAL

World Journal of Clinical Cases

ISSN

ISSN 2307-8960 (online)

LAUNCH DATE

April 16, 2013

FREQUENCY

Thrice Monthly

EDITORS-IN-CHIEF

Dennis A Bloomfield, Sandro Vento, Bao-Gan Peng

EDITORIAL BOARD MEMBERS

<https://www.wjgnet.com/2307-8960/editorialboard.htm>

PUBLICATION DATE

August 26, 2021

COPYRIGHT

© 2021 Baishideng Publishing Group Inc

INSTRUCTIONS TO AUTHORS

<https://www.wjgnet.com/bpg/gerinfo/204>

GUIDELINES FOR ETHICS DOCUMENTS

<https://www.wjgnet.com/bpg/GerInfo/287>

GUIDELINES FOR NON-NATIVE SPEAKERS OF ENGLISH

<https://www.wjgnet.com/bpg/gerinfo/240>

PUBLICATION ETHICS

<https://www.wjgnet.com/bpg/GerInfo/288>

PUBLICATION MISCONDUCT

<https://www.wjgnet.com/bpg/gerinfo/208>

ARTICLE PROCESSING CHARGE

<https://www.wjgnet.com/bpg/gerinfo/242>

STEPS FOR SUBMITTING MANUSCRIPTS

<https://www.wjgnet.com/bpg/GerInfo/239>

ONLINE SUBMISSION

<https://www.f6publishing.com>

New mechanism of partial duplication and deletion of chromosome 8: A case report

Yan Jiang, Shuang Tang, Fang He, Jue-Xin Yuan, Zhu Zhang

ORCID number: Yan Jiang 0000-0002-4906-4107; Shuang Tang 0000-0001-2345-6789; Fang He 0000-0003-3443-634X; Jue-Xin Yuan 0000-0002-8845-1492; Zhu Zhang 0000-0003-0004-8277.

Author contributions: Jiang Y and He F reviewed the literature and contributed to manuscript drafting; Yuan JX performed the G-banding chromosome analyses and contributed to manuscript drafting; Tang S performed the genetic counseling and contributed to manuscript drafting; Zhang Z performed the chromosome microarray analysis and contributed to manuscript drafting; Jiang Y and Tang S were responsible for revision of the manuscript for important intellectual content; all authors issued final approval for the version to be submitted.

Informed consent statement: The patient provided informed written consent prior to study enrollment.

Conflict-of-interest statement: The authors declare that they have no conflict of interest.

CARE Checklist (2016) statement: The authors have read the CARE Checklist (2016), and the manuscript was prepared and revised according to the CARE Checklist (2016).

Yan Jiang, Shuang Tang, Jue-Xin Yuan, Office of Prenatal Diagnosis, Mianyang People's Hospital, Mianyang 621000, Sichuan Province, China

Fang He, Department of Obstetrics, Mianyang People's Hospital, Mianyang 621000, Sichuan Province, China

Zhu Zhang, Office of Prenatal Diagnosis, West China Second University Hospital, Sichuan University, Chengdu 610000, Sichuan Province, China

Corresponding author: Shuang Tang, MBBS, Attending Doctor, Office of Prenatal Diagnosis, Mianyang People's Hospital, No. 10-12 West Jiannan Road, Fuchen District, Mianyang 621000, Sichuan Province, China. 154179285@qq.com

Abstract

BACKGROUND

During meiosis, the recombination of homologous chromosomes produces some new heritable mutations, which are the basis of biological evolution and diversity. However, when there is pericentric inversion of chromosomes, unbalanced gametes will be formed in the process of germ cell meiosis.

CASE SUMMARY

A 23-year-old pregnant woman at 25 wk of gestation wanted to terminate her pregnancy due to fetal chromosomal abnormalities. She had no exposure to toxic or hazardous substances before and during pregnancy, no history of medication usage during pregnancy, and she underwent cystectomy of ovarian cysts in 2017. On the second day of the 16th week of gestation, non-invasive prenatal testing showed chromosome 8 copy number variation. Following genetic counseling, her pregnancy was terminated.

CONCLUSION

Recombinant offspring chromosome is rarely seen when the inversion segment is shorter than one-third of the chromosome length. In terms of the mechanism of chromosome 8 duplication/deletion occurrence, attention should be paid to the production of unbalanced gametes by the pairing of homologous chromosome during meiosis, and the possibility of mitotic recombination exchange as well.

Key Words: Chromosome 8; Spontaneous mutation; Mitosis; Non-invasive prenatal testing; Case report

Open-Access: This article is an open-access article that was selected by an in-house editor and fully peer-reviewed by external reviewers. It is distributed in accordance with the Creative Commons Attribution NonCommercial (CC BY-NC 4.0) license, which permits others to distribute, remix, adapt, build upon this work non-commercially, and license their derivative works on different terms, provided the original work is properly cited and the use is non-commercial. See: <http://creativecommons.org/licenses/by-nc/4.0/>

Manuscript source: Unsolicited manuscript

Specialty type: Medicine, research and experimental

Country/Territory of origin: China

Peer-review report's scientific quality classification

Grade A (Excellent): 0
Grade B (Very good): B, B
Grade C (Good): 0
Grade D (Fair): 0
Grade E (Poor): 0

Received: February 21, 2021

Peer-review started: February 21, 2021

First decision: May 6, 2021

Revised: May 23, 2021

Accepted: June 7, 2021

Article in press: June 7, 2021

Published online: August 26, 2021

P-Reviewer: Bolshakova GB, soleimani S

S-Editor: Gao CC

L-Editor: Webster JR

P-Editor: Yuan YY



©The Author(s) 2021. Published by Baishideng Publishing Group Inc. All rights reserved.

Core Tip: The mechanism of partial deletion/duplication at the end of chromosome 8 involves two prevailing theories: Parental chromosome 8 inversion producing unbalanced gametes, and a recombination hot spot of chromosome 8p. Although the recombination hot spot of chromosome 8q occurring during mitosis is rarely reported, it was confirmed in the present case. Non-invasive prenatal testing (NIPT) for copy number variation has been used, but 40% or less mosaic abnormalities cannot be detected by NIPT. When chromosome 8 partial deletion/duplication occurs, in addition to the unbalanced gamete production caused by parental chromosome 8 inversion, attention should be paid to the mechanism of spontaneous recombination in meiosis or mitosis.

Citation: Jiang Y, Tang S, He F, Yuan JX, Zhang Z. New mechanism of partial duplication and deletion of chromosome 8: A case report. *World J Clin Cases* 2021; 9(24): 7139-7145
URL: <https://www.wjgnet.com/2307-8960/full/v9/i24/7139.htm>
DOI: <https://dx.doi.org/10.12998/wjcc.v9.i24.7139>

INTRODUCTION

The occurrence of duplicated and deleted offspring chromosome ends is commonly triggered by the joint pairing of pericentric inversion of chromosomes and homologous chromosomes during the first stage of meiosis. If the joint pairing forms an inverted ring, four different gametes are theoretically produced, including one with a normal chromosome, one with an inverted chromosome, and the other two with both partial duplication and partial deletions; *e.g.*, mother 46,xx,inv(8)(p15q36), offspring: 46,xy,rec(8)dup p,inv(8)(p15q36)mat. Many factors seem to influence the production of recombinant chromosomes, such as the affected chromosome and involved region, location of the breakpoints, or size of the inverted segment. The rate of recombination varies according to the size of the inverted segment[1]. Research has shown that chromosome 8p has a recombination hot spot, which leads to the complex de novo 8p rearrangement[2,3].

CASE PRESENTATION

Chief complaints

A 23-year-old pregnant woman at 25 wk of gestation wanted to terminate her pregnancy due to fetal chromosomal abnormalities.

History of present illness

On the second day of the 16th week of gestation, non-invasive prenatal testing (NIPT) showed chromosome 8 copy number variation.

History of past illness

The patient underwent a cystectomy for benign ovarian cysts in 2017.

Personal and family history

The patient had no special personal and family history.

Physical examination

The pregnant woman's uterine height was 23 cm, abdominal circumference was 84 cm and blood pressure was 114/64 mmHg.

Laboratory examinations

NIPT showed that there was low-risk syndrome of chromosome 13, 18 and 21 and high risk of the end of the short arm of chromosome 8 missing about 3 Mb (Figure 1). Amniocentesis chromosome microarray analysis showed: arr[GRCH37]8p23.3p23.2

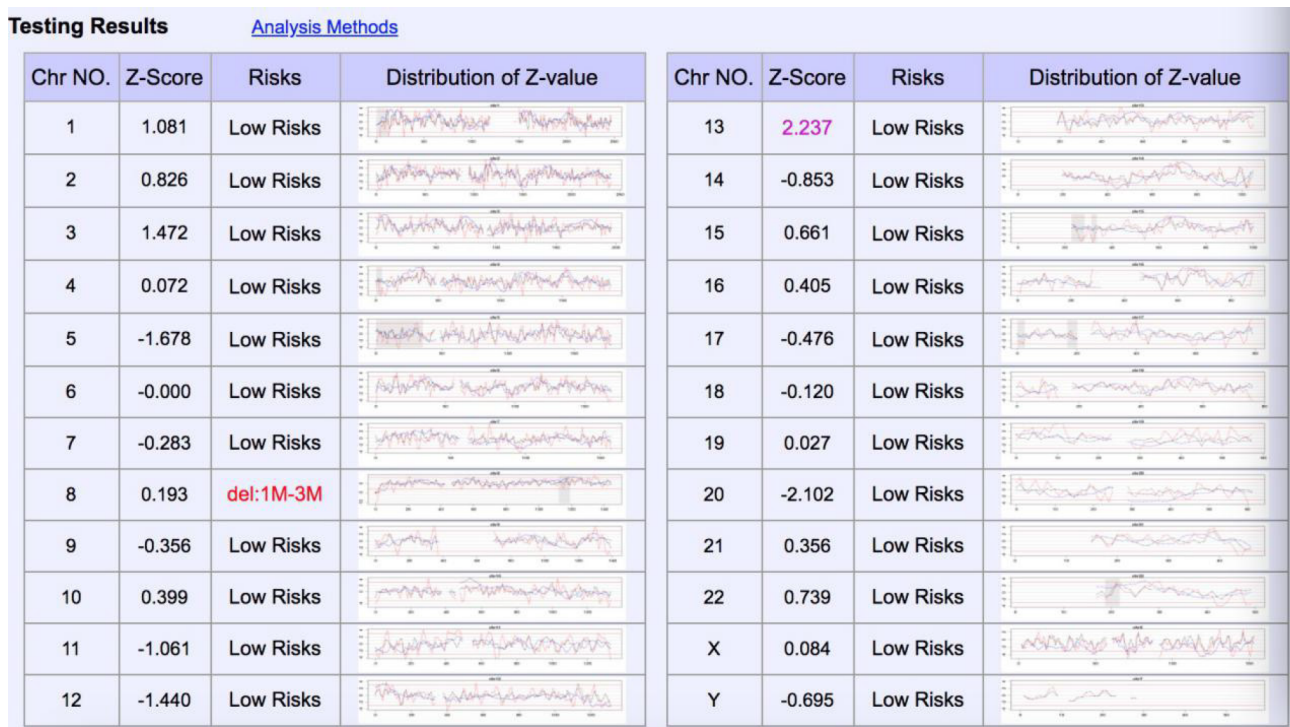


Figure 1 Non-invasive prenatal testing showed high risk of 3 Mb deletion at the end of chromosome 8p.

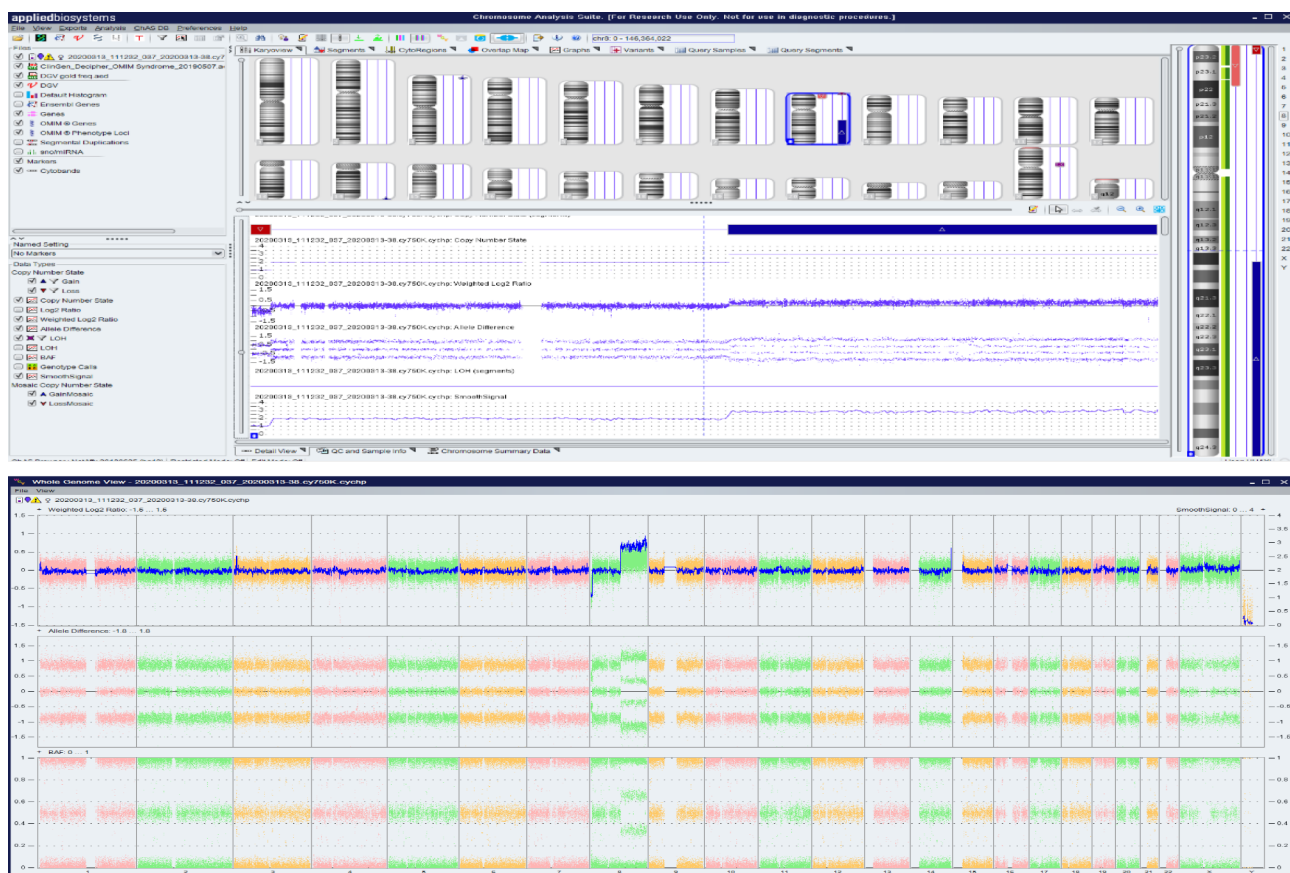


Figure 2 Amniocentesis chromosome microarray analysis showed 3.06Mb deletion in 8p23.3p23.2, and 69.18Mb duplication in 8q21.1q24.3.

(158048-3220759)x1,8q21.1q24.3(77115706-146295771)x3 (Figure 2).

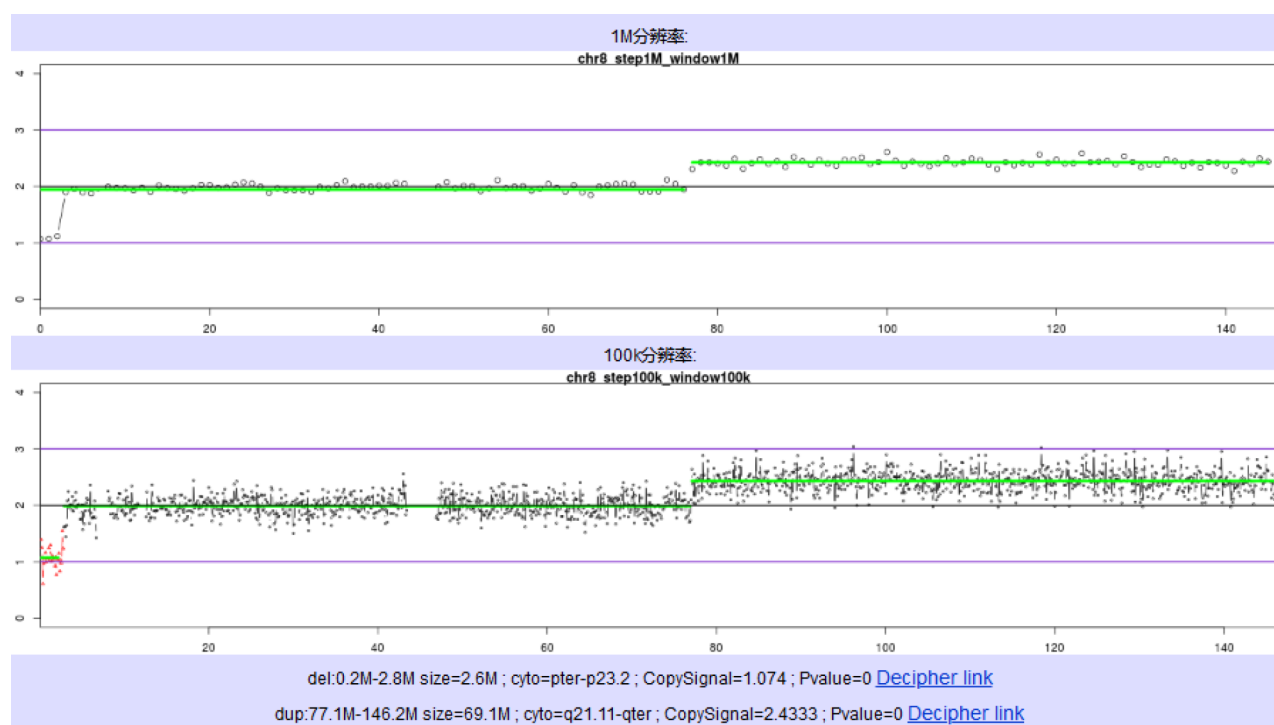


Figure 3 Placental high throughput sequencing showed 3.06Mb deletion in 8p23.3p23.2, and 69.18Mb duplication in 8q21.11q24.3 with 40% mosaicism.

Imaging examinations

Systematic ultrasonography showed that the fetal ventricles were widened bilaterally, and the measured value of the septum pellucidum was smaller than the normal. Cardiac ultrasound suggested fetal venous catheter occlusion or absence.

FINAL DIAGNOSIS

The fetus had an abnormal copy number of chromosome 8 and restricted placental mosaicism.

TREATMENT

The pregnancy was terminated after genetic counseling.

OUTCOME AND FOLLOW-UP

The couple underwent peripheral blood karyotype examination, and no significant abnormalities were seen in the G-dominant band (400 bands). They have no plans for another pregnancy.

DISCUSSION

In the present case, NIPT showed that the fetus may have a terminal deletion of chromosome 8p (Figure 1), and amniocentesis chromosome microarray analysis showed a deletion/duplication of chromosome 8p/8q (Figure 2). They are not consistent with each other. It has been reported that NIPT has higher efficiency for detecting > 2 Mb copy number variations[4-7] compared to other techniques. However, further placental high-throughput sequencing confirmed that the placental long-arm terminal duplication was 40% mosaic (Figure 3), indicating that NIPT may not have a high

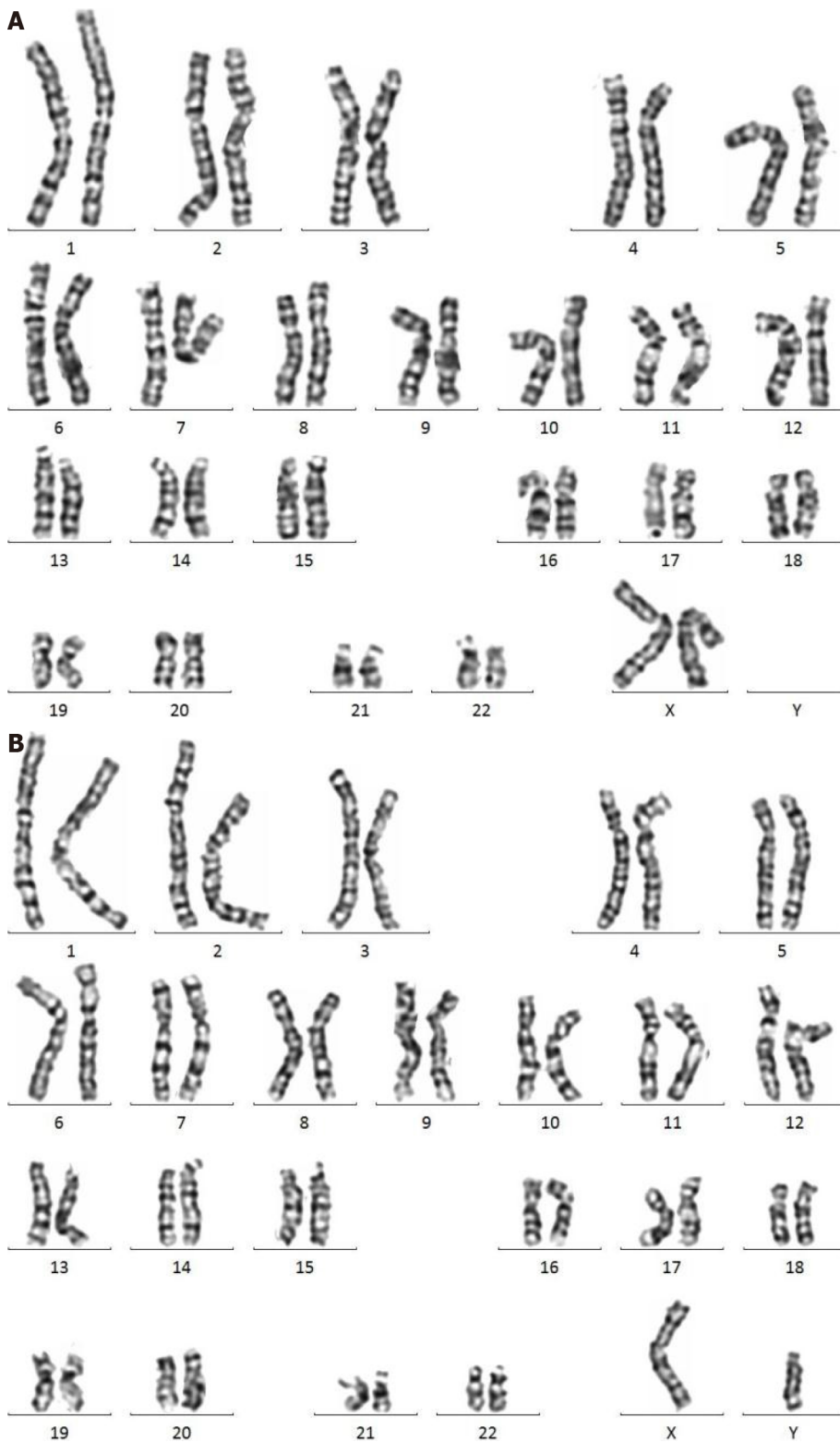


Figure 4 The karyotype of the mother and father. A: The karyotype of the mother was 46,XX; B: The karyotype of the father was 46,XY.

detection rate when chromosomal copy number variations show a low placental mosaic proportion, thus it has a limited role in the detection of chromosomal copy number variations.

All the chromosomes, mostly chromosomes 2 and 8, are known to be involved in pericentric inversions[8]. Carriers of these inversions can produce a significant percentage of chromosomal unbalanced gametes (duplication q/deletion p or duplication p/deletion q). The rate of recombination varies according to the size of the inverted segment[1,9].

Chromosome 8p is especially prone to various genomic rearrangements mainly due to the existence of the two olfactory receptor gene clusters (REPD and REPP) of 8p23.1 [10-12].

In the present case, the chromosome microarray analysis indicated a deletion of 8p and a duplication of 8q, and pericentric inversions of chromosome 8 were not found in the couple's G-dominant band (400 bands) of chromosomal karyotype (Figure 4). CNV-seq of the placenta indicated a deletion of 8p and a duplication of 8q with 40% mosaicism (Figure 3). All the above data indicated that the short-arm deletion and long-arm duplication of fetal chromosome 8 were new mutations. The deletion of chromosome 8p is presumed to have a high possibility of a deletion in the meiotic homologous chromosome synapsis and exchange, which is consistent with the high recombination rate of the terminal arm of chromosome 8 based on the database of recombination rates of human homologous chromosomes[3]. Cases of terminal deletion of chromosome 8p have also been reported[13,14], which further confirmed that mutation sites may be at the end of the short arm of chromosome 8 resulting in the prevention of breakpoints from synapsis and recombination. The duplication of chromosome 8q may arise from a disorder of the mitotic homologous chromosome recombination early in the development of the fertilized egg, and later the inner cell mass of the mulberry embryo develops from the deletion and repeated cell line of chromosome 8. Thus, two cell lines exist in the placenta resulting in the terminal deletion and duplication of chromosome 8p and chromosome 8q.

CONCLUSION

Recombinant offspring chromosomes are rarely seen when the inversion segment is shorter than one-third of the chromosome length. The extent of the genetic imbalance of these recombinants depends on the relative size of the inversion segment. In terms of the mechanism of chromosome 8 duplication/deletion occurrence, attention should be paid to the production of unbalanced gametes by the pairing of homologous chromosome during meiosis, and the possibility of mitotic recombination exchange as well.

REFERENCES

- 1 **Caer E**, Perrin A, Douet-Guilbert N, Amice V, De Braekeleer M, Morel F. Differing mechanisms of meiotic segregation in spermatozoa from three carriers of a pericentric inversion of chromosome 8. *Fertil Steril* 2008; **89**: 1637-1640 [PMID: 17603050 DOI: 10.1016/j.fertnstert.2007.04.056]
- 2 **Vermeesch JR**, Thoelen R, Salden I, Raes M, Matthijs G, Fryns JP. Mosaicism del(8p)/inv dup(8p) in a dysmorphic female infant: a mosaic formed by a meiotic error at the 8p OR gene and an independent terminal deletion event. *J Med Genet* 2003; **40**: e93 [PMID: 12920085 DOI: 10.1136/jmg.40.8.e93]
- 3 **Giorda R**, Ciccone R, Gimelli G, Pramparo T, Beri S, Bonaglia MC, Giglio S, Genuardi M, Argente J, Rocchi M, Zuffardi O. Two classes of low-copy repeats mediate a new recurrent rearrangement consisting of duplication at 8p23.1 and triplication at 8p23.2. *Hum Mutat* 2007; **28**: 459-468 [PMID: 17262805 DOI: 10.1002/humu.20465]
- 4 **Yin AH**, Peng CF, Zhao X, Caughey BA, Yang JX, Liu J, Huang WW, Liu C, Luo DH, Liu HL, Chen YY, Wu J, Hou R, Zhang M, Ai M, Zheng L, Xue RQ, Mai MQ, Guo FF, Qi YM, Wang DM, Krawczyk M, Zhang D, Wang YN, Huang QF, Karin M, Zhang K. Noninvasive detection of fetal subchromosomal abnormalities by semiconductor sequencing of maternal plasma DNA. *Proc Natl Acad Sci USA* 2015; **112**: 14670-14675 [PMID: 26554006 DOI: 10.1073/pnas.1518151112]
- 5 **Wang Q**, Zeng XL, Yu L, Zhao SY. Clinical research progress of non-invasive prenatal detection for fetal chromosome microdeletion/microrepetition. *Shiyong Fuke Neifenmi Dianzi Zazhi* 2020; **13**: 22-24 [DOI: 10.16484/j.cnki.issn2095-8803.2019.13.008]
- 6 **Ye XQ**, Gao Y, Song XW, Wu XJ, Chen JY, Wang JY, Yan HC, Chen M. Evaluation of Detection Efficiency for Fetal Chromosome Copy Number Variation Measured by Low-Depth Sequencing Noninvasive Prenatal Test. *Shiyong Fuchanke Zazhi* 2020; **36**: 380-384
- 7 **Yu D**, Zhang K, Han M, Pan W, Chen Y, Wang Y, Jiao H, Duan L, Zhu Q, Song X, Hong Y, Chen C, Wang J, Hui F, Huang L, Du Y. Noninvasive prenatal testing for fetal subchromosomal copy number variations and chromosomal aneuploidy by low-pass whole-genome sequencing. *Mol Genet Genomic Med* 2019; **7**: e674 [PMID: 31004415 DOI: 10.1002/mgg3.674]
- 8 **Jaarola M**, Martin RH, Ashley T. Direct evidence for suppression of recombination within two pericentric inversions in humans: a new sperm-FISH technique. *Am J Hum Genet* 1998; **63**: 218-224 [PMID: 9634501 DOI: 10.1086/301900]
- 9 **Vera-Carbonell A**, López-González V, Bafalliu JA, Piñero-Fernández J, Susmozas J, Sorli M,

- López-Pérez R, Fernández A, Guillén-Navarro E, López-Expósito I. Pre- and postnatal findings in a patient with a novel *rec(8)dup(8q)inv(8)(p23.2q22.3)* associated with San Luis Valley syndrome. *Am J Med Genet A* 2013; **161A**: 2369-2375 [PMID: [23894102](#) DOI: [10.1002/ajmg.a.36103](#)]
- 10 **Hollox EJ**, Barber JC, Brookes AJ, Armour JA. Defensins and the dynamic genome: what we can learn from structural variation at human chromosome band 8p23.1. *Genome Res* 2008; **18**: 1686-1697 [PMID: [18974263](#) DOI: [10.1101/gr.080945.108](#)]
 - 11 **Cooke SL**, Northup JK, Champaige NL, Zinser W, Edwards PA, Lockhart LH, Velagaleti GV. Molecular cytogenetic characterization of a unique and complex *de novo* 8p rearrangement. *Am J Med Genet A* 2008; **146A**: 1166-1172 [PMID: [18302246](#) DOI: [10.1002/ajmg.a.32248](#)]
 - 12 **Shimokawa O**, Miyake N, Yoshimura T, Sosonkina N, Harada N, Mizuguchi T, Kondoh S, Kishino T, Ohta T, Remco V, Takashima T, Kinoshita A, Yoshiura K, Niikawa N, Matsumoto N. Molecular characterization of *del(8)(p23.1p23.1)* in a case of congenital diaphragmatic hernia. *Am J Med Genet A* 2005; **136**: 49-51 [PMID: [15937941](#) DOI: [10.1002/ajmg.a.30778](#)]
 - 13 **Liu FR**, Hao SJ, Zhang C, Zhou BB, Wang X, Zheng L. Cytogenetic and molecular genetic study of duplication deletion of 8p in a new case. *Linchuang Erke Zazhi* 2020; **38**: 707-709 [DOI: [10.3969/j.issn.1000-3606.2020.09.016](#)]
 - 14 **Han X**, Zhang JM, Jiang WT, Hu Q, Tao J. Cytogenetic and molecular genetic study of a case with 8p inverted duplication deletion syndrome. *Zhonghua Yixue Yichuanxue Zazhi* 2010; **27**: 361-366 [DOI: [10.3760/cma.j.issn.1003-9406.2010.04.001](#)]



Published by **Baishideng Publishing Group Inc**
7041 Koll Center Parkway, Suite 160, Pleasanton, CA 94566, USA

Telephone: +1-925-3991568

E-mail: bpgoffice@wjgnet.com

Help Desk: <https://www.f6publishing.com/helpdesk>

<https://www.wjgnet.com>

