

World Journal of *Clinical Cases*

World J Clin Cases 2021 August 26; 9(24): 6964-7291



OPINION REVIEW

- 6964** Reconsideration of recurrence and metastasis in colorectal cancer
Wang R, Su Q, Yan ZP

MINIREVIEWS

- 6969** Multiple immune function impairments in diabetic patients and their effects on COVID-19
Lu ZH, Yu WL, Sun Y
- 6979** Discontinuation of antiviral therapy in chronic hepatitis B patients
Medas R, Liberal R, Macedo G

ORIGINAL ARTICLE

Case Control Study

- 6987** Textural differences based on apparent diffusion coefficient maps for discriminating pT3 subclasses of rectal adenocarcinoma
Lu ZH, Xia KJ, Jiang H, Jiang JL, Wu M

Retrospective Cohort Study

- 6999** Cost-effective screening using a two-antibody panel for detecting mismatch repair deficiency in sporadic colorectal cancer
Kim JB, Kim YI, Yoon YS, Kim J, Park SY, Lee JL, Kim CW, Park IJ, Lim SB, Yu CS, Kim JC

Retrospective Study

- 7009** Novel model combining contrast-enhanced ultrasound with serology predicts hepatocellular carcinoma recurrence after hepatectomy
Tu HB, Chen LH, Huang YJ, Feng SY, Lin JL, Zeng YY
- 7022** Influence of volar margin of the lunate fossa fragment fixation on distal radius fracture outcomes: A retrospective series
Meng H, Yan JZ, Wang B, Ma ZB, Kang WB, Liu BG
- 7032** Case series of COVID-19 patients from the Qinghai-Tibetan Plateau Area in China
Li JJ, Zhang HQ, Li PJ, Xin ZL, Xi AQ, Zhuo-Ma, Ding YH, Yang ZP, Ma SQ
- 7043** Patients' awareness about their own breast cancer characteristics
Geng C, Lu GJ, Zhu J, Li YY
- 7053** Fracture risk assessment in children with benign bone lesions of long bones
Li HB, Ye WS, Shu Q

SYSTEMATIC REVIEWS

- 7062 Mothers' experiences of neonatal intensive care: A systematic review and implications for clinical practice
Wang LL, Ma JJ, Meng HH, Zhou J

META-ANALYSIS

- 7073 *Helicobacter pylori* infection and peptic ulcer disease in cirrhotic patients: An updated meta-analysis
Wei L, Ding HG

CASE REPORT

- 7085 Tuberous sclerosis complex-lymphangiomyomatosis involving several visceral organs: A case report
Chen HB, Xu XH, Yu CG, Wan MT, Feng CL, Zhao ZY, Mei DE, Chen JL
- 7092 Long-term survivor of metastatic squamous-cell head and neck carcinoma with occult primary after cetuximab-based chemotherapy: A case report
Große-Thie C, Maletzki C, Junghanss C, Schmidt K
- 7099 Genetic mutations associated with sensitivity to neoadjuvant chemotherapy in metastatic colon cancer: A case report and review of literature
Zhao L, Wang Q, Zhao SD, Zhou J, Jiang KW, Ye YJ, Wang S, Shen ZL
- 7110 Coexistence of cervical extramedullary plasmacytoma and squamous cell carcinoma: A case report
Zhang QY, Li TC, Lin J, He LL, Liu XY
- 7117 Reconstruction of the chest wall after resection of malignant peripheral nerve sheath tumor: A case report
Guo X, Wu WM, Wang L, Yang Y
- 7123 A rare occurrence of a hereditary Birt-Hogg-Dubé syndrome: A case report
Lu YR, Yuan Q, Liu J, Han X, Liu M, Liu QQ, Wang YG
- 7133 Late-onset Leigh syndrome without delayed development in China: A case report
Liang JM, Xin CJ, Wang GL, Wu XM
- 7139 New mechanism of partial duplication and deletion of chromosome 8: A case report
Jiang Y, Tang S, He F, Yuan JX, Zhang Z
- 7146 S-1 plus temozolomide as second-line treatment for neuroendocrine carcinoma of the breast: A case report
Wang X, Shi YF, Duan JH, Wang C, Tan HY
- 7154 Minimally invasive treatment of hepatic hemangioma by transcatheter arterial embolization combined with microwave ablation: A case report
Wang LZ, Wang KP, Mo JG, Wang GY, Jin C, Jiang H, Feng YF
- 7163 Progressive disfiguring facial masses with pupillary axis obstruction from Morbihan syndrome: A case report
Zhang L, Yan S, Pan L, Wu SF

- 7169** Idiopathic basal ganglia calcification associated with new *MYORG* mutation site: A case report
Fei BN, Su HZ, Yao XP, Ding J, Wang X
- 7175** Geleophysic dysplasia caused by a mutation in *FBNI*: A case report
Tao Y, Wei Q, Chen X, Nong GM
- 7181** Combined laparoscopic-endoscopic approach for gastric glomus tumor: A case report
Wang WH, Shen TT, Gao ZX, Zhang X, Zhai ZH, Li YL
- 7189** Aspirin-induced long-term tumor remission in hepatocellular carcinoma with adenomatous polyposis coli stop-gain mutation: A case report
Lin Q, Bai MJ, Wang HF, Wu XY, Huang MS, Li X
- 7196** Prenatal diagnosis of isolated lateral facial cleft by ultrasonography and three-dimensional printing: A case report
Song WL, Ma HO, Nan Y, Li YJ, Qi N, Zhang LY, Xu X, Wang YY
- 7205** Therapy-related myeloid leukemia during erlotinib treatment in a non-small cell lung cancer patient: A case report
Koo SM, Kim KU, Kim YK, Uh ST
- 7212** Pediatric schwannoma of the tongue: A case report and review of literature
Yun CB, Kim YM, Choi JS, Kim JW
- 7218** Status epilepticus as a complication after COVID-19 mRNA-1273 vaccine: A case report
Šin R, Štruncová D
- 7224** Successful outcome of retrograde pancreatojejunostomy for chronic pancreatitis and infected pancreatic cysts: A case report
Kimura K, Adachi E, Toyohara A, Omori S, Ezaki K, Ihara R, Higashi T, Ohgaki K, Ito S, Maehara SI, Nakamura T, Maehara Y
- 7231** Incidentally discovered asymptomatic splenic hamartoma misdiagnosed as an aneurysm: A case report
Cao XF, Yang LP, Fan SS, Wei Q, Lin XT, Zhang XY, Kong LQ
- 7237** Secondary peripheral T-cell lymphoma and acute myeloid leukemia after Burkitt lymphoma treatment: A case report
Huang L, Meng C, Liu D, Fu XJ
- 7245** Retroperitoneal bronchogenic cyst in suprarenal region treated by laparoscopic resection: A case report
Wu LD, Wen K, Cheng ZR, Alwalid O, Han P
- 7251** Coexistent vestibular schwannoma and meningioma in a patient without neurofibromatosis: A case report and review of literature
Zhao LY, Jiang YN, Wang YB, Bai Y, Sun Y, Li YQ
- 7261** Thoracoabdominal duplication with hematochezia as an onset symptom in a baby: A case report
Yang SB, Yang H, Zheng S, Chen G

- 7269** Dental management of a patient with Moebius syndrome: A case report
Chen B, Li LX, Zhou LL
- 7279** Epidural gas-containing pseudocyst leading to lumbar radiculopathy: A case report
Chen Y, Yu SD, Lu WZ, Ran JW, Yu KX
- 7285** Regression of intervertebral disc calcification combined with ossification of the posterior longitudinal ligament: A case report
Wang XD, Su XJ, Chen YK, Wang WG

ABOUT COVER

Editorial Board Member of *World Journal of Clinical Cases*, Vijaykumar Chava, MD, Professor, Department of Periodontology, Narayana Dental College and Hospital, Nellore 524003, Andhra Pradesh, India. chava7@hotmail.com

AIMS AND SCOPE

The primary aim of *World Journal of Clinical Cases* (WJCC, *World J Clin Cases*) is to provide scholars and readers from various fields of clinical medicine with a platform to publish high-quality clinical research articles and communicate their research findings online.

WJCC mainly publishes articles reporting research results and findings obtained in the field of clinical medicine and covering a wide range of topics, including case control studies, retrospective cohort studies, retrospective studies, clinical trials studies, observational studies, prospective studies, randomized controlled trials, randomized clinical trials, systematic reviews, meta-analysis, and case reports.

INDEXING/ABSTRACTING

The WJCC is now indexed in Science Citation Index Expanded (also known as SciSearch®), Journal Citation Reports/Science Edition, Scopus, PubMed, and PubMed Central. The 2021 Edition of Journal Citation Reports® cites the 2020 impact factor (IF) for WJCC as 1.337; IF without journal self cites: 1.301; 5-year IF: 1.742; Journal Citation Indicator: 0.33; Ranking: 119 among 169 journals in medicine, general and internal; and Quartile category: Q3. The WJCC's CiteScore for 2020 is 0.8 and Scopus CiteScore rank 2020: General Medicine is 493/793.

RESPONSIBLE EDITORS FOR THIS ISSUE

Production Editor: Ji-Hong Lin; Production Department Director: Yun-Jie Ma; Editorial Office Director: Jin-Lei Wang.

NAME OF JOURNAL

World Journal of Clinical Cases

ISSN

ISSN 2307-8960 (online)

LAUNCH DATE

April 16, 2013

FREQUENCY

Thrice Monthly

EDITORS-IN-CHIEF

Dennis A Bloomfield, Sandro Vento, Bao-Gan Peng

EDITORIAL BOARD MEMBERS

<https://www.wjgnet.com/2307-8960/editorialboard.htm>

PUBLICATION DATE

August 26, 2021

COPYRIGHT

© 2021 Baishideng Publishing Group Inc

INSTRUCTIONS TO AUTHORS

<https://www.wjgnet.com/bpg/gerinfo/204>

GUIDELINES FOR ETHICS DOCUMENTS

<https://www.wjgnet.com/bpg/GerInfo/287>

GUIDELINES FOR NON-NATIVE SPEAKERS OF ENGLISH

<https://www.wjgnet.com/bpg/gerinfo/240>

PUBLICATION ETHICS

<https://www.wjgnet.com/bpg/GerInfo/288>

PUBLICATION MISCONDUCT

<https://www.wjgnet.com/bpg/gerinfo/208>

ARTICLE PROCESSING CHARGE

<https://www.wjgnet.com/bpg/gerinfo/242>

STEPS FOR SUBMITTING MANUSCRIPTS

<https://www.wjgnet.com/bpg/GerInfo/239>

ONLINE SUBMISSION

<https://www.f6publishing.com>

Secondary peripheral T-cell lymphoma and acute myeloid leukemia after Burkitt lymphoma treatment: A case report

Li Huang, Can Meng, Dan Liu, Xiang-Jun Fu

ORCID number: Li Huang 0000-0002-7012-8048; Can Meng 0000-0002-7774-6316; Dan Liu 0000-0002-6290-6153; Xiang-Jun Fu 0000-0001-8077-6201.

Author contributions: Huang L, Meng C and Liu D gathered the clinical information and drafted the manuscript; Fu XJ approved the final diagnosis and formulated the therapeutic strategies; All authors critically revised and gave the final approval of the manuscript.

Supported by Medical and Health Research Project of Hainan Province, No. 20A200013.

Informed consent statement: Written informed consent was obtained from the patient to publish this manuscript and any accompanying images.

Conflict-of-interest statement: The authors declared no potential conflicts of interest concerning the research, authorship and/or publication of this article.

CARE Checklist (2016) statement: The authors have read the CARE Checklist (2016), and the manuscript was prepared and revised according to the CARE Checklist (2016).

Open-Access: This article is an

Li Huang, Can Meng, Dan Liu, Xiang-Jun Fu, Department of Hematology, Hainan General Hospital, Hainan Affiliated Hospital of Hainan Medical University, Haikou 570311, Hainan Province, China

Corresponding author: Xiang-Jun Fu, Department of Hematology, Hainan General Hospital, Hainan Affiliated Hospital of Hainan Medical University, No. 19 Xiuhua Road, Xiuying District, Haikou 570311, Hainan Province, China. 78318742@qq.com

Abstract

BACKGROUND

Multiple primary cancer refers to more than one synchronous or sequential cancer in the same individual. Multiple primary cancer always presents as solid cancer or acute myeloid leukemia (AML) secondary to lymphoma. Here, we report a rare case of secondary peripheral T-cell lymphoma and AML after Burkitt lymphoma treatment.

CASE SUMMARY

A 54-year-old female patient was admitted to our hospital complaining of edema on her left lower limb. Physical examination revealed multiple superficial lymphadenectasis on her neck and pelvis. Color ultrasonography examination showed multiple uterine fibroids and a solid mass at the lower left side of the abdomen. Pathological biopsy revealed Burkitt lymphoma. After three hyper-CVAD (A + B) regimens, she achieved complete remission. Two years later, lymphadenectasis reoccurred. A relevant biopsy confirmed the diagnosis of peripheral T-cell lymphoma, which was accompanied by gastrointestinal invasion and hemocytopenia. Meanwhile, bone marrow examination revealed AML. On the second day of scheduled treatment, she developed gastrointestinal bleeding, peptic ulcers, and hemorrhagic shock and was critically ill. She was then discharged from the hospital due to financial concerns.

CONCLUSION

This is the first report of secondary peripheral T-cell lymphoma and AML after Burkitt lymphoma treatment with heterochronous and synchronal multiple primary cancers.

Key Words: Burkitt lymphoma; Peripheral T-cell lymphoma; Acute myeloid leukemia; Multiplicity carcinoma; Positron emission tomography-computed tomography; Case report

open-access article that was selected by an in-house editor and fully peer-reviewed by external reviewers. It is distributed in accordance with the Creative Commons Attribution NonCommercial (CC BY-NC 4.0) license, which permits others to distribute, remix, adapt, build upon this work non-commercially, and license their derivative works on different terms, provided the original work is properly cited and the use is non-commercial. See: <http://creativecommons.org/licenses/by-nc/4.0/>

Manuscript source: Unsolicited manuscript

Specialty type: Medicine, research and experimental

Country/Territory of origin: China

Peer-review report's scientific quality classification

Grade A (Excellent): 0
Grade B (Very good): 0
Grade C (Good): C, C, C
Grade D (Fair): 0
Grade E (Poor): 0

Received: April 16, 2021

Peer-review started: April 16, 2021

First decision: April 27, 2021

Revised: May 25, 2021

Accepted: July 5, 2021

Article in press: July 5, 2021

Published online: August 26, 2021

P-Reviewer: Intagliata E, Yoshida N

S-Editor: Gao CC

L-Editor: Filipodia

P-Editor: Ma YJ



©The Author(s) 2021. Published by Baishideng Publishing Group Inc. All rights reserved.

Core Tip: Frequently, secondary malignancies are not identified in a timely manner or are misdiagnosed. Literature indicates that secondary malignancies occur sporadically and spread gradually. The survival time for secondary cancer depends on the extent of tumor lesions than the number of tumors. This paper presents a rare case of secondary cancer to provide a complete understanding to the medical staff allowing them to make early diagnoses and initiate rational and integrated treatments to prolong the survival time and improve the prognosis.

Citation: Huang L, Meng C, Liu D, Fu XJ. Secondary peripheral T-cell lymphoma and acute myeloid leukemia after Burkitt lymphoma treatment: A case report. *World J Clin Cases* 2021; 9(24): 7237-7244

URL: <https://www.wjgnet.com/2307-8960/full/v9/i24/7237.htm>

DOI: <https://dx.doi.org/10.12998/wjcc.v9.i24.7237>

INTRODUCTION

Multiple primary cancer (MPC) refers to two or more simultaneous or sequential occurrences of primary malignant tumors in the same individual arising from different sites and/or with different histology or morphology[1]. Depending on the time interval between two cancer occurrences, MPC can be classified as synchronous (occurrence of two cancers detected simultaneously or sequentially within a time interval of ≤ 6 mo) or heterochronous (occurrence of two cancers detected sequentially within a time interval of > 6 mo)[1]. MPCs are always reported as two or more solid cancers[1-4], sometimes as secondary malignancies following nonsolid cancer treatment[1]. However, both lymphoma and leukemia secondary to lymphoma treatment are rare. This report presents a rare case of secondary peripheral T-cell lymphoma not otherwise specified (PTCL-NOS) and acute myeloid leukemia (AML) after treatment for Burkitt lymphoma and a review of the relevant MPC literature to understand the clinical features, pathogenesis, treatment and prognosis of MPC.

CASE PRESENTATION

Chief complaints

A 54-year-old woman was admitted to our hospital with a complaint of edema on her left lower limb on April 7, 2017. The patient showed no signs of abdominal pain, abdominal distension, low fever, night sweats, fatigue, frequent urination, urgent urination, dysuria, abnormal vaginal bleeding or discomfort owing to vaginal discharge.

History of present illness

She was fit and had no history of exposure to chemicals or radiation.

Personal and family history

She had no specific personal or family medical history.

Physical examination

Physical examination revealed multiple superficial lymphadenectasis on her neck and a palpable mass of approximately 8 cm \times 6 cm on the lower left side of her abdomen.

Laboratory examinations

A blood test for hepatitis B virus (HBV) showed an HBV surface antigen of > 225.00 ng/mL, HBV e antigen of 10.822 PEI U/mL, HBV core antibody 11.082 PEI U/mL and positive HBV pre-S1 antigen.

Imaging examinations

Pelvic ultrasound examination revealed multiple uterine fibroids, with the largest located at the bottom of the uterus (5.5 cm × 5.4 cm) and a solid mass at the lower left side of the abdomen (7.5 cm × 5.7 cm). Color Doppler echocardiography revealed mild aortic valve regurgitation. No abnormalities were observed in the cardiac morphology, structure and valve activity.

Further diagnostic work-up

Ultrasound-guided pathological biopsy of the mass on the lower left abdomen showed local necrosis. The immunohistochemistry results were as follows: cluster of differentiation 20 (CD20)+, CD79a+, CD3-, CD43-, CD21+, Ki-67 (90%+), CD10+, B-cell lymphoma 6 (Bcl-6)+, CD38+, terminal deoxynucleotidyl transferase-, CD5-, CD30-, CD23-, Cyclin D1-, Bcl-2-, melanoma ubiquitous mutated protein 1+/-, myeloperoxidase-, CD117-, creatine kinase-, vimentin+, CD56-, CD99-, S-100-, c-Myc (70%+) and EBV encoded small RNAs (EBER)+ (Figure 1).

Quantitative serum EBV was 2.35×10^4 copies/mL. The morphology of bone marrow cells indicated active bone marrow hyperplasia and a lymphocyte ratio of 18.0%, with a ratio of 3.0% for lymphoblasts and prolymphocytes. Immunotyping revealed that lymphocytes accounted for approximately 15% of the karyocytes, with a normal distribution of lymphocyte subsets. The protoregional cells accounted for approximately 1% of the karyocytes, with a scattered distribution. Monocytes accounted for approximately 5.5% of the karyocytes, with a mature phenotype. Granulocytes accounted for about 67.5% of the karyocytes, without abnormal development. Positron emission tomography-computed tomography (PET/CT) showed fluorodeoxyglucose uptake in the nasopharyngeal superior/posterior wall with multiple lymph nodes in the bilateral neck, multiple nodules and masses in the abdominal and pelvic cavities and local thickening of the ascending colon, partial small intestine and rectum. Burkitt lymphoma Stage IV in group A with high risk was diagnosed, complicated with uterine leiomyoma and chronic hepatitis B.

FINAL DIAGNOSIS

Burkitt lymphoma.

TREATMENT

The patient received entecavir to treat the HBV infection. On May 6, 2017, she received a low-dose dexamethasone (10 mg, days 1-5) + cyclophosphamide (0.2 g, days 1-3) regimen for cytoreduction. Two cycles of chemotherapy with the hyper-CVAD (A + B) regimen were performed on May 12, 2017 and July 19, 2017. PET/CT on October 9, 2017 showed complete remission. Next, another cycle of chemotherapy with the hyper-CVAD (A + B) regimen was performed on October 13, 2017.

OUTCOME AND FOLLOW-UP

The PET/CT in January 2018 showed complete remission.

During the following 2.5 years, the patient was admitted to our hospital three times because of interstitial pneumonia, and antifungal treatment was performed. The follow-up PET/CT on April 18, 2019 showed increased fluorodeoxyglucose metabolism in the bilateral nasopharynx walls, bilateral submaxillary, bilateral neck, bilateral axilla and bilateral groin multiple lymphadenectasis, thickened intercostal pleura between the 11th and 12th right ribs and multiple nodules in peritoneal, retroperitoneal and pelvic cavities. Recurrence of lymphoma was suspected. However, the patient refused to be hospitalized for re-examination and treatment.

On July 16, 2020, the patient was readmitted to our hospital due to severe diarrhea episodes for 5 d. The diarrhea was brought under control after oral administration of levofloxacin, but the stools were still sparse (once per day). Physical examination revealed cervical lymphadenectasis. Routine blood examination results were as follows: white blood cells: 8.43×10^9 /L, neutrophils: 4.12×10^9 /L, hemoglobin: 112 g/L, platelets: 49×10^9 /L, EBV polymerase chain reaction: 5.63×10^4 copies/mL, erythrocyte sedimentation rate: 80.0 mm/h and lactate dehydrogenase: 322.4 U/L.

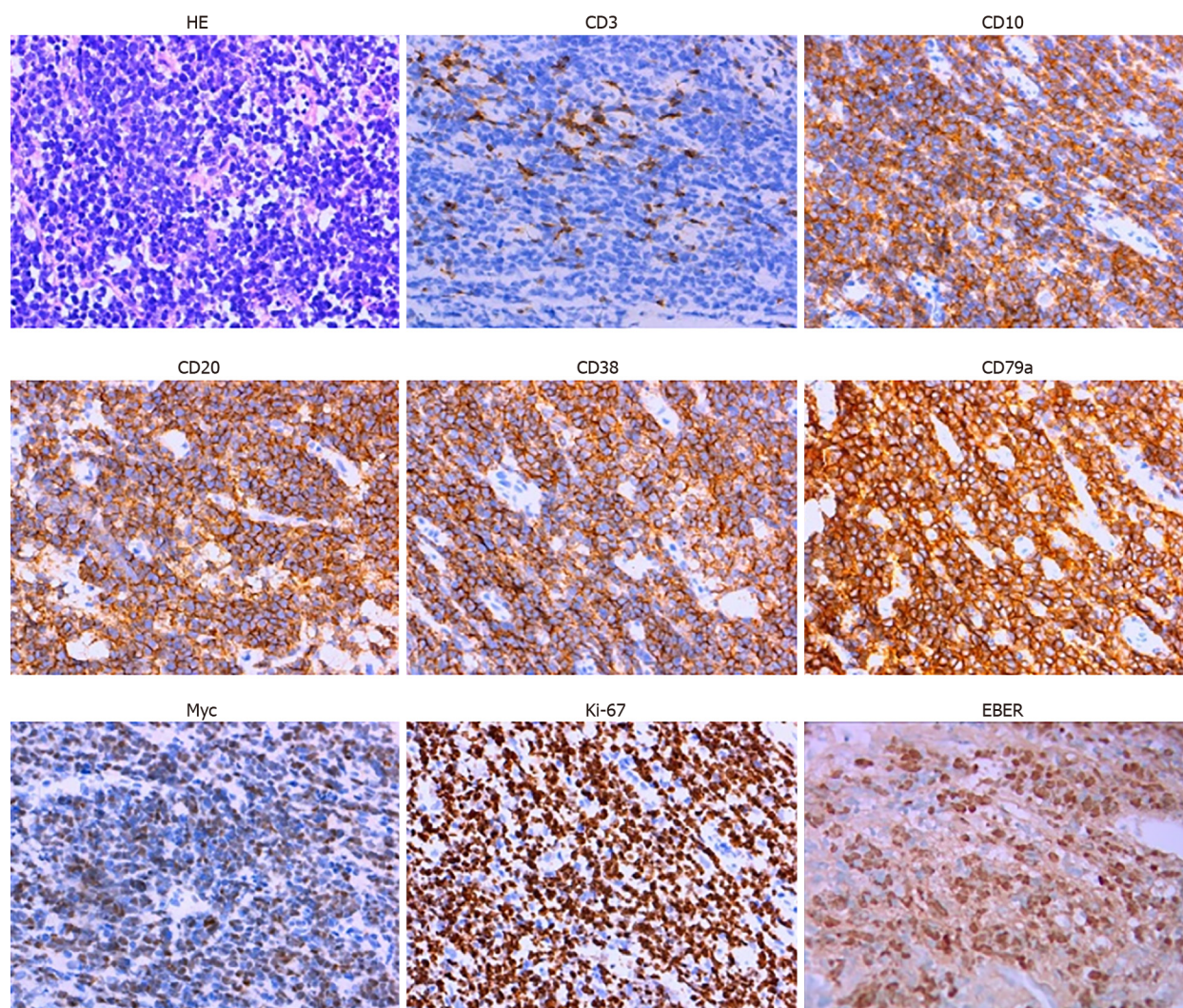


Figure 1 Hematoxylin-eosin staining showing local necrosis and immunohistochemistry of the pathological biopsy of the lower-left abdomen mass in April 2017. HE: Hematoxylin-eosin.

Ultrasound-guided biopsy of the lower left cervical lymph nodes showed CD3(+), granzyme B (+), CD8 (+), CD4 (-), CD20 (-), CD19 (-), CD79a (-), Bcl-2 (-), Bcl-6 (-), CD10 (-), CD21 (-), Cyclin D1 (-), anaplastic lymphoma receptor tyrosine kinase (-), CD30 (-), creatine kinase (-), CD56 (-), creatine kinase 5/6 (-), SRY-related HMG-box-11 (-), c-Myc (+, approximately 20%), melanoma ubiquitous mutated protein 1 (+, approximately 50%), Ki-67 (+, approximately 70%), CD5 (partially +) and EBER (+). T-cell lymphoma was suspected.

Colonoscopy results showed a submucosal eminence of approximately 1.0 cm × 1.0 cm with a smooth surface in the cecum. Further biopsy results showed this submucosal eminence was consistent with lymphoma in structure and consistent with the cervical lymph nodes in terms of classification.

Another ultrasound-guided biopsy of the left cervical lymph nodes on July 31, 2020 showed CD2 (+), CD3 (+), CD8 (-), CD56 (-), Ki67 (70%), T-cell intracytoplasmic antigen-1 (+), granzyme B (+), P53 (+, wild type), c-Myc (10%+), CD20 (-), CD7 (+), programmed cell death protein 1 (40%+), programmed death-ligand 1 (interstitial cell +) and EBER (-) (Figure 2). PTCL-NOS was diagnosed. Moreover, TCR β rearrangement was positive in PTCL-NOS.

Considering the patient's poor condition and gastrointestinal tumor invasion, COP (cyclophosphamide, vincristine and methylprednisolone) was administered on August 17, 2020 for cytoreduction. Bone marrow morphology examination on September 4, 2020 showed an abnormal cell colony in the region where myeloid cells extended to the protocells. The colony accounted for approximately 80% of the karyocytes, expressing CD4, CD13, CD15, CD33, CD38, CD58, CD64 and myeloperoxidase and partially expressing CD11b (Figure 3). Lymphoid proliferation was inhibited. AML was diagnosed.

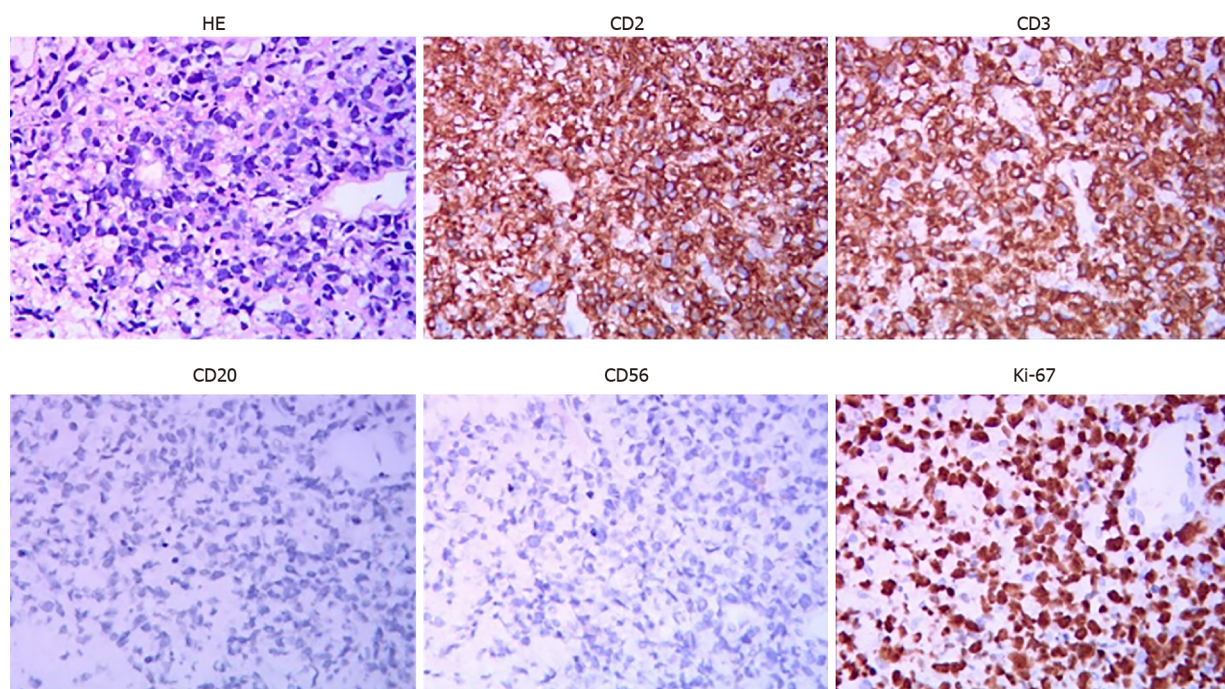


Figure 2 Hematoxylin-eosin staining and immunohistochemistry of the pathological biopsy of the left cervical lymph nodes on July 31, 2020. HE: Hematoxylin-eosin.

Considering her poor health condition, the patient was scheduled to receive decitabine (25 mg, days 1-5) and venetoclax (100 mg, once daily on days 1-7 and 200 mg on days 8-28) treatment supplemented with symptomatic and supportive treatments starting from October 2, 2020. However, she developed gastrointestinal bleeding, peptic ulcers and hemorrhagic shock on the second day of treatment, and the chemotherapy was suspended. Although many symptomatic and supportive treatments were given, the patient developed diarrhea in the afternoon of October 18, and her blood pressure dropped. She was critically ill, but her family members refused any further appropriate treatments, such as tracheal intubation. She was then discharged from the hospital.

The clinical course of the present case was summarized in [Figure 4](#).

DISCUSSION

MPC was first recognized and reported by Owen[5] in 1921 and later by other researchers[6,7]. The frequency of MPC is reported to be in the range of 2%-17%^[1], and the reported frequency in China is only 0.84% to 1.31%^[8-10]. With the progress in early cancer diagnosis and treatment, patient survival time with malignant tumors has been prolonged, leading to an increased frequency of MPC. MPCs always occur as solid cancers. Although MPC associated with lymphoma and leukemia has been reported^[11], the present case is the first report on secondary peripheral T-cell lymphoma and AML after the treatment of Burkitt lymphoma. Two years after treatment for Burkitt lymphoma, lymphadenectasis and gastrointestinal neoplasm occurred, which could have been easily misdiagnosed as metastatic or recurrent primary cancer. Currently, pathological biopsy is still the formal diagnosis method for tumors. Therefore, MPC diagnosis should be based on repeated multisite biopsies and should be conformed after multicenter consultation.

The mechanism for MPC remains unclear. Relevant factors may be roughly divided into endogenous factors (low immune function of patients with tumors), exogenous factors (such as environmental reasons and exposure to radiation and chemicals), genetic factors (such as family genetic defects and continuous action of carcinogenic factors) and factors related to appropriate therapy (such as the carcinogenic effects of radiation and chemotherapy)^[1,12,13]. In this case, the patient developed PTCL-NOS together with AML approximately 2 years after being treated for Burkitt lymphoma. Although they were all hematological malignancies, the initial B-cell lymphoma and subsequent PTCL-NOS and AML had different sources of malignant cells. In this case,

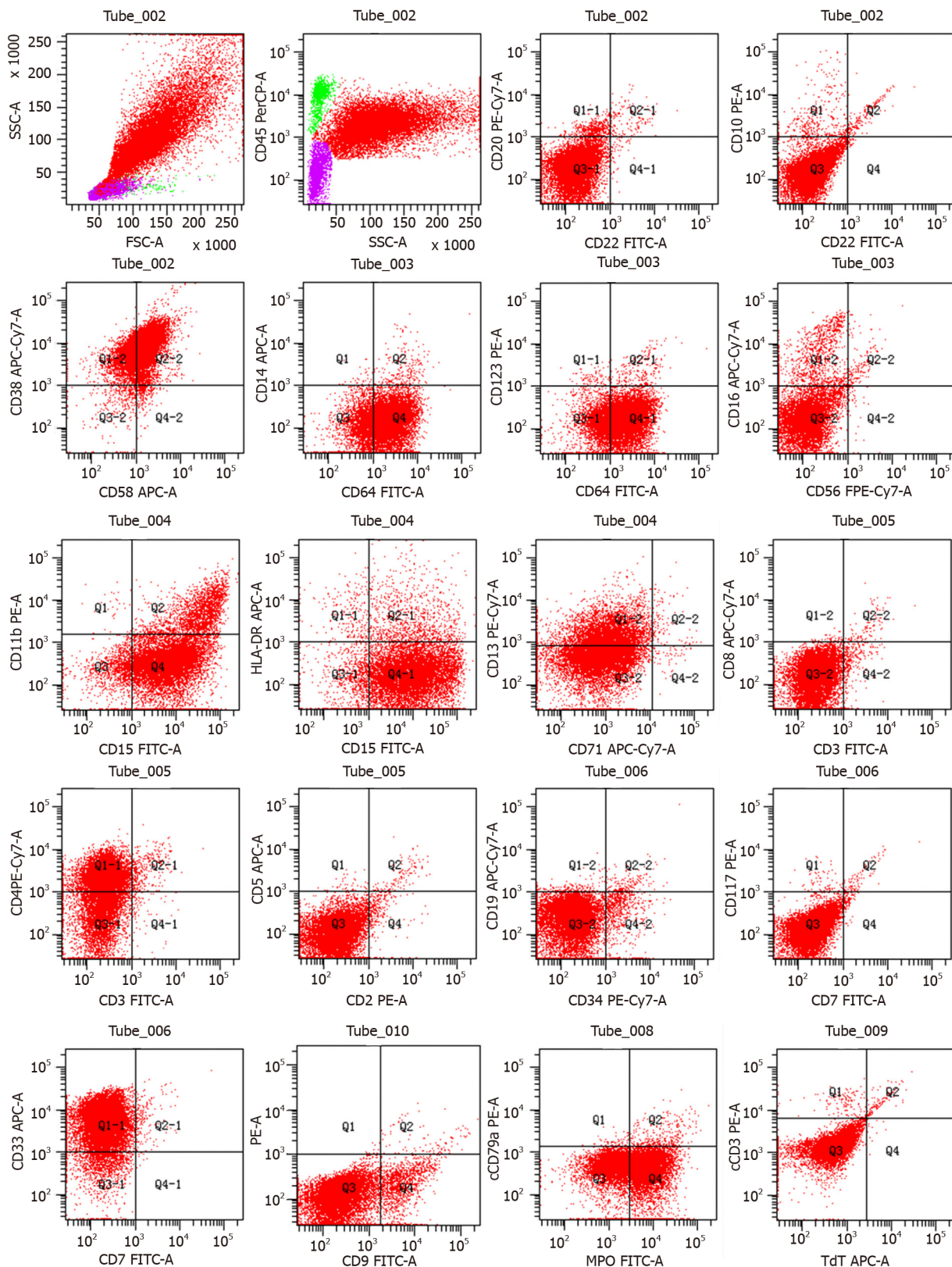


Figure 3 Flow cytometry showing the expression profile of bone marrow collected on September 4, 2020.

both heterochronous and synchronal MPCs occurred. The former is related to DNA strand breaks, gene mutations and chromosome aberrations caused by multiple chemotherapies, while the latter is scarce. The patient's constitution may have contributed to this. Next-generation sequencing can help understand if tumors originate from different clones, thus guiding appropriate treatment. However, the patient refused further diagnosis and treatment due to economic reasons. Moreover, both Burkitt lymphoma and PTCL-NOS in the presented case had EBER, indicating

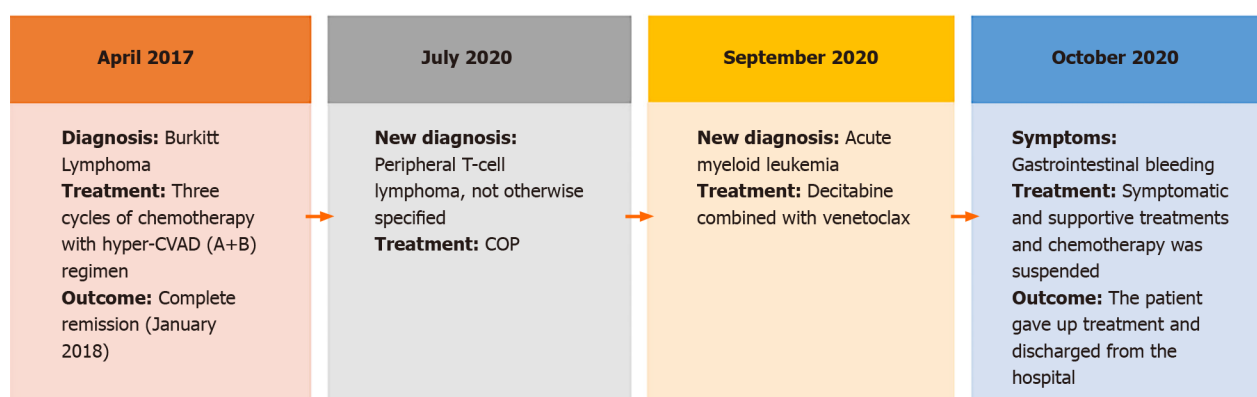


Figure 4 The clinical course of the present case. COP: Cyclophosphamide, vincristine and methylprednisolone.

common B/T progenitors may have EBV in this case. However, we could not perform Southern blotting analysis at our center to confirm this hypothesis.

The prognosis for MPC is poor, and there is still no consensus on the appropriate treatment. Currently, a patient-centered multidisciplinary comprehensive treatment model is recommended[14]. For patients with solid tumors, all lesions should be completely removed either simultaneously or successively. If a lesion cannot be excised, comprehensive therapies such as immunotherapy, targeted therapy and chemotherapy can be employed. However, the accumulation of drug toxicity or radiation doses in the same area should be monitored[15]. Burkitt lymphoma in this patient was in complete remission after the initial treatment until January 2018 when lymphadenectasis reoccurred, and PTCL-NOS complicated with AML newly occurred. For further diagnosis and treatment, chemotherapy is considered the primary choice. The patient was unable to withstand intense chemotherapy owing to her weak physical condition. Consequently, optimal supportive treatment was considered. However, she did not continue the treatment due to economic limitations.

CONCLUSION

In conclusion, we report a case of secondary PTCL-NOS complicated with AML and Burkitt lymphoma, with both heterochronous and synchronal MPCs. When a new tumor is diagnosed, its relationship to the old tumor treatment should be determined. If the economic condition allows, second-generation sequencing should be performed to identify the origin of tumors.

ACKNOWLEDGEMENTS

We thank Pro. Lin L from the Department of Hematology, Hainan Provincial People's Hospital Hainan Affiliated Hospital of Hainan Medical University for guiding the organization and revising medical records, Pro. Fu XJ from the Department of Hematology, Hainan Provincial People's Hospital Hainan Affiliated Hospital of Hainan Medical University for providing relevant medical information for the case summary and Dr. Liu D, Dr. Meng C and Dr. Lin XY for their help in medical writing.

REFERENCES

- 1 **Vogt A**, Schmid S, Heinimann K, Frick H, Herrmann C, Cerny T, Omlin A. Multiple primary tumours: challenges and approaches, a review. *ESMO Open* 2017; **2**: e000172 [PMID: [28761745](#) DOI: [10.1136/esmoopen-2017-000172](#)]
- 2 **Zhang ZG**, Chen Y, Ji R, Zhao YJ, Wang J, Robinson L, Chen XP, Zhang L. Synchronous cancers of gallbladder carcinoma and combined hepatocellular cholangiocarcinoma: an unusual case and literature review. *BMC Cancer* 2018; **18**: 1046 [PMID: [30373546](#) DOI: [10.1186/s12885-018-4969-2](#)]
- 3 **Nezu K**, Okubo T, Shiraiwa M, Nozawa Y, Kyan A. Systemic treatment for coexisting mucinous urethral adenocarcinoma and prostate adenocarcinoma. *IJU Case Rep* 2020; **3**: 261-264 [PMID: [33163919](#) DOI: [10.1002/iju5.12210](#)]

- 4 **Xu Y**, Chen QN, Wang H, Liu NB, Shi BM. Synchronous hepatocellular carcinoma and gallbladder adenocarcinoma with neuroendocrine differentiation: a case report and literature review. *BMC Surg* 2020; **20**: 246 [PMID: [33081789](#) DOI: [10.1186/s12893-020-00905-6](#)]
- 5 **Owen LJ**. Multiple malignant neoplasms. *JAMA* 1921; **76**: 1329
- 6 **Hanlon FR**. Multiple Primary Carcinomas. *Am J Cancer* 1931; **15**: 2001
- 7 **Warren S**. Multiple primary malignant tumors. A survey of the literature and a statistical study. *Am J Cancer* 1932; **16**: 1358-1414
- 8 **Liu Z**, Liu C, Guo W, Li S, Bai O. Clinical analysis of 152 cases of multiple primary malignant tumors in 15,398 patients with malignant tumors. *PLoS One* 2015; **10**: e0125754 [PMID: [25945938](#) DOI: [10.1371/journal.pone.0125754](#)]
- 9 **Lv M**, Zhang X, Shen Y, Wang F, Yang J, Wang B, Chen Z, Li P, Li S. Clinical analysis and prognosis of synchronous and metachronous multiple primary malignant tumors. *Medicine (Baltimore)* 2017; **96**: e6799 [PMID: [28445321](#) DOI: [10.1097/MD.00000000000006799](#)]
- 10 **Jiao F**, Yao LJ, Zhou J, Hu H, Wang LW. Clinical features of multiple primary malignancies: a retrospective analysis of 72 Chinese patients. *Asian Pac J Cancer Prev* 2014; **15**: 331-334 [PMID: [24528052](#) DOI: [10.7314/apjcp.2014.15.1.331](#)]
- 11 **Wu RJ**, Zheng RJ, Huang YQ, Ma XD. [Chidamide combined with chemotherapy for treatment of therapy-related acute myeloid leukemia secondary to peripheral T-cell lymphoma: a case report and literatures review]. *Zhonghua Xueye Xue Zazhi* 2019; **40**: 685-687 [PMID: [31495139](#) DOI: [10.3760/cma.j.issn.0253-2727.2019.08.013](#)]
- 12 **Wood ME**, Vogel V, Ng A, Foxhall L, Goodwin P, Travis LB. Second malignant neoplasms: assessment and strategies for risk reduction. *J Clin Oncol* 2012; **30**: 3734-3745 [PMID: [23008293](#) DOI: [10.1200/JCO.2012.41.8681](#)]
- 13 **Copur MS**, Manapuram S. Multiple Primary Tumors Over a Lifetime. *Oncology (Williston Park)* 2019; **33** [PMID: [31365752](#)]
- 14 **Digestive tract Oncology Professional Committee of Chinese Association of Research Hospitals**; Multidisciplinary Comprehensive Treatment Committee SB; Chinese Medical Doctors Association. Expert consensus on the diagnosis and treatment model of the multidisciplinary treatment collaboration group for gastric cancer. *Zhongguo Shiyong Waikao Zazhi* 2017; **37**: 37-38
- 15 **Kumar S**. Second malignant neoplasms following radiotherapy. *Int J Environ Res Public Health* 2012; **9**: 4744-4759 [PMID: [23249860](#) DOI: [10.3390/ijerph9124744](#)]



Published by **Baishideng Publishing Group Inc**
7041 Koll Center Parkway, Suite 160, Pleasanton, CA 94566, USA

Telephone: +1-925-3991568

E-mail: bpgoffice@wjgnet.com

Help Desk: <https://www.f6publishing.com/helpdesk>

<https://www.wjgnet.com>

