

World Journal of *Clinical Cases*

World J Clin Cases 2021 September 6; 9(25): 7292-7613



Contents

Thrice Monthly Volume 9 Number 25 September 6, 2021

EDITORIAL

- 7292 Radiation oncology practice during COVID-19 pandemic in developing countries

Abuhijla F, Abuhijlih R, Mohamad I

OPINION REVIEW

- 7297 Complete mesocolic excision and central vascular ligation in colorectal cancer in the era of minimally invasive surgery

Franceschilli M, Di Carlo S, Vinci D, Sensi B, Siragusa L, Bellato V, Caronna R, Rossi P, Cavallaro G, Guida A, Sibio S

- 7306 Fecal diversion in complex anal fistulas: Is there a way to avoid it?

Garg P, Yagnik VD, Dawka S

MINIREVIEWS

- 7311 Regulatory roles of extracellular vesicles in immune responses against *Mycobacterium tuberculosis* infection

Yan Z, Wang H, Mu L, Hu ZD, Zheng WQ

- 7319 Aortic stenosis and Heyde's syndrome: A comprehensive review

Lourdusamy D, Mupparaju VK, Sharif NF, Ibebuogu UN

ORIGINAL ARTICLE

Retrospective Study

- 7330 Key determinants of misdiagnosis of tracheobronchial tuberculosis among senile patients in contemporary clinical practice: A retrospective analysis

Tang F, Lin LJ, Guo SL, Ye W, Zha XK, Cheng Y, Wu YF, Wang YM, Lyu XM, Fan XY, Lyu LP

- 7340 Long-term outcome of pancreatic function following oncological surgery in children: Institutional experience and review of the literature

Bolasco G, Capriati T, Grimaldi C, Monti L, De Pasquale MD, Patera IP, Spada M, Maggiore G, Diamanti A

- 7350 Efficacy of arbidol in COVID-19 patients: A retrospective study

Wei S, Xu S, Pan YH

- 7358 Characteristic analysis of clinical coronary heart disease and coronary artery disease concerning young and middle-aged male patients

Peng KG, Yu HL

- 7365 Quantitative analysis of early diabetic retinopathy based on optical coherence tomography angiography biological image

Shi Y, Lin PY, Ruan YM, Lin CF, Hua SS, Li B

- 7372** Mucin 1 and interleukin-11 protein expression and inflammatory reactions in the intestinal mucosa of necrotizing enterocolitis children after surgery

Pan HX, Zhang CS, Lin CH, Chen MM, Zhang XZ, Yu N

Observational Study

- 7381** Research on the prognosis of different types of microvessels in bladder transitional cell carcinoma

Wang HB, Qin Y, Yang JY

- 7391** Is burnout a mediating factor between sharps injury and work-related factors or musculoskeletal pain?

Chen YH, Tsai CF, Yeh CJ, Jong GP

- 7405** Role of international normalized ratio in nonpulmonary sepsis screening: An observational study

Zhang J, Du HM, Cheng MX, He FM, Niu BL

Randomized Controlled Trial

- 7417** Clinical effectiveness of adding probiotics to a low FODMAP diet: Randomized double-blind placebo-controlled study

Turan B, Bengi G, Cehreli R, Akpınar H, Soytürk M

SYSTEMATIC REVIEWS

- 7433** Association between COVID-19 and anxiety during social isolation: A systematic review

Santos ERRD, Silva de Paula JL, Tardieux FM, Costa-e-Silva VN, Lal A, Leite AFB

CASE REPORT

- 7445** Avascular necrosis of the first metatarsal head in a young female adult: A case report and review of literature

Siu RWH, Liu JHP, Man GCW, Ong MTY, Yung PSH

- 7453** Successful treatment of solitary bladder plasmacytoma: A case report

Cao JD, Lin PH, Cai DF, Liang JH

- 7459** Pseudomyxoma peritonei originating from intestinal duplication: A case report and review of the literature

Han XD, Zhou N, Lu YY, Xu HB, Guo J, Liang L

- 7468** Agranulocytosis following injection of inactivated Japanese encephalitis vaccine (Vero cell): A case report

Wang L, Zhang X, Liu YT

- 7472** Importance of clinical suspicion and multidisciplinary management for early diagnosis of a cardiac laminopathy patient: A case report

Santobuono VE, Guaricci AI, Carulli E, Bozza N, Pepe M, Ranauro A, Ranieri C, Carella MC, Loizzi F, Resta N, Favale S, Forleo C

- 7478** First case of forearm crisscross injury in children: A case report

Jiang YK, Wang YB, Peng CG, Qu J, Wu DK

- 7484** Octreotide-induced acute life-threatening gallstones after vicarious contrast medium excretion: A case report
Han ZH, He ZM, Chen WH, Wang CY, Wang Q
- 7490** Acute deep venous thrombosis induced by May-Thurner syndrome after spondylolisthesis surgery: A case report and review of literature
Yue L, Fu HY, Sun HL
- 7498** Successful treatment of refractory lung adenocarcinoma harboring a germline *BRCA2* mutation with olaparib: A case report
Zhang L, Wang J, Cui LZ, Wang K, Yuan MM, Chen RR, Zhang LJ
- 7504** Effective treatment of polyneuropathy, organomegaly, endocrinopathy, M-protein, and skin changes syndrome with congestive heart failure: A case report
Fu LY, Zhang HB
- 7512** Awake craniotomy for auditory brainstem implant in patients with neurofibromatosis type 2: Four case reports
Wang DX, Wang S, Jian MY, Han RQ
- 7520** Coexistence of tuberculosis and squamous cell carcinoma in the right main bronchus: A case report
Jiang H, Li YQ
- 7527** Is simultaneous presence of IgG4-positive plasma cells and giant-cell hepatitis a coincidence in autoimmune hepatitis? A case report
Tan YW, Wang JM, Chen L
- 7535** Surgical treatment of delayed cervical infection and incomplete quadriplegia with fish-bone ingestion: A case report
Li SY, Miao Y, Cheng L, Wang YF, Li ZQ, Liu YB, Zou TM, Shen J
- 7542** Neonatal biliary atresia combined with preduodenal portal vein: A case report
Xiang XL, Cai P, Zhao JG, Zhao HW, Jiang YL, Zhu ML, Wang Q, Zhang RY, Zhu ZW, Chen JL, Gu ZC, Zhu J
- 7551** Hemorrhagic transformation after acute ischemic stroke caused by polycythemia vera: Report of two case
Cao YY, Cao J, Bi ZJ, Xu SB, Liu CC
- 7558** Treatment of lower part of glenoid fractures through a novel axillary approach: A case report
Jia X, Zhou FL, Zhu YH, Jin DJ, Liu WX, Yang ZC, Liu RP
- 7564** Trigger finger at the wrist caused by an intramuscular lipoma within the carpal tunnel: A case report
Huang C, Jin HJ, Song DB, Zhu Z, Tian H, Li ZH, Qu WR, Li R
- 7572** Thrombolysis and embolectomy in treatment of acute stroke as a bridge to open-heart resection of giant cardiac myxoma: A case report
Chang WS, Li N, Liu H, Yin JJ, Zhang HQ
- 7579** Breast adenoid cystic carcinoma arising in microglandular adenosis: A case report and review of literature
An JK, Woo JJ, Kim EK, Kwak HY

- 7588** Diagnosis and management of ophthalmic zoster sine herpette accompanied by cervical spine disc protrusion: A case report
Yun G, Kim E, Baik J, Do W, Jung YH, You CM
- 7593** Hemorrhagic pericardial effusion following treatment with infliximab: A case report and literature review
Li H, Xing H, Hu C, Sun BY, Wang S, Li WY, Qu B
- 7600** Wernicke's encephalopathy in a rectal cancer patient with atypical radiological features: A case report
Nie T, He JL
- 7605** Total hip revision with custom-made spacer and prosthesis: A case report
Liu YB, Pan H, Chen L, Ye HN, Wu CC, Wu P, Chen L

ABOUT COVER

Editorial Board Member of *World Journal of Clinical Cases*, Lan Sun, MD, PhD, Chief Physician, Professor, Department of Oncology, The People's Hospital of Bishan District, Chongqing 402760, China. sunlan6203@163.com

AIMS AND SCOPE

The primary aim of *World Journal of Clinical Cases* (WJCC, *World J Clin Cases*) is to provide scholars and readers from various fields of clinical medicine with a platform to publish high-quality clinical research articles and communicate their research findings online.

WJCC mainly publishes articles reporting research results and findings obtained in the field of clinical medicine and covering a wide range of topics, including case control studies, retrospective cohort studies, retrospective studies, clinical trials studies, observational studies, prospective studies, randomized controlled trials, randomized clinical trials, systematic reviews, meta-analysis, and case reports.

INDEXING/ABSTRACTING

The WJCC is now indexed in Science Citation Index Expanded (also known as SciSearch®), Journal Citation Reports/Science Edition, Scopus, PubMed, and PubMed Central. The 2021 Edition of Journal Citation Reports® cites the 2020 impact factor (IF) for WJCC as 1.337; IF without journal self cites: 1.301; 5-year IF: 1.742; Journal Citation Indicator: 0.33; Ranking: 119 among 169 journals in medicine, general and internal; and Quartile category: Q3. The WJCC's CiteScore for 2020 is 0.8 and Scopus CiteScore rank 2020: General Medicine is 493/793.

RESPONSIBLE EDITORS FOR THIS ISSUE

Production Editor: Yan-Xia Xing; **Production Department Director:** Xiang Li; **Editorial Office Director:** Jin-Lai Wang.

NAME OF JOURNAL

World Journal of Clinical Cases

ISSN

ISSN 2307-8960 (online)

LAUNCH DATE

April 16, 2013

FREQUENCY

Thrice Monthly

EDITORS-IN-CHIEF

Dennis A Bloomfield, Sandro Vento, Bao-Gan Peng

EDITORIAL BOARD MEMBERS

<https://www.wjgnet.com/2307-8960/editorialboard.htm>

PUBLICATION DATE

September 6, 2021

COPYRIGHT

© 2021 Baishideng Publishing Group Inc

INSTRUCTIONS TO AUTHORS

<https://www.wjgnet.com/bpg/gerinfo/204>

GUIDELINES FOR ETHICS DOCUMENTS

<https://www.wjgnet.com/bpg/GerInfo/287>

GUIDELINES FOR NON-NATIVE SPEAKERS OF ENGLISH

<https://www.wjgnet.com/bpg/gerinfo/240>

PUBLICATION ETHICS

<https://www.wjgnet.com/bpg/GerInfo/288>

PUBLICATION MISCONDUCT

<https://www.wjgnet.com/bpg/gerinfo/208>

ARTICLE PROCESSING CHARGE

<https://www.wjgnet.com/bpg/gerinfo/242>

STEPS FOR SUBMITTING MANUSCRIPTS

<https://www.wjgnet.com/bpg/GerInfo/239>

ONLINE SUBMISSION

<https://www.f6publishing.com>



Total hip revision with custom-made spacer and prosthesis: A case report

Yang-Bo Liu, Hao Pan, Li Chen, Hao-Nan Ye, Cong-Cong Wu, Peng Wu, Lei Chen

ORCID number: Yang-Bo Liu 0000-0002-1180-4974; Hao Pan 0000-0002-6921-9671; Li Chen 0000-0002-6717-5708; Hao-Nan Ye 0000-0002-2606-8826; Cong-Cong Wu 0000-0002-7653-9198; Peng Wu 0000-0002-8650-7106; Lei Chen 0000-0001-9128-1116.

Author contributions: Liu YB, Pan H, and Chen L conducted the literature review; Liu YB, Pan H and Chen Li contributed to the drafting of the manuscript; Ye HN and Wu CC collected the medical records of this case; Chen L assisted in revising the manuscript; Wu P participated in surgical planning, surgery, and patient management; Chen L was the chief surgeon of the patient and was responsible for important revisions of the manuscript; all authors have read and approved the final version of the manuscript.

Informed consent statement: Informed consent was obtained from the patient for the publication of this case report.

Conflict-of-interest statement: The authors declare that they have no conflict of interest to report.

CARE Checklist (2016) statement: The authors have read the CARE Checklist (2016), and the manuscript was prepared and revised according to the CARE

Yang-Bo Liu, Hao Pan, Cong-Cong Wu, Peng Wu, Lei Chen, Department of Orthopaedics, The First Affiliated Hospital of Wenzhou Medical University, Wenzhou 325000, Zhejiang Province, China

Li Chen, Orthopaedics Unit, St. Vincent's Hospital Melbourne, 41 Victoria Parade, Fitzroy VIC 3065, Australia

Hao-Nan Ye, First School of Clinical Medicine, Wenzhou Medical University, Wenzhou 325000, Zhejiang Province, China

Corresponding author: Lei Chen, MD, Director, Professor, Department of Orthopaedics, The First Affiliated Hospital of Wenzhou Medical University, Nanbaixiang, Ouhai District, Wenzhou 325000, Zhejiang Province, China. chenlei689595@wmu.edu.cn

Abstract

BACKGROUND

Both periprosthetic joint infections (PJIs) and severe femoral segmental defects are catastrophic complications of total hip arthroplasty (THA), and both present a significant challenge in revisional surgery. There are limited data available to guide clinical decision making when both occur concurrently.

CASE SUMMARY

A 61-year-old woman presented with a 6-mo history of a sinus tract at the site of her original THA incision. Radiological imaging revealed a total hip joint implant with an ipsilateral segmental femoral defect. Based on histological, radiological, laboratory, and clinical features, a diagnosis of concurrent chronic PJI and segmental femoral defect (Type IIIB, Paprosky classification) was made. After multidisciplinary team discussion, three-dimensional (3D)-printed, custom-made antibiotic spacers were created that could be used to mold antibiotic-loaded cement spacer. These were placed following PJI debridement in the first stage of revision surgery. After the PJI was eliminated, a 3D-printed, custom-made, femoral prosthesis was created to repair the considerable femoral defect. After 20-mo follow-up, the patient had excellent functional outcomes with a near-normal range of hip movement. So far, neither evidence of recurrent infection nor loosening of the prosthesis has been observed.

CONCLUSION

We describe a case of "two-stage, custom-made" total hip revision to treat PJI with a concurrent segmental femoral defect. Use of a personalized, 3D-printed

Checklist (2016).

Open-Access: This article is an open-access article that was selected by an in-house editor and fully peer-reviewed by external reviewers. It is distributed in accordance with the Creative Commons Attribution NonCommercial (CC BY-NC 4.0) license, which permits others to distribute, remix, adapt, build upon this work non-commercially, and license their derivative works on different terms, provided the original work is properly cited and the use is non-commercial. See: <http://creativecommons.org/licenses/by-nc/4.0/>

Manuscript source: Unsolicited manuscript

Specialty type: Orthopedics

Country/Territory of origin: China

Peer-review report's scientific quality classification

Grade A (Excellent): 0
Grade B (Very good): B
Grade C (Good): 0
Grade D (Fair): 0
Grade E (Poor): 0

Received: April 28, 2021

Peer-review started: April 28, 2021

First decision: June 15, 2021

Revised: June 16, 2021

Accepted: July 15, 2021

Article in press: July 15, 2021

Published online: September 6, 2021

P-Reviewer: Baryshnikova NV

S-Editor: Ma YJ

L-Editor: Wang TQ

P-Editor: Li X



spacer and proximal femoral prosthesis led to satisfactory hip function and no early postoperative complications. Use of a customized implant provides surgeons with an alternative option for patients where no suitable spacer or implant is available. However, the long-term function, longevity, and cost-effectiveness of the use of custom-made prostheses have yet to be fully explored.

Key Words: Total hip arthroplasty; Joint revision; Prosthesis-related infections; Bone loss; Bone cement; Antibiotics; Case report

©The Author(s) 2021. Published by Baishideng Publishing Group Inc. All rights reserved.

Core Tip: This paper reports a pioneering technique where a 3D-printed, custom-made antibiotic spacer and femoral prosthesis were used in revisional surgery for a challenging case of periprosthetic joint infection with a concurrent femoral segmental defect after total hip arthroplasty. A review of other relevant cases from the literature is presented, and the potential challenges and solutions of novel, personalized reconstructive methods are discussed.

Citation: Liu YB, Pan H, Chen L, Ye HN, Wu CC, Wu P, Chen L. Total hip revision with custom-made spacer and prosthesis: A case report. *World J Clin Cases* 2021; 9(25): 7605-7613

URL: <https://www.wjgnet.com/2307-8960/full/v9/i25/7605.htm>

DOI: <https://dx.doi.org/10.12998/wjcc.v9.i25.7605>

INTRODUCTION

The safety and effectiveness of total hip arthroplasty (THA) have led to this being one of the most commonly performed operations worldwide, with more than 1 million hips replaced each year according to Organisation for Economic Co-operation and Development (OECD) data[1]. With the rise in the volume of primary THA performed, the total volume of revisional surgery (including complex re-revision) is projected to grow by 137% in the United States by 2030[2]. Infection and significant bone defects after THA are devastating and costly complications that are challenging to resolve. Here we present a rare case of two-stage revisional surgery for THA, in which both a 3D-printed, customized spacer and proximal femur prosthesis (PFP) were used to manage periprosthetic joint infection (PJI) with a concurrent segmental femoral defect.

CASE PRESENTATION

Chief complaints

A 61-year-old woman presented to our orthopaedic service with a 6-mo history of a non-healing ulcer and tract over the site of her original THA incision.

History of present illness

The patient reported low-grade fevers, particularly in the afternoons, and she had received several previous courses of antibiotics for deep infection at the wound site.

History of past illness

In September 2012, the patient had a severe car accident and was diagnosed with a left distal radius and ulna fracture (23r-E/4.2 and 23 μmol/L/3.1; ICD-10: S52.50 and S52.60), left acetabular fracture (62B3.1; ICD-10: S32.40), left femoral intertrochanteric and ipsilateral head fracture (31A2.3 & 31C1.3; ICD-10: S72.14 & S72.05), right-sided transverse process fracture at L1 (ICD-10: S32.01), and multiple left-sided rib fractures (5-7th, 9th, 11th, ICD-10: S22.42). Internal fixation of the left proximal femoral fracture and ipsilateral femoral head fracture was performed, but later failed and she underwent total hip arthroplasty (THA) appropriately 6 mo after her initial injury. Four years after her primary THA, the patient had required a further open reduction of the replaced left hip due to another accident.

Personal and family history

No other relevant family history was reported

Physical examination

On examination, the patient had swelling over the left hip region, with mild pain on pressing the swollen area. The healed THA wound site was moist with pale secretions, and a deep leading sinus tract was identified.

Laboratory examinations

The patient's haematological profile revealed a raised erythrocyte sedimentation rate (ESR, 74 mm/h; normal: 0-20 mm/h), and biochemistry demonstrated a raised level of C-reactive protein (CRP, 48.3 mg/L; normal: 0-8 mg/L). All other blood results were within normal limits. A swab test along the sinus tract grew an *Enterococcus species* on culture, which was consistent with the previous sinus tract examination

Imaging examinations

Plain radiography of the left hip in the anteroposterior plane demonstrated a post-THA hip with a severe proximal femoral defect (Figure 1).

FINAL DIAGNOSIS

The result of histological examination of a biopsy sample and bacterial cultures from the non-healing sinus tract over the incision site scar led to a diagnosis of PJI (ICD-10: T84.52), corroborated by the serum biochemistry results[3]. The femoral defect was classified using the Paprosky system as Type IIIB, and the acetabular defect as Type IIC.

TREATMENT

Two-stage total hip revisional surgery was conducted using a 3D-printed, customized antibiotic-loaded cement spacer (ALCS) during the first stage and a personalized proximal femur prosthesis (PFP) for the second stage. Postoperatively, intravenous vancomycin was administered twice daily at a dose of 15 mm/kg for the first 7 postoperative days, followed by oral moxifloxacin (400 mg every 24 h) for a further 2 wk as recommended by the DISA (Infectious Diseases Society of America) guidelines [4].

OUTCOME AND FOLLOW-UP

Postoperative inflammatory markers, including ESR and CRP, were monitored weekly for 8 wk, revealing the return to the normal range within 4 wk. The patient was kept non-weight bearing for 6 wk from the day of surgery, and then was allowed to partially weight bear for the following 6 wk before full weight bearing at 12 wk after surgery onwards. At her last follow-up (20 mo after surgery), she was asymptomatic and had significant functional improvement of her left hip with a Harris Hip Score of 91. Radiographs demonstrated no signs of implant loosening (Figure 2), and her serum markers were within normal limits.

DISCUSSION

This report describes a challenging case of chronic PJI with a concomitant segmental femoral defect, which were managed by a two-stage revisional procedure using custom-made, 3-D printed ALCS and PFP, respectively. There were several key learning points throughout the treatment pathway that will be beneficial for surgeons faced with this challenge in the future.

Custom-made antibiotic-loaded cement spacer

Prefabricated antibiotic-loaded interval spacers are available in various configurations. However, certain cases with complex anatomy and pathoetiology warrant custom-

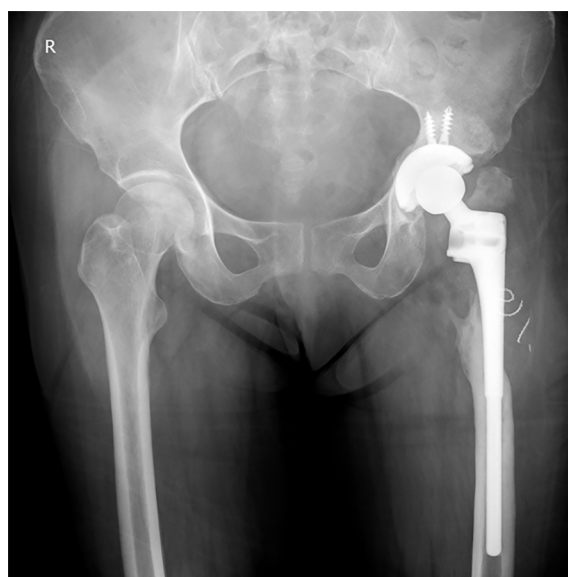


Figure 1 X-ray film, anteroposterior plane. The left artificial hip had a severe proximal femoral defect.

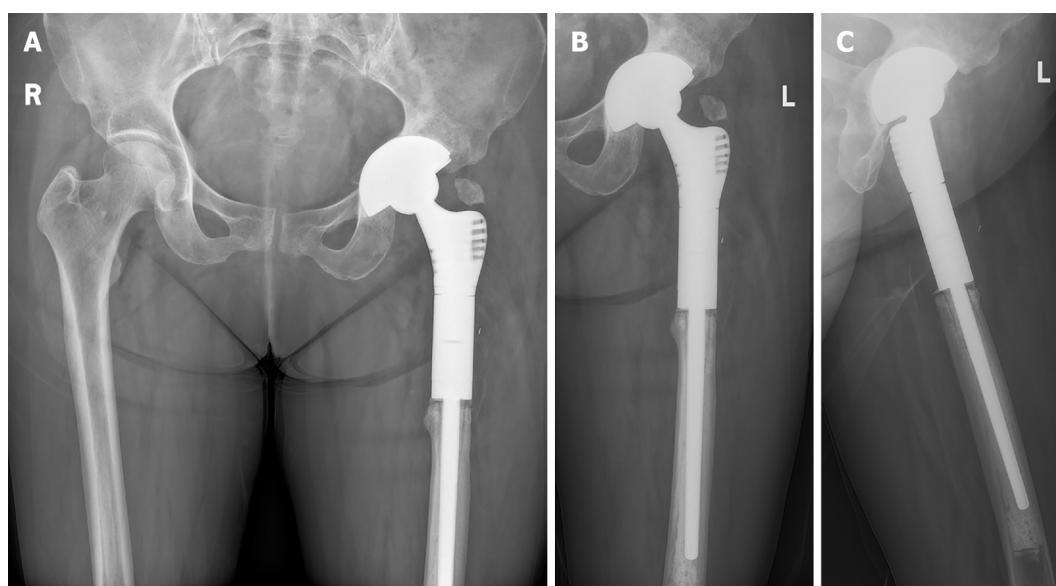


Figure 2 Radiographs of the pelvis taken 20 mo after the second-stage surgery. A: Pelvic plane; B: Anteroposterior plane; C: Lateral plane.

made spacers. In the previous literature, both standard and customized spacers have similar infection clearance rates, and each has their own merits based on the clinical circumstances[5,6]. In this case, the treating surgeon attempted to manually transform an “off-the-shelf” spacer to fix the anatomy[7], but the reformed spacers were inadequate. Therefore, customized spacer molds were designed using computed tomography (CT) and three-dimension (3D) model data (Figure 3A and B). The molds were divided into two blocks, which could be accurately aligned using complementary locating bars and holes. Several discharge channels were included to allow space for excess cement to be removed (Figure 3C and D). The custom-made ALCS (Figure 4A and B) replaced the infected prosthesis to create a near anatomical left hip joint (Figure 5A). The patient was so satisfied with the first-stage revision that she consistently refused her scheduled 2nd-stage until a second fall occurred 6 mo after the first-stage surgery (Figure 5B).

A binding bundle of Kirschner wires surrounded by several single wires was settled to strengthen the positioning of the ALCS. This remained functional in the patient's body for nearly 6 mo (2 to 3 times longer than expected).

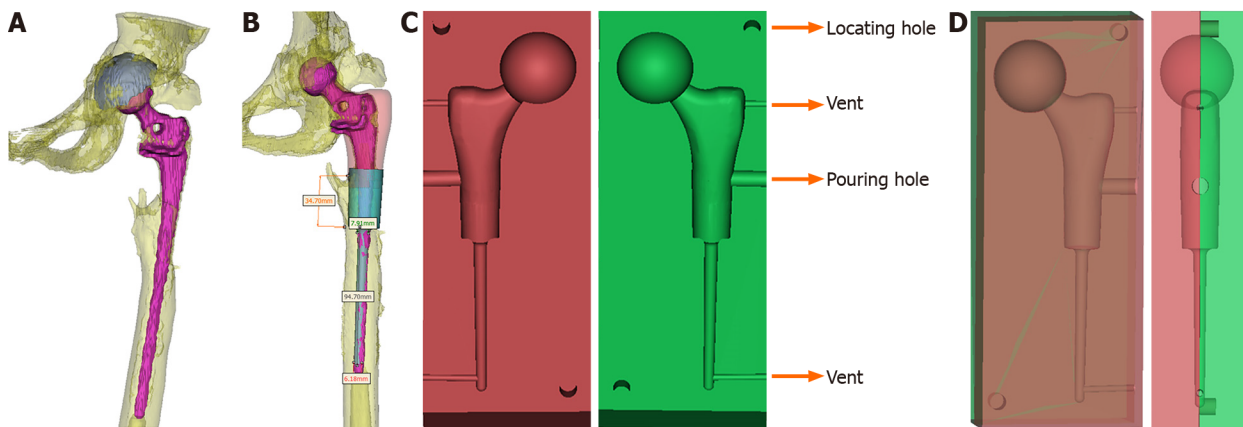


Figure 3 Design process of the customized spacer molds. A: Reconstruction image of the prosthesis and left hip; B: The blueprint of the spacer according to the reconstruction image; C: The blueprint of the customized spacer molds; D: The blueprint of the assembled spacer molds.

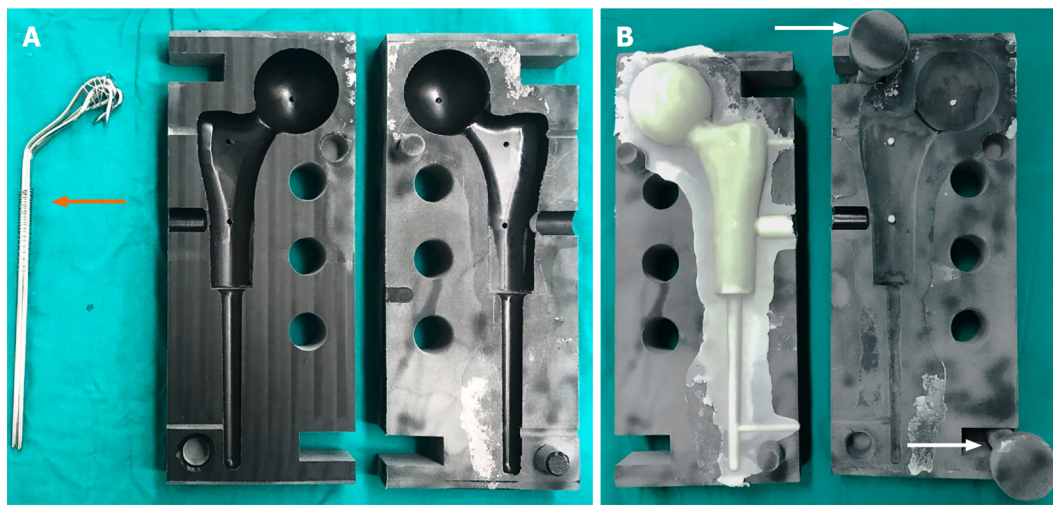


Figure 4 Molding process of the custom-made spacer cement. A: The molds and the binding bundle of Kirschner wires (orange arrow); B: Spacer cement and the pressure rods (white arrow).

In our experience, the advantages of custom-made spacers included retention of limb length and lateral offset, both of which made it easier to perform further revisional surgery[8]. Moreover, custom-made spacers also allow the treating surgeon to control the type and dosage of antibiotics[9].

Antimicrobial therapy

After reviewing sensitivities of the bacterial culture, 2 g of vancomycin were combined with each pouch of PALACOS MV+G cement, which delivered a safe and effective dosage of gentamicin[10]. Because ALCS can deliver high local concentrations of antibiotics, this can enter systemic circulation and result in toxicity or other adverse reactions such as acute renal failure, hepatic failure, and bone marrow depression[11, 12]. Due to the high local concentration of vancomycin in the custom-made ALCS, the concentration of intravenous vancomycin administered postoperatively was down-titrated to ensure safe levels of delivery. The patient's serum vancomycin concentration after surgery has been maintained above twice the minimal inhibitory concentration as recommended by Whiteside *et al*[13].

Custom-made, 3D-printed prosthesis

Reports to date of the operative management of severe proximal femoral osteopenia (classified as Paprosky types IIIB and IV) have included impaction grafting[14], allograft prosthesis composite (APC)[15,16], and prosthetic implants (*i.e.*, modular mega-prostheses)[17]. Each of these methods has unique advantages and limitations [17-19]. Standard modular prostheses are an available option for proximal femoral reconstruction in many cases and have been developed to be broadly applicable across

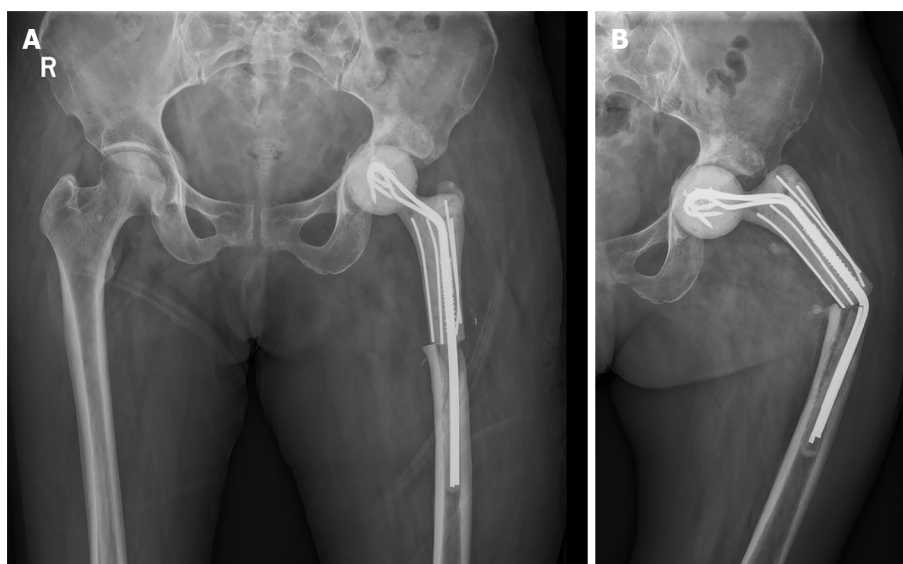


Figure 5 Radiographs of the pelvis taken the day after the first-stage revision (anteroposterior plane) (A) and the left hip taken 6 mo after the first-stage revision (B). The spacer stem was bent (anteroposterior plane).

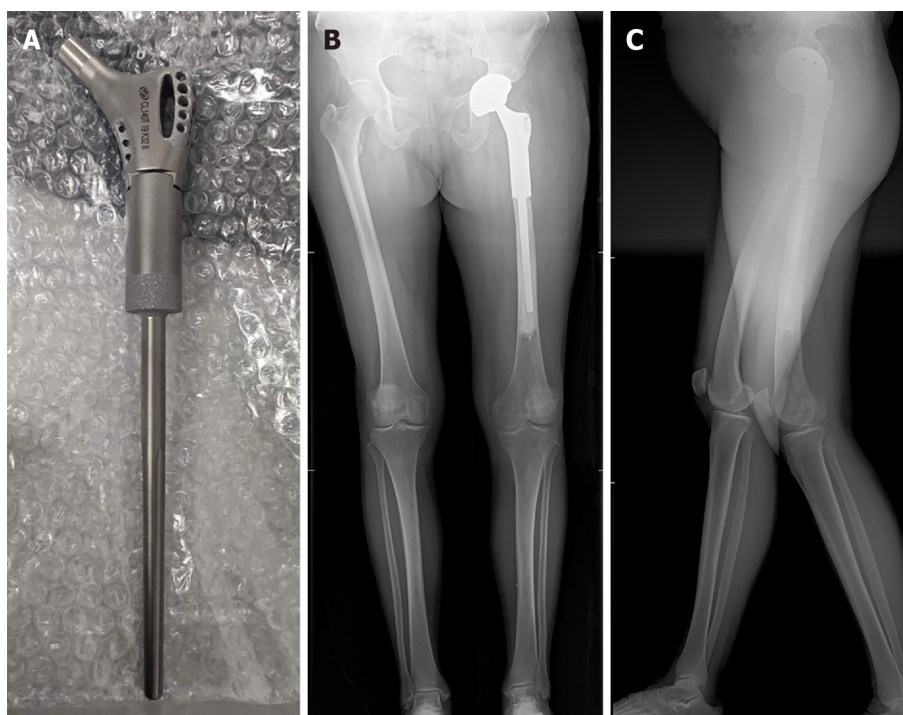


Figure 6 The custom-made prosthesis with porous design, and full lower limb radiographs taken the day after the second-stage revision. A: The custom-made prosthesis with porous design; B: Anteroposterior plane; C: Lateral plane.

several patient groups and fracture morphologies. Where standard prosthetic implantation is feasible, the estimated 5-year survival rate is encouraging at approximately 90.7% [20]. However, for some cases, custom-made prosthesis is needed to facilitate reconstruction (Table 1) [21-26].

To reconstruct this large, atypical segmental femoral bone deficiency, a custom-made PFP was designed and manufactured by a qualified medical implant provider (Beijing Chunlizhengda Medical Instruments Corporation, Beijing, China) (Figure 6A). To adjust the lower limb length to fit the uneven proximal cortical bone, three accessory ring blocks of different height (5 mm, 10 mm, and 15 mm) were made available. The 10 mm block was chosen intraoperatively to neutralize any shortening of the femur. The postoperative radiographs showed excellent resolution of the proximal femoral defect with the custom-made prosthesis. The patient regained a

Table 1 Literature review of custom-made femoral implants related total hip arthroplasty (with or without infection)

Ref.	No. of patients	Patient age (yr)	Follow-up (yr)	PJI	Type of femoral defect	Clinical outcome	Complications	Custom method
Jones <i>et al</i> [21]	1 in 9	60	3.3	Chronic (for 50 yr)	Girdlestone resection	No recurrence of infection; walk unaided	-	-
Hsieh <i>et al</i> [22]	9 in 24	59 (average)	4.2 (average)	All chronic	Type-III ¹ : 6 case Type-I ¹ : 3 case	No recurrence of infection	2 fractures & 1 dislocation	Spacer and femoral cement prosthesis with allografts
Westerman <i>et al</i> [23]	1	14	0.8	No infection	III-B ²	Symptom free	-	CT reconstruction
Wang <i>et al</i> [24]	1	73	2	No infection	III-B ²	Symptom free	-	3D printed titanium sleeve-prosthetic with allografts
Kamath <i>et al</i> [25]	1	68	1.5	Chronic for both knee and hip	IV ²	Hip disarticulation	TKA incision breakdown for infection	Mating of a PROSTALAC spacer with an intramedullary nail
Angelini <i>et al</i> [26]	1 in 41	66	1.5	1.3-mo after the first surgery	III-B ²	Healed	Deep infection	3D-printed prosthetic implant

¹Classified according to the system proposed by the American Academy of Orthopaedic Surgeons.

²Classified according to Paprosky classification. PJI: Periprosthetic joint infection.

near-anatomical hip joint with significant symptomatic improvement after years of discomfort and loss of function (Figure 6B and C).

CONCLUSION

In this case report, we have demonstrated the safety, feasibility, and effectiveness of two-stage revisional surgery for chronic PFI with a concurrent segmental femoral defect using a 3D-printed customized ALCS (first-stage) and a custom-made PFP (second-stage). We propose that the advantages of the custom-made ALCS are retention leg length and lateral offset, facilitating second stage revision, a robust fixation, and a low risk of dislocation or breakage. The apparent advantage of the custom-made PFP is near-perfect anatomical reconstruction of the affected hip with maximal preservation of bone tissue. Although manufacturing custom-made spacers and femoral prostheses is expensive and time-consuming, it presents a useful alternative when there is no suitable standard implant.

ACKNOWLEDGEMENTS

The authors are thankful to the Wenwen-Sun from the Department of Pathology, The First Affiliated Hospital of Wenzhou Medical University for her help in pathology. We are thankful to the patient enrolled in this study.

REFERENCES

- 1 Ferguson RJ, Palmer AJ, Taylor A, Porter ML, Malchau H, Glyn-Jones S. Hip replacement. *Lancet* 2018; **392**: 1662-1671 [PMID: 30496081 DOI: 10.1016/S0140-6736(18)31777-X]
- 2 Kurtz S, Ong K, Lau E, Mowat F, Halpern M. Projections of primary and revision hip and knee arthroplasty in the United States from 2005 to 2030. *J Bone Joint Surg Am* 2007; **89**: 780-785 [PMID: 17403800 DOI: 10.2106/JBJS.F.00222]
- 3 Parvizi J, Tan TL, Goswami K, Higuera C, Della Valle C, Chen AF, Shohat N. The 2018 Definition of Periprosthetic Hip and Knee Infection: An Evidence-Based and Validated Criteria. *J Arthroplasty* 2018; **33**: 1309-1314.e2 [PMID: 29551303 DOI: 10.1016/j.arth.2018.02.078]

- 4 **Osmon DR**, Berbari EF, Berendt AR, Lew D, Zimmerli W, Steckelberg JM, Rao N, Hanssen A, Wilson WR; Infectious Diseases Society of America. Diagnosis and management of prosthetic joint infection: clinical practice guidelines by the Infectious Diseases Society of America. *Clin Infect Dis* 2013; **56**: e1-e25 [PMID: [23223583](#) DOI: [10.1093/cid/cis803](#)]
- 5 **Jacobs C**, Christensen CP, Berend ME. Static and mobile antibiotic-impregnated cement spacers for the management of prosthetic joint infection. *J Am Acad Orthop Surg* 2009; **17**: 356-368 [PMID: [19474445](#) DOI: [10.5435/00124635-200906000-00004](#)]
- 6 **Veltman ES**, Moojen DJ, Glehr M, Poolman RW. Similar rate of infection eradication for functional articulating, prefabricated and custom-made spacers in 2-stage revision of the infected total hip: a literature review. *Hip Int* 2016; **26**: 319-326 [PMID: [27373276](#) DOI: [10.5301/hipint.5000400](#)]
- 7 **Ohtsuru T**, Morita Y, Murata Y, Munakata Y, Itoh M, Kato Y, Okazaki K. Custom-made, antibiotic-loaded, acrylic cement spacers using a dental silicone template for treatment of infected hip prostheses. *Eur J Orthop Surg Traumatol* 2018; **28**: 615-620 [PMID: [29332203](#) DOI: [10.1007/s00590-017-2117-3](#)]
- 8 **Veltman ES**, Moojen DJF, Poolman RW. Improved patient reported outcomes with functional articulating spacers in two-stage revision of the infected hip. *World J Orthop* 2020; **11**: 595-605 [PMID: [33362995](#) DOI: [10.5312/wjo.v11.i12.595](#)]
- 9 **Klinder A**, Zaatreh S, Ellenrieder M, Redanz S, Podbielski A, Reichel T, Bösebeck H, Mittelmeier W, Bader R. Antibiotics release from cement spacers used for two-stage treatment of implant-associated infections after total joint arthroplasty. *J Biomed Mater Res B Appl Biomater* 2019; **107**: 1587-1597 [PMID: [30312529](#) DOI: [10.1002/jbm.b.34251](#)]
- 10 **Wahlig H**, Dingeldein E, Buchholz HW, Buchholz M, Bachmann F. Pharmacokinetic study of gentamicin-loaded cement in total hip replacements. Comparative effects of varying dosage. *J Bone Joint Surg Br* 1984; **66**: 175-179 [PMID: [6707051](#) DOI: [10.1302/0301-620X.66B2.6707051](#)]
- 11 **Luu A**, Syed F, Raman G, Bhalla A, Muldoon E, Hadley S, Smith E, Rao M. Two-stage arthroplasty for prosthetic joint infection: a systematic review of acute kidney injury, systemic toxicity and infection control. *J Arthroplasty* 2013; **28**: 1490-8.e1 [PMID: [23578491](#) DOI: [10.1016/j.arth.2013.02.035](#)]
- 12 **van Raaij TM**, Visser LE, Vulto AG, Verhaar JA. Acute renal failure after local gentamicin treatment in an infected total knee arthroplasty. *J Arthroplasty* 2002; **17**: 948-950 [PMID: [12375257](#) DOI: [10.1054/arth.2002.34525](#)]
- 13 **Whiteside LA**, Peppers M, Nayfeh TA, Roy ME. Methicillin-resistant *Staphylococcus aureus* in TKA treated with revision and direct intra-articular antibiotic infusion. *Clin Orthop Relat Res* 2011; **469**: 26-33 [PMID: [20390472](#) DOI: [10.1007/s11999-010-1313-9](#)]
- 14 **Oshima S**, Yasunaga Y, Yamasaki T, Yoshida T, Hori J, Ochi M. Midterm results of femoral impaction bone grafting with an allograft combined with hydroxyapatite in revision total hip arthroplasty. *J Arthroplasty* 2012; **27**: 470-476 [PMID: [21955793](#) DOI: [10.1016/j.arth.2011.07.012](#)]
- 15 **Babis GC**, Sakellariou VI, O'Connor MI, Hanssen AD, Sim FH. Proximal femoral allograft-prosthesis composites in revision hip replacement: a 12-year follow-up study. *J Bone Joint Surg Br* 2010; **92**: 349-355 [PMID: [20190304](#) DOI: [10.1302/0301-620X.92B3.23112](#)]
- 16 **Mayle RE Jr**, Paprosky WG. Massive bone loss: allograft-prosthetic composites and beyond. *J Bone Joint Surg Br* 2012; **94**: 61-64 [PMID: [23118384](#) DOI: [10.1302/0301-620X.94B11.30791](#)]
- 17 **Meluzio MC**, Oliva MS, Minutillo F, Zirano A, Saccomanno MF, Maccauro G. The use of knee mega-prosthesis for the management of distal femoral fractures: A systematic review. *Injury* 2020; **51** Suppl 3: S17-S22 [PMID: [31526601](#) DOI: [10.1016/j.injury.2019.08.011](#)]
- 18 **Gautam D**, Malhotra R. Megaprosthesis vs Allograft Prosthesis Composite for massive skeletal defects. *J Clin Orthop Trauma* 2018; **9**: 63-80 [PMID: [29628687](#) DOI: [10.1016/j.jcot.2017.09.010](#)]
- 19 **Diaz-Dilernia F**, Slullitel PA, Oñativia JI, Comba FM, Piccaluga F, Buttarro MA. Impaction Bone Grafting or Uncemented Modular Stems for the Treatment of Type B3 Periprosthetic Femoral Fractures? *J Arthroplasty* 2019; **34**: 2051-2057 [PMID: [31160153](#) DOI: [10.1016/j.arth.2019.04.047](#)]
- 20 **Chandrasekar CR**, Grimer RJ, Carter SR, Tillman RM, Abudu A, Buckley L. Modular endoprosthetic replacement for tumours of the proximal femur. *J Bone Joint Surg Br* 2009; **91**: 108-112 [PMID: [19092014](#) DOI: [10.1302/0301-620X.91B1.20448](#)]
- 21 **Jones NF**, Eadie P, Johnson PC, Mears DC. Treatment of chronic infected hip arthroplasty wounds by radical debridement and obliteration with pedicled and free muscle flaps. *Plast Reconstr Surg* 1991; **88**: 95-101 [PMID: [2052665](#) DOI: [10.1097/00006534-199107000-00016](#)]
- 22 **Hsieh PH**, Shih CH, Chang YH, Lee MS, Yang WE, Shih HN. Treatment of deep infection of the hip associated with massive bone loss: two-stage revision with an antibiotic-loaded interim cement prosthesis followed by reconstruction with allograft. *J Bone Joint Surg Br* 2005; **87**: 770-775 [PMID: [15911656](#) DOI: [10.1302/0301-620X.87B6.15411](#)]
- 23 **Westerman RW**, Timperley AJ. Use of an anatomic long-stemmed component in femoral impaction grafting. *Hip Int* 2016; **26**: e1-e3 [PMID: [26692247](#) DOI: [10.5301/hipint.5000302](#)]
- 24 **Wang X**, Xu H, Zhang J. Using personalized 3D printed Titanium sleeve-prosthetic composite for reconstruction of severe segmental bone loss of proximal femur in revision total hip arthroplasty: A case report. *Medicine (Baltimore)* 2020; **99**: e18784 [PMID: [32011474](#) DOI: [10.1097/MD.0000000000001874](#)]
- 25 **Kamath AF**, Austin D, Lee GC. Mating of a PROSTALAC spacer with an intramedullary nail for reconstruction of an infected interprosthetic femoral shaft fracture: a case report. *J Orthop Surg (Hong Kong)* 2012; **20**: 263-268 [PMID: [22933694](#) DOI: [10.1177/230949901202000228](#)]

- 26 **Angelini A**, Kotrych D, Trovarelli G, Szafrński A, Bohatyrewicz A, Ruggieri P. Analysis of principles inspiring design of three-dimensional-printed custom-made prostheses in two referral centres. *Int Orthop* 2020; **44**: 829-837 [PMID: [32170471](#) DOI: [10.1007/s00264-020-04523-y](#)]



Published by **Baishideng Publishing Group Inc**
7041 Koll Center Parkway, Suite 160, Pleasanton, CA 94566, USA

Telephone: +1-925-3991568

E-mail: bpgoffice@wjgnet.com

Help Desk: <https://www.f6publishing.com/helpdesk>

<https://www.wjgnet.com>

