

World Journal of *Clinical Cases*

World J Clin Cases 2021 September 16; 9(26): 7614-7962



Contents

Thrice Monthly Volume 9 Number 26 September 16, 2021

EDITORIAL

- 7614 Advances in deep learning for computed tomography denoising
Park SB

REVIEW

- 7620 Spirituality, religiousness, and mental health: A review of the current scientific evidence
Lucchetti G, Koenig HG, Lucchetti ALG
- 7632 Role of hospitalization for inflammatory bowel disease in the post-biologic era
Soriano CR, Powell CR, Chiorean MV, Simianu VV

MINIREVIEWS

- 7643 Combined targeted therapy and immunotherapy for cancer treatment
Guo CX, Huang X, Xu J, Zhang XZ, Shen YN, Liang TB, Bai XL

ORIGINAL ARTICLE

Basic Study

- 7653 Mechanism of Jianpi Qingchang Huashi Recipe in treating ulcerative colitis: A study based on network pharmacology and molecular docking
Zheng L, Wen XL, Dai YC

Case Control Study

- 7671 Common bile duct morphology is associated with recurrence of common bile duct stones in Billroth II anatomy patients
Ji X, Jia W, Zhao Q, Wang Y, Ma SR, Xu L, Kan Y, Cao Y, Fan BJ, Yang Z

Retrospective Cohort Study

- 7682 Efficacy of roxadustat in treatment of peritoneal dialysis patients with renal anaemia
Zhu XW, Zhang CX, Xu TH, Jiang GN, Yao L

Retrospective Study

- 7693 Clinical metagenomic sequencing for rapid diagnosis of pneumonia and meningitis caused by *Chlamydia psittaci*
Yin XW, Mao ZD, Zhang Q, Ou QX, Liu J, Shao Y, Liu ZG
- 7704 Evaluation of the etiology and risk factors for maternal sepsis: A single center study in Guangzhou, China
Lin L, Ren LW, Li XY, Sun W, Chen YH, Chen JS, Chen DJ

- 7717 Influencing factors for hepatic fat accumulation in patients with type 2 diabetes mellitus

Wu MJ, Fang QL, Zou SY, Zhu Y, Lu W, Du X, Shi BM

- 7729 Clinical effect of peripheral capsule preservation in eyes with silicone oil tamponade

Jiang B, Dong S, Sun MH, Zhang ZY, Sun DW

- 7738 Potential effects of the nursing work environment on the work-family conflict in operating room nurses

Fu CM, Ou J, Chen XM, Wang MY

Observational Study

- 7750 Effect and satisfaction of outpatient services by precision valuation reservation registration

Jin HJ, Cheng AL, Qian JY, Lin LM, Tang HM

Randomized Controlled Trial

- 7762 Impact of intravenous dexmedetomidine on postoperative bowel movement recovery after laparoscopic nephrectomy: A consort-prospective, randomized, controlled trial

Huang SS, Song FX, Yang SZ, Hu S, Zhao LY, Wang SQ, Wu Q, Liu X, Qi F

META-ANALYSIS

- 7772 Comparison of different methods of nasogastric tube insertion in anesthetized and intubated patients: A meta-analysis

Ou GW, Li H, Shao B, Huang LM, Chen GM, Li WC

CASE REPORT

- 7786 Secondary injuries caused by ill-suited rehabilitation treatments: Five case reports

Zhou L, Zhou YQ, Yang L, Ma SY

- 7798 Gastric syphilis mimicking gastric cancer: A case report

Lan YM, Yang SW, Dai MG, Ye B, He FY

- 7805 Low-grade chondrosarcoma of the larynx: A case report

Vučković L, Klisic A, Filipović A, Popović M, Čulafić T

- 7811 Pediatric temporal fistula: Report of three cases

Gu MZ, Xu HM, Chen F, Xia WW, Li XY

- 7818 Treatment for CD57-negative $\gamma\delta$ T-cell large granular lymphocytic leukemia with pure red cell aplasia: A case report

Xiao PP, Chen XY, Dong ZG, Huang JM, Wang QQ, Chen YQ, Zhang Y

- 7825 Rare neonatal malignant primary orbital tumors: Three case reports

Zhang Y, Li YY, Yu HY, Xie XL, Zhang HM, He F, Li HY

- 7833 Carbon ion radiotherapy for bladder cancer: A case report

Zhang YS, Li XJ, Zhang YH, Hu TC, Chen WZ, Pan X, Chai HY, Wang X, Yang YL

- 7840** Extravasation of chemotherapeutic drug from an implantable intravenous infusion port in a child: A case report
Ly DN, Xu HZ, Zheng LL, Chen LL, Ling Y, Ye AQ
- 7845** Chronic active Epstein-Barr virus infection treated with PEG-asparaginase: A case report
Song DL, Wang JS, Chen LL, Wang Z
- 7850** Omental mass combined with indirect inguinal hernia leads to a scrotal mass: A case report
Liu JY, Li SQ, Yao SJ, Liu Q
- 7857** Critical lower extremity ischemia after snakebite: A case report
Lu ZY, Wang XD, Yan J, Ni XL, Hu SP
- 7863** Migration of the localization wire to the back in patient with nonpalpable breast carcinoma: A case report
Choi YJ
- 7870** Uniportal video-assisted thoracoscopic surgery for complex mediastinal mature teratoma: A case report
Hu XL, Zhang D, Zhu WY
- 7876** Congenital disorder of glycosylation caused by mutation of *ATP6AP1* gene (c.1036G>A) in a Chinese infant: A case report
Yang X, Lv ZL, Tang Q, Chen XQ, Huang L, Yang MX, Lan LC, Shan QW
- 7886** Rare monolocular intrahepatic biliary cystadenoma: A case report
Che CH, Zhao ZH, Song HM, Zheng YY
- 7893** Hepatocellular carcinoma with inferior vena cava and right atrium thrombus: A case report
Liu J, Zhang RX, Dong B, Guo K, Gao ZM, Wang LM
- 7901** Delayed diagnosis of ascending colon mucinous adenocarcinoma with local abscess as primary manifestation: Report of three cases
Han SZ, Wang R, Wen KM
- 7909** Gastrointestinal bleeding caused by syphilis: A case report
Sun DJ, Li HT, Ye Z, Xu BB, Li DZ, Wang W
- 7917** Transient involuntary movement disorder after spinal anesthesia: A case report
Yun G, Kim E, Do W, Jung YH, Lee HJ, Kim Y
- 7923** Diagnosis and treatment of an inborn error of bile acid synthesis type 4: A case report
Wang SH, Hui TC, Zhou ZW, Xu CA, Wu WH, Wu QQ, Zheng W, Yin QQ, Pan HY
- 7930** Malignant fibrous histiocytoma of the bone in a traumatic amputation stump: A case report and review of the literature
Zhao KY, Yan X, Yao PF, Mei J

- 7937** Rare complication of acute adrenocortical dysfunction in adrenocortical carcinoma after transcatheter arterial chemoembolization: A case report
Wang ZL, Sun X, Zhang FL, Wang T, Li P
- 7944** Peripherally inserted central catheter placement in neonates with persistent left superior vena cava: Report of eight cases
Chen Q, Hu YL, Li YX, Huang X
- 7954** Subcutaneous angiolipoma in the scrotum: A case report
Li SL, Zhang JW, Wu YQ, Lu KS, Zhu P, Wang XW

LETTER TO THE EDITOR

- 7959** Should people with chronic liver diseases be vaccinated against COVID-19?
Chen LP, Zeng QH, Gong YF, Liang FL

ABOUT COVER

Editorial Board Member of *World Journal of Clinical Cases*, Alessandro Leite Cavalcanti, DDS, MSc, PhD, Associate Professor, Department of Dentistry, State University of Paraiba, Campina Grande 58429500, Paraiba, Brazil. alessandrouepb@gmail.com

AIMS AND SCOPE

The primary aim of *World Journal of Clinical Cases* (WJCC, *World J Clin Cases*) is to provide scholars and readers from various fields of clinical medicine with a platform to publish high-quality clinical research articles and communicate their research findings online.

WJCC mainly publishes articles reporting research results and findings obtained in the field of clinical medicine and covering a wide range of topics, including case control studies, retrospective cohort studies, retrospective studies, clinical trials studies, observational studies, prospective studies, randomized controlled trials, randomized clinical trials, systematic reviews, meta-analysis, and case reports.

INDEXING/ABSTRACTING

The WJCC is now indexed in Science Citation Index Expanded (also known as SciSearch®), Journal Citation Reports/Science Edition, Scopus, PubMed, and PubMed Central. The 2021 Edition of Journal Citation Reports® cites the 2020 impact factor (IF) for WJCC as 1.337; IF without journal self cites: 1.301; 5-year IF: 1.742; Journal Citation Indicator: 0.33; Ranking: 119 among 169 journals in medicine, general and internal; and Quartile category: Q3. The WJCC's CiteScore for 2020 is 0.8 and Scopus CiteScore rank 2020: General Medicine is 493/793.

RESPONSIBLE EDITORS FOR THIS ISSUE

Production Editor: Jia-Hui Li; Production Department Director: Yun-Jie Ma; Editorial Office Director: Jin-Lei Wang.

NAME OF JOURNAL

World Journal of Clinical Cases

ISSN

ISSN 2307-8960 (online)

LAUNCH DATE

April 16, 2013

FREQUENCY

Thrice Monthly

EDITORS-IN-CHIEF

Dennis A Bloomfield, Sandro Vento, Bao-Gan Peng

EDITORIAL BOARD MEMBERS

<https://www.wjnet.com/2307-8960/editorialboard.htm>

PUBLICATION DATE

September 16, 2021

COPYRIGHT

© 2021 Baishideng Publishing Group Inc

INSTRUCTIONS TO AUTHORS

<https://www.wjnet.com/bpg/gerinfo/204>

GUIDELINES FOR ETHICS DOCUMENTS

<https://www.wjnet.com/bpg/GerInfo/287>

GUIDELINES FOR NON-NATIVE SPEAKERS OF ENGLISH

<https://www.wjnet.com/bpg/gerinfo/240>

PUBLICATION ETHICS

<https://www.wjnet.com/bpg/GerInfo/288>

PUBLICATION MISCONDUCT

<https://www.wjnet.com/bpg/gerinfo/208>

ARTICLE PROCESSING CHARGE

<https://www.wjnet.com/bpg/gerinfo/242>

STEPS FOR SUBMITTING MANUSCRIPTS

<https://www.wjnet.com/bpg/GerInfo/239>

ONLINE SUBMISSION

<https://www.f6publishing.com>

Carbon ion radiotherapy for bladder cancer: A case report

Yan-Shan Zhang, Xiao-Jun Li, Yi-He Zhang, Ting-Chao Hu, Wei-Zuo Chen, Xin Pan, Hong-Yu Chai, Xin Wang, Yu-Ling Yang

ORCID number: Yan-Shan Zhang 0000-0003-4621-148X; Xiao-Jun Li 0000-0002-1885-4747; Yi-He Zhang 0000-0003-0800-8747; Ting-Chao Hu 0000-0003-3901-3637; Wei-Zuo Chen 0000-0002-6826-2950; Xin Pan 0000-0003-1235-3869; Hong-Yu Chai 0000-0002-7907-6918; Xin Wang 0000-0002-0347-1057; Yu-Ling Yang 0000-0003-1003-707X.

Author contributions: Zhang YS and Li XJ equally contributed to this article and should be regarded as co-first authors; Zhang YS, Li XJ, Zhang YH, and Hu TC designed the study; Chen WZ, Pan X, and Chai HY drafted the work; Wang X and Yang YL collected the data; Zhang YS and Li XJ analyzed and interpreted the data; Zhang YH and Hu TC wrote the article.

Supported by Key R&D Plan of Science and Technology Program of Gansu Province, China, No. 19YF3FH001.

Informed consent statement: All study participants, or their legal guardian, provided informed written consent prior to study enrollment.

Conflict-of-interest statement: Dr. Zhang YS reports grants from Key R&D Plan of Science and Technology Program of Gansu Province, China during the conduct of the study.

Yan-Shan Zhang, Xiao-Jun Li, Yi-He Zhang, Ting-Chao Hu, Wei-Zuo Chen, Xin Pan, Hong-Yu Chai, Xin Wang, Yu-Ling Yang, Heavy Ion Center, Wuwei Cancer Hospital, Wuwei 733000, Gansu Province, China

Corresponding author: Yan-Shan Zhang, PhD, Chief Doctor, Heavy Ion Center, Wuwei Cancer Hospital, No. 31 Sanitary Lane, Haizang Road, Wuwei 733000, Gansu Province, China. 13830510999@163.com

Abstract

BACKGROUND

Radical cystectomy is considered the first choice for the treatment of muscle-invasive bladder cancer. However, for some patients who have lost the indications for surgery, external beam radiotherapy is a non-invasive and effective treatment.

CASE SUMMARY

A 76-year-old patient with bladder cancer who had serious comorbidities and could not tolerate surgery or chemotherapy came to the Wuwei Heavy Ion Center. He received carbon ion radiotherapy (CIRT) with a whole-bladder dose of 44 GyE and tumor boost of 20 GyE. When he finished CIRT, his bladder cancer-related hematuria completely disappeared, and computed tomography examination showed that the tumor had obviously decreased in size. At the 3-mo follow-up, the tumor disappeared, and there were no acute or late adverse events. CIRT was well tolerated in this patient.

CONCLUSION

CIRT may allow for avoiding resection and was well tolerated with curative outcomes.

Key Words: Carbon ion radiotherapy; Bladder cancer; Galloping scheme; Case report

©The Author(s) 2021. Published by Baishideng Publishing Group Inc. All rights reserved.

Core Tip: This case report is of a bladder cancer patient who received carbon ion radiotherapy (CIRT). The patient tolerated CIRT well. After the completion of CIRT, the hematuria associated with bladder cancer disappeared completely, and computed tomography examination showed that the tumor was significantly reduced. During the

CARE Checklist (2016) statement:

The authors have read the CARE Checklist (2016), and the manuscript was prepared and revised according to the CARE Checklist (2016).

Open-Access: This article is an open-access article that was selected by an in-house editor and fully peer-reviewed by external reviewers. It is distributed in accordance with the Creative Commons Attribution NonCommercial (CC BY-NC 4.0) license, which permits others to distribute, remix, adapt, build upon this work non-commercially, and license their derivative works on different terms, provided the original work is properly cited and the use is non-commercial. See: <http://creativecommons.org/licenses/by-nc/4.0/>

Manuscript source: Unsolicited manuscript

Specialty type: Radiology, nuclear medicine and medical imaging

Country/Territory of origin: China

Peer-review report's scientific quality classification

Grade A (Excellent): 0
Grade B (Very good): B
Grade C (Good): 0
Grade D (Fair): 0
Grade E (Poor): 0

Received: April 6, 2021

Peer-review started: April 6, 2021

First decision: April 28, 2021

Revised: May 9, 2021

Accepted: July 6, 2021

Article in press: July 6, 2021

Published online: September 16, 2021

P-Reviewer: Siracusano S

S-Editor: Yan JP

L-Editor: Filipodia

P-Editor: Xing YX



3-mo follow-up, the tumor disappeared and there were no acute or late adverse events.

Citation: Zhang YS, Li XJ, Zhang YH, Hu TC, Chen WZ, Pan X, Chai HY, Wang X, Yang YL. Carbon ion radiotherapy for bladder cancer: A case report. *World J Clin Cases* 2021; 9(26): 7833-7839

URL: <https://www.wjgnet.com/2307-8960/full/v9/i26/7833.htm>

DOI: <https://dx.doi.org/10.12998/wjcc.v9.i26.7833>

INTRODUCTION

Radical cystectomy is considered the treatment of choice for muscle-invasive bladder carcinoma[1-6]. Surgery may not be possible, however, for patients with locally advanced tumors or for those considered medically unfit[7,8]. External beam radiotherapy (EBRT) is a noninvasive and efficient treatment modality[9-11], although it is based on very limited literature consisting mainly of small retrospective series of patients not eligible for curative treatment[12-14].

Carbon ion beams produce increased energy deposition at the end of their range to form the Bragg peak while minimizing radiation damage to the surrounding tissue, leading to a more precise dosage and localization than photon beams. Furthermore, carbon ion radiotherapy (CIRT) is cell cycle independent with a high relative biologic effectiveness (RBE) and low oxygen enhancement ratio. This kind of radiation also leads to double-strand breaks in DNA molecules, resulting in lethal damage to tumor cells. These properties are thus advantageous for treating radiation-insensitive tumors [15]. Here, we present 1 case of a bladder carcinoma patient who underwent CIRT who achieved good results.

CASE PRESENTATION

Chief complaints

A 76-year-old male patient with bladder cancer is presented. The patient complained of intermittent gross hematuria for 1 year.

History of past illness

The patient had previously been in good health.

Personal and family history

No similar medical history in the family.

Physical examination

After the patient was transferred to our center, we performed a full work up. We found the patient had serious gross hematuria (Figure 1A) through the entire course of micturition with pain on straining to urinate.

Laboratory examinations

No abnormalities in blood routine, biochemistry, and electrolytes tests.

Imaging examinations

Due to the renal and cardiac insufficiency, the patient only underwent abdominopelvic computed tomography (CT) scanning and magnetic resonance imaging without contrast. Imaging in August 2020 showed that the bladder wall was in-homogeneous thickened with mass formation, the mass protrusion into the lumen, and a mass size of 27.9 mm × 29.1 mm. The radiography diagnosis was bladder cancer. Given his comorbidity, he had a high risk of cystoscopy; at our center, we took urine exfoliation cytology, which found transitional cell carcinoma. He had a serious macroscopic hematuria, and laboratory examination showed urinary red blood cell count (URBC) 14653/μL.

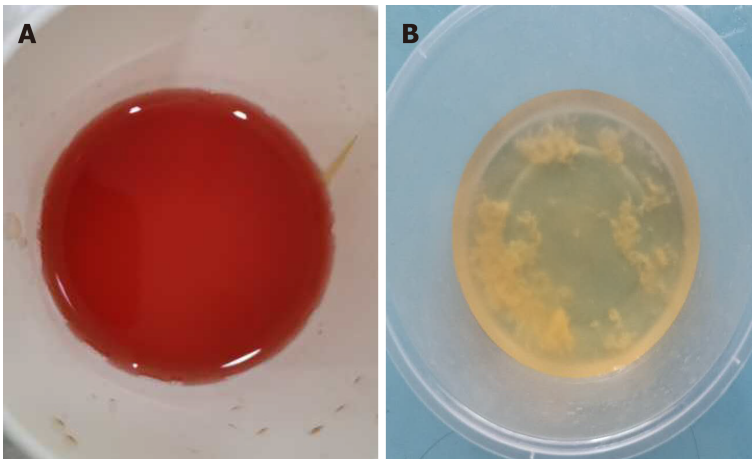


Figure 1 The patient's urine. A: Image at the time of admission to the hospital; B: Image after just completing carbon ion radiotherapy.

FINAL DIAGNOSIS

After detailed comprehensive evaluation, the patient's definite diagnosis was bladder cancer, American Joint Committee on Cancer (8th edition), cT2N0M0, stage II, and Karnofsky score of 70 points. Due to the patient's underlying co-morbidity (diabetes, chronic renal and cardiac insufficiency), the patient had high risk of surgical treatment or cystoscopy. He and his family refused to accept surgery, cystoscopy, or chemotherapy. After MDT, we decided CIRT for the patient with the "galloping scheme" technique (as discussed in the next paragraph) (Figure 2).

TREATMENT

Introduction of the "galloping scheme": Before CIRT, the patient underwent indwelling urinary catheter placement. The catheter needs to have a large inner diameter with double-lumen and have 21F-24F inner lumen diameter, which is connected to the bladder and closed thoracic drainage bottle, which has a large volume of more than 2000 mL. Physiological saline solution is injected into the water-sealed bottle (Figure 3). By using "the law of connected vessels", bladder pressure is related to bladder volume, detrusor, sphincter contraction, abdominal pressure, *etc.* The fluid flow in and out of the water-sealed bottle was observed until a fluctuating level of relative equilibrium was reached. We adjusted the liquid level of the closed thoracic drainage bottle, and we acquired an ideal bladder volume when finally the water level of the closed thoracic drainage bottle and the bladder pressure is in equilibrium. The ideal bladder volume was obtained by adjusting the liquid level of the bottle according to the lesion location and irradiation range of the bladder cancer. The liquid level of the closed thoracic drainage bottle was measured and recorded. When the patient was asked to urinate forcibly, we found an increase in the level of the thoracic drainage bottle, and finally the water level came back to the original level. The bladder volume repeatability was observed. The specified pressure of closed thoracic drainage bottle was transmitted to the bladder, making the internal bladder pressure and volume almost constant during CIRT. In other words, during the treatment, we kept the precise level of the closed thoracic drainage bottle, and we reached a steady bladder volume and position.

In CT simulation positioning, the whole process of CIRT was simulated several times to determine the variation of urine volume and bladder contour with urine production during treatment, and the internal target volume (ITV) range of bladder was determined individually. Technically, we obtained the individualized data of constant bladder volume and pressure during CIRT (the fluid level in the water-sealed bottle has generally good reproducibility of 10-20 cm above anterior portion of the pubis). Before CIRT, the difference of bladder volume was observed at the simulated positioning session more than three times to determine the degree and range of bladder volume change during radiotherapy, so as to finally achieve the demand of precise treatment. The "galloping scheme" was used to control the constant bladder volume and position throughout the treatment. We had adopted this technique at



Figure 2 Schematic diagram of “galloping scheme”, the orange arrow (left-the closed thoracic, right-simulation of the bladder).




Figure 3 Double lumen latex balloon foley catheter.

CIRT for prostate cancer and cervical cancer patients and find it was very wonderful. During CT simulation and positioning, the whole CIRT session was simulated for several times, and the ITV range of the bladder was determined often as 2-4 mm.

Target area was delineated: Gross tumor volume (GTV) was delineated as bladder lesions visible on CT and magnetic resonance imaging. Internal GTV (IGTV) was formed by external expansion of 3 mm on the basis of GTV; GTV plus 3 mm formed primary GTV (PGTV). Clinical target volume included the whole bladder, and ITV was within 0.2-0.4 cm of uniform external expansion of the bladder. Primary tumor volume (PTV) was expanded by 3mm on the basis of ITV, and the 3 mm margins were modified if intestinal tract was close to the bladder; 4-field ‘box’ technique was used to treat both PTV 1 and PGTV.

IGTV was formed by external expansion of 3 mm on the basis of GTV and was formed by external expansion of 3 mm on the basis of IGTV. It was tailored appropriately according to the location of intestinal tract. The irradiation dose was expressed in Gy (RBE), defined as the carbon ion physical dose (Gy) multiplied by a RBE value of 3.0.

The patient was given total doses of 64 Gy (15 fractions, 5 d per week); 20 GyE in four fractions (5 GyE/Fx) was delivered in the first course to the PGTV covering the entire tumor, and then in the second course to PTV to the full dose [alternatively, the whole bladder receives an additional 44 Gy in 11 (4 GyE/Fx) fractions].

OUTCOME AND FOLLOW-UP

The treatment was started on August 28, 2020. Blood routine, biochemical items, and urine routine were regularly reviewed every 2-d during the treatment, and no toxicity and side effects of radiotherapy were found. After five times of CIRT (Figure 4), gross hematuria disappeared and dysuria was relieved. URBC value of routine URBC decreased significantly (14653 cases/ μ L to 31 cases/ μ L). After the initial six times of CIRT, the patient's gross hematuria was completely disappeared (Figure 1B). At the end of the CIRT, pelvic CT indicated that the tumor shrank to 7.6 mm \times 17.7 mm, the maximum tumor diameter shrank to 39.1%, and the RECIST1.1 tumor efficacy was assessed as PR, and there were thickening changes of the bladder wall (Figure 5). At the 4-mo of follow-up, A large amount of urinary sediment was discharged during and until 50 d after treatment. About 30 d after treatment, his pain on straining to urinate disappeared.

There were no Grade II or more acute effect and late effects observed, and CT assessed the tumor completely disappeared and the bladder wall thickening change came back to normal. We assessed it was the complete response, and no any late effects were observed. Toxicities were assessed using the Common Terminology Criteria for Adverse Events (version 4.0).

DISCUSSION

To the best of our knowledge, there are no reports concerning CIRT in the management of bladder carcinomas. Compared to photons, carbon ions have a superior dose conformity, which is even better than that of modern radiotherapy techniques such as stereotactic body irradiation or intensity-modulated radiation therapy/volumetric-modulated arc radiotherapy[16]. CIRT also has greater biological advantages due to a higher linear energy transfer of heavy ions, resulting in better local tumor control and fewer adverse effects on normal tissue[17-20]. Hence, CIRT may be an effective treatment for patients with bladder carcinoma.

The most appropriate treatment algorithm for muscle invasive disease remains controversial. Although radical cystectomy has long been the standard treatment in the United States, organ-preserving regimens using irradiation with concurrent chemotherapy are emerging as viable alternatives in a subset of patients. In clinical practice, irradiation as an adjuvant to cystectomy, preoperative radiation therapy, or postoperative radiation therapy is often used. In the past, radical EBRT was widely used as a single modality for T2 to T4 bladder cancers, particularly in Europe. In the United States, however, the use of irradiation was frequently limited to patients whose medical comorbidities made them poor candidates for surgical monotherapy.

However, currently, there is no CIRT protocol for bladder cancer worldwide. The main reason is that the bladder volume and shape are constantly changing, so it is difficult to ensure the accuracy of treatment and spare OARs. In our clinical experience with applying carbon ion treatment for prostate cancer and cervical cancer, we adopted a closed thoracic drainage bottle to control the pressure and volume of the bladder to ultimately summarize the "galloping scheme" and found that this approach could perfectly resolve the issue of changes in bladder volume and shape.

The present patient had inoperable cancer, was elderly, and was not even a candidate for surgery or chemotherapy. From our clinical experience, for both bladder cancer and other cancers, we found that CIRT was effective in controlling hemorrhage. For this patient, after six fractions of CIRT, the patient's gross hematuria disappeared. Studies investigating EBRT for bladder-related bleeding (follow-up) have reported a 10%-100% efficacy. A few retrospective studies have reported the efficacy of different radiotherapy schedules as palliative treatment for bladder invasion-related gross hematuria, with a hemostatic control rate of 16%-100%. Even though the studies were very heterogeneous in terms of doses and techniques, all of them consistently showed a high rate of HC with low toxicity rates. All patients presented hematuria related to bladder invasion.

For muscle invasive bladder cancer, a single radiotherapy modality is no longer sufficient, and comprehensive treatment is often required. This patient was unable to receive comprehensive treatment due to the presence of many complications, which may have affected the efficacy of treatment in this patient.

Carbon ion beams can provide ideal dose distributions and improved biological efficacy, and their efficacy does not depend on the cell cycle stage.

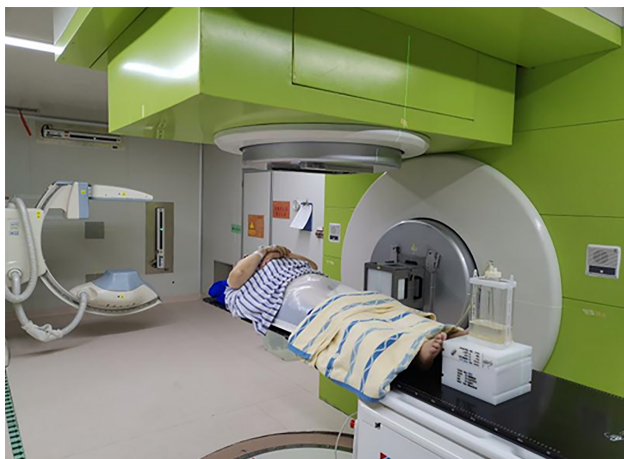

Figure 4 Image of patient during computed tomography immobilization with “galloping scheme”.

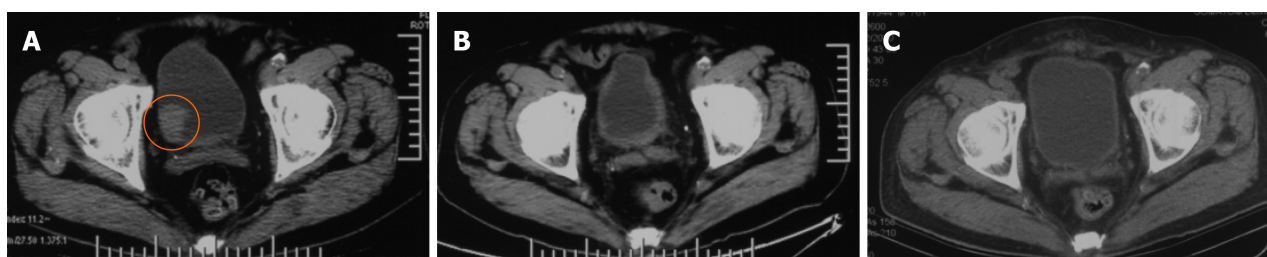


Figure 5 Computed tomography images. A: Pre-carbon ion radiotherapy (CIRT, tumor shown as red circle); B: After CIRT; C: Three months after CIRT.

CONCLUSION

In summary, the present study shows that CIRT is feasible, even in very elderly patients with comorbidities. CIRT had good tolerance, with few acute or late severe toxic events. As shown in this study, CIRT deserves further investigation in trials. Nevertheless, this is the first report of CIRT for bladder carcinoma, and we achieved a great success. Thus, we want to report our results to help more patients around the world.

The management of this patient population, which includes our patient, is challenging, and CIRT might be an effective and safe option worthy for further evaluation due to its higher relative biological effectiveness associated with greater linear energy transfer; this may lead to a higher probability of achieving tumor control with a lower rate of post radiation morbidities.

We reported a case of bladder cancer treated by CIRT. To the best of our knowledge, this is the first study to use CIRT for bladder cancer. Currently, the patient has achieved relapse-free survival. The favorable clinical course and outcome suggest that CIRT might allow for avoiding resection and was well tolerated with curative outcomes.

REFERENCES

- 1 Roghmann F, Breyer J, Kriegmair M, Wezel F, Burger M, Noldus J, Bolenz C; Bladder Cancer Research Initiative for Drug Targets Germany (BRIDGE) Consortium e. V. [Quality assessment of radical cystectomy-opportunities, risks, challenges]. *Urologe A* 2021; **60**: 151-161 [PMID: [33481063](#) DOI: [10.1007/s00120-020-01439-8](#)]
- 2 Aminoltejari K, Black PC. Radical cystectomy: a review of techniques, developments and controversies. *Transl Androl Urol* 2020; **9**: 3073-3081 [PMID: [33457280](#) DOI: [10.21037/tau.2020.03.23](#)]
- 3 Domínguez Escrig JL. [Muscle invasive bladder cancer and bladder preservation protocols. Where are we? *Arch Esp Urol* 2020; **73**: 986-995 [PMID: [33269717](#)]
- 4 Álvarez-Maestro M, Guerrero-Ramos F, Rodríguez-Faba O, Domínguez-Escrig JL, Fernández-Gómez JM. Current treatments for BCG failure in non-muscle invasive bladder cancer (NMIBC).

- Actas Urol Esp (Engl Ed)* 2021; **45**: 93-102 [PMID: [33012593](#) DOI: [10.1016/j.acuro.2020.08.003](#)]
- 5 **Liu Z**, Zhang X, Wu B, Zhao Y, Bai S. Development and Validation of a Model for Predicting Urethral Recurrence in Male Patients with Muscular Invasive Bladder Cancer After Radical Cystectomy Combined with Urinary Diversion. *Cancer Manag Res* 2020; **12**: 7649-7657 [PMID: [32922074](#) DOI: [10.2147/CMAR.S261809](#)]
 - 6 **Inamoto T**, Ibuki N, Komura K, Juri H, Yamamoto K, Fujita K, Nonomura N, Narumi Y, Azuma H. Can bladder preservation therapy come to the center stage? *Int J Urol* 2018; **25**: 134-140 [PMID: [29171098](#) DOI: [10.1111/iju.13495](#)]
 - 7 **Brummelhuis ISG**, Wimper Y, Witjes-van Os HGJM, Arends TJH, van der Heijden AG, Witjes JA. Long-Term Experience with Radiofrequency-Induced Hyperthermia Combined with Intravesical Chemotherapy for Non-Muscle Invasive Bladder Cancer. *Cancers (Basel)* 2021; **13** [PMID: [33498535](#) DOI: [10.3390/cancers13030377](#)]
 - 8 **Mascarenhas F**, Maes K, Marques F, Formoso R, Antunes T. Robot-assisted brachytherapy of the bladder with long distance support using video conferencing. *J Contemp Brachytherapy* 2017; **9**: 375-382 [PMID: [28951758](#) DOI: [10.5114/jcb.2017.69548](#)]
 - 9 **Kulkarni GS**, Hermanns T, Wei Y, Bhindi B, Satkunasivam R, Athanasopoulos P, Bostrom PJ, Kuk C, Li K, Templeton AJ, Sridhar SS, van der Kwast TH, Chung P, Bristow RG, Milosevic M, Warde P, Fleshner NE, Jewett MAS, Bashir S, Zlotta AR. Propensity Score Analysis of Radical Cystectomy Versus Bladder-Sparing Trimodal Therapy in the Setting of a Multidisciplinary Bladder Cancer Clinic. *J Clin Oncol* 2017; **35**: 2299-2305 [PMID: [28410011](#) DOI: [10.1200/JCO.2016.69.2327](#)]
 - 10 **Tiwana MS**, Ni LH, Saini S, Verma SK, Doddamani D, Jain N, Biswas M, Gupta M, Saini M, Chauhan N. Radiation therapy outcomes in muscle invasive urinary bladder cancer: A single institution experience. *Indian J Cancer* 2016; **53**: 143-146 [PMID: [27146766](#) DOI: [10.4103/0019-509X.180842](#)]
 - 11 **Ploussard G**, Daneshmand S, Efstathiou JA, Herr HW, James ND, Rödel CM, Shariat SF, Shipley WU, Sternberg CN, Thalmann GN, Kassouf W. Critical analysis of bladder sparing with trimodal therapy in muscle-invasive bladder cancer: a systematic review. *Eur Urol* 2014; **66**: 120-137 [PMID: [24613684](#) DOI: [10.1016/j.eururo.2014.02.038](#)]
 - 12 **Coraggio G**, Husheng S, Loganadane G, Ghith S, Grellier N, Hervé ML, To NH, Colson Durand L, Jouhaud A, Fayolle Campana M, Nourieh M, Vordos D, Belkacemi Y. Hemostatic radiotherapy for bladder cancer-related hematuria in patients unfit for surgery: is there any impact of fractionation schedule? *J BUON* 2020; **25**: 2092-2096 [PMID: [33099958](#)]
 - 13 **Lacarrière E**, Smaali C, Benyoucef A, Pfister C, Grise P. The efficacy of hemostatic radiotherapy for bladder cancer-related hematuria in patients unfit for surgery. *Int Braz J Urol* 2013; **39**: 808-816 [PMID: [24456773](#) DOI: [10.1590/S1677-5538.IBJU.2013.06.06](#)]
 - 14 **Dirix P**, Vingerhoedt S, Joniau S, Van Cleynenbreugel B, Haustermans K. Hypofractionated palliative radiotherapy for bladder cancer. *Support Care Cancer* 2016; **24**: 181-186 [PMID: [25975677](#) DOI: [10.1007/s00520-015-2765-y](#)]
 - 15 **Mohamad O**, Tabuchi T, Nitta Y, Nomoto A, Sato A, Kasuya G, Makishima H, Choy H, Yamada S, Morishima T, Tsuji H, Miyashiro I, Kamada T. Risk of subsequent primary cancers after carbon ion radiotherapy, photon radiotherapy, or surgery for localised prostate cancer: a propensity score-weighted, retrospective, cohort study. *Lancet Oncol* 2019; **20**: 674-685 [PMID: [30885458](#) DOI: [10.1016/S1470-2045\(18\)30931-8](#)]
 - 16 **Wang WH**, Tsuji H, Ishikawa H, Tsujii H, Kamada T, Mizoe J, Li YX. [Comparison of treatment planning by carbon ion radiotherapy and by intensity-modulated radiotherapy for prostatic adenocarcinoma]. *Zhonghua Zhong Liu Za Zhi* 2006; **28**: 836-839 [PMID: [17416005](#)]
 - 17 **Wang L**, Wang X, Zhang Q, Ran J, Geng Y, Feng S, Li C, Zhao X. Is there a role for carbon therapy in the treatment of gynecological carcinomas? *Future Oncol* 2019; **15**: 3081-3095 [PMID: [31426679](#) DOI: [10.2217/fon-2019-0187](#)]
 - 18 **Okonogi N**, Fukahori M, Wakatsuki M, Ohkubo Y, Kato S, Miyasaka Y, Tsuji H, Nakano T, Kamada T. Dose constraints in the rectum and bladder following carbon-ion radiotherapy for uterus carcinoma: a retrospective pooled analysis. *Radiat Oncol* 2018; **13**: 119 [PMID: [29941040](#) DOI: [10.1186/s13014-018-1061-7](#)]
 - 19 **Okonogi N**, Wakatsuki M, Kato S, Shiba S, Kobayashi D, Kiyohara H, Karasawa K, Ohno T, Nakano T, Kamada T, Shozu M; WORKING GROUP OF GYNECOLOGICAL TUMORS. Long-term Outcomes of Carbon-ion Radiotherapy for Locally Advanced Squamous Cell Carcinoma of the Uterine Cervix. *Anticancer Res* 2018; **38**: 457-463 [PMID: [29277809](#) DOI: [10.21873/anticancer.12244](#)]
 - 20 **Shiba S**, Wakatsuki M, Kato S, Ohno T, Okonogi N, Karasawa K, Kiyohara H, Tsujii H, Nakano T, Kamada T, Shozu M; The Working Group of the Gynecological Tumor. Carbon-ion radiotherapy for locally advanced cervical cancer with bladder invasion. *J Radiat Res* 2016; **57**: 684-690 [PMID: [27422932](#) DOI: [10.1093/jrr/rrw070](#)]



Published by **Baishideng Publishing Group Inc**
7041 Koll Center Parkway, Suite 160, Pleasanton, CA 94566, USA

Telephone: +1-925-3991568

E-mail: bpgoffice@wjgnet.com

Help Desk: <https://www.f6publishing.com/helpdesk>

<https://www.wjgnet.com>

