

World Journal of *Clinical Cases*

World J Clin Cases 2021 September 16; 9(26): 7614-7962



Contents

Thrice Monthly Volume 9 Number 26 September 16, 2021

EDITORIAL

- 7614 Advances in deep learning for computed tomography denoising
Park SB

REVIEW

- 7620 Spirituality, religiousness, and mental health: A review of the current scientific evidence
Lucchetti G, Koenig HG, Lucchetti ALG
- 7632 Role of hospitalization for inflammatory bowel disease in the post-biologic era
Soriano CR, Powell CR, Chiorean MV, Simianu VV

MINIREVIEWS

- 7643 Combined targeted therapy and immunotherapy for cancer treatment
Guo CX, Huang X, Xu J, Zhang XZ, Shen YN, Liang TB, Bai XL

ORIGINAL ARTICLE

Basic Study

- 7653 Mechanism of Jianpi Qingchang Huashi Recipe in treating ulcerative colitis: A study based on network pharmacology and molecular docking
Zheng L, Wen XL, Dai YC

Case Control Study

- 7671 Common bile duct morphology is associated with recurrence of common bile duct stones in Billroth II anatomy patients
Ji X, Jia W, Zhao Q, Wang Y, Ma SR, Xu L, Kan Y, Cao Y, Fan BJ, Yang Z

Retrospective Cohort Study

- 7682 Efficacy of roxadustat in treatment of peritoneal dialysis patients with renal anaemia
Zhu XW, Zhang CX, Xu TH, Jiang GN, Yao L

Retrospective Study

- 7693 Clinical metagenomic sequencing for rapid diagnosis of pneumonia and meningitis caused by *Chlamydia psittaci*
Yin XW, Mao ZD, Zhang Q, Ou QX, Liu J, Shao Y, Liu ZG
- 7704 Evaluation of the etiology and risk factors for maternal sepsis: A single center study in Guangzhou, China
Lin L, Ren LW, Li XY, Sun W, Chen YH, Chen JS, Chen DJ

- 7717 Influencing factors for hepatic fat accumulation in patients with type 2 diabetes mellitus

Wu MJ, Fang QL, Zou SY, Zhu Y, Lu W, Du X, Shi BM

- 7729 Clinical effect of peripheral capsule preservation in eyes with silicone oil tamponade

Jiang B, Dong S, Sun MH, Zhang ZY, Sun DW

- 7738 Potential effects of the nursing work environment on the work-family conflict in operating room nurses

Fu CM, Ou J, Chen XM, Wang MY

Observational Study

- 7750 Effect and satisfaction of outpatient services by precision valuation reservation registration

Jin HJ, Cheng AL, Qian JY, Lin LM, Tang HM

Randomized Controlled Trial

- 7762 Impact of intravenous dexmedetomidine on postoperative bowel movement recovery after laparoscopic nephrectomy: A consort-prospective, randomized, controlled trial

Huang SS, Song FX, Yang SZ, Hu S, Zhao LY, Wang SQ, Wu Q, Liu X, Qi F

META-ANALYSIS

- 7772 Comparison of different methods of nasogastric tube insertion in anesthetized and intubated patients: A meta-analysis

Ou GW, Li H, Shao B, Huang LM, Chen GM, Li WC

CASE REPORT

- 7786 Secondary injuries caused by ill-suited rehabilitation treatments: Five case reports

Zhou L, Zhou YQ, Yang L, Ma SY

- 7798 Gastric *syphilis* mimicking gastric cancer: A case report

Lan YM, Yang SW, Dai MG, Ye B, He FY

- 7805 Low-grade chondrosarcoma of the larynx: A case report

Vučković L, Klisic A, Filipović A, Popović M, Čulafić T

- 7811 Pediatric temporal fistula: Report of three cases

Gu MZ, Xu HM, Chen F, Xia WW, Li XY

- 7818 Treatment for CD57-negative $\gamma\delta$ T-cell large granular lymphocytic leukemia with pure red cell aplasia: A case report

Xiao PP, Chen XY, Dong ZG, Huang JM, Wang QQ, Chen YQ, Zhang Y

- 7825 Rare neonatal malignant primary orbital tumors: Three case reports

Zhang Y, Li YY, Yu HY, Xie XL, Zhang HM, He F, Li HY

- 7833 Carbon ion radiotherapy for bladder cancer: A case report

Zhang YS, Li XJ, Zhang YH, Hu TC, Chen WZ, Pan X, Chai HY, Wang X, Yang YL

- 7840** Extravasation of chemotherapeutic drug from an implantable intravenous infusion port in a child: A case report
Ly DN, Xu HZ, Zheng LL, Chen LL, Ling Y, Ye AQ
- 7845** Chronic active Epstein-Barr virus infection treated with PEG-asparaginase: A case report
Song DL, Wang JS, Chen LL, Wang Z
- 7850** Omental mass combined with indirect inguinal hernia leads to a scrotal mass: A case report
Liu JY, Li SQ, Yao SJ, Liu Q
- 7857** Critical lower extremity ischemia after snakebite: A case report
Lu ZY, Wang XD, Yan J, Ni XL, Hu SP
- 7863** Migration of the localization wire to the back in patient with nonpalpable breast carcinoma: A case report
Choi YJ
- 7870** Uniportal video-assisted thoracoscopic surgery for complex mediastinal mature teratoma: A case report
Hu XL, Zhang D, Zhu WY
- 7876** Congenital disorder of glycosylation caused by mutation of *ATP6AP1* gene (c.1036G>A) in a Chinese infant: A case report
Yang X, Lv ZL, Tang Q, Chen XQ, Huang L, Yang MX, Lan LC, Shan QW
- 7886** Rare monolocular intrahepatic biliary cystadenoma: A case report
Che CH, Zhao ZH, Song HM, Zheng YY
- 7893** Hepatocellular carcinoma with inferior vena cava and right atrium thrombus: A case report
Liu J, Zhang RX, Dong B, Guo K, Gao ZM, Wang LM
- 7901** Delayed diagnosis of ascending colon mucinous adenocarcinoma with local abscess as primary manifestation: Report of three cases
Han SZ, Wang R, Wen KM
- 7909** Gastrointestinal bleeding caused by syphilis: A case report
Sun DJ, Li HT, Ye Z, Xu BB, Li DZ, Wang W
- 7917** Transient involuntary movement disorder after spinal anesthesia: A case report
Yun G, Kim E, Do W, Jung YH, Lee HJ, Kim Y
- 7923** Diagnosis and treatment of an inborn error of bile acid synthesis type 4: A case report
Wang SH, Hui TC, Zhou ZW, Xu CA, Wu WH, Wu QQ, Zheng W, Yin QQ, Pan HY
- 7930** Malignant fibrous histiocytoma of the bone in a traumatic amputation stump: A case report and review of the literature
Zhao KY, Yan X, Yao PF, Mei J

- 7937** Rare complication of acute adrenocortical dysfunction in adrenocortical carcinoma after transcatheter arterial chemoembolization: A case report
Wang ZL, Sun X, Zhang FL, Wang T, Li P
- 7944** Peripherally inserted central catheter placement in neonates with persistent left superior vena cava: Report of eight cases
Chen Q, Hu YL, Li YX, Huang X
- 7954** Subcutaneous angiolipoma in the scrotum: A case report
Li SL, Zhang JW, Wu YQ, Lu KS, Zhu P, Wang XW

LETTER TO THE EDITOR

- 7959** Should people with chronic liver diseases be vaccinated against COVID-19?
Chen LP, Zeng QH, Gong YF, Liang FL

ABOUT COVER

Editorial Board Member of *World Journal of Clinical Cases*, Alessandro Leite Cavalcanti, DDS, MSc, PhD, Associate Professor, Department of Dentistry, State University of Paraiba, Campina Grande 58429500, Paraiba, Brazil. alessandrouepb@gmail.com

AIMS AND SCOPE

The primary aim of *World Journal of Clinical Cases* (WJCC, *World J Clin Cases*) is to provide scholars and readers from various fields of clinical medicine with a platform to publish high-quality clinical research articles and communicate their research findings online.

WJCC mainly publishes articles reporting research results and findings obtained in the field of clinical medicine and covering a wide range of topics, including case control studies, retrospective cohort studies, retrospective studies, clinical trials studies, observational studies, prospective studies, randomized controlled trials, randomized clinical trials, systematic reviews, meta-analysis, and case reports.

INDEXING/ABSTRACTING

The WJCC is now indexed in Science Citation Index Expanded (also known as SciSearch®), Journal Citation Reports/Science Edition, Scopus, PubMed, and PubMed Central. The 2021 Edition of Journal Citation Reports® cites the 2020 impact factor (IF) for WJCC as 1.337; IF without journal self cites: 1.301; 5-year IF: 1.742; Journal Citation Indicator: 0.33; Ranking: 119 among 169 journals in medicine, general and internal; and Quartile category: Q3. The WJCC's CiteScore for 2020 is 0.8 and Scopus CiteScore rank 2020: General Medicine is 493/793.

RESPONSIBLE EDITORS FOR THIS ISSUE

Production Editor: Jia-Hui Li; Production Department Director: Yun-Jie Ma; Editorial Office Director: Jin-Lei Wang.

NAME OF JOURNAL

World Journal of Clinical Cases

ISSN

ISSN 2307-8960 (online)

LAUNCH DATE

April 16, 2013

FREQUENCY

Thrice Monthly

EDITORS-IN-CHIEF

Dennis A Bloomfield, Sandro Vento, Bao-Gan Peng

EDITORIAL BOARD MEMBERS

<https://www.wjnet.com/2307-8960/editorialboard.htm>

PUBLICATION DATE

September 16, 2021

COPYRIGHT

© 2021 Baishideng Publishing Group Inc

INSTRUCTIONS TO AUTHORS

<https://www.wjnet.com/bpg/gerinfo/204>

GUIDELINES FOR ETHICS DOCUMENTS

<https://www.wjnet.com/bpg/GerInfo/287>

GUIDELINES FOR NON-NATIVE SPEAKERS OF ENGLISH

<https://www.wjnet.com/bpg/gerinfo/240>

PUBLICATION ETHICS

<https://www.wjnet.com/bpg/GerInfo/288>

PUBLICATION MISCONDUCT

<https://www.wjnet.com/bpg/gerinfo/208>

ARTICLE PROCESSING CHARGE

<https://www.wjnet.com/bpg/gerinfo/242>

STEPS FOR SUBMITTING MANUSCRIPTS

<https://www.wjnet.com/bpg/GerInfo/239>

ONLINE SUBMISSION

<https://www.f6publishing.com>



Chronic active Epstein-Barr virus infection treated with PEG-asparaginase: A case report

De-Li Song, Jing-Shi Wang, Lei-Lei Chen, Zhao Wang

ORCID number: De-Li Song 0000-0002-3429-7952; Jing-Shi Wang 0000-0001-5050-9225; Lei-Lei Chen 0000-0003-4155-984X; Zhao Wang 0000-0003-1067-4589.

Author contributions: Song DL and Chen LL took care of the patient; Song DL wrote this article; Wang JS and Wang Z guided article writing; all authors have read and approved the final version for submission.

Supported by National Natural Science Foundation of China, No. 81871633; Beijing Natural Science Foundation, No. 7181003; and Beijing Municipal Administration of Hospitals' Ascent Plan, No. DFL20180101.

Informed consent statement: Informed written consent was obtained from the patient for publication of this report and any accompanying images.

Conflict-of-interest statement: The authors declare that they have no conflict of interest.

CARE Checklist (2016) statement: The authors have read the CARE Checklist (2016), and the manuscript was prepared and revised according to the CARE Checklist (2016).

Open-Access: This article is an

De-Li Song, Jing-Shi Wang, Lei-Lei Chen, Zhao Wang, Department of Hematology, Beijing Friendship Hospital, Capital Medical University, Beijing 100050, China

Corresponding author: Zhao Wang, MD, Professor, Department of Hematology, Beijing Friendship Hospital, Capital Medical University, No. 95 Yong An Road, Xicheng District, Beijing 100050, China. wangzhao@ccmu.edu.cn

Abstract

BACKGROUND

Chronic active Epstein-Barr virus infection (EBV) is a systemic EBV-positive lymphoproliferative disease, which may lead to fatal illness. There is currently no standard treatment regimen for chronic active EBV (CAEBV), and hematopoietic stem cell transplantation is the only effective treatment. We here report a CAEBV patient treated with PEG-asparaginase, who achieved negative EBV-DNA.

CASE SUMMARY

A 33-year-old female Chinese patient who had fever for approximately 3 mo was admitted to our hospital in December 2017. EBV-DNA was positive with a high copy number. She was diagnosed with chronic active EB virus infection. PEG-asparaginase was administered at a dose of 1500 U/m² at a 14-d interval, resulting in eradication of EBV for more than 6 mo. The effect of PEG-asparaginase in this patient was excellent.

CONCLUSION

A chemotherapy regimen containing PEG-asparaginase for CAEBV may be further considered.

Key Words: Chronic active Epstein-Barr virus infection; PEG-asparaginase; Chemotherapy; L-asparaginase; Case report

©The Author(s) 2021. Published by Baishideng Publishing Group Inc. All rights reserved.

Core Tip: Chronic active Epstein-Barr virus (EBV) infection may lead to fatal diseases, including EBV-positive lymphoproliferative disorders, lymphomas, and hemophagocytic lymphohistiocytosis. We present a chronic active EBV (CAEBV) patient who was treated with PEG-asparaginase and achieved decreased load of EBV-DNA. PEG-

open-access article that was selected by an in-house editor and fully peer-reviewed by external reviewers. It is distributed in accordance with the Creative Commons Attribution NonCommercial (CC BY-NC 4.0) license, which permits others to distribute, remix, adapt, build upon this work non-commercially, and license their derivative works on different terms, provided the original work is properly cited and the use is non-commercial. See: <http://creativecommons.org/licenses/by-nc/4.0/>

Manuscript source: Unsolicited manuscript

Specialty type: Hematology

Country/Territory of origin: China

Peer-review report's scientific quality classification

Grade A (Excellent): 0
Grade B (Very good): 0
Grade C (Good): 0
Grade D (Fair): 0
Grade E (Poor): 0

Received: March 29, 2021

Peer-review started: March 29, 2021

First decision: April 28, 2021

Revised: May 8, 2021

Accepted: August 13, 2021

Article in press: August 13, 2021

Published online: September 16, 2021

P-Reviewer: Renzo ND

S-Editor: Liu M

L-Editor: A

P-Editor: Zhang YL



asparaginase requires further investigation as a chemotherapy drug for CAEBV to reduce the load of EBV-DNA.

Citation: Song DL, Wang JS, Chen LL, Wang Z. Chronic active Epstein-Barr virus infection treated with PEG-asparaginase: A case report. *World J Clin Cases* 2021; 9(26): 7845-7849

URL: <https://www.wjgnet.com/2307-8960/full/v9/i26/7845.htm>

DOI: <https://dx.doi.org/10.12998/wjcc.v9.i26.7845>

INTRODUCTION

Chronic active Epstein-Barr virus infection (EBV) is a systemic EBV-positive lymphoproliferative disease, which may lead to fatal illness. There is currently no standard treatment regimen for chronic active EBV (CAEBV), and the only effective treatment is hematopoietic stem cell transplantation (HSCT)[1]. We here report a patient with CAEBV who achieved eradication of EBV for more than 6 mo following the completion of PEG-asparaginase treatment. PEG-asparaginase may provide a new treatment regimen to reduce EBV load for CAEBV.

CASE PRESENTATION

Chief complaints

A 33-year-old female Chinese patient was admitted to our hospital with intermittent fever and weakness for 3 mo.

History of present illness

About 2 mo previously, this patient was admitted to a local hospital due to fever and decreased appetite. The laboratory examination showed leukopenia and liver function damage. EBV-DNA was 6.09×10^5 IU/mL in September 2017. Fever was not effectively improved with cephalosporin and ganciclovir. Interferon was given; EBV-DNA decreased slightly, but fever persisted. The fever had lasted 3 mo when she was admitted to our hospital in December 2017.

History of past illness

The patient had no other previous medical history.

Personal and family history

The patient had no personal or family history of similar illnesses.

Physical examination

Physical examination revealed enlargement of multiple superficial lymph nodes and splenomegaly. Abdominal ultrasonography showed that the spleen was 15.7 cm in diameter.

Laboratory examinations

Complete blood count revealed bicytopenia with a white blood cell count of 1.39×10^9 /L, hemoglobin 14.2 gm/dL, and platelet count of 89×10^9 /L. ALT and AST were elevated to 95 U/L and 173.2 U/L, respectively. EBV-DNA (whole blood) was 5.1×10^4 copies/mL and EBV-DNA (plasma) was 5.60×10^4 copies/mL in December 2017. Natural killer cell was mainly involved in lymphocyte subsets of EBV infection, despite the accumulation of all lymphocyte subsets. Flow cytometry of the bone marrow revealed about 2.26% abnormal phenotype natural killer (NK) cells, expressing CD56bri, CD2, CD7, CD94bri, CD161, and CD159a. Biopsy was taken from the swollen left inguinal lymph node and bone marrow. However, no tumor was detected, and EBV-encoded small RNA (EBER) was not found by *in situ* hybridization of two biopsies. The tests of hepatitis virus, human immunodeficiency virus, antinuclear antibody, and rheumatoid antibody were all negative.

FINAL DIAGNOSIS

According to the diagnostic criteria for CAEBV, she was finally diagnosed with CAEBV.

TREATMENT

The patient started on PEG-asparaginase (1500 U/m²) treatment every 14 d from December 2017. The informed consent was obtained from the patient and this therapy was approved by the institutional ethics committee.

OUTCOME AND FOLLOW-UP

The patient's body temperature gradually dropped, and fever improved on the 7th day during the first treatment course with PEG-asparaginase. On the 14th day, the patient's liver enzymes had returned to normal and the spleen shrank to normal size. EBV-DNA (whole blood) was 760 copies/mL and EBV-DNA (plasma) was < 500 copies/mL in January 2018. EBV-DNA had maintained negative for more than 6 mo (Figure 1) since February 2018. Re-examination of the bone marrow showed that abnormal NK cells disappeared. Hypofibrinogenemia was recorded during PEG-asparaginase treatment, but bleeding or thromboembolism did not occur. No other side effects of PEG-asparaginase, such as allergy, pancreatitis, and hepatotoxicity, were noted. The patient rejected allogeneic HSCT for personal reasons. Unfortunately, the patient eventually died due to relapse of CAEBV and occurrence of hemophagocytic lymphohistiocytosis (HLH) after more than 6 mo of PEG-asparaginase treatment. Due to severe liver dysfunction at the time of relapse, the patient could no longer receive PEG-asparaginase therapy.

DISCUSSION

CAEBV is a chronic disease with persistent infectious mononucleosis-like symptoms, such as fever, lymphadenopathy, and hepatosplenomegaly. CAEBV may develop into fatal diseases, including multi-organ failure, EBV-associated T/NK cell lymphoproliferative disorder, T or NK cell lymphomas, and HLH[1].

The diagnostic criteria for CAEBV are as follows: (1) Sustained or recurrent infectious mononucleosis-like symptoms persistent for > 3 mo; (2) Increased amounts of EBV detected by Southern blot hybridization, EBER-positive cells in affected tissues or the peripheral blood, or $\geq 10^{2.5}$ copies/ μ g of EBV-DNA in peripheral blood mononuclear cells (PBMCs); and (3) No evidence of previous immunological abnormalities or other recent infection that might explain the existing condition[2]. Our patient met the above three criteria, and was diagnosed with CAEBV. Cohen *et al*[3] have suggested that the diagnosis of CAEBV must be combined with lymphocytic infiltration and EBV in the tissues to ensure that the organ damage was attributed to EBV-infected lymphocytes. However, EBER was not detected by *in situ* hybridization of the biopsy samples taken from the left inguinal lymph node and bone marrow of the patient that we reported. In a study by Kawamoto *et al*[4], the median count of EBER-positive cells in the affected lesion of patients with CAEBV was 53 per high-power field, and 86.3% (44/51) of the cases showed ≥ 10 EBER-positive cells per high-power field. Hence, in some patients, EBER may be negative in tissues, but high EBV-DNA load is detected in PBMCs.

There is currently no standard treatment for CAEBV. Sawada *et al*[5] suggested a sequential treatment strategy consisting of prednisolone, cyclosporine A, and etoposide, a so-called cooling therapy as the first step, and combination chemotherapies, such as CHOP (cyclophosphamide, doxorubicin, vincristine, and prednisone) regimen. However, the conventional chemotherapy regimen for CAEBV is unsatisfactory, and the resolution rates of CAEBV disease activity by chemotherapy are very low, approximately 10%[1]. The only effective treatment for this disease is HSCT. The high load of EBV-DNA before HSCT may lead to a high risk of recurrence after HSCT. Therefore, more effective chemotherapy could improve outcome and reduce EBV-DNA load of CAEBV patients[1].

PEG-asparaginase, a pegylated form of L-asparaginase, has a prolonged circulation time and diminished immunogenicity compared with native L-asparaginase[6].

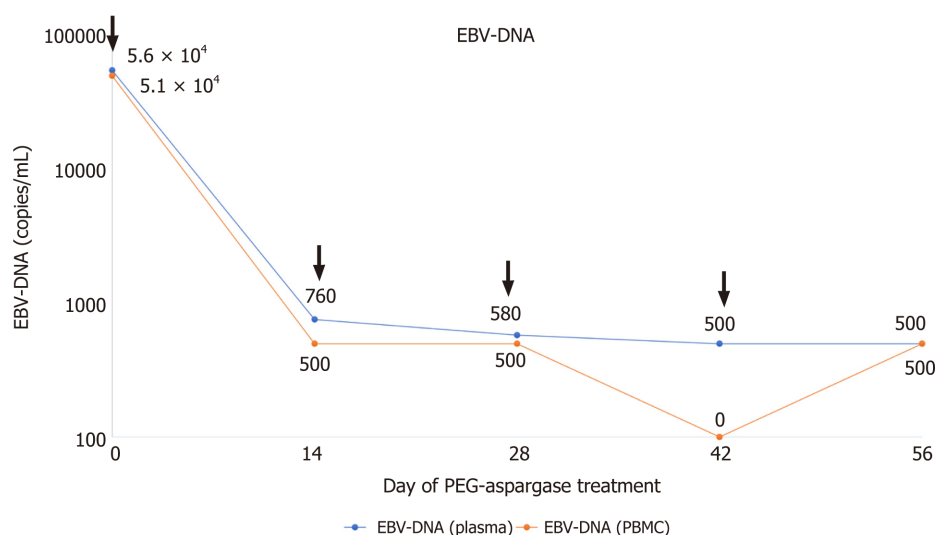


Figure 1 Graph of the Epstein-Barr virus-DNA change trend of the patient after PEG-asparaginase treatment. There is a significant decrease after the first PEG-asparaginase treatment. After the third course of treatment, the patient's Epstein-Barr virus-DNA (EBV-DNA) turned negative (according to our hospital test standard, EBV-DNA < 500 copies/mL is negative). The arrow indicates the time of for PEG-asparaginase treatment. EBV: Epstein-Barr virus.

Therefore, PEG-asparaginase requires less frequent administration and has better treatment efficacy compared to L-asparaginase. Multiple studies on NK/T-cell lymphoma have found that chemotherapy regimens containing PEG-asparaginase significantly reduce the load of EBV-DNA while treating lymphoma, and the reduced load of EBV-DNA after treatment suggests longer survival[7,8]. Our study on refractory relapsed EBV-HLH found that the L-DEP regimen (PEG-asparaginase and DEP combination therapy) can reduce EBV-DNA load while effectively controlling HLH-induced fever and organ dysfunction[9]. Therefore, it can be speculated that PEG-asparaginase may have an “eliminating” effect on EBV infection. In the present patient, EBV was eradicated after treatment with PEG-asparaginase, and EBV-DNA remained negative for more than 6 mo.

The possible mechanisms underlying this may include the following aspects. First, PEG-asparaginase accelerates apoptosis in EBV-positive T and NK cells, which has been confirmed in *in vitro* experiments. Ando *et al*[10] have reported specific antitumor activity of L-asparaginase against NK-cell tumors *in vitro*. Jinta *et al*[11] confirmed that L-asparaginase decreased the number of living cells in all examined EBV-positive cell lines in a dose-dependent manner, an effect not seen in the PBMCs. The “apoptosis” induced by L-asparaginase of EBV-infected T/NK cells may decompose asparagine, an essential amino acid for protein synthesis, such as the effect of treating NK/T cell lymphomas. Second, the expression of P-glycoprotein may be a cause of chemoresistance of EBV-positivity-related malignant disease. Yamaguchi *et al*[12] found that tumor cells from nine of 10 patients with Extranodal natural killer/T-cell lymphoma, an EBV-positive NK-LPD, were positive for P-glycoprotein. They also examined P-glycoprotein expression in ENKL by immunohistochemistry. Yoshimori *et al*[13] reported that EBV-infected T cells in EBV-T-LPDs expressed functional P-glycoprotein. The effect of PEG-asparaginase is not influenced by P-glycoprotein. Therefore, compared to other chemotherapeutic drugs, PEG-asparaginase, which is not a substrate of P-glycoprotein, can more effectively reduce EBV-positive T/NK cells.

Whether CAEBV patients are suitable for PEG-asparaginase therapy remains unclear. Ando *et al*[10] found that the level of asparagine synthetase expression in NK-cell tumors was related to sensitivity and clinical response to L-asparaginase in ENKL. However, Jinta *et al*[11] suggested that the level of asparagine synthetase did not sufficiently determine the response to L-asparaginase on EBV-T/NK-LPDs. Therefore, which indicators reflect the response of patients to PEG-asparaginase should be further explored. In addition, the mechanism of asparaginase therapy is asparagine depletion. However, the optimum target of asparaginase activity to achieve optimal asparagine depletion of PEG-asparaginase still needs to be fully elucidated[14]. Therefore, further clinical study is required to confirm whether regimens containing PEG-asparaginase are effective in treating CAEBV, who can respond to this treatment and how to achieve maximum therapeutic benefit.

CONCLUSION

PEG-asparaginase may be effective in reducing the load of EBV-DNA in CAEBV patients. A chemotherapy regimen containing PEG-asparaginase for treatment of CAEBV may warrant further study.

REFERENCES

- 1 **Arai A.** Advances in the Study of Chronic Active Epstein-Barr Virus Infection: Clinical Features Under the 2016 WHO Classification and Mechanisms of Development. *Front Pediatr* 2019; **7**: 14 [PMID: 30805320 DOI: 10.3389/fped.2019.00014]
- 2 **Kimura H,** Ito Y, Kawabe S, Gotoh K, Takahashi Y, Kojima S, Naoe T, Esaki S, Kikuta A, Sawada A, Kawa K, Ohshima K, Nakamura S. EBV-associated T/NK-cell lymphoproliferative diseases in nonimmunocompromised hosts: prospective analysis of 108 cases. *Blood* 2012; **119**: 673-686 [PMID: 22096243 DOI: 10.1182/blood-2011-10-381921]
- 3 **Cohen JI,** Jaffe ES, Dale JK, Pittaluga S, Heslop HE, Rooney CM, Gottschalk S, Bollard CM, Rao VK, Marques A, Burbelo PD, Turk SP, Fulton R, Wayne AS, Little RF, Cairo MS, El-Mallawany NK, Fowler D, Sportes C, Bishop MR, Wilson W, Straus SE. Characterization and treatment of chronic active Epstein-Barr virus disease: a 28-year experience in the United States. *Blood* 2011; **117**: 5835-5849 [PMID: 21454450 DOI: 10.1182/blood-2010-11-316745]
- 4 **Kawamoto K,** Miyoshi H, Suzuki T, Kozai Y, Kato K, Miyahara M, Yujiri T, Choi I, Fujimaki K, Muta T, Kume M, Moriguchi S, Tamura S, Kato T, Tagawa H, Makiyama J, Kanisawa Y, Sasaki Y, Kurita D, Yamada K, Shimono J, Sone H, Takizawa J, Seto M, Kimura H, Ohshima K. A distinct subtype of Epstein-Barr virus-positive T/NK-cell lymphoproliferative disorder: adult patients with chronic active Epstein-Barr virus infection-like features. *Haematologica* 2018; **103**: 1018-1028 [PMID: 29242302 DOI: 10.3324/haematol.2017.174177]
- 5 **Sawada A,** Inoue M, Kawa K. How we treat chronic active Epstein-Barr virus infection. *Int J Hematol* 2017; **105**: 406-418 [PMID: 28210942 DOI: 10.1007/s12185-017-2192-6]
- 6 **van der Sluis IM,** Vrooman LM, Pieters R, Baruchel A, Escherich G, Goulden N, Mondelaers V, Sanchez de Toledo J, Rizzari C, Silverman LB, Whitlock JA. Consensus expert recommendations for identification and management of asparaginase hypersensitivity and silent inactivation. *Haematologica* 2016; **101**: 279-285 [PMID: 26928249 DOI: 10.3324/haematol.2015.137380]
- 7 **Wang JH,** Wang L, Liu CC, Xia ZJ, Huang HQ, Lin TY, Jiang WQ, Lu Y. Efficacy of combined gemcitabine, oxaliplatin and pegasparaginase (P-gemox regimen) in patients with newly diagnosed advanced-stage or relapsed/refractory extranodal NK/T-cell lymphoma. *Oncotarget* 2016; **7**: 29092-29101 [PMID: 27093153 DOI: 10.18632/oncotarget.8647]
- 8 **Liu T,** Zhu F, Xiao Y, Li Q, Liu X, Yang K, Wu G, Zhang L. Pegasparaginase, gemcitabine, dexamethasone, and cisplatin (P-GDP) combined chemotherapy is effective for newly diagnosed extranodal NK/T-cell lymphoma: a retrospective study. *Cancer Manag Res* 2018; **10**: 5061-5069 [PMID: 30464606 DOI: 10.2147/CMAR.S179567]
- 9 **Wang J,** Wang Y, Wu L, Zhang J, Lai W, Wang Z. PEG-asparaginase and DEP regimen combination therapy for refractory Epstein-Barr virus-associated hemophagocytic lymphohistiocytosis. *J Hematol Oncol* 2016; **9**: 84 [PMID: 27613189 DOI: 10.1186/s13045-016-0317-7]
- 10 **Ando M,** Sugimoto K, Kitoh T, Sasaki M, Mukai K, Ando J, Egashira M, Schuster SM, Oshimi K. Selective apoptosis of natural killer-cell tumours by l-asparaginase. *Br J Haematol* 2005; **130**: 860-868 [PMID: 16156856 DOI: 10.1111/j.1365-2141.2005.05694.x]
- 11 **Jinta M,** Imadome K, Komatsu H, Yoshimori M, Kurata M, Fujiwara S, Miura O, Arai A. L-Asparaginase monotherapy for EBV-positive T/NK lymphoproliferative diseases: A pilot Study. *J Med Dent Sci* 2015; **62**: 1-9 [PMID: 26111530 DOI: 10.11480/620101]
- 12 **Yamaguchi M,** Kita K, Miwa H, Nishii K, Oka K, Ohno T, Shirakawa S, Fukumoto M. Frequent expression of P-glycoprotein/MDR1 by nasal T-cell lymphoma cells. *Cancer* 1995; **76**: 2351-2356 [PMID: 8635042 DOI: 10.1002/1097-0142(19951201)76:11<2351::aid-cnrc2820761125>3.0.co;2-1]
- 13 **Yoshimori M,** Takada H, Imadome K, Kurata M, Yamamoto K, Koyama T, Shimizu N, Fujiwara S, Miura O, Arai A. P-glycoprotein is expressed and causes resistance to chemotherapy in EBV-positive T-cell lymphoproliferative diseases. *Cancer Med* 2015; **4**: 1494-1504 [PMID: 26153782 DOI: 10.1002/cam4.494]
- 14 **Heo YA,** Syed YY, Keam SJ. Pegasparaginase: A Review in Acute Lymphoblastic Leukaemia. *Drugs* 2019; **79**: 767-777 [PMID: 31030380 DOI: 10.1007/s40265-019-01120-1]



Published by **Baishideng Publishing Group Inc**
7041 Koll Center Parkway, Suite 160, Pleasanton, CA 94566, USA

Telephone: +1-925-3991568

E-mail: bpgoffice@wjgnet.com

Help Desk: <https://www.f6publishing.com/helpdesk>

<https://www.wjgnet.com>

