

# World Journal of *Clinical Cases*

*World J Clin Cases* 2021 September 26; 9(27): 7963-8279



## Contents

Thrice Monthly Volume 9 Number 27 September 26, 2021

## EDITORIAL

7963 *Exophiala dermatitidis**Usuda D, Higashikawa T, Hotchi Y, Usami K, Shimozawa S, Tokunaga S, Osugi I, Katou R, Ito S, Yoshizawa T, Asako S, Mishima K, Kondo A, Mizuno K, Takami H, Komatsu T, Oba J, Nomura T, Sugita M*

## REVIEW

7973 Gastric neuroendocrine neoplasms: A review

*Köseoglu H, Duzenli T, Sezikli M*

## MINIREVIEWS

7986 Coronavirus disease 2019 and renal transplantation

*Nassar M, Nso N, Ariyaratnam J, Sandhu J, Mohamed M, Baraka B, Ibrahim A, Alfshawy M, Zheng D, Bhangoo H, Soliman KM, Li M, Rizzo V, Daoud A*

7998 Impact of COVID-19 on liver

*Su YJ, Chang CW, Chen MJ, Lai YC*

## ORIGINAL ARTICLE

## Case Control Study

8008 Association of gestational anemia with pregnancy conditions and outcomes: A nested case-control study

*Sun Y, Shen ZZ, Huang FL, Jiang Y, Wang YW, Zhang SH, Ma S, Liu JT, Zhan YL, Lin H, Chen YL, Shi YJ, Ma LK*

## Retrospective Cohort Study

8020 Clinical stages of recurrent hepatocellular carcinoma: A retrospective cohort study

*Yao SY, Liang B, Chen YY, Tang YT, Dong XF, Liu TQ*

## Retrospective Study

8027 Accuracy of ultrasonography in diagnosis of fetal central nervous system malformation

*Pang B, Pan JJ, Li Q, Zhang X*

8035 Analysis of ocular structural parameters and higher-order aberrations in Chinese children with myopia

*Li X, Hu Q, Wang QR, Feng ZQ, Yang F, Du CY*

8044 Radial nerve recovery following closed nailing of humeral shaft fractures without radial nerve exploration: A retrospective study

*Yeh KL, Liaw CK, Wu TY, Chen CP*

8051 Bridging therapy and direct mechanical thrombectomy in the treatment of cardiogenic cerebral infarction with anterior circulation macrovascular occlusion

*Ding HJ, Ma C, Ye FP, Zhang JF*

- 8061** Endu combined with concurrent chemotherapy and radiotherapy for stage IIB-IVA cervical squamous cell carcinoma patients

*Zhao FJ, Su Q, Zhang W, Yang WC, Zhao L, Gao LY*

### CASE REPORT

- 8071** Primary pancreatic paraganglioma harboring lymph node metastasis: A case report

*Jiang CN, Cheng X, Shan J, Yang M, Xiao YQ*

- 8082** Retraction of lumbar disc herniation achieved by noninvasive techniques: A case report

*Wang P, Chen C, Zhang QH, Sun GD, Wang CA, Li W*

- 8090** Mixed neuroendocrine carcinoma of the gastric stump: A case report

*Zhu H, Zhang MY, Sun WL, Chen G*

- 8097** Diploic vein as a newly treatable cause of pulsatile tinnitus: A case report

*Zhao PF, Zeng R, Qiu XY, Ding HY, Lv H, Li XS, Wang GP, Li D, Gong SS, Wang ZC*

- 8104** Acute myocardial infarction and extensive systemic thrombosis in thrombotic thrombocytopenic purpura: A case report and review of literature

*Şalaru DL, Adam CA, Marcu DTM, Şimon IV, Macovei L, Ambrosie L, Chirita E, Sascau RA, Statescu C*

- 8114** Limited thoracoplasty and free musculocutaneous flap transposition for postpneumonectomy empyema: A case report

*Huang QQ, He ZL, Wu YY, Liu ZJ*

- 8120** Paraneoplastic focal segmental glomerulosclerosis associated with gastrointestinal stromal tumor with cutaneous metastasis: A case report

*Zhou J, Yang Z, Yang CS, Lin H*

- 8127** Acute coronary syndrome with severe atherosclerotic and hyperthyroidism: A case report

*Zhu HM, Zhang Y, Tang Y, Yuan H, Li ZX, Long Y*

- 8135** Gastric cancer with calcifications: A case report

*Lin YH, Yao W, Fei Q, Wang Y*

- 8142** Value of eosinophil count in bronchoalveolar lavage fluid for diagnosis of allergic bronchopulmonary aspergillosis: A case report

*Wang WY, Wan SH, Zheng YL, Zhou LM, Zhang H, Jiang LB*

- 8147** Asymptomatic gastric adenomyoma and heterotopic pancreas in a patient with pancreatic cancer: A case report and review of the literature

*Li K, Xu Y, Liu NB, Shi BM*

- 8157** Successful treatment of gastrointestinal infection-induced septic shock using the oXiris® hemofilter: A case report

*Li Y, Ji XJ, Jing DY, Huang ZH, Duan ML*

- 8164** Streptococcal pneumonia-associated hemolytic uremic syndrome treated by T-antibody-negative plasma exchange in children: Two case reports  
*Wang XL, Du Y, Zhao CG, Wu YB, Yang N, Pei L, Wang LJ, Wang QS*
- 8171** Subclavian steal syndrome associated with Sjogren's syndrome: A case report  
*Hao LJ, Zhang J, Naveed M, Chen KY, Xiao PX*
- 8177** Metachronous mixed cellularity classical Hodgkin's lymphoma and T-cell leukemia/lymphoma: A case report  
*Dong Y, Deng LJ, Li MM*
- 8186** Duodenal perforation after organophosphorus poisoning: A case report  
*Lu YL, Hu J, Zhang LY, Cen XY, Yang DH, Yu AY*
- 8192** Surgical treatment of abnormal systemic artery to the left lower lobe: A case report  
*Zhang YY, Gu XY, Li JL, Liu Z, Lv GY*
- 8199** Madelung's disease with alcoholic liver disease and acute kidney injury: A case report  
*Wu L, Jiang T, Zhang Y, Tang AQ, Wu LH, Liu Y, Li MQ, Zhao LB*
- 8207** Anesthetic technique for awake artery malformation clipping with motor evoked potential and somatosensory evoked potential: A case report  
*Zhou HY, Chen HY, Li Y*
- 8214** Multiple hidden vessels in walled-off necrosis with high-risk bleeding: Report of two cases  
*Xu N, Zhai YQ, Li LS, Chai NL*
- 8220** Non-small-cell lung cancer with epidermal growth factor receptor L861Q-L833F compound mutation benefits from both afatinib and osimertinib: A case report  
*Zhang Y, Shen JQ, Shao L, Chen Y, Lei L, Wang JL*
- 8226** Successful removal of two magnets in the small intestine by laparoscopy and colonoscopy: A case report  
*Oh RG, Lee CG, Park YN, Lee YM*
- 8232** Acute lower extremity arterial thrombosis after intraocular foreign body removal under general anesthesia: A case report and review of literature  
*Jeon S, Hong JM, Lee HJ, Kim E, Lee H, Kim Y, Ri HS, Lee JJ*
- 8242** Low-intensity extracorporeal shock wave therapy for midshaft clavicular delayed union: A case report and review of literature  
*Yue L, Chen H, Feng TH, Wang R, Sun HL*
- 8249** Treatment of bilateral granulomatous lobular mastitis during lactation with traditional Chinese medicine: A case report  
*Li ZY, Sun XM, Li JW, Liu XF, Sun ZY, Chen HH, Dong YL, Sun XH*
- 8260** Early acute fat embolism syndrome caused by femoral fracture: A case report  
*Yang J, Cui ZN, Dong JN, Lin WB, Jin JT, Tang XJ, Guo XB, Cui SB, Sun M, Ji CC*

- 8268** Combined fascia iliaca compartment block and monitored anesthesia care for geriatric patients with hip fracture: Two case reports  
*Zhan L, Zhang YJ, Wang JX*
- 8274** Bell's palsy after inactivated COVID-19 vaccination in a patient with history of recurrent Bell's palsy: A case report  
*Yu BY, Cen LS, Chen T, Yang TH*

**ABOUT COVER**

Editorial Board Member of *World Journal of Clinical Cases*, Sunil Kumar Gupta, MBBS, MD, Reader (Associate Professor), Department of Dermatology, Venereology and Leprology, All India Institute of Medical Sciences, Gorakhpur, Gorakhpur 273008, Uttar Pradesh, India. dr.sunil\_30@yahoo.co.in

**AIMS AND SCOPE**

The primary aim of *World Journal of Clinical Cases* (WJCC, *World J Clin Cases*) is to provide scholars and readers from various fields of clinical medicine with a platform to publish high-quality clinical research articles and communicate their research findings online.

WJCC mainly publishes articles reporting research results and findings obtained in the field of clinical medicine and covering a wide range of topics, including case control studies, retrospective cohort studies, retrospective studies, clinical trials studies, observational studies, prospective studies, randomized controlled trials, randomized clinical trials, systematic reviews, meta-analysis, and case reports.

**INDEXING/ABSTRACTING**

The WJCC is now indexed in Science Citation Index Expanded (also known as SciSearch®), Journal Citation Reports/Science Edition, Scopus, PubMed, and PubMed Central. The 2021 Edition of Journal Citation Reports® cites the 2020 impact factor (IF) for WJCC as 1.337; IF without journal self cites: 1.301; 5-year IF: 1.742; Journal Citation Indicator: 0.33; Ranking: 119 among 169 journals in medicine, general and internal; and Quartile category: Q3. The WJCC's CiteScore for 2020 is 0.8 and Scopus CiteScore rank 2020: General Medicine is 493/793.

**RESPONSIBLE EDITORS FOR THIS ISSUE**

Production Editor: Ji-Hong Lin; Production Department Director: Xiang Li; Editorial Office Director: Jin-Lai Wang.

**NAME OF JOURNAL**

*World Journal of Clinical Cases*

**ISSN**

ISSN 2307-8960 (online)

**LAUNCH DATE**

April 16, 2013

**FREQUENCY**

Thrice Monthly

**EDITORS-IN-CHIEF**

Bao-Gan Peng, Sandro Vento, Dennis A Bloomfield

**EDITORIAL BOARD MEMBERS**

<https://www.wjnet.com/2307-8960/editorialboard.htm>

**PUBLICATION DATE**

September 26, 2021

**COPYRIGHT**

© 2021 Baishideng Publishing Group Inc

**INSTRUCTIONS TO AUTHORS**

<https://www.wjnet.com/bpg/gerinfo/204>

**GUIDELINES FOR ETHICS DOCUMENTS**

<https://www.wjnet.com/bpg/GerInfo/287>

**GUIDELINES FOR NON-NATIVE SPEAKERS OF ENGLISH**

<https://www.wjnet.com/bpg/gerinfo/240>

**PUBLICATION ETHICS**

<https://www.wjnet.com/bpg/GerInfo/288>

**PUBLICATION MISCONDUCT**

<https://www.wjnet.com/bpg/gerinfo/208>

**ARTICLE PROCESSING CHARGE**

<https://www.wjnet.com/bpg/gerinfo/242>

**STEPS FOR SUBMITTING MANUSCRIPTS**

<https://www.wjnet.com/bpg/GerInfo/239>

**ONLINE SUBMISSION**

<https://www.f6publishing.com>

## Exophiala dermatitidis

Daisuke Usuda, Toshihiro Higashikawa, Yuta Hotchi, Kenki Usami, Shintaro Shimozaawa, Shungo Tokunaga, Ippei Osugi, Risa Katou, Sakurako Ito, Toshihiko Yoshizawa, Suguru Asako, Kentaro Mishima, Akihiko Kondo, Keiko Mizuno, Hiroki Takami, Takayuki Komatsu, Jiro Oba, Tomohisa Nomura, Manabu Sugita

**ORCID number:** Daisuke Usuda 0000-0002-0059-4035; Toshihiro Higashikawa 0000-0001-8690-5473; Yuta Hotchi 0000-0002-5576-2956; Kenki Usami 0000-0003-4023-1789; Shintaro Shimozaawa 0000-0001-6155-0039; Shungo Tokunaga 0000-0002-7027-0984; Ippei Osugi 0000-0003-4719-6373; Risa Katou 0000-0001-5231-7438; Sakurako Ito 0000-0001-5477-0551; Toshihiko Yoshizawa 0000-0001-9700-1322; Suguru Asako 0000-0002-5092-1532; Kentaro Mishima 0000-0001-8674-8148; Akihiko Kondo 0000-0002-3709-8000; Keiko Mizuno 0000-0002-6326-6872; Hiroki Takami 0000-0003-2955-3752; Takayuki Komatsu 0000-0002-8730-2081; Jiro Oba 0000-0001-8473-8771; Tomohisa Nomura 0000-0001-5632-2584; Manabu Sugita 0000-0002-1956-9286.

**Author contributions:** Usuda D wrote the manuscript; Higashikawa T, Hotchi Y, Usami K, Shimozaawa S, Tokunaga S, Osugi I, Katou R, Ito S, Yoshizawa T, Asako S, Mishima K, Kondo A, Mizuno K, Takami H, Komatsu T, Oba J, Nomura T, and Sugita M proofread and revised the manuscript; all authors approved the final version to be published.

**Conflict-of-interest statement:** The authors declare that they have no conflict of interest.

**Open-Access:** This article is an open-access article that was

Daisuke Usuda, Yuta Hotchi, Kenki Usami, Shintaro Shimozaawa, Shungo Tokunaga, Ippei Osugi, Risa Katou, Sakurako Ito, Toshihiko Yoshizawa, Suguru Asako, Kentaro Mishima, Akihiko Kondo, Keiko Mizuno, Hiroki Takami, Takayuki Komatsu, Jiro Oba, Tomohisa Nomura, Manabu Sugita, Department of Emergency and Critical Care Medicine, Juntendo University Nerima Hospital, Nerima-ku 177-8521, Tokyo, Japan

Toshihiro Higashikawa, Department of Geriatric Medicine, Kanazawa Medical University Hime Municipal Hospital, Hime-shi 935-8531, Toyama-ken, Japan

**Corresponding author:** Daisuke Usuda, MD, MSc, PhD, Doctor, Lecturer, Department of Emergency and Critical Care Medicine, Juntendo University Nerima Hospital, 3-1-10 Takanodai, Nerima-ku 177-8521, Tokyo, Japan. [d.usuda.qa@juntendo.ac.jp](mailto:d.usuda.qa@juntendo.ac.jp)

### Abstract

*Exophiala* is a genus comprising several species of opportunistic black yeasts, which belongs to Ascomycotina. It is a rare cause of fungal infections. However, infections are often chronic and recalcitrant, and while the number of cases is steadily increasing in both immunocompromised and immunocompetent people, detailed knowledge remains scarce regarding infection mechanisms, virulence factors, specific predisposing factors, risk factors, and host response. The most common manifestations of *Exophiala* infection are skin infections, and the most frequent type of deep infection is pulmonary infection due to inhalation. The invasive disease ranges from cutaneous or subcutaneous infection to systemic dissemination to internal organs. The final identification of the causative organism should be achieved through a combination of several methods, including the newly introduced diagnostic analysis, matrix-assisted laser desorption/ionization-time-of-flight mass spectrometry, together with sequencing of the ribosomal ribonucleic acid internal transcribed spacer region of the fungi, and histological and culture findings. Regarding treatment, because anti-infective agents and natural compounds exhibited poor antibiofilm activity, few treatments have ultimately been found to be effective for specific antifungal therapy, so the optimal antifungal therapy and duration of therapy for these infections remain unknown. Therefore, most forms of disease caused by *Exophiala dermatitidis* require aggressive combination therapies: Both surgical intervention and aggressive antifungal therapy with novel compounds and azoles are necessary for effective treatment.



selected by an in-house editor and fully peer-reviewed by external reviewers. It is distributed in accordance with the Creative Commons Attribution NonCommercial (CC BY-NC 4.0) license, which permits others to distribute, remix, adapt, build upon this work non-commercially, and license their derivative works on different terms, provided the original work is properly cited and the use is non-commercial. See: <http://creativecommons.org/licenses/by-nc/4.0/>

**Manuscript source:** Invited manuscript

**Specialty type:** Mycology

**Country/Territory of origin:** Japan

**Peer-review report's scientific quality classification**

Grade A (Excellent): 0  
Grade B (Very good): B  
Grade C (Good): 0  
Grade D (Fair): 0  
Grade E (Poor): 0

**Received:** March 5, 2021

**Peer-review started:** March 5, 2021

**First decision:** March 25, 2021

**Revised:** April 3, 2021

**Accepted:** August 24, 2021

**Article in press:** August 24, 2021

**Published online:** September 26, 2021

**P-Reviewer:** Uchida-Fujii E

**S-Editor:** Gong ZM

**L-Editor:** A

**P-Editor:** Liu JH



**Key Words:** *Exophiala dermatitidis*; Black yeast; Immunocompromised host; Matrix-assisted laser desorption/ionization-time-of-flight mass spectrometry; Ribosomal ribonucleic acid; Antifungal drugs

©The Author(s) 2021. Published by Baishideng Publishing Group Inc. All rights reserved.

**Core Tip:** *Exophiala* is a genus comprising several species of opportunistic black yeasts, which belongs to Ascomycotina, and it is a rare cause of fungal infections. The final identification of this organism should be achieved through a combination of several methods, including the newly introduced diagnostic analysis, matrix-assisted laser desorption/ionization-time-of-flight mass spectrometry, together with sequencing of the ribosomal ribonucleic acid internal transcribed spacer region of the fungi, and histological and culture findings. Most forms of disease caused by this pathogen require aggressive combination therapies: both surgical intervention and aggressive antifungal therapy with novel compounds and azoles are necessary for effective treatment. Today, detailed knowledge regarding this pathogen is scarce, so further studies are required in order to collect evidence.

**Citation:** Usuda D, Higashikawa T, Hotchi Y, Usami K, Shimozaawa S, Tokunaga S, Osugi I, Katou R, Ito S, Yoshizawa T, Asako S, Mishima K, Kondo A, Mizuno K, Takami H, Komatsu T, Oba J, Nomura T, Sugita M. *Exophiala dermatitidis*. *World J Clin Cases* 2021; 9(27): 7963-7972

**URL:** <https://www.wjgnet.com/2307-8960/full/v9/i27/7963.htm>

**DOI:** <https://dx.doi.org/10.12998/wjcc.v9.i27.7963>

## INTRODUCTION

*Exophiala* is a genus comprising several species of opportunistic black yeasts, which belongs to Ascomycotina, in the order Chaetothyriales[1,2]. *Exophiala dermatitidis* (*E. dermatitidis*) is a melanized, thermophilic, dimorphic, dematiaceous, and hyphal growth state fungus with multiple conidial forms, and it can be found in abundance in extreme natural habitats; in hot, moist artificial environments that are rich in toxic hydrocarbons, such as steam baths and bathrooms; in decaying organic matter; in creosote-treated oak railway ties in regions near sea level; and in dishwashers[3-12]. It is a polyextremophilic opportunistic human pathogen, which has frequently been isolated in tropical regions of the world[8,13]. Its growth characteristics include a polymorphic life cycle, its ability to grow in both high and low temperatures in broadly varying pH environments, its ability to survive high sodium chloride concentrations, and its ability to survive high amounts of both ultraviolet and radioactive radiation[2,10]. However, despite many ecological studies done worldwide, little remains known about the natural habitat of this fungus[2].

This dematiaceous (brown-pigmented) fungus is a large, heterogenous group of molds that can cause a wide range of diseases, including phaeohyphomycosis, chromoblastomycosis, and eumycotic mycetoma; however, it is rarely the cause of fungal infection, primarily in patients who already have certain predisposing factors[3, 8,14-17]. It is known to generate a biofilm in a strain-specific manner, with invasive *E. dermatitidis* isolates forming biofilms with the greatest biomass[16,18]. In addition, melanin, which forms part of the cell wall of black yeasts, is known to be a major contributing factor to the pathogenicity of *E. dermatitidis*, and to its increased resistance against both host defense and anti-infective therapeutics[16]. Additionally, clinically, it is considered to be the most virulent species, and potentially the cause of disseminated infections, as both produce extracellular capsule-like material[19].

## SYMPTOMS

*E. dermatitidis* is a rare cause of fungal infections, and the infection is often chronic and recalcitrant; however, much is still unknown about the mechanisms of infection[2,7,17,



20]. In addition, while the number of cases is steadily increasing in both immunocompromised and immunocompetent people, detailed knowledge remains scarce regarding infection mechanisms, virulence factors, specific predisposing factors, risk factors, and host response[8,17,21].

Altered immune status is known to affect the progress of infectious diseases[14]. While more and more cases have been seen in immunocompromised patients, there is still little knowledge regarding infections, virulence factors, and host response[11]. Immunocompromised patients, including patients undergoing steroid therapy, patients who have received transplants, and patients with cancer and/or AIDS, are especially at risk of contracting fungal infections[14,21]. For instance, cutaneous, subcutaneous, and corneal infections with dematiaceous fungi naturally occur worldwide, and tropical and subtropical climates lend themselves to increased incidence of these infections, particularly because they are seen mainly as opportunistic infections in immune-deficient patients, and can cause cutaneous and subcutaneous phaeohyphomycosis in healthy individuals[4]. Disseminated infections are rare, but becoming more common, particularly in individuals who are immunocompromised, such as chemotherapy patients[3,22,23]. On the other hand, this fungus may potentially be a cause of disseminated infection in humans who otherwise appear to be healthy[24].

The most common manifestations of the infection are skin infections; in addition, less commonly, extracutaneous diseases from traumatic implantation have been reported, including the eyes, heart, gastrointestinal tract, lungs, and bones[3,4,14,22,25,26]. The fungus can actively grow and penetrate the skin; consequently, it is more frequently isolated from superficial, cutaneous, subcutaneous, and deep seated infections, including visceral infections, with central line associated bloodstream infection (CLABSI) or endocarditis seen on rare occasions[11,25,27-29]. Regarding these skin infections, mycetoma is a tumorous skin growth, notable for the black granules that form within tissue[14]. Chromoblastomycosis is a superficial or subcutaneous skin infection, which is histologically characterized by pigmented sclerotic bodies, as well as pseudoepitheliomatous hyperplasia[14]. The invasive disease, known as phaeohyphomycosis, varies significantly: from cutaneous or subcutaneous infections to systemic dissemination to the internal organs[4,14]. According to a previous report, this is the third most common species among the reported causes of disseminated phaeohyphomycosis, at 7%, and is among the most significant human pathogens of the dematiaceous fungi[3].

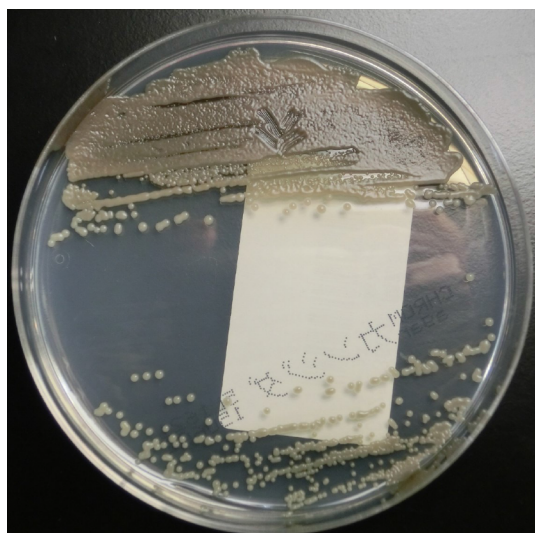
The most common forms of deep infections are respiratory system infections, due to inhalation, and pulmonary infections; the latter are mostly not invasive, but it seems likely that subclinical colonization may be involved in Europe or Latin America, as rates can vary from 1% to 19%[3,16,25,30]. This pathogen is known to cause deep or localized phaeohyphomycosis in immunocompromised people worldwide, and is regularly found in the lungs of cystic fibrosis (CF) patients, but only very rarely is it found in respiratory specimens from patients who do not suffer from CF[2,18,31]. In one study, about 75% of CF patients were found to have been colonized by yeasts, chiefly among these *Candida albicans* (38%) and *C. dubliniensis* (12%). Additionally, *Aspergillus* spp. (*Aspergillus fumigatus*: 29%) was detected in 35% of patients, followed by *E. dermatitidis* and *Scedosporium/Lomentospora* complex isolates, each found in 4% of patients[32]. Conversely, the most common form of systemic phaeohyphomycosis is cerebral infection, though only in Asian patients; other localized deep forms of the disease have also been reported, including arthritis and endocarditis[3,25]. This suggests the potential possibility of race-dependent virulence[25]. Cerebral phaeohyphomycosis is a central nervous infection that is sporadic, but often fatal[7,16,33]. Although cases of cerebral phaeohyphomycosis are known to have occurred in immunocompromised persons, it has most commonly been found in immunocompetent individuals who have no obvious risk factors[3].

## EXAMINATION

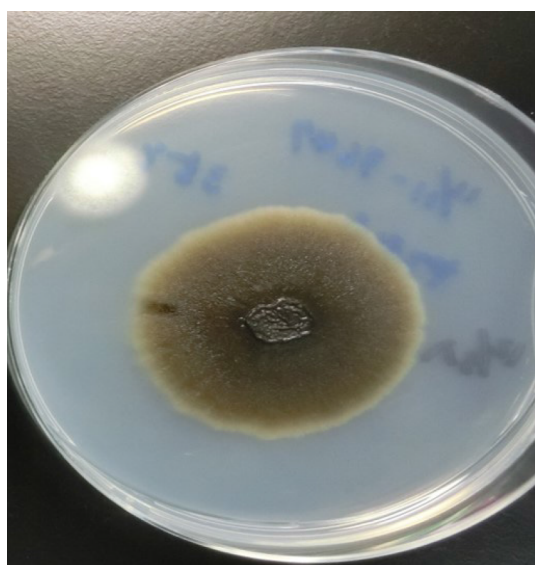Identification of *Exophiala* at the species level has conventionally been based on morphological observations, complemented by molecular tests[34]. Tissue cultures can provide a definitive contribution to differential diagnosis of mold infections[14]. In one study, 100% of *E. dermatitidis* was correctly identified when using Sabouraud glucose agar, and 92.9% of strains were correctly identified at the species level when using Columbia agar[35]. In addition, *Burkholderia cepacia* selective agar can prove useful for recovery from CF patients' sputum samples[36]. Here, we show a sputum sample from

our institution, from a patient with pneumonia due to *E. dermatitidis*. Black, yeast-like colonies grown on the Chromogenic Agar CHROMagar® *Candida* plate can be observed (Figure 1). We extracted and cultured the bacteria on potato dextrose agar using the specimen at 37 °C, yielding a huge colony on the plate 21 days later (Figure 2). In addition, the diphasic form was observed under a differential interference contrast microscope (Figure 3), bacterial growth was confirmed below 40 °C, and morphological characteristics were confirmed with a stereoscopic microscope (Figure 4). All of these characteristics were also compatible with *E. dermatitidis*. However, this is a slow-growing fungus, which can ordinarily take up to two weeks to culture in a microbiology laboratory setting; therefore, it is slow to detect it conventionally, leading to a risk of bacterial overgrowth due to common cohabiting pan- and multi-resistant bacterial pathogens from sputum, specifically *Pseudomonas aeruginosa* and *B. cepacia* complex organisms[37]. As mentioned above, conventional mycological identification, premised on recognizing morphological characteristics, can prove problematic[38].

On the other hand, in the past decade, matrix-assisted laser desorption/ionization-time-of-flight mass spectrometry (MALDI-TOF MS) has come into use at medical centers internationally, as a diagnostic technique[35]. This technique takes advantage of taxon-specific mass patterns that have been recorded from abundant cell proteins, directly from whole-cell preparations[38]. The relationships observed between the ITS (internal transcribed spacer) strains, from the MALDI-TOF MS profiling analyses, were supported by DNA-sequence-based analyses of the ITS1 and ITS2 regions of ribonucleic acid[38]. The ribosomal RNA (rRNA) genes (small and large subunits), rRNA ITS regions, and protein-coding genes, including the genes for translation elongation factor 1- $\alpha$  and  $\beta$ -tubulin, have served as fungal identification targets[38]. There was extremely little intra-species sequence diversity in medically important dematiaceous fungi, such as *E. dermatitidis*: In some cases, no changes were detected at all in *Exophiala* species[15]. Furthermore, the D1/D2 domain is sufficiently variable to identify pathogenic dematiaceous fungi and other relevant species[15]. Therefore, phylogenetic analysis of the ITS region sequence provided information that was useful for not only the identification of new species, but also for the subtyping and origin of *Exophiala* species[39]. The data demonstrated that MALDI-TOF MS can serve a rapid, reliable, and cost-effective way to identify isolates of *E. dermatitidis*, as well as other clinically relevant fungi and yeasts that can ordinarily be difficult to identify using conventional methods[38,40]. This represents a major breakthrough in medical mycology diagnostics, and will lead to improved fungal pathogen identification rates, including rare and nonsporulating fungi, in ordinary clinical laboratory settings[35]. In addition, this is expected to simplify the routine identification of bacteria, mycobacteria, and fungi, compared to using traditional diagnostic methods; one exception, however, is viruses, which, due to their relatively low protein content, remain difficult to detect, even with this technique[35,38]. Consequently, this technique seems promising for use in species-level identification of *Exophiala*, alongside ITS sequencing, which remains the gold standard[41]. On the other hand, there is still very little generated data available on any black yeast species; as a result, these databases are often incomplete or entirely absent[35,41]. However, a recent study has confirmed that this technique is able to identify organisms such as black yeasts, which are ordinarily comparatively difficult to identify, down to the species level, with a discrimination rate of *E. dermatitidis* using MALDI-TOF MS of at least 80.6% – impressive, but unfortunately still not 100%[35]. The identification results for *E. dermatitidis* is based on the database provided with the system. In this study, mass spectrometry was performed using the Microflex LT model (Bruker Daltonik GmbH) MALDI-TOF instrument. Also, the linear positive-ion mode was used within a mass range of 2000-20000 Da for microbial identification, and the instrument was equipped with a 60-Hz nitrogen laser and for each spectrum, 240 Laser shots from different positions of the sample spot were accumulated and analyzed. Accurate, quality-controlled reference databases are still necessary for both the ITS-based and MALDI-TOF MS-based identification modalities, and it understanding each approach's limitations is key[35]. In particular, the low-quality mass spectra caused by bad material processing and insufficient database entries for some fungal isolates can hinder MALDI-TOF MS-based identification; additionally, only a very small percentage of fungi have been sequenced in the ITS region, and the taxonomic reliability of fungal ITS sequences available in public repositories remains inadequate [35]. Another major issue currently associated with MALDI-TOF MS-based identification of fungi is similarities in molecular components, which can make it impossible to distinguish between sister species[41]. As shown here, there are several limitations to the MALDI-TOF MS technique[41].



**Figure 1** Colonies of *Exophiala dermatitidis* on Chromogenic Agar CHROMagar® Candida plate. Sputum sample of pneumonia patient from our institution. Many black, yeast-like colonies were observed.



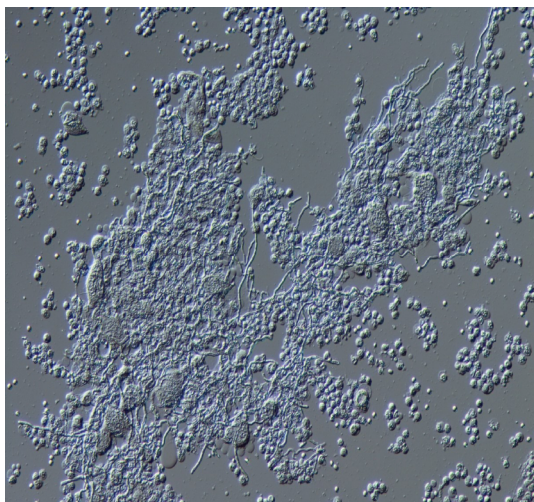
**Figure 2** A colony of *Exophiala dermatitidis* on potato dextrose agar. Sputum sample of pneumonia patient from our institution, 21 d after cultivation. A very large black colony was yielded.

A high-resolution melting assay has been developed, which can be serve to help ascertain the identity of *E. dermatitidis*, which may vary in its clinical significance, with a high degree of accuracy[1]. For species-level identification of *Exophiala* isolates, the ligase-dependent reaction assay was found to be both less expensive and more reliable than rolling circle amplification[42]. Antifungal susceptibility tests demonstrated that triazole compounds were the most active agents against *Exophiala* in vitro[34]. In addition, triazoles, especially itraconazole (ITCZ) and posaconazole (PSCZ), were found to have minimum inhibitory concentration (MIC) values below those of amphotericin B (AMB), caspofungin (CPFG), and flucytosine (5-FC)[40]. This suggests that, in the future, it may be possible to use this in order to identify species directly, in clinical samples and/or in environmental niches[1].

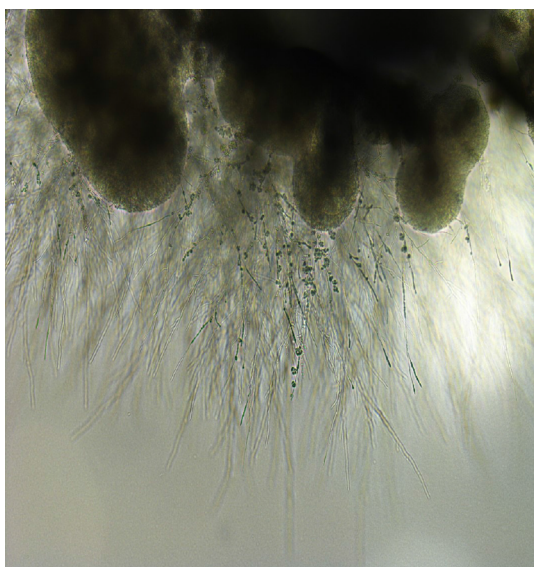
## TREATMENT

Due to the rarity of infections caused by this fungus, little is known about its treatment [17]. Various fungi are able to colonize surfaces and form biofilms[18]. Due to resis-





**Figure 3 Appearance of *Exophiala dermatitidis* under differential interference contrast microscope.** Sputum sample of pneumonia patient from our institution. The diphase form was observed.



**Figure 4 Appearance of *Exophiala dermatitidis* under stereoscopic microscope.** Sputum sample of pneumonia patient from our institution. Melanized, dimorphic, dematiaceous, and hyphal-growth-state fungus, with multiple conidial forms, was confirmed.

tance to antifungal drugs, infections associated with fungal biofilms are frequently refractory to targeted treatment[18]. This leads to a variety of illnesses in humans that are always refractory to the available treatment modalities[43]. Data on *in vitro* susceptibility remains scarce, and seemingly correlates poorly with *in vivo* drug efficacy[44]. More information remains necessary on activities against species of *Exophiala*[44]. Furthermore, although antifungal susceptibility tests have been developed, there is still very little *in vitro* data available for dematiaceous fungi, and comparisons are difficult because the previous literature is often inconsistent regarding methodology[44]. To date, most forms of disease caused by *E. dermatitidis* have required therapy combining surgery with medical treatment that uses novel compounds and azoles, in order to achieve effective results[3,20,25]. In particular, aggressive antifungal therapy is vital, in combination with surgical intervention[45]. However, because anti-infective agents and natural compounds have demonstrated poor antibiofilm activity, few treatments have ultimately been found to be effective when it comes to specific antifungal therapy; as a result, it is still unknown what the optimal antifungal therapy and duration of therapy are for these infections[18,21,25,44]. MIC results for all *E. dermatitidis* strains have revealed that CPFG has the widest range and the highest MICs (range 1–16 mg/L, geometric mean 4.912 mg/L), while PSCZ has the lowest MICs (range 0.016–0.031 mg/L, geometric mean 0.061 mg/L)[10].

However, their clinical effectiveness remains unknown for treatment of infections caused by this fungus[10]. Additionally, European Society of Clinical Microbiology and Infectious Diseases and European Confederation of Medical Mycology joint clinical guidelines for the diagnosis and management of systemic phaeohyphomycosis: Diseases caused by black fungi, which was published in 2014, do not indicate AMB for treatment[34]. Therefore, combination therapies that use novel compounds and azoles could prove to be an effective solution[20,21].

A recent study has reported that crucial stress responses, mechanisms of cell wall repair, and antifungal resistance in pathogenic fungi are governed by Hsp90[43]. Consequently, targeting Hsp90 with specific inhibitors holds considerable promise as a combination strategy[43]. In addition, the compounds were detected to have the greatest impact when added prior to cell adhesion; these findings suggest that, ultimately, prevention may prove more effective than treatment for biofilm-associated infections caused by this fungus[22]. Furthermore, in cases of suspected CLABSI, the most effective treatment seems to be promptly removing the central line, followed by treatment with AMB or an azole[29]. According to another study, pyrvinium pamoate may exert antifungal activity on its own, and may demonstrate a favorable synergy with azoles against planktonic *E. dermatitidis*[20,21]. The underlying mechanisms could perhaps be elucidated by inducing apoptosis/necrosis, inhibiting drug efflux pumps, and signaling pathways that are related to stress response and growth control[20,21]. More in-depth investigation into the mechanism of the antifungal properties of pyrvinium, and the innovation of novel formulation of pyrvinium, may help establish novel antifungal strategies. In addition, lonafarnib, an orally bioavailable nonpeptide tricyclic farnesyltransferase inhibitor, which has excellent pharmacokinetic and safety profiles, could serve to enhance the *in vitro* antifungal activity of ITCZ, PSCZ, and voriconazole against *E. dermatitidis*; this suggests that azoles, particularly ITCZ and PSCZ, combined with a farnesyltransferase inhibitor, might provide a potential strategy for managing infections caused by this fungus[44].

## PROGNOSIS

Diseases reported to have been caused by this fungus range from benign cutaneous infections to systemic infections with a 40% fatality rate[8,11]. In particular, while systemic infections are exceedingly rare, they are associated with both significant morbidity and mortality[9]. A positive outcome was achieved in a disseminated *E. dermatitidis* infection in an immunodeficient patient, through a combination of aggressive surgical intervention and prolonged treatment using broad-spectrum antifungal agents[9]. In addition, it is suspected that melanin may dramatically reduce the invasiveness and virulence of *E. dermatitidis* during the initial days of the skin infection[8].

## CONCLUSION

There are clearly still many uncertainties, mainly regarding accurate diagnosis and treatment. Because of the difficulty of morphological distinction in culture between *E. dermatitidis* and other species, and because no individual technique is sufficient for identification on its own, the final identification of the causative organism should be achieved through a combination of several methods, including the newly introduced diagnostic analysis MALDI-TOF MS, together with sequencing of the rDNA ITS region of the fungi, and histological and culture findings. Furthermore, due to the rarity of infections caused by this fungus, little is known about its treatment. Therefore, further studies are required in order to collect evidence.

## REFERENCES

- 1 **Bahadori T**, Didehdar M, Khansarinezhad B, Shokohi T. Identification of opportunistic and nonopportunistic *Exophiala* species using high resolution melting analysis. *Med Mycol* 2020; **58**: 938-945 [PMID: 31977020 DOI: 10.1093/mmy/myz136]
- 2 **Babič MN**, Zupančič J, Gunde-Cimerman N, de Hoog S, Zalar P. Ecology of the Human Opportunistic Black Yeast *Exophiala dermatitidis* Indicates Preference for Human-Made Habitats. *Mycopathologia* 2018; **183**: 201-212 [PMID: 28447292 DOI: 10.1007/s11046-017-0134-8]

- 3 **Brandt ME**, Warnock DW. Epidemiology, clinical manifestations, and therapy of infections caused by dematiaceous fungi. *J Chemother* 2003; **15** Suppl 2: 36-47 [PMID: [14708965](#) DOI: [10.1179/joc.2003.15.Supplement-2.36](#)]
- 4 **Döğen A**, Kaplan E, Ilkit M, de Hoog GS. Massive contamination of *Exophiala dermatitidis* and *E. phaeomuriformis* in railway stations in subtropical Turkey. *Mycopathologia* 2013; **175**: 381-386 [PMID: [23124309](#) DOI: [10.1007/s11046-012-9594-z](#)]
- 5 **Zalar P**, Novak M, de Hoog GS, Gunde-Cimerman N. Dishwashers--a man-made ecological niche accommodating human opportunistic fungal pathogens. *Fungal Biol* 2011; **115**: 997-1007 [PMID: [21944212](#) DOI: [10.1016/j.funbio.2011.04.007](#)]
- 6 **Lavrin T**, Konte T, Kostanjšek R, Sitar S, Sepčič K, Prpar Mihevc S, Žagar E, Župunski V, Lenassi M, Rogelj B, Gunde Cimerman N. The Neurotropic Black Yeast *Exophiala dermatitidis* Induces Neurocytotoxicity in Neuroblastoma Cells and Progressive Cell Death. *Cells* 2020; **9** [PMID: [32295162](#) DOI: [10.3390/cells9040963](#)]
- 7 **Wang C**, Xing H, Jiang X, Zeng J, Liu Z, Chen J, Wu Y. Cerebral Phaeohyphomycosis Caused by *Exophiala dermatitidis* in a Chinese *CARD9*-Deficient Patient: A Case Report and Literature Review. *Front Neurol* 2019; **10**: 938 [PMID: [31551907](#) DOI: [10.3389/fneur.2019.00938](#)]
- 8 **Poyntner C**, Mirastschijski U, Sterflinger K, Tafer H. Transcriptome Study of an *Exophiala dermatitidis* *PKSI* Mutant on an *ex Vivo* Skin Model: Is Melanin Important for Infection? *Front Microbiol* 2018; **9**: 1457 [PMID: [30018609](#) DOI: [10.3389/fmicb.2018.01457](#)]
- 9 **Lang R**, Minion J, Skinner S, Wong A. Disseminated *Exophiala dermatitidis* causing septic arthritis and osteomyelitis. *BMC Infect Dis* 2018; **18**: 255 [PMID: [29866071](#) DOI: [10.1186/s12879-018-3171-0](#)]
- 10 **Yazdanparast SA**, Mohseni S, De Hoog GS, Aslani N, Sadeh A, Badali H. Consistent high prevalence of *Exophiala dermatitidis*, a neurotropic opportunist, on railway sleepers. *J Mycol Med* 2017; **27**: 180-187 [PMID: [28190754](#) DOI: [10.1016/j.mycmed.2017.01.007](#)]
- 11 **Poyntner C**, Blasi B, Arcalis E, Mirastschijski U, Sterflinger K, Tafer H. The Transcriptome of *Exophiala dermatitidis* during *Ex-vivo* Skin Model Infection. *Front Cell Infect Microbiol* 2016; **6**: 136 [PMID: [27822460](#) DOI: [10.3389/fcimb.2016.00136](#)]
- 12 **Zupančič J**, Novak Babič M, Zalar P, Gunde-Cimerman N. The Black Yeast *Exophiala dermatitidis* and Other Selected Opportunistic Human Fungal Pathogens Spread from Dishwashers to Kitchens. *PLoS One* 2016; **11**: e0148166 [PMID: [26867131](#) DOI: [10.1371/journal.pone.0148166](#)]
- 13 **Jayaram M**, Nagao H. First Report of Environmental Isolation of *Exophiala* spp. in Malaysia. *Curr Microbiol* 2020; **77**: 2915-2924 [PMID: [32661678](#) DOI: [10.1007/s00284-020-02109-w](#)]
- 14 **Myoken Y**, Sugata T, Fujita Y, Kyo T, Fujihara M, Katsu M, Mikami Y. Successful treatment of invasive stomatitis due to *Exophiala dermatitidis* in a patient with acute myeloid leukemia. *J Oral Pathol Med* 2003; **32**: 51-54 [PMID: [12558959](#) DOI: [10.1034/j.1600-0714.2003.00056.x](#)]
- 15 **Abliz P**, Fukushima K, Takizawa K, Nishimura K. Identification of pathogenic dematiaceous fungi and related taxa based on large subunit ribosomal DNA D1/D2 domain sequence analysis. *FEMS Immunol Med Microbiol* 2004; **40**: 41-49 [PMID: [14734185](#) DOI: [10.1016/S0928-8244\(03\)00275-X](#)]
- 16 **Kirchhoff L**, Olsowski M, Rath PM, Steinmann J. *Exophiala dermatitidis*: Key issues of an opportunistic fungal pathogen. *Virulence* 2019; **10**: 984-998 [PMID: [30887863](#) DOI: [10.1080/21505594.2019.1596504](#)]
- 17 **Tanuskova D**, Horakova J, Buzassyova D, Poczova M, Bodova I, Svec P, Chocholova A, Adamcakova J, Sykora T, Pozdechova M, Geczova L, Kolenova A. A case of *Exophiala dermatitidis* infection in a child after allogeneic stem cell transplantation: case report and literature review of paediatric cases. *JMM Case Rep* 2017; **4**: e005102 [PMID: [29026629](#) DOI: [10.1099/jmmcr.0.005102](#)]
- 18 **Kirchhoff L**, Olsowski M, Zilmans K, Dittmer S, Haase G, Sedlacek L, Steinmann E, Buer J, Rath PM, Steinmann J. Biofilm formation of the black yeast-like fungus *Exophiala dermatitidis* and its susceptibility to anti-infective agents. *Sci Rep* 2017; **7**: 42886 [PMID: [28211475](#) DOI: [10.1038/srep42886](#)]
- 19 **Song Y**, da Silva NM, Weiss VA, Vu D, Moreno LF, Vicente VA, Li R, de Hoog GS. Comparative Genomic Analysis of Capsule-Producing Black Yeasts *Exophiala dermatitidis* and *Exophiala spinifera*, Potential Agents of Disseminated Mycoses. *Front Microbiol* 2020; **11**: 586 [PMID: [32373085](#) DOI: [10.3389/fmicb.2020.00586](#)]
- 20 **Sun Y**, Gao L, Yuan M, Yuan L, Yang J, Zeng T. *In vitro* and *in vivo* Study of Antifungal Effect of Pyrvinium Pamoate Alone and in Combination With Azoles Against *Exophiala dermatitidis*. *Front Cell Infect Microbiol* 2020; **10**: 576975 [PMID: [33194816](#) DOI: [10.3389/fcimb.2020.576975](#)]
- 21 **Hagiya H**, Maeda T, Kusakabe S, Kawasaki K, Hori Y, Kimura K, Ueda A, Yoshioka N, Sunada A, Nishi I, Morii E, Kanakura Y, Tomono K. A fatal case of *Exophiala dermatitidis* disseminated infection in an allogeneic hematopoietic stem cell transplant recipient during micafungin therapy. *J Infect Chemother* 2019; **25**: 463-466 [PMID: [30679025](#) DOI: [10.1016/j.jiac.2018.12.009](#)]
- 22 **Gutierrez-Velez M**, Hoang A, Weinstein J, Harkins K, Shah R. Endogenous *Exophiala dermatitidis* endophthalmitis. *Am J Ophthalmol Case Rep* 2020; **19**: 100774 [PMID: [32637729](#) DOI: [10.1016/j.ajoc.2020.100774](#)]
- 23 **Yoshida T**, Tachita T, Fujinami H, Oshima Y, Sasaki H, Marumo Y, Narita T, Ito A, Ri M, Kusumoto S, Ishida T, Komatsu H, Iida S. *Exophiala dermatitidis* Fungemia Diagnosed Using Time-of-flight Mass Spectrometry during Chemotherapy for Malignant Lymphoma and Successful Treatment with Voriconazole. *Intern Med* 2019; **58**: 2219-2224 [PMID: [30996161](#) DOI: [10.2169/internalmedicine.2082-18](#)]

- 24 **Song Y**, Laureijssen-van de Sande WWJ, Moreno LF, Gerrits van den Ende B, Li R, de Hoog S. Comparative Ecology of Capsular *Exophiala* Species Causing Disseminated Infection in Humans. *Front Microbiol* 2017; **8**: 2514 [PMID: 29312215 DOI: 10.3389/fmicb.2017.02514]
- 25 **Zeng JS**, Sutton DA, Fothergill AW, Rinaldi MG, Harrak MJ, de Hoog GS. Spectrum of clinically relevant *Exophiala* species in the United States. *J Clin Microbiol* 2007; **45**: 3713-3720 [PMID: 17596364 DOI: 10.1128/JCM.02012-06]
- 26 **Iwahashi C**, Eguchi H, Hotta F, Uezumi M, Sawa M, Kimura M, Yaguchi T, Kusaka S. Orbital abscess caused by *Exophiala dermatitidis* following posterior subtenon injection of triamcinolone acetonide: a case report and a review of literature related to *Exophiala* eye infections. *BMC Infect Dis* 2020; **20**: 566 [PMID: 32746887 DOI: 10.1186/s12879-020-05294-y]
- 27 **Vila A**, Jahan C, Rivero C, Amadio C, Ampuero A, Pagella H. Central line associated blood stream infection (CLABSI) due to *Exophiala dermatitidis* in an adult patient: Case report and review. *Med Mycol Case Rep* 2019; **24**: 33-36 [PMID: 30949426 DOI: 10.1016/j.mmcr.2019.03.001]
- 28 **Berger JS**, Cusumano LR, Derose JJ, Sarwar UN. *Exophiala* (*Wangiella*) *dermatitidis* Prosthetic Aortic Valve Endocarditis and Prosthetic Graft Infection in an Immune Competent Patient. *Case Rep Infect Dis* 2017; **2017**: 4839314 [PMID: 28484654 DOI: 10.1155/2017/4839314]
- 29 **Kumar A**, Nandakumar A, Nair S, Singh A, Shashindran N, Thulasidharan S, Subhash K, Ramachandran A, Chowdhary A. *Exophiala dermatitidis* as a cause of central line associated bloodstream infection in an infant: Case report and literature review. *Rev Iberoam Micol* 2021; **38**: 12-15 [PMID: 33279387 DOI: 10.1016/j.riam.2020.09.004]
- 30 **Devoto TB**, Alava KSH, Pola SJ, Pereda R, Ruboglio E, Finquelievich JL, Cuestas ML. Molecular epidemiology of *Aspergillus* species and other moulds in respiratory samples from Argentinean patients with cystic fibrosis. *Med Mycol* 2020; **58**: 867-873 [PMID: 31915834 DOI: 10.1093/mmy/myz133]
- 31 **Grenouillet F**, Cimon B, Pana-Katatali H, Person C, Gainet-Brun M, Malinge MC, Le Govic Y, Richaud-Thiriez B, Bouchara JP. *Exophiala dermatitidis* Revealing Cystic Fibrosis in Adult Patients with Chronic Pulmonary Disease. *Mycopathologia* 2018; **183**: 71-79 [PMID: 29094263 DOI: 10.1007/s11046-017-0218-5]
- 32 **Ziesing S**, Suerbaum S, Sedlacek L. Fungal epidemiology and diversity in cystic fibrosis patients over a 5-year period in a national reference center. *Med Mycol* 2016; **54**: 781-786 [PMID: 27364649 DOI: 10.1093/mmy/myw035]
- 33 **Deng S**, Pan W, Liao W, de Hoog GS, Gerrits van den Ende AH, Vitale RG, Rafati H, Ilkit M, Van der Lee AH, Rijs AJ, Verweij PE, Seyedmousavi S. Combination of Amphotericin B and Flucytosine against Neurotropic Species of Melanized Fungi Causing Primary Cerebral Phaeohyphomycosis. *Antimicrob Agents Chemother* 2016; **60**: 2346-2351 [PMID: 26833164 DOI: 10.1128/AAC.02526-15]
- 34 **Silva WC**, Gonçalves SS, Santos DW, Padovan AC, Bizerra FC, Melo AS. Species diversity, antifungal susceptibility and phenotypic and genotypic characterisation of *Exophiala* spp. infecting patients in different medical centres in Brazil. *Mycoses* 2017; **60**: 328-337 [PMID: 28139861 DOI: 10.1111/myc.12597]
- 35 **Özhak-Baysan B**, Ögünç D, Döğen A, Ilkit M, de Hoog GS. MALDI-TOF MS-based identification of black yeasts of the genus *Exophiala*. *Med Mycol* 2015; **53**: 347-352 [PMID: 25851261 DOI: 10.1093/mmy/myu093]
- 36 **Raclavsky V**, Novotny R. Burkholderia cepacia selective agar can be useful for recovery of *Exophiala dermatitidis* from sputum samples of cystic fibrosis patients. *J Cyst Fibros* 2016; **15**: e19 [PMID: 26778596 DOI: 10.1016/j.jcf.2015.12.021]
- 37 **Nagano Y**, Elborn JS, Millar BC, Goldsmith CE, Rendall J, Moore JE. Development of a novel PCR assay for the identification of the black yeast, *Exophiala* (*Wangiella*) *dermatitidis* from adult patients with cystic fibrosis (CF). *J Cyst Fibros* 2008; **7**: 576-580 [PMID: 18571996 DOI: 10.1016/j.jcf.2008.05.004]
- 38 **Kondori N**, Erhard M, Welinder-Olsson C, Groenewald M, Verkley G, Moore ER. Analyses of black fungi by matrix-assisted laser desorption/ionization time-of-flight mass spectrometry (MALDI-TOF MS): species-level identification of clinical isolates of *Exophiala dermatitidis*. *FEMS Microbiol Lett* 2015; **362**: 1-6 [PMID: 25790495 DOI: 10.1093/femsle/fnu016]
- 39 **Suh MK**, Lee HC, Kim DM, Ha GY, Choi JS. Molecular phylogenetics of *exophiala* species isolated from Korea. *Ann Dermatol* 2012; **24**: 287-294 [PMID: 22879712 DOI: 10.5021/ad.2012.24.3.287]
- 40 **de Almeida JN Júnior**, Sztajnbock J, da Silva AR Junior, Vieira VA, Galastri AL, Bissoli L, Litvinov N, Del Negro GM, Motta AL, Rossi F, Benard G. Rapid identification of moulds and arthroconidial yeasts from positive blood cultures by MALDI-TOF mass spectrometry. *Med Mycol* 2016; **54**: 885-889 [PMID: 27317582 DOI: 10.1093/mmy/myw044]
- 41 **Ergin Ç**, Gök Y, Bayğu Y, Gümrall R, Özhak-Baysan B, Döğen A, Ögünç D, Ilkit M, Seyedmousavi S. ATR-FTIR Spectroscopy Highlights the Problem of Distinguishing Between *Exophiala dermatitidis* and *E. phaeomuriformis* Using MALDI-TOF MS. *Microb Ecol* 2016; **71**: 339-346 [PMID: 26373644 DOI: 10.1007/s00248-015-0670-z]
- 42 **Kaplan E**, Ilkit M, de Hoog GS. Comparison of the rolling circle amplification and ligase-dependent reaction methods for the identification of opportunistic *Exophiala* species. *Med Mycol* 2018; **56**: 759-769 [PMID: 29087521 DOI: 10.1093/mmy/myx095]
- 43 **Gao L**, Sun Y, He C, Li M, Zeng T. In vitro interactions between 17-AAG and azoles against *Exophiala dermatitidis*. *Mycoses* 2018; **61**: 853-856 [PMID: 29998564 DOI: 10.1111/myc.12824]



- 44 **Qiao J**, Sun Y, Gao L, He C, Zheng W. Lonafarnib synergizes with azoles against *Aspergillus* spp. and *Exophiala* spp. *Med Mycol* 2018; **56**: 452-457 [PMID: [29420769](#) DOI: [10.1093/mmy/myx072](#)]
- 45 **Homa M**, Manikandan P, Saravanan V, Revathi R, Anita R, Narendran V, Panneerselvam K, Shobana CS, Aidarous MA, Galgóczy L, Vágvölgyi C, Papp T, Kredics L. *Exophiala dermatitidis* Endophthalmitis: Case Report and Literature Review. *Mycopathologia* 2018; **183**: 603-609 [PMID: [29374798](#) DOI: [10.1007/s11046-017-0235-4](#)]



Published by **Baishideng Publishing Group Inc**  
7041 Koll Center Parkway, Suite 160, Pleasanton, CA 94566, USA

**Telephone:** +1-925-3991568

**E-mail:** [bpgoffice@wjgnet.com](mailto:bpgoffice@wjgnet.com)

**Help Desk:** <https://www.f6publishing.com/helpdesk>

<https://www.wjgnet.com>

