

World Journal of *Clinical Cases*

World J Clin Cases 2021 September 26; 9(27): 7963-8279



Contents

Thrice Monthly Volume 9 Number 27 September 26, 2021

EDITORIAL

7963 *Exophiala dermatitidis**Usuda D, Higashikawa T, Hotchi Y, Usami K, Shimoizawa S, Tokunaga S, Osugi I, Katou R, Ito S, Yoshizawa T, Asako S, Mishima K, Kondo A, Mizuno K, Takami H, Komatsu T, Oba J, Nomura T, Sugita M*

REVIEW

7973 Gastric neuroendocrine neoplasms: A review

Köseoglu H, Duzenli T, Sezikli M

MINIREVIEWS

7986 Coronavirus disease 2019 and renal transplantation

Nassar M, Nso N, Ariyaratnam J, Sandhu J, Mohamed M, Baraka B, Ibrahim A, Alfshawy M, Zheng D, Bhangoo H, Soliman KM, Li M, Rizzo V, Daoud A

7998 Impact of COVID-19 on liver

Su YJ, Chang CW, Chen MJ, Lai YC

ORIGINAL ARTICLE

Case Control Study

8008 Association of gestational anemia with pregnancy conditions and outcomes: A nested case-control study

Sun Y, Shen ZZ, Huang FL, Jiang Y, Wang YW, Zhang SH, Ma S, Liu JT, Zhan YL, Lin H, Chen YL, Shi YJ, Ma LK

Retrospective Cohort Study

8020 Clinical stages of recurrent hepatocellular carcinoma: A retrospective cohort study

Yao SY, Liang B, Chen YY, Tang YT, Dong XF, Liu TQ

Retrospective Study

8027 Accuracy of ultrasonography in diagnosis of fetal central nervous system malformation

Pang B, Pan JJ, Li Q, Zhang X

8035 Analysis of ocular structural parameters and higher-order aberrations in Chinese children with myopia

Li X, Hu Q, Wang QR, Feng ZQ, Yang F, Du CY

8044 Radial nerve recovery following closed nailing of humeral shaft fractures without radial nerve exploration: A retrospective study

Yeh KL, Liaw CK, Wu TY, Chen CP

8051 Bridging therapy and direct mechanical thrombectomy in the treatment of cardiogenic cerebral infarction with anterior circulation macrovascular occlusion

Ding HJ, Ma C, Ye FP, Zhang JF

- 8061** Endu combined with concurrent chemotherapy and radiotherapy for stage IIB-IVA cervical squamous cell carcinoma patients

Zhao FJ, Su Q, Zhang W, Yang WC, Zhao L, Gao LY

CASE REPORT

- 8071** Primary pancreatic paraganglioma harboring lymph node metastasis: A case report

Jiang CN, Cheng X, Shan J, Yang M, Xiao YQ

- 8082** Retraction of lumbar disc herniation achieved by noninvasive techniques: A case report

Wang P, Chen C, Zhang QH, Sun GD, Wang CA, Li W

- 8090** Mixed neuroendocrine carcinoma of the gastric stump: A case report

Zhu H, Zhang MY, Sun WL, Chen G

- 8097** Diploic vein as a newly treatable cause of pulsatile tinnitus: A case report

Zhao PF, Zeng R, Qiu XY, Ding HY, Lv H, Li XS, Wang GP, Li D, Gong SS, Wang ZC

- 8104** Acute myocardial infarction and extensive systemic thrombosis in thrombotic thrombocytopenic purpura: A case report and review of literature

Şalaru DL, Adam CA, Marcu DTM, Şimon IV, Macovei L, Ambrosie L, Chirita E, Sascau RA, Statescu C

- 8114** Limited thoracoplasty and free musculocutaneous flap transposition for postpneumectomy empyema: A case report

Huang QQ, He ZL, Wu YY, Liu ZJ

- 8120** Paraneoplastic focal segmental glomerulosclerosis associated with gastrointestinal stromal tumor with cutaneous metastasis: A case report

Zhou J, Yang Z, Yang CS, Lin H

- 8127** Acute coronary syndrome with severe atherosclerotic and hyperthyroidism: A case report

Zhu HM, Zhang Y, Tang Y, Yuan H, Li ZX, Long Y

- 8135** Gastric cancer with calcifications: A case report

Lin YH, Yao W, Fei Q, Wang Y

- 8142** Value of eosinophil count in bronchoalveolar lavage fluid for diagnosis of allergic bronchopulmonary aspergillosis: A case report

Wang WY, Wan SH, Zheng YL, Zhou LM, Zhang H, Jiang LB

- 8147** Asymptomatic gastric adenomyoma and heterotopic pancreas in a patient with pancreatic cancer: A case report and review of the literature

Li K, Xu Y, Liu NB, Shi BM

- 8157** Successful treatment of gastrointestinal infection-induced septic shock using the oXiris® hemofilter: A case report

Li Y, Ji XJ, Jing DY, Huang ZH, Duan ML

- 8164** Streptococcal pneumonia-associated hemolytic uremic syndrome treated by T-antibody-negative plasma exchange in children: Two case reports
Wang XL, Du Y, Zhao CG, Wu YB, Yang N, Pei L, Wang LJ, Wang QS
- 8171** Subclavian steal syndrome associated with Sjogren's syndrome: A case report
Hao LJ, Zhang J, Naveed M, Chen KY, Xiao PX
- 8177** Metachronous mixed cellularity classical Hodgkin's lymphoma and T-cell leukemia/lymphoma: A case report
Dong Y, Deng LJ, Li MM
- 8186** Duodenal perforation after organophosphorus poisoning: A case report
Lu YL, Hu J, Zhang LY, Cen XY, Yang DH, Yu AY
- 8192** Surgical treatment of abnormal systemic artery to the left lower lobe: A case report
Zhang YY, Gu XY, Li JL, Liu Z, Lv GY
- 8199** Madelung's disease with alcoholic liver disease and acute kidney injury: A case report
Wu L, Jiang T, Zhang Y, Tang AQ, Wu LH, Liu Y, Li MQ, Zhao LB
- 8207** Anesthetic technique for awake artery malformation clipping with motor evoked potential and somatosensory evoked potential: A case report
Zhou HY, Chen HY, Li Y
- 8214** Multiple hidden vessels in walled-off necrosis with high-risk bleeding: Report of two cases
Xu N, Zhai YQ, Li LS, Chai NL
- 8220** Non-small-cell lung cancer with epidermal growth factor receptor L861Q-L833F compound mutation benefits from both afatinib and osimertinib: A case report
Zhang Y, Shen JQ, Shao L, Chen Y, Lei L, Wang JL
- 8226** Successful removal of two magnets in the small intestine by laparoscopy and colonoscopy: A case report
Oh RG, Lee CG, Park YN, Lee YM
- 8232** Acute lower extremity arterial thrombosis after intraocular foreign body removal under general anesthesia: A case report and review of literature
Jeon S, Hong JM, Lee HJ, Kim E, Lee H, Kim Y, Ri HS, Lee JJ
- 8242** Low-intensity extracorporeal shock wave therapy for midshaft clavicular delayed union: A case report and review of literature
Yue L, Chen H, Feng TH, Wang R, Sun HL
- 8249** Treatment of bilateral granulomatous lobular mastitis during lactation with traditional Chinese medicine: A case report
Li ZY, Sun XM, Li JW, Liu XF, Sun ZY, Chen HH, Dong YL, Sun XH
- 8260** Early acute fat embolism syndrome caused by femoral fracture: A case report
Yang J, Cui ZN, Dong JN, Lin WB, Jin JT, Tang XJ, Guo XB, Cui SB, Sun M, Ji CC

- 8268** Combined fascia iliaca compartment block and monitored anesthesia care for geriatric patients with hip fracture: Two case reports
Zhan L, Zhang YJ, Wang JX
- 8274** Bell's palsy after inactivated COVID-19 vaccination in a patient with history of recurrent Bell's palsy: A case report
Yu BY, Cen LS, Chen T, Yang TH

ABOUT COVER

Editorial Board Member of *World Journal of Clinical Cases*, Sunil Kumar Gupta, MBBS, MD, Reader (Associate Professor), Department of Dermatology, Venereology and Leprology, All India Institute of Medical Sciences, Gorakhpur, Gorakhpur 273008, Uttar Pradesh, India. dr.sunil_30@yahoo.co.in

AIMS AND SCOPE

The primary aim of *World Journal of Clinical Cases* (WJCC, *World J Clin Cases*) is to provide scholars and readers from various fields of clinical medicine with a platform to publish high-quality clinical research articles and communicate their research findings online.

WJCC mainly publishes articles reporting research results and findings obtained in the field of clinical medicine and covering a wide range of topics, including case control studies, retrospective cohort studies, retrospective studies, clinical trials studies, observational studies, prospective studies, randomized controlled trials, randomized clinical trials, systematic reviews, meta-analysis, and case reports.

INDEXING/ABSTRACTING

The WJCC is now indexed in Science Citation Index Expanded (also known as SciSearch®), Journal Citation Reports/Science Edition, Scopus, PubMed, and PubMed Central. The 2021 Edition of Journal Citation Reports® cites the 2020 impact factor (IF) for WJCC as 1.337; IF without journal self cites: 1.301; 5-year IF: 1.742; Journal Citation Indicator: 0.33; Ranking: 119 among 169 journals in medicine, general and internal; and Quartile category: Q3. The WJCC's CiteScore for 2020 is 0.8 and Scopus CiteScore rank 2020: General Medicine is 493/793.

RESPONSIBLE EDITORS FOR THIS ISSUE

Production Editor: Ji-Hong Lin; Production Department Director: Xiang Li; Editorial Office Director: Jin-Lai Wang.

NAME OF JOURNAL

World Journal of Clinical Cases

ISSN

ISSN 2307-8960 (online)

LAUNCH DATE

April 16, 2013

FREQUENCY

Thrice Monthly

EDITORS-IN-CHIEF

Dennis A Bloomfield, Sandro Vento, Bao-Gan Peng

EDITORIAL BOARD MEMBERS

<https://www.wjnet.com/2307-8960/editorialboard.htm>

PUBLICATION DATE

September 26, 2021

COPYRIGHT

© 2021 Baishideng Publishing Group Inc

INSTRUCTIONS TO AUTHORS

<https://www.wjnet.com/bpg/gerinfo/204>

GUIDELINES FOR ETHICS DOCUMENTS

<https://www.wjnet.com/bpg/GerInfo/287>

GUIDELINES FOR NON-NATIVE SPEAKERS OF ENGLISH

<https://www.wjnet.com/bpg/gerinfo/240>

PUBLICATION ETHICS

<https://www.wjnet.com/bpg/GerInfo/288>

PUBLICATION MISCONDUCT

<https://www.wjnet.com/bpg/gerinfo/208>

ARTICLE PROCESSING CHARGE

<https://www.wjnet.com/bpg/gerinfo/242>

STEPS FOR SUBMITTING MANUSCRIPTS

<https://www.wjnet.com/bpg/GerInfo/239>

ONLINE SUBMISSION

<https://www.f6publishing.com>



Limited thoracoplasty and free musculocutaneous flap transposition for postpneumonectomy empyema: A case report

Qian-Qian Huang, Zhong-Liang He, Yong-Yong Wu, Zhi-Jun Liu

ORCID number: Qian-Qian Huang 0000-0002-0363-0556; Zhong-Liang He 0000-0003-0990-3604; Yong-Yong Wu 0000-0001-6080-309X; Zhi-Jun Liu 0000-0001-9376-1666.

Author contributions: Huang QQ, Wu YY and Liu ZJ were the patient's cardiothoracic surgeons and nurse, reviewed the literature and contributed to manuscript drafting; He ZL was responsible for the revision of the manuscript for important intellectual content; all authors issued final approval for the version to be submitted.

Informed consent statement:

Written informed consent was obtained from the patient for the publication of this case report and the accompanying images.

Conflict-of-interest statement: The authors declare that they have no conflicts of interest.

CARE Checklist (2016) statement:

The authors have read the CARE Checklist (2016), and the manuscript was prepared and revised accordingly.

Open-Access: This article is an open-access article that was selected by an in-house editor and fully peer-reviewed by external reviewers. It is distributed in accordance with the Creative Commons Attribution

Qian-Qian Huang, Operating Room, Tongde Hospital of Zhejiang Province, Hangzhou 310012, Zhejiang Province, China

Zhong-Liang He, Yong-Yong Wu, Zhi-Jun Liu, Department of Cardiothoracic Surgery, Tongde Hospital of Zhejiang Province, Hangzhou 310012, Zhejiang Province, China

Corresponding author: Zhong-Liang He, MD, Chief Doctor, Director, Surgeon, Department of Cardiothoracic Surgery, Tongde Hospital of Zhejiang Province, No. 234 Gucui Road, Hangzhou 310012, Zhejiang Province, China. doctorhzh@163.com

Abstract

BACKGROUND

Empyema is a severe complication following pneumonectomy that is associated with high morbidity and mortality rates. Although there are a wide variety of treatment options, successful management remains challenging when this condition is combined with a large cavity in very thin patients who had previously undergone a posterolateral thoracotomy.

CASE SUMMARY

We reported the case of a thin, 63-year-old man with a progressive pulmonary cyst who underwent left pneumonectomy *via* posterolateral thoracotomy 23 years ago. After an initially uneventful postoperative course, he was readmitted with empyema and a large cavity 21 years after surgery. He was successfully treated with limited thoracoplasty, followed by free vastus lateralis musculocutaneous flap transposition.

CONCLUSION

This case highlights that the treatment mode of limited thoracoplasty and free vastus lateralis musculocutaneous flap transposition is safe and effective for the management of postpneumonectomy empyema with a large cavity in thin patients who had previously undergone a posterolateral thoracotomy.

Key Words: Pneumonectomy; Postpneumonectomy empyema; Thoracoplasty; Free muscle flap; Surgical treatment; Case report

©The Author(s) 2021. Published by Baishideng Publishing Group Inc. All rights reserved.

NonCommercial (CC BY-NC 4.0) license, which permits others to distribute, remix, adapt, build upon this work non-commercially, and license their derivative works on different terms, provided the original work is properly cited and the use is non-commercial. See: <http://creativecommons.org/licenses/by-nc/4.0/>

Manuscript source: Unsolicited manuscript

Specialty type: Surgery

Country/Territory of origin: China

Peer-review report's scientific quality classification

Grade A (Excellent): 0
Grade B (Very good): 0
Grade C (Good): C
Grade D (Fair): 0
Grade E (Poor): 0

Received: April 10, 2021

Peer-review started: April 10, 2021

First decision: May 11, 2021

Revised: May 24, 2021

Accepted: August 12, 2021

Article in press: August 12, 2021

Published online: September 26, 2021

P-Reviewer: Riis M

S-Editor: Ma YJ

L-Editor: A

P-Editor: Xing YX



Core Tip: Empyema is a severe complication following pneumonectomy and is associated with high morbidity and mortality rates. Although there are a wide variety of treatment options, successful management remains challenging. We performed limited thoracoplasty and free vastus lateralis musculocutaneous flap transposition for postpneumonectomy empyema with a large cavity in a thin patient who had previously undergone a posterolateral thoracotomy. This treatment mode is safe and effective for such patients.

Citation: Huang QQ, He ZL, Wu YY, Liu ZJ. Limited thoracoplasty and free musculocutaneous flap transposition for postpneumonectomy empyema: A case report. *World J Clin Cases* 2021; 9(27): 8114-8119

URL: <https://www.wjgnet.com/2307-8960/full/v9/i27/8114.htm>

DOI: <https://dx.doi.org/10.12998/wjcc.v9.i27.8114>

INTRODUCTION

Postpneumonectomy empyema (PPE) is an uncommon but severe complication that is associated with high morbidity and mortality rates[1,2]. Although there are a wide variety of treatment options for PPE, successful management remains challenging when this condition is combined with a large empyema cavity in very thin patients who had previously undergone a posterolateral thoracotomy[2,3]. Here, we report the case of a 63-year-old man with this kind of PPE who was successfully treated with limited thoracoplasty, followed by free vastus lateralis musculocutaneous flap transposition.

CASE PRESENTATION

Chief complaints

A 63-year-old man was admitted to our hospital due to cough, fever, and malaise for 2 years.

History of present illness

The patient's cough continued, while his fever was relieved by the administration of antibiotics and the insertion of closed thoracic drainage.

History of past illness

The patient had a history of a progressive pulmonary cyst and underwent left pneumonectomy *via* posterolateral thoracotomy 23 years prior to admission.

Personal and family history

The patient was a nonsmoker and had no specific family history.

Physical examination

A physical examination showed that the patient was a very thin man, with a height of 170 cm, a weight of 45 kg and a body mass index of 15.6 kg/m². A scarred posterolateral incision was found on the left collapsed thorax, and chest auscultation demonstrated diminished breath sounds in the left lung field (Figure 1).

Laboratory examinations

The pathogens identified *via* culture of the dark red pus that drained from closed thoracic tubes were *Enterobacter cloacae* and *Proteus mirabilis*.

Imaging examinations

The chest computed tomography (CT) scan revealed complete opacification of the left contracted chest (Figure 2A and B). The patient underwent bronchoscopy, which revealed an intact stump of the left mainstem bronchus.

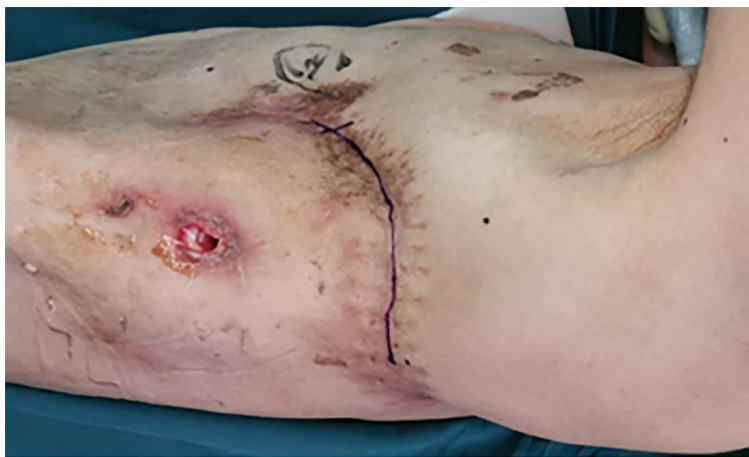

Figure 1 Preoperative image showing a posterolateral scarred incision on the left collapsed thorax.

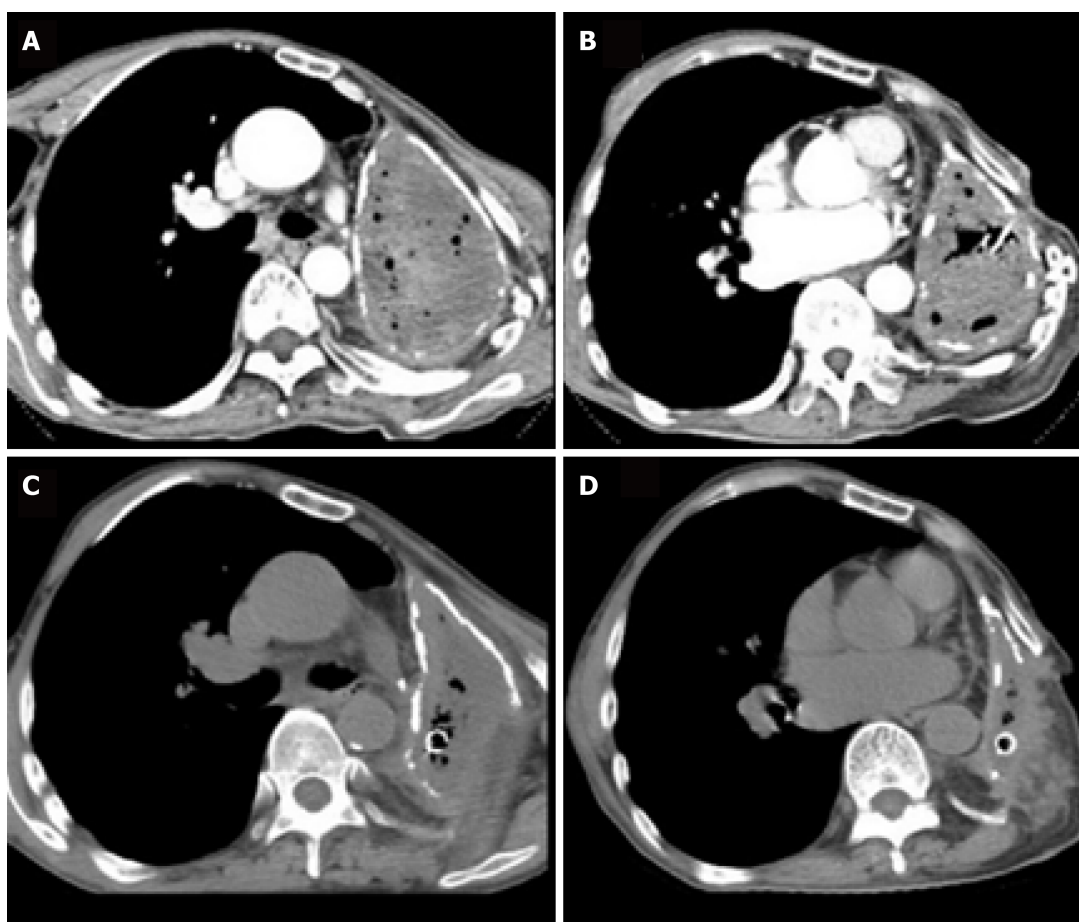


Figure 2 Chest computed tomography scan. A and B: Preoperative chest computed tomography (CT) scan (axial view) revealed complete opacification of the left contracted chest; C and D: Postoperative chest CT scan (axial view) showed that the pleural volume was reduced by half at two months after limited thoracoplasty.

FINAL DIAGNOSIS

The final diagnosis was postpneumonectomy empyema.

TREATMENT

After the patient's condition stabilized, he underwent limited thoracoplasty *via*

resection of the 4th-8th ribs, and two months later, the volume of the residual space of approximately 300 cm³ achieved a 50% reduction in the cavity, as measured by chest CT (Figure 2C and D). When it was confirmed that there was no infection in the cavity, the patient underwent free muscle flap transposition. During this operation, residual cavity debridement was performed, and the ipsilateral thoracodorsal vessels were prepared in the upper left thorax. Then, a free vastus lateralis musculocutaneous flap was harvested from the patient's left thigh and transferred to obliterate the residual space, and separate microvascular anastomoses were completed end to end between the pedicle vessels and the thoracodorsal vessels (Figure 3A and B). The free flap was firmly stabilized inside the space with the surrounding tissue using monofilament absorbable sutures, and the remaining skin paddle was sutured with the surface skin.

OUTCOME AND FOLLOW-UP

The patient was discharged on POD 14 (Figure 3C and D). Fifteen months postoperatively, the patient remained clinically and radiographically disease-free (Figure 4).

DISCUSSION

PPE is a potentially fatal postoperative complication that poses a complex challenge for thoracic surgeons[1,2]. The prevalence of PPE ranges from 2% to 16%, and both local and systemic factors have been implicated in the development of empyema[2,3]. The clinical presentation depends mainly on the presence or absence of a BPF. For patients with PPE without BPF, the onset of infection is often insidious and can occur anywhere from a few days to many years after surgery. Signs and symptoms often initially consist of low-grade fever and leukocytosis, and the mortality rate is higher than 10%. The diagnosis of PPE is usually confirmed by chest CT scans and bacteriological studies[1,2]. Our patient was diagnosed with PPE based on his symptoms, chest CT scan findings, drainage fluid and microbiology.

Once PPE has developed, there are many treatment options[1,2]. After the infection is controlled by adequate pleural drainage, obliteration of PPE may be achieved by treatment options such as antimicrobial solution, thoracoplasty, muscle and greater omentum flap transfer or a combination of these options[3-5]. A major contribution to the treatment of PPE (with or without BPF) came from Clagett and Geraci of the Mayo Clinic, who reported their landmark technique in 1963 that now bears Dr. Clagett's name[1]. However, our patient did not undergo the Clagett procedure because his residual pleural space was very large.

Thoracoplasty has been proven to be a reliable filling procedure[3], and a rough estimate for the expected reduction of the pleural cavity with thoracoplasty is that the resection of 5 ribs results in an approximate 25% collapse, while a 7-rib thoracoplasty can achieve a 50% reduction of the cavity. However, the disadvantages of thoracoplasty reportedly include progressive scoliosis, chronic pain, and a mutilating cosmetic appearance; therefore, the procedure has become obsolete[1,3]. Currently, limited thoracoplasty can be used to reduce the pleural space volume as a surgical step for select cases, such as with our patient. A combination of limited thoracoplasty and intrathoracic muscle transposition is required to effectively obliterate this cavity[1].

Tissue flaps may be used to obliterate the pleural cavity as pedicled, free, and combination methods[4-6]. The most common pedicled muscles used are the latissimus dorsi, serratus anterior, and intercostal muscles[4]. However, for very thin patients who have previously undergone a posterolateral thoracotomy, these muscle flaps may not be sufficient to obliterate the empyema cavity because they have already been divided during the original operation, or the greater omentum may not have enough volume to obliterate the cavity unless an open window thoracostomy is performed[4,5]. In this situation, a free musculocutaneous flap, such as a vastus lateralis, could be harvested and transposed to completely obliterate the cavity after the pleural cavity is reduced by limited thoracoplasty[6]. During the operation, the descending branches of the lateral circumflex femoral artery and two accompanying veins functioning as nutrient vessels underwent separate microvascular anastomoses end to end to the ipsilateral thoracodorsal vessels by interrupted suture. After completion of the microvascular anastomosis, the free flap was firmly stabilized inside the space with the surrounding tissue using monofilament absorbable sutures, and the remaining skin paddle was sutured with the surface skin[6]. This free muscle flap may easily obliterate the pleural space, as the volume was reduced by half at two months

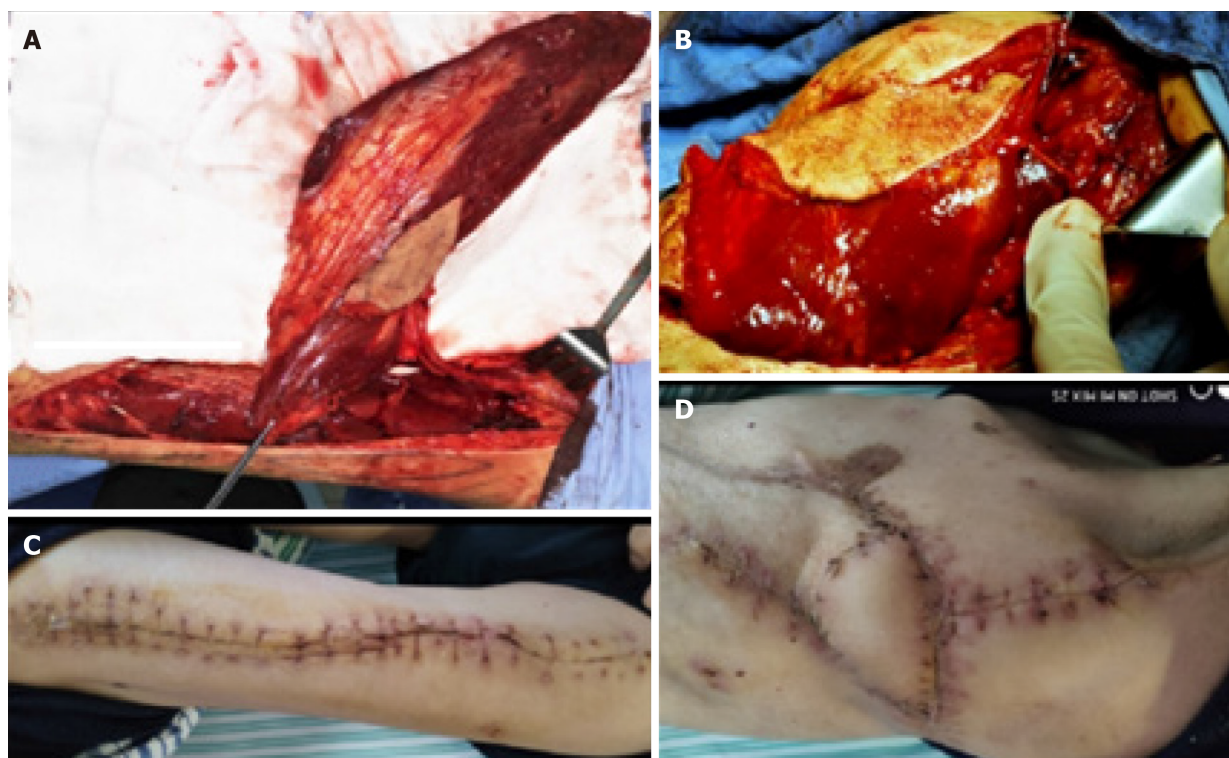


Figure 3 Intraoperative and postoperative images. A: A 27 cm × 11 cm free vastus lateralis musculocutaneous flap was harvested from the patient's left thigh; B: The free flap was transferred to obliterate the residual pleural space; C: Healed donor site; D: The free musculocutaneous flap healed very well.

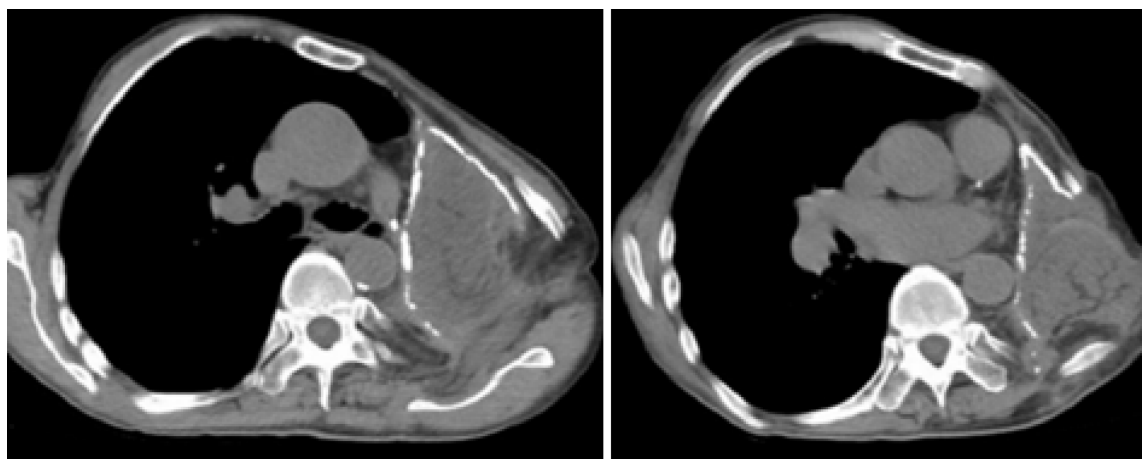


Figure 4 Postoperative chest computed tomography scan (axial view) showing successful obliteration of the empyema cavity by limited thoracoplasty and free vastus lateralis musculocutaneous flap transposition.

after limited thoracoplasty. At 15 mo after surgery, the patient had recovered well without any recurrence.

CONCLUSION

In conclusion, limited thoracoplasty and free muscle flap transposition are effective management methods for PPE in thin patients who have a large cavity.

REFERENCES

- 1 **Bribriesco A**, Patterson GA. Management of Postpneumectomy Bronchopleural Fistula: From Thoracoplasty to Transsternal Closure. *Thorac Surg Clin* 2018; **28**: 323-335 [PMID: [30054070](#) DOI: [10.1016/j.thorsurg.2018.05.008](#)]
- 2 **Hicham H**, Ibrahim I, Rabiou S, Marouane L, Yassine O, Mohamed S. Postpneumectomy empyema: risk factors, prevention, diagnosis, and management. *Asian Cardiovasc Thorac Ann* 2020; **28**: 89-96 [PMID: [31865750](#) DOI: [10.1177/0218492319888048](#)]
- 3 **Hysi I**, Rousse N, Claret A, Bellier J, Pinçon C, Wallet F, Akkad R, Porte H. Open window thoracostomy and thoracoplasty to manage 90 postpneumectomy empyemas. *Ann Thorac Surg* 2011; **92**: 1833-1839 [PMID: [21955574](#) DOI: [10.1016/j.athoracsur.2011.07.004](#)]
- 4 **Lu C**, Feng Z, Ge D, Yuan Y, Zhang Y, Qi F, Gu J, Xu F. Pedicle muscle flap transposition for chronic empyema with persistent bronchopleural fistula: experience of a single clinical center in China. *Surg Today* 2016; **46**: 1132-1137 [PMID: [26743783](#) DOI: [10.1007/s00595-015-1288-y](#)]
- 5 **Shinohara S**, Chikaishi Y, Kuwata T, Takenaka M, Oka S, Hirai A, Imanishi N, Kuroda K, Tanaka F. Benefits of using omental pedicle flap over muscle flap for closure of open window thoracotomy. *J Thorac Dis* 2016; **8**: 1697-1703 [PMID: [27499959](#) DOI: [10.21037/jtd.2016.05.91](#)]
- 6 **He X**, He Z, Shen L, Chen G, He X. Free musculocutaneous flap transfer for refractory chronic empyema with chest wall sinus in a 43-year-old male with hemophilia A. *J Thorac Dis* 2018; **10**: E416-E419 [PMID: [30069395](#) DOI: [10.21037/jtd.2018.05.201](#)]



Published by **Baishideng Publishing Group Inc**
7041 Koll Center Parkway, Suite 160, Pleasanton, CA 94566, USA

Telephone: +1-925-3991568

E-mail: bpgoffice@wjgnet.com

Help Desk: <https://www.f6publishing.com/helpdesk>

<https://www.wjgnet.com>

