

# World Journal of *Clinical Cases*

*World J Clin Cases* 2021 September 26; 9(27): 7963-8279



## Contents

Thrice Monthly Volume 9 Number 27 September 26, 2021

## EDITORIAL

7963 *Exophiala dermatitidis**Usuda D, Higashikawa T, Hotchi Y, Usami K, Shimozaawa S, Tokunaga S, Osugi I, Katou R, Ito S, Yoshizawa T, Asako S, Mishima K, Kondo A, Mizuno K, Takami H, Komatsu T, Oba J, Nomura T, Sugita M*

## REVIEW

7973 Gastric neuroendocrine neoplasms: A review

*Köseoglu H, Duzenli T, Sezikli M*

## MINIREVIEWS

7986 Coronavirus disease 2019 and renal transplantation

*Nassar M, Nso N, Ariyaratnam J, Sandhu J, Mohamed M, Baraka B, Ibrahim A, Alfshawy M, Zheng D, Bhangoo H, Soliman KM, Li M, Rizzo V, Daoud A*

7998 Impact of COVID-19 on liver

*Su YJ, Chang CW, Chen MJ, Lai YC*

## ORIGINAL ARTICLE

## Case Control Study

8008 Association of gestational anemia with pregnancy conditions and outcomes: A nested case-control study

*Sun Y, Shen ZZ, Huang FL, Jiang Y, Wang YW, Zhang SH, Ma S, Liu JT, Zhan YL, Lin H, Chen YL, Shi YJ, Ma LK*

## Retrospective Cohort Study

8020 Clinical stages of recurrent hepatocellular carcinoma: A retrospective cohort study

*Yao SY, Liang B, Chen YY, Tang YT, Dong XF, Liu TQ*

## Retrospective Study

8027 Accuracy of ultrasonography in diagnosis of fetal central nervous system malformation

*Pang B, Pan JJ, Li Q, Zhang X*

8035 Analysis of ocular structural parameters and higher-order aberrations in Chinese children with myopia

*Li X, Hu Q, Wang QR, Feng ZQ, Yang F, Du CY*

8044 Radial nerve recovery following closed nailing of humeral shaft fractures without radial nerve exploration: A retrospective study

*Yeh KL, Liaw CK, Wu TY, Chen CP*

8051 Bridging therapy and direct mechanical thrombectomy in the treatment of cardiogenic cerebral infarction with anterior circulation macrovascular occlusion

*Ding HJ, Ma C, Ye FP, Zhang JF*

- 8061** Endu combined with concurrent chemotherapy and radiotherapy for stage IIB-IVA cervical squamous cell carcinoma patients

*Zhao FJ, Su Q, Zhang W, Yang WC, Zhao L, Gao LY*

### CASE REPORT

- 8071** Primary pancreatic paraganglioma harboring lymph node metastasis: A case report

*Jiang CN, Cheng X, Shan J, Yang M, Xiao YQ*

- 8082** Retraction of lumbar disc herniation achieved by noninvasive techniques: A case report

*Wang P, Chen C, Zhang QH, Sun GD, Wang CA, Li W*

- 8090** Mixed neuroendocrine carcinoma of the gastric stump: A case report

*Zhu H, Zhang MY, Sun WL, Chen G*

- 8097** Diploic vein as a newly treatable cause of pulsatile tinnitus: A case report

*Zhao PF, Zeng R, Qiu XY, Ding HY, Lv H, Li XS, Wang GP, Li D, Gong SS, Wang ZC*

- 8104** Acute myocardial infarction and extensive systemic thrombosis in thrombotic thrombocytopenic purpura: A case report and review of literature

*Şalaru DL, Adam CA, Marcu DTM, Şimon IV, Macovei L, Ambrosie L, Chirita E, Sascau RA, Statescu C*

- 8114** Limited thoracoplasty and free musculocutaneous flap transposition for postpneumonectomy empyema: A case report

*Huang QQ, He ZL, Wu YY, Liu ZJ*

- 8120** Paraneoplastic focal segmental glomerulosclerosis associated with gastrointestinal stromal tumor with cutaneous metastasis: A case report

*Zhou J, Yang Z, Yang CS, Lin H*

- 8127** Acute coronary syndrome with severe atherosclerotic and hyperthyroidism: A case report

*Zhu HM, Zhang Y, Tang Y, Yuan H, Li ZX, Long Y*

- 8135** Gastric cancer with calcifications: A case report

*Lin YH, Yao W, Fei Q, Wang Y*

- 8142** Value of eosinophil count in bronchoalveolar lavage fluid for diagnosis of allergic bronchopulmonary aspergillosis: A case report

*Wang WY, Wan SH, Zheng YL, Zhou LM, Zhang H, Jiang LB*

- 8147** Asymptomatic gastric adenomyoma and heterotopic pancreas in a patient with pancreatic cancer: A case report and review of the literature

*Li K, Xu Y, Liu NB, Shi BM*

- 8157** Successful treatment of gastrointestinal infection-induced septic shock using the oXiris® hemofilter: A case report

*Li Y, Ji XJ, Jing DY, Huang ZH, Duan ML*

- 8164** Streptococcal pneumonia-associated hemolytic uremic syndrome treated by T-antibody-negative plasma exchange in children: Two case reports  
*Wang XL, Du Y, Zhao CG, Wu YB, Yang N, Pei L, Wang LJ, Wang QS*
- 8171** Subclavian steal syndrome associated with Sjogren's syndrome: A case report  
*Hao LJ, Zhang J, Naveed M, Chen KY, Xiao PX*
- 8177** Metachronous mixed cellularity classical Hodgkin's lymphoma and T-cell leukemia/lymphoma: A case report  
*Dong Y, Deng LJ, Li MM*
- 8186** Duodenal perforation after organophosphorus poisoning: A case report  
*Lu YL, Hu J, Zhang LY, Cen XY, Yang DH, Yu AY*
- 8192** Surgical treatment of abnormal systemic artery to the left lower lobe: A case report  
*Zhang YY, Gu XY, Li JL, Liu Z, Lv GY*
- 8199** Madelung's disease with alcoholic liver disease and acute kidney injury: A case report  
*Wu L, Jiang T, Zhang Y, Tang AQ, Wu LH, Liu Y, Li MQ, Zhao LB*
- 8207** Anesthetic technique for awake artery malformation clipping with motor evoked potential and somatosensory evoked potential: A case report  
*Zhou HY, Chen HY, Li Y*
- 8214** Multiple hidden vessels in walled-off necrosis with high-risk bleeding: Report of two cases  
*Xu N, Zhai YQ, Li LS, Chai NL*
- 8220** Non-small-cell lung cancer with epidermal growth factor receptor L861Q-L833F compound mutation benefits from both afatinib and osimertinib: A case report  
*Zhang Y, Shen JQ, Shao L, Chen Y, Lei L, Wang JL*
- 8226** Successful removal of two magnets in the small intestine by laparoscopy and colonoscopy: A case report  
*Oh RG, Lee CG, Park YN, Lee YM*
- 8232** Acute lower extremity arterial thrombosis after intraocular foreign body removal under general anesthesia: A case report and review of literature  
*Jeon S, Hong JM, Lee HJ, Kim E, Lee H, Kim Y, Ri HS, Lee JJ*
- 8242** Low-intensity extracorporeal shock wave therapy for midshaft clavicular delayed union: A case report and review of literature  
*Yue L, Chen H, Feng TH, Wang R, Sun HL*
- 8249** Treatment of bilateral granulomatous lobular mastitis during lactation with traditional Chinese medicine: A case report  
*Li ZY, Sun XM, Li JW, Liu XF, Sun ZY, Chen HH, Dong YL, Sun XH*
- 8260** Early acute fat embolism syndrome caused by femoral fracture: A case report  
*Yang J, Cui ZN, Dong JN, Lin WB, Jin JT, Tang XJ, Guo XB, Cui SB, Sun M, Ji CC*

- 8268** Combined fascia iliaca compartment block and monitored anesthesia care for geriatric patients with hip fracture: Two case reports  
*Zhan L, Zhang YJ, Wang JX*
- 8274** Bell's palsy after inactivated COVID-19 vaccination in a patient with history of recurrent Bell's palsy: A case report  
*Yu BY, Cen LS, Chen T, Yang TH*

**ABOUT COVER**

Editorial Board Member of *World Journal of Clinical Cases*, Sunil Kumar Gupta, MBBS, MD, Reader (Associate Professor), Department of Dermatology, Venereology and Leprology, All India Institute of Medical Sciences, Gorakhpur, Gorakhpur 273008, Uttar Pradesh, India. dr.sunil\_30@yahoo.co.in

**AIMS AND SCOPE**

The primary aim of *World Journal of Clinical Cases* (WJCC, *World J Clin Cases*) is to provide scholars and readers from various fields of clinical medicine with a platform to publish high-quality clinical research articles and communicate their research findings online.

WJCC mainly publishes articles reporting research results and findings obtained in the field of clinical medicine and covering a wide range of topics, including case control studies, retrospective cohort studies, retrospective studies, clinical trials studies, observational studies, prospective studies, randomized controlled trials, randomized clinical trials, systematic reviews, meta-analysis, and case reports.

**INDEXING/ABSTRACTING**

The WJCC is now indexed in Science Citation Index Expanded (also known as SciSearch®), Journal Citation Reports/Science Edition, Scopus, PubMed, and PubMed Central. The 2021 Edition of Journal Citation Reports® cites the 2020 impact factor (IF) for WJCC as 1.337; IF without journal self cites: 1.301; 5-year IF: 1.742; Journal Citation Indicator: 0.33; Ranking: 119 among 169 journals in medicine, general and internal; and Quartile category: Q3. The WJCC's CiteScore for 2020 is 0.8 and Scopus CiteScore rank 2020: General Medicine is 493/793.

**RESPONSIBLE EDITORS FOR THIS ISSUE**

Production Editor: Ji-Hong Lin; Production Department Director: Xiang Li; Editorial Office Director: Jin-Lai Wang.

**NAME OF JOURNAL**

*World Journal of Clinical Cases*

**ISSN**

ISSN 2307-8960 (online)

**LAUNCH DATE**

April 16, 2013

**FREQUENCY**

Thrice Monthly

**EDITORS-IN-CHIEF**

Dennis A Bloomfield, Sandro Vento, Bao-Gan Peng

**EDITORIAL BOARD MEMBERS**

<https://www.wjgnet.com/2307-8960/editorialboard.htm>

**PUBLICATION DATE**

September 26, 2021

**COPYRIGHT**

© 2021 Baishideng Publishing Group Inc

**INSTRUCTIONS TO AUTHORS**

<https://www.wjgnet.com/bpg/gerinfo/204>

**GUIDELINES FOR ETHICS DOCUMENTS**

<https://www.wjgnet.com/bpg/GerInfo/287>

**GUIDELINES FOR NON-NATIVE SPEAKERS OF ENGLISH**

<https://www.wjgnet.com/bpg/gerinfo/240>

**PUBLICATION ETHICS**

<https://www.wjgnet.com/bpg/GerInfo/288>

**PUBLICATION MISCONDUCT**

<https://www.wjgnet.com/bpg/gerinfo/208>

**ARTICLE PROCESSING CHARGE**

<https://www.wjgnet.com/bpg/gerinfo/242>

**STEPS FOR SUBMITTING MANUSCRIPTS**

<https://www.wjgnet.com/bpg/GerInfo/239>

**ONLINE SUBMISSION**

<https://www.f6publishing.com>

## Madelung's disease with alcoholic liver disease and acute kidney injury: A case report

Ling Wu, Ting Jiang, Yan Zhang, An-Qi Tang, Li-Hua Wu, Yu Liu, Ming-Quan Li, Liang-Bin Zhao

**ORCID number:** Ling Wu 0000-0002-8222-4125; Ting Jiang 0000-0003-1776-1626; Yan Zhang 0000-0001-6131-5944; An-Qi Tang 0000-0003-0920-2760; Li-Hua Wu 0000-0001-6112-4195; Yu Liu 0000-0002-9295-8384; Ming-Quan Li 0000-0003-2867-4915; Liang-Bin Zhao 0000-0003-3786-0015.

**Author contributions:** Wu L, Jiang T, and Zhao LB contributed equally to this work and wrote the draft; Jiang T, Zhang Y, Tang AQ, and Liu Y collected the literature; Wu L and Wu LH conceptualized the article and revised the manuscript; Zhao LB and Li MQ were responsible for the revision of the manuscript for important intellectual content; all authors have read and approved the final manuscript.

**Supported by** the National Natural Science Foundation of China, No. 81973831; and the Sichuan Provincial Department of Finance, Sichuan Provincial Department of Labor and Social Security (2020) No. 201 Traditional Chinese Medicine Inheritance and Innovation Ten Thousands of Talents Project-Ye Chuanhui Studio.

**Informed consent statement:** Informed written consent was obtained from the patient for publication of this report and any

Ling Wu, Ting Jiang, An-Qi Tang, Li-Hua Wu, Yu Liu, Ming-Quan Li, Liang-Bin Zhao, Department of Nephrology, Hospital of Chengdu University of Traditional Chinese Medicine, Chengdu 610072, Sichuan Province, China

Yan Zhang, Department of Ultrasound, Hospital of Chengdu University of Traditional Chinese Medicine, Chengdu 610072, Sichuan Province, China

**Corresponding author:** Liang-Bin Zhao, MM, Attending Doctor, Department of Nephrology, Hospital of Chengdu University of Traditional Chinese Medicine, No. 39 Shierqiao Road, Chengdu 610072, Sichuan Province, China. [zlb31928856@163.com](mailto:zlb31928856@163.com)

### Abstract

#### BACKGROUND

Madelung's disease (MD) is a rare disorder of lipid metabolism, characterized by the growth of unencapsulated masses of adipose tissue symmetrically deposited around the neck, shoulders, or other sites around the body. Its pathological mechanism is not yet known. One of the most common comorbidities in MD patients is liver disease, especially chronic alcoholic liver disease (CALD); however, no reports exist of acute kidney injury (AKI) with MD.

#### CASE SUMMARY

We report a 60-year-old man who presented with complaint of edema in the lower limbs that had persisted for 3 d. Physical examination showed subcutaneous masses around the neck, and history-taking revealed the masses to have been present for 2 years and long-term heavy drinking. Considering the clinical symptoms, along with various laboratory test results and imaging characteristics, a diagnosis was made of MD with acute exacerbation of CALD and AKI. The patient was treated with liver function protection and traditional Chinese medicine, without surgical intervention. He was advised to quit drinking. After 10 d, the edema had subsided, renal function indicators returned to normal, liver function significantly improved, and size of subcutaneous masses remained stable.

#### CONCLUSION

In MD, concomitant liver or kidney complications are possible and monitoring of liver and kidney functions can be beneficial.

**Key Words:** Madelung's disease; Multiple symmetric lipomatosis; Drinking; Alcoholic



accompanying images.

**Conflict-of-interest statement:** The authors declare that they have no conflicts of interest.

#### CARE Checklist (2016) statement:

The authors have read the CARE Checklist (2016), and the manuscript was prepared and revised according to the CARE Checklist (2016).

**Open-Access:** This article is an open-access article that was selected by an in-house editor and fully peer-reviewed by external reviewers. It is distributed in accordance with the Creative Commons Attribution NonCommercial (CC BY-NC 4.0) license, which permits others to distribute, remix, adapt, build upon this work non-commercially, and license their derivative works on different terms, provided the original work is properly cited and the use is non-commercial. See: <http://creativecommons.org/licenses/by-nc/4.0/>

**Manuscript source:** Unsolicited manuscript

**Specialty type:** Medicine, research and experimental

**Country/Territory of origin:** China

#### Peer-review report's scientific quality classification

Grade A (Excellent): 0  
Grade B (Very good): B  
Grade C (Good): C, C  
Grade D (Fair): 0  
Grade E (Poor): 0

**Received:** April 23, 2021

**Peer-review started:** April 28, 2021

**First decision:** June 6, 2021

**Revised:** June 17, 2021

**Accepted:** August 31, 2021

**Article in press:** August 31, 2021

**Published online:** September 26, 2021

**P-Reviewer:** Dumitrascu DL, Skrypnik I

**S-Editor:** Wang LL

**L-Editor:** A

**P-Editor:** Ma YJ

liver disease; Acute kidney injury; Case report

©The Author(s) 2021. Published by Baishideng Publishing Group Inc. All rights reserved.

**Core Tip:** Madelung's disease (MD) is a rare disorder of lipid metabolism, characterized by symmetrically deposited unencapsulated masses of adipose tissue. Liver disease is one of the most common comorbidities of MD, but no reports exist of comorbid kidney disease. Here, we report a male patient, 60 years of age, diagnosed as MD with acute exacerbation of chronic alcoholic liver disease and acute kidney injury. This case reminds us that in the diagnosis and treatment of MD, in addition to the known liver comorbidities, we also need to consider renal function in order to detect any concomitant kidney disease.

**Citation:** Wu L, Jiang T, Zhang Y, Tang AQ, Wu LH, Liu Y, Li MQ, Zhao LB. Madelung's disease with alcoholic liver disease and acute kidney injury: A case report. *World J Clin Cases* 2021; 9(27): 8199-8206

**URL:** <https://www.wjgnet.com/2307-8960/full/v9/i27/8199.htm>

**DOI:** <https://dx.doi.org/10.12998/wjcc.v9.i27.8199>

## INTRODUCTION

Madelung's disease (MD) - a rare benign tumor of fat tissue, and also known by the names of multiple symmetric lipomatosis, benign symmetric lipomatosis and Launois-Bensaude syndrome - was first reported by Brodie in 1846[1]. Since then, the MD cases reported show the characteristics of progressive symmetrical deposition of unencapsulated adipose tissue in the neck, upper back, shoulders, or other bodily areas. The causes of MD have not been completely investigated, but the rudimentary knowledge is that alcoholism is associated with its onset[2]. Moreover, among the multiple comorbidities of MD that have been reported, chronic alcoholic liver disease (CALD) is one of the most common types, in line with the associated alcohol abuse, but there have been no reports of MD with acute kidney injury (AKI).

Herein, we report a MD patient with CALD and AKI, to share our clinical experience of the diagnosis and treatment of this disease.

## CASE PRESENTATION

### Chief complaints

A 60-year-old man presented to the Department of Nephrology, complaining of severe edema in the lower limbs.

### History of present illness

The patient reported that his symptoms had started 3 d prior, accompanied by a decrease of 24 h urine output (estimated to about 800 mL/d). He had self-administered furosemide but achieved no relief of his symptoms, and noted that the edema was gradually increasing.

### History of past illness

The patient denied any relevant previous medical history. During the physical examination, we found a symmetrical soft mass on the neck, which produced no pain. The patient reported that the neck mass had appeared 2 years prior and had gradually increased in size over time; he stated that he had not received any particular treatment for it. However, he specified that in the past month the mass had grown in a much more significant manner than before.

### Personal and family history

The patient had a > 10-year history of severe alcoholism (about 200 mL liquor per day). He reported that in the past month his alcohol consumption had increased





significantly, due to work failures. His family history was unremarkable.

### **Physical examination**

The patient was of medium size, with body mass index of 26.22 kg/m<sup>2</sup>. Both lower extremities had moderate to severe pitting edema, with normal skin temperature and without ulcers or inflammatory exudation. The skin and mucous membranes showed no signs of jaundice or cyanosis. Rash, liver palms and spider moles were also not present. However, there were subcutaneous masses around the neck, located symmetrically; these were soft, immovable, without tenderness, and with clear boundaries (Figure 1). There were no signs of moon face, hirsutism, or purple striae. The liver and spleen were not palpated under the rib and shifting dullness was negative. The remaining physical examinations showed no obvious abnormalities.

### **Laboratory examinations**

Serum test results showed elevated liver enzymes (including aspartate aminotransferase, alanine aminotransferase, gamma-glutamyl transpeptidase, and alkaline phosphatase), decreased serum total proteins and albumin, increased blood uric acid, and markers of impaired renal function. Blood routine findings suggested moderate anemia. Tests for coagulation indices, tumor markers, immunoglobulin light chains, thyroid hormones and autoimmune antibodies revealed no abnormalities. Liver fibrosis indices showed increased levels (Table 1).

### **Imaging examinations**

Two-dimensional ultrasound examination showed chronic liver damage (Figure 2) and peritoneal effusion. Abdominal computed tomography (CT) scan also showed peritoneal effusion, and was negative for splenomegaly and portal vein expansion. The imaging findings, considered along with the patient's long-term drinking history, indicated acute exacerbation of CALD. The clinical appearance of symmetrically subcutaneous masses around the neck was compatible with the characteristics of type I MD, which was confirmed by the two dimensional ultrasound (Figure 3) and CT (Figure 4).

### **Further diagnostic work-up**

To further screen out other possible causes of liver damage, we measured viral hepatitis-related antigens and antibodies. The results showed that the patient was negative for hepatitis. The blood vessel color Doppler ultrasound results for both lower extremities were unremarkable.

---

## **MULTIDISCIPLINARY EXPERT CONSULTATION**

---

### **Yan Zhang, MD, Deputy Chief Physician, Department of Ultrasound**

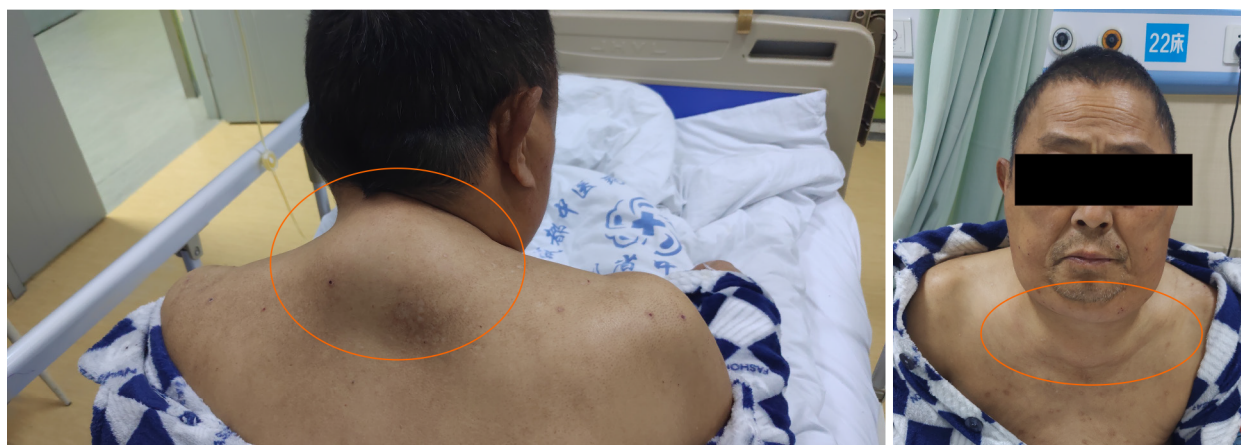According to the patient's physical examination, ultrasound and CT imaging findings, combined with the patient's history of heavy drinking, the diagnosis of MD can be supported and further pathological diagnosis should be performed. Surgery is the first treatment for MD. However, the patient has no symptoms of pressure, such as dyspnea, so surgical treatment may not be considered for the time being, and medical treatment is recommended as the main treatment. Complications will need to be actively treated to prevent other organs' damage and delay progression of the disease. Alcohol abstinence will be of great value for delaying the growth of lumps and delaying the progression of the disease.

### **Liang-Bin Zhao, MM, Attending Physician, Department of Nephrology**

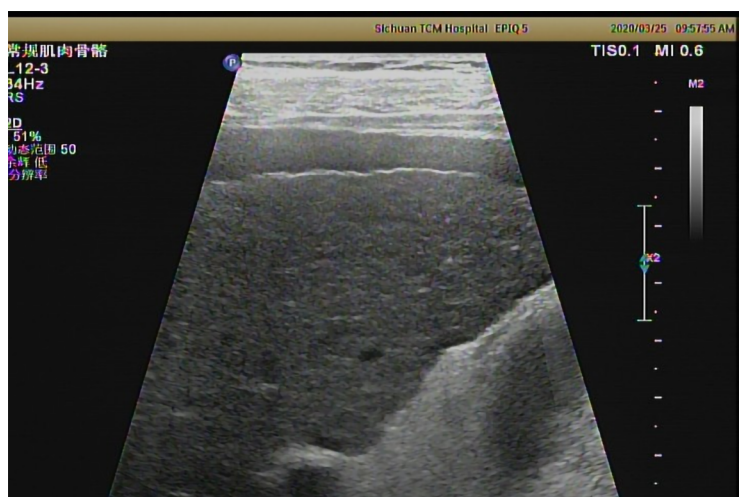
The main complaint of the patient was pitting edema affecting both lower extremities, which prompted his visit to the Department of Nephrology. After the examination, the patient was diagnosed with AKI. After inquiring about the medical history, medication history, and laboratory tests, causes of prerenal, obstructive and drug-induced injury were ruled out. We considered that it may be related to heavy drinking, metabolic disorders combined with MD, or relatively insufficient blood volume. However, there have been no reports of MD combined with AKI in general or alcohol-related AKI in particular. The patient's current kidney damage was still in the early stage, and renal function could be improved by mitigating the factors of kidney damage. No blood purification treatment was required. Therefore, alcohol abstinence was the primary recommended treatment. During that treatment process, the patient

**Table 1 Results of blood tests during hospitalization and after 10 d of treatment**

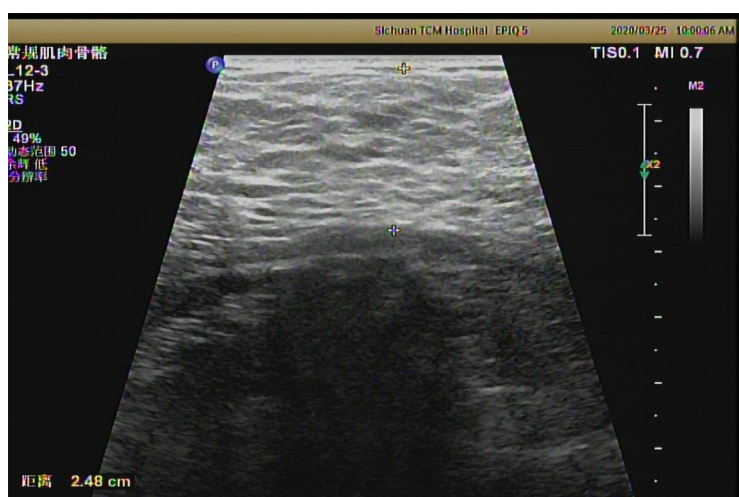
| Variable                                    | At admission             | After 10 d              | Reference range             |
|---|--------------------------|-------------------------|-----------------------------|
| Alanine aminotransferase                    | 118 U/L                  | 37 U/L                  | 9-50 U/L                    |
| Aspartate aminotransferase                  | 112 U/L                  | 43 U/L                  | 15-40 U/L                   |
| $\gamma$ -glutamyl transferase              | 1103 U/L                 | 502 U/L                 | 10-60 U/L                   |
| Alkaline phosphatase                        | 159 U/L                  | 161 U/L                 | 45-125 U/L                  |
| Total bilirubin                             | 26.2 $\mu$ mol/L         | 18.7 $\mu$ mol/L        | 5.1-28.0 $\mu$ mol/L        |
| Creatinine                                  | 133.6 $\mu$ mol/L        | 96.8 $\mu$ mol/L        | 57-111 $\mu$ mol/L          |
| Uric acid                                   | 561 $\mu$ mol/L          | 448 $\mu$ mol/L         | 202-416 $\mu$ mol/L         |
| Urea nitrogen                               | 17.99 mmol/L             | 5.52 mmol/L             | 3.6-9.5 mmol/L              |
| B-type natriuretic peptide                  | 902.3 pg/mL              | 325.6 pg/mL             | 0-125 pg/mL                 |
| Serum total protein                         | 57.9 g/L                 | 60.1 g/L                | 65-85 g/L                   |
| Albumin                                     | 34.9 g/L                 | 26.9 g/L                | 40-55 g/L                   |
| Albumin/globulin                            | 1.5                      | 1.1                     | 1.2-2.4                     |
| Leukocyte count                             | $3.29 \times 10^9$ /L    | $3.49 \times 10^9$ /L   | $3.5-9.5 \times 10^9$ /L    |
| Erythrocyte count                           | $2.38 \times 10^{12}$ /L | $2.4 \times 10^{12}$ /L | $4.3-5.8 \times 10^{12}$ /L |
| Platelet count                              | $72 \times 10^9$ /L      | $84 \times 10^9$ /L     | $100-300 \times 10^9$ /L    |
| Hemoglobin                                  | 80 g/L                   | 78 g/L                  | 130-175 g/L                 |
| Reticulocyte percentage (%)                 | 6.2                      | 4.7                     | 0.5-1.5                     |
| Liver fibrosis indicators                   |                          |                         |                             |
| Serum hyaluronic acid                       | 473.3 ng/mL              | -                       | 0-100 ng/mL                 |
| Laminin                                     | 70.91 ng/mL              | -                       | 0.51-50 ng/mL               |
| Collagen IV                                 | 39.4 mg/mL               | -                       | 0.021-30 mg/mL              |
| Cholyglycine                                | 13.98 mg/mL              | -                       | 0-2.7 mg/mL                 |
| Amino terminal procollagen type III peptide | 34.63 ng/mL              |                         | 0.021-30 ng/mL              |

**Figure 1 The patient at presentation.** Symmetrical lumps were obvious around the neck, featuring normal skin color and no ulceration or exudation.

must be closely monitored for changes in urine output, body weight and renal function indicators, and the treatment plan must be adjusted in a timely manner.



**Figure 2** Ultrasound image of the patient's liver. Chronic liver damage is seen.



**Figure 3** Ultrasound image of a neck mass in the patient. The subcutaneous fatty masses are seen in the cervical-supraclavicular and occipital regions, being significantly enhanced on both sides, with the thickness of 2.48 cm and unclear borders.

## FINAL DIAGNOSIS

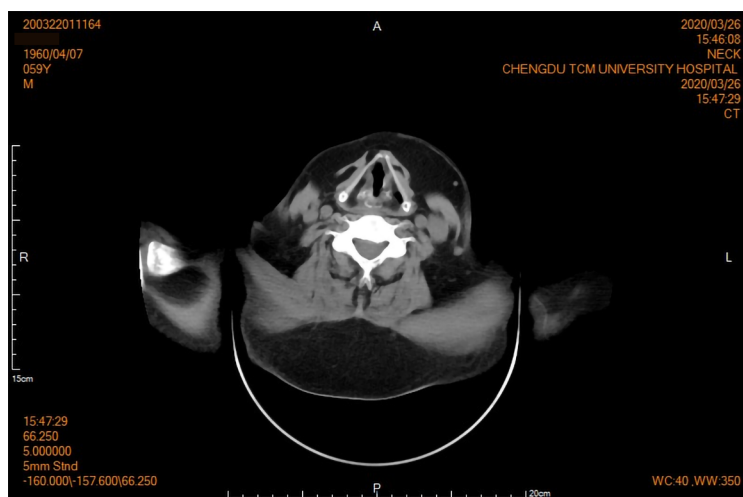
MD with acute exacerbation of CALD and AKI, and moderate anemia

## TREATMENT

As the patient had no dyspnea, dysphagia or neck movement disorders, surgical treatment and subsequent pathological diagnosis were deemed unnecessary. The patient was treated using a combination strategy of liver function protection (reduced glutathione, compound diisopropylamine dichloroacetate injection, and bicyclol tablets) and traditional Chinese medicine, and was advised to stop drinking.

## OUTCOME AND FOLLOW-UP

After 10 d, the patient's edema had subsided, his liver function had significantly improved, and his levels of renal function indices had returned to normal (Table 1). His subcutaneous masses had remained the same in size. He was continued on medications for alcohol withdrawal and liver function protection.



**Figure 4** Computed tomography image showing the subcutaneous fat layer around the neck (including the submandibular region) to be significantly thickened and symmetrically distributed on both sides. Morphology of the oropharynx and laryngo-pharynx was normal. No obvious stenosis was observed.

## DISCUSSION

MD is a rare disorder of lipid metabolism, featuring abnormal accumulation of adipose tissue. Among Italians, the incidence rate is 1/25000, having a higher prevalence in the Mediterranean region; it is less widespread in Asia[3]. In general, the disease is more common among middle-aged adults (30-60-years-old), affecting males with a history of chronic alcoholism especially, who account for more than 80% of the patients[4]. The patient presented herein was a 60-year-old male with a > 10-year history of alcoholism (approximately 200 mL liquor per day).

The diagnosis of MD is based on clinical history, physical signs, and findings from routine physical and imaging examinations; biopsy can be helpful for further differential diagnosis. The main signs of this disease are progressive, symmetrical and painless subcutaneous fatty masses. According to the clinical manifestations and the distribution of fatty masses, MD can be divided into two types[5]. Type I occurs mainly in males and is characterized by fat deposition in the upper body, including the parotid glands (the “hamster cheeks”), cervical region (the “horse collar”), posterior neck (the “buffalo hump”), submental region (the “Madelung collar”), shoulders, and proximal upper limbs. Type II shows no sex-specific prevalence and is characterized by diffuse fat deposits in the abdomen and thighs, giving patients the appearance of simple obesity. In addition, fat deposits may also occur in rare parts, such as breasts [6], tongue[7], and scrotum[8]. The fat tissue of the patient described herein was mainly deposited around the neck, supporting the diagnosis of type I MD.

The fatty masses of either type of MD are non-encapsulated and can eventually reach a very large size. If the fat deposits compress or infiltrate important blood vessels, nerves, throat, trachea and bronchi, it can cause a series of symptoms, consisting of mediastinal syndrome, tracheobronchial obstruction, dysphagia, dysphonia, hoarseness, or limitations of neck mobility[9]. The appearance of these symptoms is often what prompts patients to visit a hospital or undergo surgical treatment. The present patient did not experience symptoms of compression or infiltration, so he did not require surgery.

MD patients have multiple comorbidities, encompassing metabolic disorders, hyperlipidemia, hypertension, hyperuricemia, hypothyroidism, diabetes mellitus, *etc.* The present case was diagnosed with hypertension and hyperuricemia, without diabetes, hyperlipidemia or abnormalities in thyroid function.

Considering the long-term history of alcoholism, significant changes in liver enzymes and imaging findings for the present case, the diagnosis of MD with acute exacerbation of CALD was confirmed. MD is more prevalent in patients with long-term alcohol abuse, and the resultant alcoholic liver injury can cause other liver diseases subsequently. Ballestri *et al*[10] proposed the neck-liver axis concept, pointing out that fat accumulation in the neck-dorsocervical area is a risk factor for liver inflammation and fibrosis. Vassallo *et al*[11] reported a male case of MD that was complicated with acute alcoholic hepatitis; the patient had presented with jaundice, ascites, breast enlargement and hepatosplenomegaly. Gao *et al*[12] reported a male case of MD



complicated with chronic alcoholic cirrhosis, and Iglesias *et al*[13] reported a 50-year-old male patient diagnosed with MD and alcoholic liver disease, who presented with edema, ascites and significant hepatosplenomegaly. In addition to these complications, alcoholic fatty liver[14] and hepatocellular carcinoma[15] have also been reported in MD patients. A survey involving 59 patients with MD found that 25% of patients had liver disease complications[4]. These cases should serve to remind us to put in extra efforts in the detection of liver function in patients with MD.

In addition, our patient was also diagnosed with AKI. To our knowledge, there are no reports of a similar kidney-related comorbidity in the literature to date. After searching for relevant information, our team considered that the patient's AKI may be related to the following three aspects: (1) Intake of a large amount of alcohol has the potential to damage the kidneys; (2) The metabolic disorder associated with MD may cause a decline in renal function; and (3) Severe edema can lead to insufficient (ineffective) blood circulation, causing prerenal AKI. However, whether there is an inevitable connection between kidney disease and MD and alcoholism needs to be confirmed by an observational study of adequately-powered clinical data.

The pathogenesis of MD remains unknown. Currently, a major hypothesis holds that the tumor-like proliferation of brown adipose tissue is the basic mechanism of MD onset[9], which is related to the reduction of lipolysis induced by decreases in the number or activity of  $\beta$ -adrenergic receptors. In addition, mitochondrial dysfunction [16] (*e.g.*, loss of the respiratory chain and decreased cytochrome C oxidase activity) and gene mutations in mitochondrial DNA (*e.g.*, MTTK c.8334A>G mutation)[17] also contribute to the occurrence and development of MD. Although accurate causes are unknown, alcoholism is a definite contributor to the progression of MD, which can cause mitochondrial dysfunction or DNA mutations, and can interfere with the adrenergic system, thereby reducing lipolysis and promoting fat deposition[18].

MD is a benign disease and surgical therapy, including lipectomy and liposuction, is the main and currently only effective treatment. However, recurrence after surgery is another concern, with an average rate of 39% in surgically-treated patients; moreover, the recurrence rate is higher among those treated with liposuction than those treated with lipectomy[4]. Other therapies, such as local injection of lipolytic drugs and oral  $\beta$ -adrenergic receptor agonists (salbutamol)[19], have been applied and investigated, but the clinical efficacy remains unclear, due to lack of large-scale clinical trials. Considering the relationship between MD and alcoholism, alcohol cessation is considered as a robust treatment method. Regardless of the fact that alcohol cessation cannot reverse the progression of MD, it truly can help to reduce the recurrence after surgery and the deposition of fatty tissue[2]. We did not conduct a surgical treatment on our patient, as he was asymptomatic. He was prescribed alcohol cessation, along with liver protective drugs and traditional Chinese medicine. To a certain extent, this case shows that traditional Chinese medicine has a positive role in the treatment, but more clinical trials are needed to confirm such.

## CONCLUSION

In summary, with regard to diagnosis and treatment of MD, clinicians must intensively monitor liver function indicators, and distinguish viral hepatitis from other liver diseases when patients have liver function damage and an absolute diagnosis has not yet been made; this is necessary to improve the accuracy of diagnosis, formulate a comprehensive treatment plan, and maximize therapeutic effect. Finally, to verify whether there is an inevitable connection between AKI and MD, more clinical observations are needed.

## ACKNOWLEDGEMENTS

The authors are grateful to the patient for allowing publication of his case details.

## REFERENCES

- 1 Brodie BC. Clinical Lectures on Surgery. Delivered at St. George's Hospital. *Am J Med Sci* 1846; 11: 437 [DOI: [10.1097/00000441-184604000-00028](https://doi.org/10.1097/00000441-184604000-00028)]
- 2 Gao Y, Hu JL, Zhang XX, Zhang MS, Lu Y. Madelung's Disease: Is Insobriety the Chief Cause?

- Aesthetic Plast Surg* 2017; **41**: 1208-1216 [PMID: [28791470](#) DOI: [10.1007/s00266-017-0920-1](#)]
- 3 **Enzi G**, Biondetti PR, Fiore D, Mazzoleni F. Computed tomography of deep fat masses in multiple symmetrical lipomatosis. *Radiology* 1982; **144**: 121-124 [PMID: [7089242](#) DOI: [10.1148/radiology.144.1.7089242](#)]
- 4 **Pinto CI**, Carvalho PJ, Correia MM. Madelung's Disease: Revision of 59 Surgical Cases. *Aesthetic Plast Surg* 2017; **41**: 359-368 [PMID: [28032179](#) DOI: [10.1007/s00266-016-0759-x](#)]
- 5 **Enzi G**. Multiple symmetric lipomatosis: an updated clinical report. *Medicine (Baltimore)* 1984; **63**: 56-64 [PMID: [6318013](#) DOI: [10.1097/00005792-198401000-00004](#)]
- 6 **Jang JH**, Lee A, Han SA, Ryu JK, Song JY. Multiple Symmetric Lipomatosis (Madelung's Disease) Presenting as Bilateral Huge Gynecomastia. *J Breast Cancer* 2014; **17**: 397-400 [PMID: [25548590](#) DOI: [10.4048/jbc.2014.17.4.397](#)]
- 7 **Kang JW**, Kim JH. Images in clinical medicine. Symmetric lipomatosis of the tongue. *N Engl J Med* 2013; **369**: e5 [PMID: [23883389](#) DOI: [10.1056/NEJMim1303413](#)]
- 8 **da Costa JN**, Gomes T, Matias J. Madelung Disease Affecting Scrotal Region. *Ann Plast Surg* 2017; **78**: 73-77 [PMID: [26835830](#) DOI: [10.1097/SAP.0000000000000714](#)]
- 9 **Enzi G**, Busetto L, Sergi G, Coin A, Inelmen EM, Vindigni V, Bassetto F, Cinti S. Multiple symmetric lipomatosis: a rare disease and its possible links to brown adipose tissue. *Nutr Metab Cardiovasc Dis* 2015; **25**: 347-353 [PMID: [25770761](#) DOI: [10.1016/j.numecd.2015.01.010](#)]
- 10 **Ballestri S**, Lonardo A, Carulli L, Ricchi M, Bertozzi L, De Santis G, Bondi M, Loria P. The neck-liver axis. Madelung disease as further evidence for an impact of body fat distribution on hepatic histology. *Hepatology* 2008; **47**: 361-362 [PMID: [18161705](#) DOI: [10.1002/hep.21977](#)]
- 11 **Vassallo GA**, Mirijello A, Tarli C, Rando MM, Antonelli M, Garcovich M, Zocco MA, Sestito L, Mosoni C, Dionisi T, D'Addio S, Tosoni A, Gasbarrini A, Addolorato G. Madelung's disease and acute alcoholic hepatitis: case report and review of literature. *Eur Rev Med Pharmacol Sci* 2019; **23**: 6272-6276 [PMID: [31364130](#) DOI: [10.26355/eurrev\\_201907\\_18448](#)]
- 12 **Gao H**, Xin ZY, Yin X, Zhang Y, Jin QL, Wen XY. Madelung disease: A case report. *Medicine (Baltimore)* 2019; **98**: e14116 [PMID: [30653136](#) DOI: [10.1097/MD.00000000000014116](#)]
- 13 **Iglesias L**, Pérez-Llantada E, Saro G, Pino M, Hernández JL. Benign symmetric lipomatosis (Madelung's disease). *Eur J Intern Med* 2000; **11**: 171-173 [PMID: [10854826](#) DOI: [10.1016/s0953-6205\(00\)00086-8](#)]
- 14 **Karashima S**, Yoneda T. Madelung disease in a 58-year-old man. *CMAJ* 2019; **191**: E48 [PMID: [30642826](#) DOI: [10.1503/cmaj.180759](#)]
- 15 **Casas Deza D**, Gotor Delso J, Bernal Monterde V. Madelung's disease in a patient with advanced hepatocellular carcinoma. *Gastroenterol Hepatol* 2018; **41**: 645-647 [PMID: [29759923](#) DOI: [10.1016/j.gastrohep.2017.12.008](#)]
- 16 **Ko MJ**, Chiu HC. Madelung's disease and alcoholic liver disorder. *Hepatology* 2010; **51**: 1466-1467 [PMID: [20162622](#) DOI: [10.1002/hep.23480](#)]
- 17 **Perera U**, Kennedy BA, Hegele RA. Multiple Symmetric Lipomatosis (Madelung Disease) in a Large Canadian Family With the Mitochondrial *MTTK* c.8344A>G Variant. *J Investig Med High Impact Case Rep* 2018; **6**: 2324709618802867 [PMID: [30283804](#) DOI: [10.1177/2324709618802867](#)]
- 18 **Calarco R**, Rapaccini G, Miele L. Fat Deposits as Manifestation of Alcohol Use Disorder: Madelung's Disease. *Clin Gastroenterol Hepatol* 2019; **17**: A26 [PMID: [29705259](#) DOI: [10.1016/j.cgh.2018.04.044](#)]
- 19 **Leung NW**, Gaer J, Beggs D, Kark AE, Holloway B, Peters TJ. Multiple symmetric lipomatosis (Launois-Bensaude syndrome): effect of oral salbutamol. *Clin Endocrinol (Oxf)* 1987; **27**: 601-606 [PMID: [2897261](#) DOI: [10.1111/j.1365-2265.1987.tb01190.x](#)]



Published by **Baishideng Publishing Group Inc**  
7041 Koll Center Parkway, Suite 160, Pleasanton, CA 94566, USA

**Telephone:** +1-925-3991568

**E-mail:** [bpgoffice@wjgnet.com](mailto:bpgoffice@wjgnet.com)

**Help Desk:** <https://www.f6publishing.com/helpdesk>

<https://www.wjgnet.com>

