

World Journal of *Clinical Cases*

World J Clin Cases 2021 September 26; 9(27): 7963-8279



Contents

Thrice Monthly Volume 9 Number 27 September 26, 2021

EDITORIAL

7963 *Exophiala dermatitidis*

Usuda D, Higashikawa T, Hotchi Y, Usami K, Shimozaawa S, Tokunaga S, Osugi I, Katou R, Ito S, Yoshizawa T, Asako S, Mishima K, Kondo A, Mizuno K, Takami H, Komatsu T, Oba J, Nomura T, Sugita M

REVIEW

7973 Gastric neuroendocrine neoplasms: A review

Köseoglu H, Duzenli T, Sezikli M

MINIREVIEWS

7986 Coronavirus disease 2019 and renal transplantation

Nassar M, Nso N, Ariyaratnam J, Sandhu J, Mohamed M, Baraka B, Ibrahim A, Alfshawy M, Zheng D, Bhangoo H, Soliman KM, Li M, Rizzo V, Daoud A

7998 Impact of COVID-19 on liver

Su YJ, Chang CW, Chen MJ, Lai YC

ORIGINAL ARTICLE

Case Control Study

8008 Association of gestational anemia with pregnancy conditions and outcomes: A nested case-control study

Sun Y, Shen ZZ, Huang FL, Jiang Y, Wang YW, Zhang SH, Ma S, Liu JT, Zhan YL, Lin H, Chen YL, Shi YJ, Ma LK

Retrospective Cohort Study

8020 Clinical stages of recurrent hepatocellular carcinoma: A retrospective cohort study

Yao SY, Liang B, Chen YY, Tang YT, Dong XF, Liu TQ

Retrospective Study

8027 Accuracy of ultrasonography in diagnosis of fetal central nervous system malformation

Pang B, Pan JJ, Li Q, Zhang X

8035 Analysis of ocular structural parameters and higher-order aberrations in Chinese children with myopia

Li X, Hu Q, Wang QR, Feng ZQ, Yang F, Du CY

8044 Radial nerve recovery following closed nailing of humeral shaft fractures without radial nerve exploration: A retrospective study

Yeh KL, Liaw CK, Wu TY, Chen CP

8051 Bridging therapy and direct mechanical thrombectomy in the treatment of cardiogenic cerebral infarction with anterior circulation macrovascular occlusion

Ding HJ, Ma C, Ye FP, Zhang JF

- 8061** Endu combined with concurrent chemotherapy and radiotherapy for stage IIB-IVA cervical squamous cell carcinoma patients

Zhao FJ, Su Q, Zhang W, Yang WC, Zhao L, Gao LY

CASE REPORT

- 8071** Primary pancreatic paraganglioma harboring lymph node metastasis: A case report

Jiang CN, Cheng X, Shan J, Yang M, Xiao YQ

- 8082** Retraction of lumbar disc herniation achieved by noninvasive techniques: A case report

Wang P, Chen C, Zhang QH, Sun GD, Wang CA, Li W

- 8090** Mixed neuroendocrine carcinoma of the gastric stump: A case report

Zhu H, Zhang MY, Sun WL, Chen G

- 8097** Diploic vein as a newly treatable cause of pulsatile tinnitus: A case report

Zhao PF, Zeng R, Qiu XY, Ding HY, Lv H, Li XS, Wang GP, Li D, Gong SS, Wang ZC

- 8104** Acute myocardial infarction and extensive systemic thrombosis in thrombotic thrombocytopenic purpura: A case report and review of literature

Şalaru DL, Adam CA, Marcu DTM, Şimon IV, Macovei L, Ambrosie L, Chirita E, Sascau RA, Statescu C

- 8114** Limited thoracoplasty and free musculocutaneous flap transposition for postpneumonectomy empyema: A case report

Huang QQ, He ZL, Wu YY, Liu ZJ

- 8120** Paraneoplastic focal segmental glomerulosclerosis associated with gastrointestinal stromal tumor with cutaneous metastasis: A case report

Zhou J, Yang Z, Yang CS, Lin H

- 8127** Acute coronary syndrome with severe atherosclerotic and hyperthyroidism: A case report

Zhu HM, Zhang Y, Tang Y, Yuan H, Li ZX, Long Y

- 8135** Gastric cancer with calcifications: A case report

Lin YH, Yao W, Fei Q, Wang Y

- 8142** Value of eosinophil count in bronchoalveolar lavage fluid for diagnosis of allergic bronchopulmonary aspergillosis: A case report

Wang WY, Wan SH, Zheng YL, Zhou LM, Zhang H, Jiang LB

- 8147** Asymptomatic gastric adenomyoma and heterotopic pancreas in a patient with pancreatic cancer: A case report and review of the literature

Li K, Xu Y, Liu NB, Shi BM

- 8157** Successful treatment of gastrointestinal infection-induced septic shock using the oXiris® hemofilter: A case report

Li Y, Ji XJ, Jing DY, Huang ZH, Duan ML

- 8164** Streptococcal pneumonia-associated hemolytic uremic syndrome treated by T-antibody-negative plasma exchange in children: Two case reports
Wang XL, Du Y, Zhao CG, Wu YB, Yang N, Pei L, Wang LJ, Wang QS
- 8171** Subclavian steal syndrome associated with Sjogren's syndrome: A case report
Hao LJ, Zhang J, Naveed M, Chen KY, Xiao PX
- 8177** Metachronous mixed cellularity classical Hodgkin's lymphoma and T-cell leukemia/lymphoma: A case report
Dong Y, Deng LJ, Li MM
- 8186** Duodenal perforation after organophosphorus poisoning: A case report
Lu YL, Hu J, Zhang LY, Cen XY, Yang DH, Yu AY
- 8192** Surgical treatment of abnormal systemic artery to the left lower lobe: A case report
Zhang YY, Gu XY, Li JL, Liu Z, Lv GY
- 8199** Madelung's disease with alcoholic liver disease and acute kidney injury: A case report
Wu L, Jiang T, Zhang Y, Tang AQ, Wu LH, Liu Y, Li MQ, Zhao LB
- 8207** Anesthetic technique for awake artery malformation clipping with motor evoked potential and somatosensory evoked potential: A case report
Zhou HY, Chen HY, Li Y
- 8214** Multiple hidden vessels in walled-off necrosis with high-risk bleeding: Report of two cases
Xu N, Zhai YQ, Li LS, Chai NL
- 8220** Non-small-cell lung cancer with epidermal growth factor receptor L861Q-L833F compound mutation benefits from both afatinib and osimertinib: A case report
Zhang Y, Shen JQ, Shao L, Chen Y, Lei L, Wang JL
- 8226** Successful removal of two magnets in the small intestine by laparoscopy and colonoscopy: A case report
Oh RG, Lee CG, Park YN, Lee YM
- 8232** Acute lower extremity arterial thrombosis after intraocular foreign body removal under general anesthesia: A case report and review of literature
Jeon S, Hong JM, Lee HJ, Kim E, Lee H, Kim Y, Ri HS, Lee JJ
- 8242** Low-intensity extracorporeal shock wave therapy for midshaft clavicular delayed union: A case report and review of literature
Yue L, Chen H, Feng TH, Wang R, Sun HL
- 8249** Treatment of bilateral granulomatous lobular mastitis during lactation with traditional Chinese medicine: A case report
Li ZY, Sun XM, Li JW, Liu XF, Sun ZY, Chen HH, Dong YL, Sun XH
- 8260** Early acute fat embolism syndrome caused by femoral fracture: A case report
Yang J, Cui ZN, Dong JN, Lin WB, Jin JT, Tang XJ, Guo XB, Cui SB, Sun M, Ji CC

- 8268** Combined fascia iliaca compartment block and monitored anesthesia care for geriatric patients with hip fracture: Two case reports
Zhan L, Zhang YJ, Wang JX
- 8274** Bell's palsy after inactivated COVID-19 vaccination in a patient with history of recurrent Bell's palsy: A case report
Yu BY, Cen LS, Chen T, Yang TH

ABOUT COVER

Editorial Board Member of *World Journal of Clinical Cases*, Sunil Kumar Gupta, MBBS, MD, Reader (Associate Professor), Department of Dermatology, Venereology and Leprology, All India Institute of Medical Sciences, Gorakhpur, Gorakhpur 273008, Uttar Pradesh, India. dr.sunil_30@yahoo.co.in

AIMS AND SCOPE

The primary aim of *World Journal of Clinical Cases* (WJCC, *World J Clin Cases*) is to provide scholars and readers from various fields of clinical medicine with a platform to publish high-quality clinical research articles and communicate their research findings online.

WJCC mainly publishes articles reporting research results and findings obtained in the field of clinical medicine and covering a wide range of topics, including case control studies, retrospective cohort studies, retrospective studies, clinical trials studies, observational studies, prospective studies, randomized controlled trials, randomized clinical trials, systematic reviews, meta-analysis, and case reports.

INDEXING/ABSTRACTING

The WJCC is now indexed in Science Citation Index Expanded (also known as SciSearch®), Journal Citation Reports/Science Edition, Scopus, PubMed, and PubMed Central. The 2021 Edition of Journal Citation Reports® cites the 2020 impact factor (IF) for WJCC as 1.337; IF without journal self cites: 1.301; 5-year IF: 1.742; Journal Citation Indicator: 0.33; Ranking: 119 among 169 journals in medicine, general and internal; and Quartile category: Q3. The WJCC's CiteScore for 2020 is 0.8 and Scopus CiteScore rank 2020: General Medicine is 493/793.

RESPONSIBLE EDITORS FOR THIS ISSUE

Production Editor: Ji-Hong Lin; Production Department Director: Xiang Li; Editorial Office Director: Jin-Lai Wang.

NAME OF JOURNAL

World Journal of Clinical Cases

ISSN

ISSN 2307-8960 (online)

LAUNCH DATE

April 16, 2013

FREQUENCY

Thrice Monthly

EDITORS-IN-CHIEF

Dennis A Bloomfield, Sandro Vento, Bao-Gan Peng

EDITORIAL BOARD MEMBERS

<https://www.wjgnet.com/2307-8960/editorialboard.htm>

PUBLICATION DATE

September 26, 2021

COPYRIGHT

© 2021 Baishideng Publishing Group Inc

INSTRUCTIONS TO AUTHORS

<https://www.wjgnet.com/bpg/gerinfo/204>

GUIDELINES FOR ETHICS DOCUMENTS

<https://www.wjgnet.com/bpg/gerinfo/287>

GUIDELINES FOR NON-NATIVE SPEAKERS OF ENGLISH

<https://www.wjgnet.com/bpg/gerinfo/240>

PUBLICATION ETHICS

<https://www.wjgnet.com/bpg/gerinfo/288>

PUBLICATION MISCONDUCT

<https://www.wjgnet.com/bpg/gerinfo/208>

ARTICLE PROCESSING CHARGE

<https://www.wjgnet.com/bpg/gerinfo/242>

STEPS FOR SUBMITTING MANUSCRIPTS

<https://www.wjgnet.com/bpg/gerinfo/239>

ONLINE SUBMISSION

<https://www.f6publishing.com>



Anesthetic technique for awake artery malformation clipping with motor evoked potential and somatosensory evoked potential: A case report

Hong-Yu Zhou, Hong-Yang Chen, Yu Li

ORCID number: Hong-Yu Zhou 0000-0001-6838-4141; Hong-Yang Chen 0000-0001-5452-8116; Yu Li 0000-0002-3548-4901.

Author contributions: Zhou HY and Chen HY reviewed the literature and contributed to manuscript drafting; Chen HY took responsibility for image and data curation; Li Y contributed to revise the manuscript.

Informed consent statement: Informed written consent was obtained from the patient for publication of this report and any accompanying images

Conflict-of-interest statement: All authors declare that they have no conflicts of interest to disclose.

CARE Checklist (2016) statement: The authors have read the CARE Checklist (2016), and the manuscript was prepared and revised according to the CARE Checklist (2016).

Open-Access: This article is an open-access article that was selected by an in-house editor and fully peer-reviewed by external reviewers. It is distributed in accordance with the Creative Commons Attribution NonCommercial (CC BY-NC 4.0)

Hong-Yu Zhou, Hong-Yang Chen, Yu Li, Department of Anesthesiology, West China Hospital, Chengdu 610041, Sichuan Province, China

Corresponding author: Yu Li, MSc, Chief Physician, Department of Anesthesiology, West China Hospital, No. 37 Guoxue Lane, Wuhou District, Chengdu 610041, Sichuan Province, China. biaojieli@163.com

Abstract

BACKGROUND

Awake craniotomy has been widely used for tumor resection, epilepsy surgery, deep brain stimulation, and carotid endarterectomy. The report on awake artery malformation clipping is rare, especially for anesthesia management.

CASE SUMMARY

A 62-year-old female diagnosed with malformation of anterior cerebral artery at the right side. We clipped the artery malformation with intraoperative neuromonitoring (IONM) in awake craniotomy. Spontaneous respiration was maintained throughout the procedure by nasopharyngeal airway during the surgery successfully.

CONCLUSION

The technique of monitoring anesthesia care can be performed successfully for the patient with IONM.

Key Words: Artery malformation; Awake craniotomy; Intraoperative neuromonitoring; Nasopharyngeal airway; Case report

©The Author(s) 2021. Published by Baishideng Publishing Group Inc. All rights reserved.

Core Tip: In this case, due to the patient's strong request for the integrity of motor function, the neurosurgeon explained the advantages and disadvantages of different surgery plans to her. This patient chose the awake craniotomy finally. Awake craniotomy was performed successfully in fully cooperative patient with stable neurological

license, which permits others to distribute, remix, adapt, build upon this work non-commercially, and license their derivative works on different terms, provided the original work is properly cited and the use is non-commercial. See: <http://creativecommons.org/licenses/by-nc/4.0/>

Manuscript source: Unsolicited manuscript

Specialty type: Medicine, research and experimental

Country/Territory of origin: China

Peer-review report's scientific quality classification

Grade A (Excellent): 0
Grade B (Very good): B
Grade C (Good): C
Grade D (Fair): 0
Grade E (Poor): 0

Received: April 19, 2021

Peer-review started: April 19, 2021

First decision: June 23, 2021

Revised: July 9, 2021

Accepted: August 6, 2021

Article in press: August 6, 2021

Published online: September 26, 2021

P-Reviewer: Chrastina J

S-Editor: Fan JR

L-Editor: A

P-Editor: Yuan YY



status.

Citation: Zhou HY, Chen HY, Li Y. Anesthetic technique for awake artery malformation clipping with motor evoked potential and somatosensory evoked potential: A case report. *World J Clin Cases* 2021; 9(27): 8207-8213

URL: <https://www.wjgnet.com/2307-8960/full/v9/i27/8207.htm>

DOI: <https://dx.doi.org/10.12998/wjcc.v9.i27.8207>

INTRODUCTION

Awake craniotomy aims to minimize the risk of postoperative neurologic deficits. Over the last decades, awake craniotomy has been widely used for epilepsy lesions, glioma near the functional procedure. Awake brain mapping may facilitate resection with the preservation of functions such as speech and memory, that cannot be monitored in asleep patients. Few cases of awake craniotomy for intracranial artery malformation were reported. Awake craniotomy along with intraoperative neuromonitoring improve the treatment for artery malformation clipping. We present a case of awake artery malformation clipping with motor evoked potential (MEP) and somatosensory evoked potential (SSEP).

CASE PRESENTATION

Chief complaints

A 62-year-old female was treated in our hospital with malformation of an anterior cerebral artery at the right side.

History of present illness

The malformation of the right anterior cerebral artery was found by medical examination due to the patient complaining of numbness in the left upper limb and headache occasionally after being hit by a heavy object accidentally 8-mo ago.

History of past illness

The patient had no past history.

Personal and family history

The patient had no personal or family history.

Physical examination

The physical examination of the patient was normal.

Laboratory examinations

Preoperative blood biochemistry, electrocardiogram, chest X-ray were normal.

Imaging examinations

The brain computed tomography (CT) shows multiple nodular and stripy high-density shadows in the right frontal lobe and anterior cerebral falx. The magnetic resonance imaging (MRI) revealed A3 and A4 segment malformation of the right anterior cerebral artery before admission (Figure 1A and B). After the patient was admitted to the hospital, the patient was diagnosed with right anterior cerebral artery malformation by digital subtraction angiography (DSA) (Figure 1C and D).

FINAL DIAGNOSIS

The definitive diagnosis of this patient was the malformation of the right anterior cerebral artery.

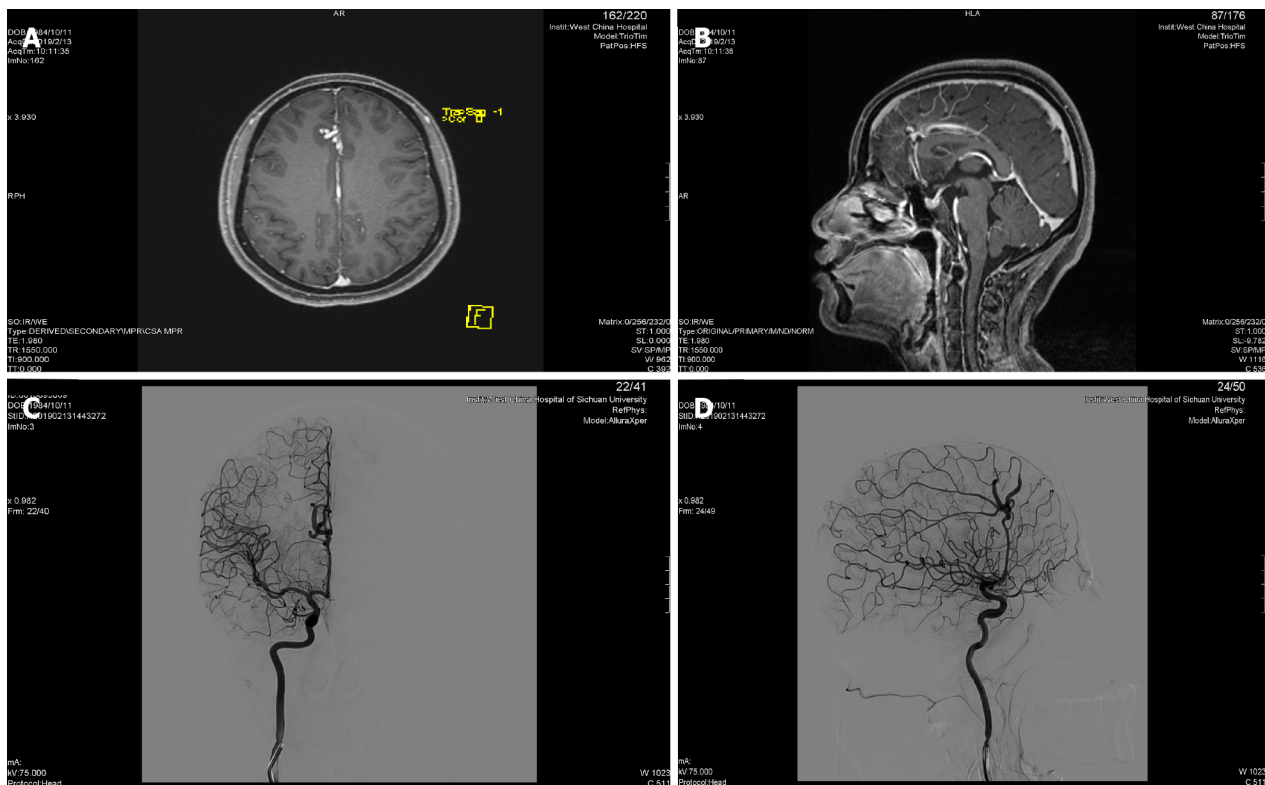


Figure 1 The preoperative magnetic resonance imaging of head showing high density shade in right front lobe and next to cerebral falx. A: The axial magnetic resonance imaging (MRI); B: The sagittal MRI. The preoperative right internal carotid artery injection angiograms showing A3 segment malformation of the right anterior cerebral artery; C: Anteroposterior projection; D: Lateral projection.

TREATMENT

In this case, due to the patient's strong request for the integrity of motor function, the neurosurgeon explained the advantages and disadvantages of different surgery plans to her. This patient chose the awake craniotomy finally. The written informed consent was obtained from the patient preoperatively. The electrocardiogram, noninvasive blood pressure, pulse oximetry, bispectral index (BIS) were monitored continuously. A Mayfield frame was used with ropivacaine prior to pin insertion. The patient was placed in a supine position comfortably.

Motor function was evaluated by the electrophysiologist preoperatively. Anesthesia was induced with propofol target controlled infusion of 2 ug/mL, remifentanyl 0.02-0.04 ug/kg/min and dexmedetomidine 0.5 ug/kg/h. After the patient's consciousness disappeared, a nasopharyngeal airway was placed to supply oxygen and monitor end-tidal carbon dioxide (Figure 2). The transcranial stimulating electrodes were placed for MEP and SSEP. Latency and amplitude of MEP and SSEP were recorded. Warning criteria for MEP and SSEP was a 10% increase in latency or a 50% decrease in amplitude as compared to baseline values.

Scalp nerve block including supraorbital nerve, auriculotemporal nerve, greater occipital nerve and lesser occipital nerve bilaterally, was performed with 0.2% ropivacaine 2 mL at each site for both perioperative anesthesia and postoperative pain. The neurosurgeon infiltrated the incision line with 0.2% ropivacaine 20 mL preoperatively.

According to various monitoring parameters, the dose was titrated to maintain BIS at 60 to 80, end-tidal carbon dioxide ($E_t\text{CO}_2$) at 35 to 50 mmol/L, respiratory rate (RR) at 10-15 beats/min, heart rate at 50-100 beats/min, and mean artery pressure at 60 to 80 mmHg. Continuous intravenous infusion with propofol 1.4-1.6 ug/kg, remifentanyl 0.02-0.04 ug/kg/min and dexmedetomidine 0.5 ug/kg/h maintained sedation during the pre-awake period. The dura mater was infiltrated with 1% lidocaine before incision.

Once the artery malformation was identified (Figure 3), all anesthetics were intermitted. After 10 min, the patient was brought into the awake stage with Observer's Assessment of Alertness/Sedation 2. The motor and language examination were normal. Then temporary occlusion clips were used to isolate the distal end of lesion

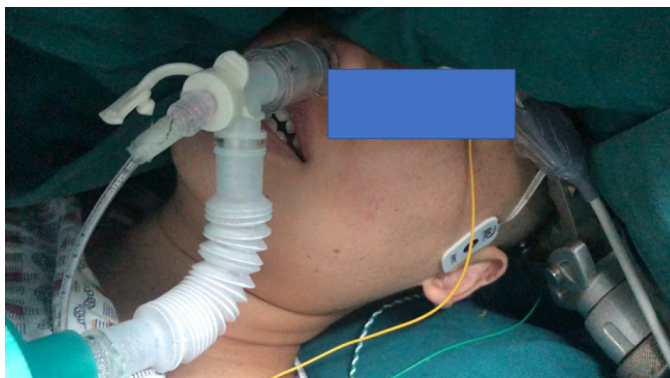

Figure 2 Intraoperative photograph showing the patient positioned in supine position with head rotated to the left. She placed a nasopharyngeal airway.

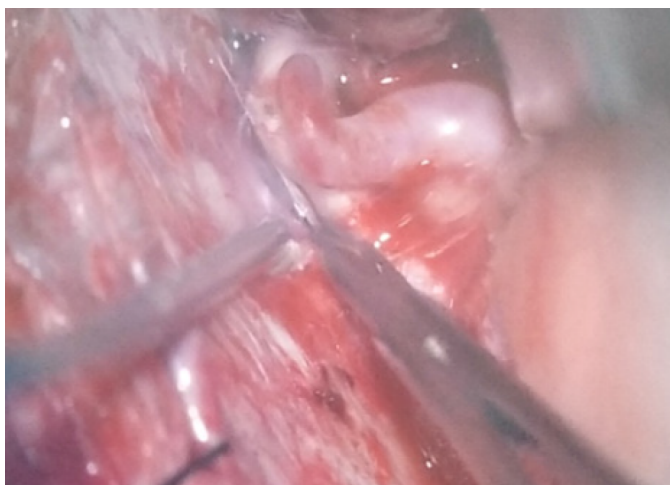


Figure 3 The intraoperative finding: The dilated and tortuous segment of the right anterior cerebral artery.

vessel one by one for clamping the supplying side of the artery. After the clipping of the artery, the patient communicated well. Intraoperative neurological assessment was done for contralateral motor functions in both upper and lower limb. The muscle strength and muscle tension of the proximal and distal lower extremities are symmetrical and normal. This patient was co-operative throughout the procedure. No neurological dysfunction was discovered for 30 min. All anesthetics were restarted. Neurophysiological monitoring showed that SSEP was normal and a slight decrease in MEP over 30 min. The indocyanine green angiography showed retrograde flow-induced fluorescein development in each corpus callosum artery branch after multiple isolated lesions. Then the temporary clamp was replaced by the final clipping, and the dilated and tortuous segments were removed. No complication occurred. The surgery lasts for 3 h.

Postoperative CT angiograph image confirmed the complete clipping of the artery malformation (Figure 4). There were no tortuous segments on DSA (Figure 5A and B), and no ischemic lesions on MRI (Figure 5C and D). The patient was treated with neurotrophic drugs postoperatively.

OUTCOME AND FOLLOW-UP

The patient was discharged without neurological deficits or other complications ten days after the surgery. The Modified Rankin Scale was 0. There was no psychological disorder for 1-year follow-up.

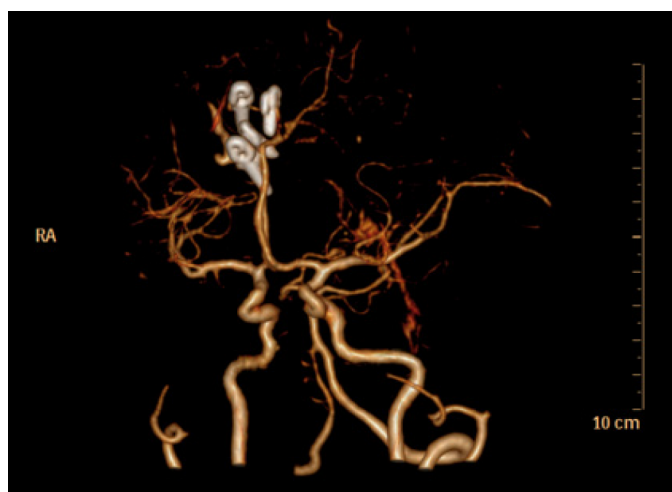


Figure 4 Postoperative computed tomography angiograph image: 3 clips used for aneurysm occlusion.

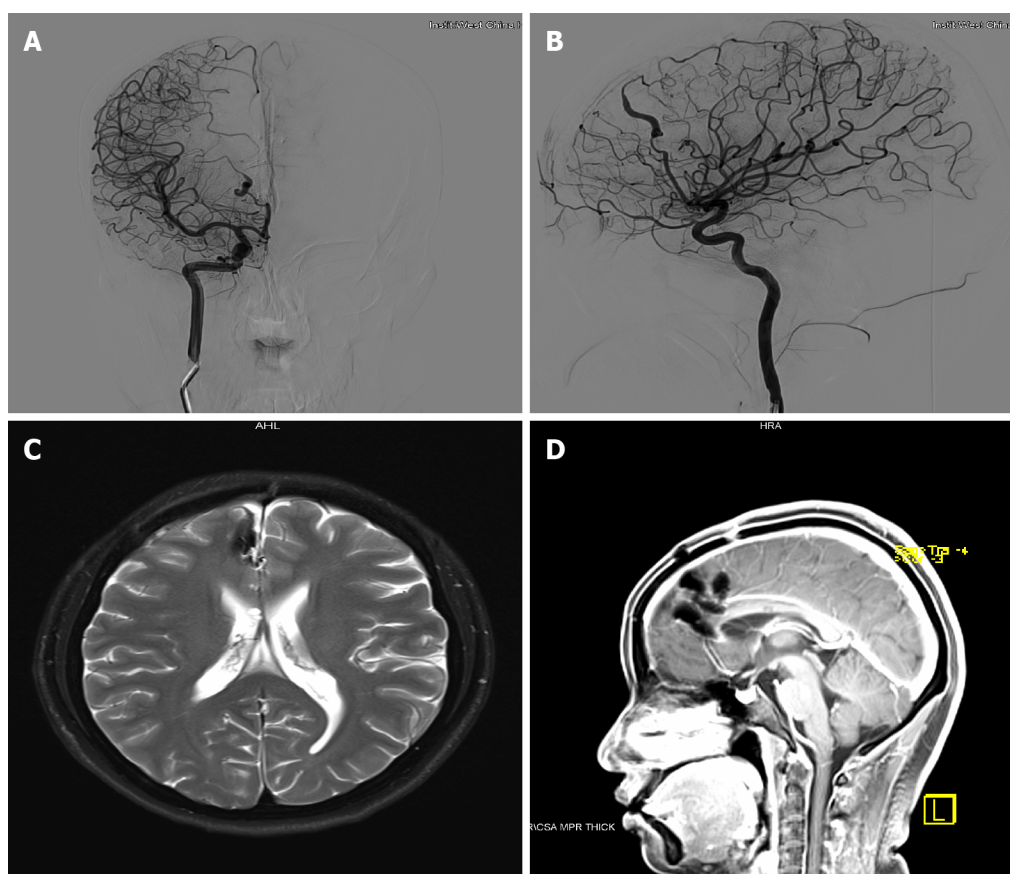


Figure 5 The postoperative right internal carotid artery injection angiograms showing no dilated and tortuous segment. A: Anteroposterior projection; B: Lateral projection. The preoperative magnetic resonance imaging (MRI) of head showing no ischemic lesions; C: The axial MRI; D: The sagittal MRI.

DISCUSSION

The incidence of pure arterial malformations is low. Pure arterial malformations have a benign natural history, and it was usually managed conservatively. Due to the rare incidence, the optimal treatment for pure arterial malformation is controversial[1]. In this case, the arterial malformation with many branches runs into the central cortex, which may affect the motor and linguistic function. Furthermore, based on the imaging data, arterial dissection can't be completely ruled out. Considering to these factors, the surgeon finally decided that awake craniotomy may be the optimal choice for this patient.

Awake craniotomy is a reliable method of ensuring neural integrity during the excision of lesions located within or near eloquent areas. Furthermore, continuous clinical neurological monitoring can detect early deficits in the motor, sensory or language domains. Our team had rich experiences with awake craniotomy for brain tumors, but this was the first awake surgery for artery malformation clipping in our institute.

Cerebral artery malformation surgery may cause motor deficits due to brain blood flow insufficiency after clipping the artery malformation. Continuous infusion of remifentanyl, dexmedetomidine and propofol has little impact on evoked potentials[2, 3]. Irie *et al*[4] reported that the limitation of this monitoring technique is the false-negative MEP; four patients had postoperative hemiparesis without intraoperative MEP changes. Once ischemia occurs, MEP maybe not sensitive to the evaluation of movement[5]. It is reported that there is a potential advantage of awake artery malformation surgery in decreasing the risk of ischemic injury[6].

Anesthetic methods in awake craniotomy include monitoring anesthesia care (MAC) and asleep-awake-asleep (SAS)[7]. Both techniques can be performed successfully in awake craniotomy. The MAC technique uses low doses of sedative agents for conscious sedation, while maintaining the adequate depth of sedation and spontaneous ventilation. In contrast, the SAS technique uses higher doses of sedative agents to provide deep sedation. As reported, in most cases of SAS technique, laryngeal mask, even endotracheal tube is used to facilitate for mechanical ventilation[8]. Several studies reported that the MAC and SAS techniques produce similar comfort and perioperative outcomes for the patients[9].

The fixed head by headrest may be a potential risk of difficult airway, whether in the supine position or lateral position. It's a severe challenge for the anesthesiologist to reinsert LAM or endotracheal tube intraoperatively. Maintaining airway patency is the key to improving the feasibility of artificial ventilation, especially in an emergency. Our case was accomplished with spontaneous breath by adjusting to the target concentration precisely.

The MAC technique may cause the risk of dose-dependent respiratory depression. BIS is recorded to monitor the depth of sedation. As we learned, propofol has dose-dependent depression in cardiovascular and respiratory system, while dexmedetomidine is beneficial for airway stability. Therefore, the combination of dexmedetomidine and propofol may reduce the dosage and side effects of drugs. As reported, propofol causes a reduction in tidal volume and an increase in RR[10]. In contrast, remifentanyl can lead to a reduction in RR and a slight increase in tidal volume[11]. The combination of propofol and remifentanyl contributes to a complex interaction in the respiratory system. Spontaneous respiration can be achieved successfully considering the interaction between the drugs[11,12]. Regional blocks are used for analgesia in awake craniotomy. Scalp nerve block and incision infiltration with ropivacaine perioperatively can make the patient obtain adequate analgesia, block the noxious stimulation, and reduce the adverse stimulation during the awaken period[13], to ensure higher awakening quality.

As Abdulrauf *et al*[6] responded, intraoperative aneurysm rupture can be observed under both awake craniotomy and general anesthesia[14]. Intraoperative hemodynamic variables are smoother in the asleep-awake-asleep group than in the general anesthesia group[15]. In addition, comparing to general anesthesia, awake craniotomy can release stress response, reduce median length of stay, and increase overall survival significantly in high-grade gliomas[16]. Therefore, the incidence of intraoperative arterial malformation rupture may be lower in awake craniotomy.

Intraoperative seizure is the most common cause for awake craniotomy failure, which is triggered by electrical cortical stimulation. The risk factors for seizure include stimulus length, current intensity, and the number of stimulations over the same cortical area. Intraoperative seizure can be easily control by ice saline and propofol, without permanent severe consequence[17]. This patient didn't develop intraoperative seizure. Hence, awake craniotomy is safe for patient with arterial malformation.

CONCLUSION

The literature on awake artery malformation clipping is rare, especially for anesthesia management. In our case, anesthetic management with nasopharyngeal airway is safe and effective for awake artery malformation clipping with intraoperative monitoring. On the basis of mastering the basic skills, anesthesiologists use simple equipment and anesthetic drugs to perform the awake artery malformation clipping successfully.

Although this scheme has some disadvantages, it can provide a reference for anesthesiologists in these patients, and its safety needs to be verified by large sample prospective clinical trials in the future.

REFERENCES

- 1 **Liu TY**, Xu N, Wan Z, Zhang ZM, Xu JJ, Meng H, Wang HL. Diagnosis and treatment of pure arterial malformation: Three case reports and literature review. *Medicine (Baltimore)* 2020; **99**: e20229 [PMID: 32481296 DOI: 10.1097/MD.00000000000020229]
- 2 **Nunes RR**, Bersot CDA, Garritano JG. Intraoperative neurophysiological monitoring in neuroanesthesia. *Curr Opin Anaesthesiol* 2018; **31**: 532-538 [PMID: 30020157 DOI: 10.1097/ACO.0000000000000645]
- 3 **Tobias JD**, Goble TJ, Bates G, Anderson JT, Hoernschemeyer DG. Effects of dexmedetomidine on intraoperative motor and somatosensory evoked potential monitoring during spinal surgery in adolescents. *Paediatr Anaesth* 2008; **18**: 1082-1088 [PMID: 18717802 DOI: 10.1111/j.1460-9592.2008.02733.x]
- 4 **Irie T**, Yoshitani K, Ohnishi Y, Shinzawa M, Miura N, Kusaka Y, Miyazaki S, Miyamoto S. The efficacy of motor-evoked potentials on cerebral aneurysm surgery and new-onset postoperative motor deficits. *J Neurosurg Anesthesiol* 2010; **22**: 247-251 [PMID: 20548170 DOI: 10.1097/ANA.0b013e3181de4eae]
- 5 **Suzuki K**, Mikami T, Sugino T, Wanibuchi M, Miyamoto S, Hashimoto N, Mikuni N. Discrepancy between voluntary movement and motor-evoked potentials in evaluation of motor function during clipping of anterior circulation aneurysms. *World Neurosurg* 2014; **82**: e739-e745 [PMID: 24036339 DOI: 10.1016/j.wneu.2013.08.034]
- 6 **Abdulrauf SI**, Vuong P, Patel R, Sampath R, Ashour AM, Germany LM, Lebovitz J, Brunson C, Nijjar Y, Dryden JK, Khan MQ, Stefan MG, Wiley E, Cleary RT, Reis C, Walsh J, Buchanan P. "Awake" clipping of cerebral aneurysms: report of initial series. *J Neurosurg* 2017; **127**: 311-318 [PMID: 27767401 DOI: 10.3171/2015.12.JNS152140]
- 7 **Kulikov A**, Lubnin A. Anesthesia for awake craniotomy. *Curr Opin Anaesthesiol* 2018; **31**: 506-510 [PMID: 29994938 DOI: 10.1097/ACO.0000000000000625]
- 8 **Pouratian N**, Cannestra AF, Bookheimer SY, Martin NA, Toga AW. Variability of intraoperative electrocortical stimulation mapping parameters across and within individuals. *J Neurosurg* 2004; **101**: 458-466 [PMID: 15352604 DOI: 10.3171/jns.2004.101.3.0458]
- 9 **Eseonu CI**, ReFaey K, Garcia O, John A, Quiñones-Hinojosa A, Tripathi P. Awake Craniotomy Anesthesia: A Comparison of the Monitored Anesthesia Care and Asleep-Awake-Asleep Techniques. *World Neurosurg* 2017; **104**: 679-686 [PMID: 28532922 DOI: 10.1016/j.wneu.2017.05.053]
- 10 **Goodman NW**, Black AM, Carter JA. Some ventilatory effects of propofol as sole anaesthetic agent. *Br J Anaesth* 1987; **59**: 1497-1503 [PMID: 3122806 DOI: 10.1093/bja/59.12.1497]
- 11 **Barker N**, Lim J, Amari E, Malherbe S, Ansermino JM. Relationship between age and spontaneous ventilation during intravenous anesthesia in children. *Paediatr Anaesth* 2007; **17**: 948-955 [PMID: 17767630 DOI: 10.1111/j.1460-9592.2007.02301.x]
- 12 **Ansermino JM**, Magruder W, Dosani M. Spontaneous respiration during intravenous anesthesia in children. *Curr Opin Anaesthesiol* 2009; **22**: 383-387 [PMID: 19434785 DOI: 10.1097/aco.0b013e328329730e]
- 13 **McClellan KJ**, Faulds D. Ropivacaine: an update of its use in regional anaesthesia. *Drugs* 2000; **60**: 1065-1093 [PMID: 11129123 DOI: 10.2165/00003495-200060050-00007]
- 14 **Agarwal N**. Letter to the Editor. Intraoperative aneurysm rupture during awake clipping of cerebral aneurysms. *J Neurosurg* 2018; **128**: 1906 [PMID: 29570014 DOI: 10.3171/2017.9.JNS172142]
- 15 **Rajan S**, Cata JP, Nada E, Weil R, Pal R, Avitsian R. Asleep-awake-asleep craniotomy: a comparison with general anesthesia for resection of supratentorial tumors. *J Clin Neurosci* 2013; **20**: 1068-1073 [PMID: 23453156 DOI: 10.1016/j.jocn.2012.09.031]
- 16 **Chowdhury T**, Gray K, Sharma M, Mau C, McNutt S, Ryan C, Farou N, Bergquist P, Caldwell C, Uribe AA, Todeschini AB, Bergese SD, Bucher O, Musto G, Azazi EA, Zadeh G, Tsang DS, Mansouri SA, Kakumanu S, Venkatraghavan L. Brain Cancer Progression: A Retrospective Multicenter Comparison of Awake Craniotomy Versus General Anesthesia in High-grade Glioma Resection. *J Neurosurg Anesthesiol* 2021 [PMID: 34001816 DOI: 10.1097/ANA.0000000000000778]
- 17 **Boetto J**, Bertram L, Moulinié G, Herbet G, Moritz-Gasser S, Duffau H. Low Rate of Intraoperative Seizures During Awake Craniotomy in a Prospective Cohort with 374 Supratentorial Brain Lesions: Electrocorticography Is Not Mandatory. *World Neurosurg* 2015; **84**: 1838-1844 [PMID: 26283485 DOI: 10.1016/j.wneu.2015.07.075]



Published by **Baishideng Publishing Group Inc**
7041 Koll Center Parkway, Suite 160, Pleasanton, CA 94566, USA

Telephone: +1-925-3991568

E-mail: bpgoffice@wjgnet.com

Help Desk: <https://www.f6publishing.com/helpdesk>

<https://www.wjgnet.com>

