

World Journal of *Clinical Cases*

World J Clin Cases 2021 September 26; 9(27): 7963-8279



Contents

Thrice Monthly Volume 9 Number 27 September 26, 2021

EDITORIAL

7963 *Exophiala dermatitidis*
Usuda D, Higashikawa T, Hotchi Y, Usami K, Shimozaawa S, Tokunaga S, Osugi I, Katou R, Ito S, Yoshizawa T, Asako S, Mishima K, Kondo A, Mizuno K, Takami H, Komatsu T, Oba J, Nomura T, Sugita M

REVIEW

7973 Gastric neuroendocrine neoplasms: A review

Köseoglu H, Duzenli T, Sezikli M

MINIREVIEWS

7986 Coronavirus disease 2019 and renal transplantation

Nassar M, Nso N, Ariyaratnam J, Sandhu J, Mohamed M, Baraka B, Ibrahim A, Alfshawy M, Zheng D, Bhangoo H, Soliman KM, Li M, Rizzo V, Daoud A

7998 Impact of COVID-19 on liver

Su YJ, Chang CW, Chen MJ, Lai YC

ORIGINAL ARTICLE

Case Control Study

8008 Association of gestational anemia with pregnancy conditions and outcomes: A nested case-control study

Sun Y, Shen ZZ, Huang FL, Jiang Y, Wang YW, Zhang SH, Ma S, Liu JT, Zhan YL, Lin H, Chen YL, Shi YJ, Ma LK

Retrospective Cohort Study

8020 Clinical stages of recurrent hepatocellular carcinoma: A retrospective cohort study

Yao SY, Liang B, Chen YY, Tang YT, Dong XF, Liu TQ

Retrospective Study

8027 Accuracy of ultrasonography in diagnosis of fetal central nervous system malformation

Pang B, Pan JJ, Li Q, Zhang X

8035 Analysis of ocular structural parameters and higher-order aberrations in Chinese children with myopia

Li X, Hu Q, Wang QR, Feng ZQ, Yang F, Du CY

8044 Radial nerve recovery following closed nailing of humeral shaft fractures without radial nerve exploration: A retrospective study

Yeh KL, Liaw CK, Wu TY, Chen CP

8051 Bridging therapy and direct mechanical thrombectomy in the treatment of cardiogenic cerebral infarction with anterior circulation macrovascular occlusion

Ding HJ, Ma C, Ye FP, Zhang JF

- 8061** Endu combined with concurrent chemotherapy and radiotherapy for stage IIB-IVA cervical squamous cell carcinoma patients

Zhao FJ, Su Q, Zhang W, Yang WC, Zhao L, Gao LY

CASE REPORT

- 8071** Primary pancreatic paraganglioma harboring lymph node metastasis: A case report

Jiang CN, Cheng X, Shan J, Yang M, Xiao YQ

- 8082** Retraction of lumbar disc herniation achieved by noninvasive techniques: A case report

Wang P, Chen C, Zhang QH, Sun GD, Wang CA, Li W

- 8090** Mixed neuroendocrine carcinoma of the gastric stump: A case report

Zhu H, Zhang MY, Sun WL, Chen G

- 8097** Diploic vein as a newly treatable cause of pulsatile tinnitus: A case report

Zhao PF, Zeng R, Qiu XY, Ding HY, Lv H, Li XS, Wang GP, Li D, Gong SS, Wang ZC

- 8104** Acute myocardial infarction and extensive systemic thrombosis in thrombotic thrombocytopenic purpura: A case report and review of literature

Şalaru DL, Adam CA, Marcu DTM, Şimon IV, Macovei L, Ambrosie L, Chirita E, Sascau RA, Statescu C

- 8114** Limited thoracoplasty and free musculocutaneous flap transposition for postpneumonectomy empyema: A case report

Huang QQ, He ZL, Wu YY, Liu ZJ

- 8120** Paraneoplastic focal segmental glomerulosclerosis associated with gastrointestinal stromal tumor with cutaneous metastasis: A case report

Zhou J, Yang Z, Yang CS, Lin H

- 8127** Acute coronary syndrome with severe atherosclerotic and hyperthyroidism: A case report

Zhu HM, Zhang Y, Tang Y, Yuan H, Li ZX, Long Y

- 8135** Gastric cancer with calcifications: A case report

Lin YH, Yao W, Fei Q, Wang Y

- 8142** Value of eosinophil count in bronchoalveolar lavage fluid for diagnosis of allergic bronchopulmonary aspergillosis: A case report

Wang WY, Wan SH, Zheng YL, Zhou LM, Zhang H, Jiang LB

- 8147** Asymptomatic gastric adenomyoma and heterotopic pancreas in a patient with pancreatic cancer: A case report and review of the literature

Li K, Xu Y, Liu NB, Shi BM

- 8157** Successful treatment of gastrointestinal infection-induced septic shock using the oXiris® hemofilter: A case report

Li Y, Ji XJ, Jing DY, Huang ZH, Duan ML

- 8164** Streptococcal pneumonia-associated hemolytic uremic syndrome treated by T-antibody-negative plasma exchange in children: Two case reports
Wang XL, Du Y, Zhao CG, Wu YB, Yang N, Pei L, Wang LJ, Wang QS
- 8171** Subclavian steal syndrome associated with Sjogren's syndrome: A case report
Hao LJ, Zhang J, Naveed M, Chen KY, Xiao PX
- 8177** Metachronous mixed cellularity classical Hodgkin's lymphoma and T-cell leukemia/lymphoma: A case report
Dong Y, Deng LJ, Li MM
- 8186** Duodenal perforation after organophosphorus poisoning: A case report
Lu YL, Hu J, Zhang LY, Cen XY, Yang DH, Yu AY
- 8192** Surgical treatment of abnormal systemic artery to the left lower lobe: A case report
Zhang YY, Gu XY, Li JL, Liu Z, Lv GY
- 8199** Madelung's disease with alcoholic liver disease and acute kidney injury: A case report
Wu L, Jiang T, Zhang Y, Tang AQ, Wu LH, Liu Y, Li MQ, Zhao LB
- 8207** Anesthetic technique for awake artery malformation clipping with motor evoked potential and somatosensory evoked potential: A case report
Zhou HY, Chen HY, Li Y
- 8214** Multiple hidden vessels in walled-off necrosis with high-risk bleeding: Report of two cases
Xu N, Zhai YQ, Li LS, Chai NL
- 8220** Non-small-cell lung cancer with epidermal growth factor receptor L861Q-L833F compound mutation benefits from both afatinib and osimertinib: A case report
Zhang Y, Shen JQ, Shao L, Chen Y, Lei L, Wang JL
- 8226** Successful removal of two magnets in the small intestine by laparoscopy and colonoscopy: A case report
Oh RG, Lee CG, Park YN, Lee YM
- 8232** Acute lower extremity arterial thrombosis after intraocular foreign body removal under general anesthesia: A case report and review of literature
Jeon S, Hong JM, Lee HJ, Kim E, Lee H, Kim Y, Ri HS, Lee JJ
- 8242** Low-intensity extracorporeal shock wave therapy for midshaft clavicular delayed union: A case report and review of literature
Yue L, Chen H, Feng TH, Wang R, Sun HL
- 8249** Treatment of bilateral granulomatous lobular mastitis during lactation with traditional Chinese medicine: A case report
Li ZY, Sun XM, Li JW, Liu XF, Sun ZY, Chen HH, Dong YL, Sun XH
- 8260** Early acute fat embolism syndrome caused by femoral fracture: A case report
Yang J, Cui ZN, Dong JN, Lin WB, Jin JT, Tang XJ, Guo XB, Cui SB, Sun M, Ji CC

- 8268** Combined fascia iliaca compartment block and monitored anesthesia care for geriatric patients with hip fracture: Two case reports
Zhan L, Zhang YJ, Wang JX
- 8274** Bell's palsy after inactivated COVID-19 vaccination in a patient with history of recurrent Bell's palsy: A case report
Yu BY, Cen LS, Chen T, Yang TH

ABOUT COVER

Editorial Board Member of *World Journal of Clinical Cases*, Sunil Kumar Gupta, MBBS, MD, Reader (Associate Professor), Department of Dermatology, Venereology and Leprology, All India Institute of Medical Sciences, Gorakhpur, Gorakhpur 273008, Uttar Pradesh, India. dr.sunil_30@yahoo.co.in

AIMS AND SCOPE

The primary aim of *World Journal of Clinical Cases* (WJCC, *World J Clin Cases*) is to provide scholars and readers from various fields of clinical medicine with a platform to publish high-quality clinical research articles and communicate their research findings online.

WJCC mainly publishes articles reporting research results and findings obtained in the field of clinical medicine and covering a wide range of topics, including case control studies, retrospective cohort studies, retrospective studies, clinical trials studies, observational studies, prospective studies, randomized controlled trials, randomized clinical trials, systematic reviews, meta-analysis, and case reports.

INDEXING/ABSTRACTING

The WJCC is now indexed in Science Citation Index Expanded (also known as SciSearch®), Journal Citation Reports/Science Edition, Scopus, PubMed, and PubMed Central. The 2021 Edition of Journal Citation Reports® cites the 2020 impact factor (IF) for WJCC as 1.337; IF without journal self cites: 1.301; 5-year IF: 1.742; Journal Citation Indicator: 0.33; Ranking: 119 among 169 journals in medicine, general and internal; and Quartile category: Q3. The WJCC's CiteScore for 2020 is 0.8 and Scopus CiteScore rank 2020: General Medicine is 493/793.

RESPONSIBLE EDITORS FOR THIS ISSUE

Production Editor: Ji-Hong Lin; Production Department Director: Xiang Li; Editorial Office Director: Jin-Lai Wang.

NAME OF JOURNAL

World Journal of Clinical Cases

ISSN

ISSN 2307-8960 (online)

LAUNCH DATE

April 16, 2013

FREQUENCY

Thrice Monthly

EDITORS-IN-CHIEF

Dennis A Bloomfield, Sandro Vento, Bao-Gan Peng

EDITORIAL BOARD MEMBERS

<https://www.wjgnet.com/2307-8960/editorialboard.htm>

PUBLICATION DATE

September 26, 2021

COPYRIGHT

© 2021 Baishideng Publishing Group Inc

INSTRUCTIONS TO AUTHORS

<https://www.wjgnet.com/bpg/gerinfo/204>

GUIDELINES FOR ETHICS DOCUMENTS

<https://www.wjgnet.com/bpg/gerinfo/287>

GUIDELINES FOR NON-NATIVE SPEAKERS OF ENGLISH

<https://www.wjgnet.com/bpg/gerinfo/240>

PUBLICATION ETHICS

<https://www.wjgnet.com/bpg/gerinfo/288>

PUBLICATION MISCONDUCT

<https://www.wjgnet.com/bpg/gerinfo/208>

ARTICLE PROCESSING CHARGE

<https://www.wjgnet.com/bpg/gerinfo/242>

STEPS FOR SUBMITTING MANUSCRIPTS

<https://www.wjgnet.com/bpg/gerinfo/239>

ONLINE SUBMISSION

<https://www.f6publishing.com>

Multiple hidden vessels in walled-off necrosis with high-risk bleeding: Report of two cases

Ning Xu, Ya-Qi Zhai, Long-Song Li, Ning-Li Chai

ORCID number: Ning Xu 0000-0002-7770-8731; Ya-Qi Zhai 0000-0001-6508-264X; Long-Song Li 0000-0002-4000-7501; Ning-Li Chai 0000-0002-6791-5817.

Author contributions: Chai NL was the patient's endoscopist and reviewed the literature; Chai NL and Xu N contributed to manuscript drafting; Xu N wrote the manuscript; Li LS and Zhai YQ were responsible for the revision of the manuscript for significant content; all authors issued final approval for the version to be submitted.

Informed consent statement: All study participants, or their legal guardian, provided informed written consent prior to study enrollment.

Conflict-of-interest statement: The authors declare no conflicts of interest for this manuscript.

CARE Checklist (2016) statement: The authors have read the CARE Checklist (2016), and the manuscript was prepared and revised according to the CARE Checklist (2016).

Open-Access: This article is an open-access article that was selected by an in-house editor and fully peer-reviewed by external reviewers. It is distributed in

Ning Xu, Ya-Qi Zhai, Long-Song Li, Ning-Li Chai, Department of Gastroenterology and Hepatology, Chinese PLA General Hospital, Beijing 100853, China

Corresponding author: Ning-Li Chai, MD, PhD, Chief Doctor, Department of Gastroenterology and Hepatology, Chinese PLA General Hospital, No. 28 Fuxing Road, Haidian District, Beijing 100853, China. chainingli@vip.163.com

Abstract

BACKGROUND

Walled-off necrosis (WON), as a local complication of acute necrotizing pancreatitis, is difficult to differentiate from pancreatic pseudocysts (PPC). Imaging modalities such as computed tomography show a lower accuracy than endoscopic ultrasound (EUS) in confirming the diagnosis. EUS-guided cystogastrostomy following direct endoscopic necrosectomy has achieved excellent results and has been regarded as a preferred alternative to traditional surgery. However, high-risk bleeding is one of the greatest concerns.

CASE SUMMARY

Two patients with symptomatic pancreatic fluid collections (PFCs) were admitted to our hospital for EUS-guided lumen-apposing metal stent therapy. The female patient suffered from intermittent abdominal pain and underwent two perioperative CT examinations. The male patient had recurrent pancreatitis and showed a growing PFC. The initial diagnosis was a PPC according to contrast-enhanced CT. However, the evidence of solid contents on EUS prompted revision of the diagnosis to WON. An endoscope was inserted into the cavity, and some necrotic debris and multiple hidden vascular structures were observed. Owing to conservative treatment by irrigation with sterile water instead of direct necrosectomy, we successfully avoided damaging hidden vessels and reduced the risk of intraoperative bleeding.

CONCLUSION

The application of EUS is helpful for the identification of PFCs. Careful intervention should be conducted for WON with multiple vessels to prevent bleeding.

Key Words: Walled-off necrosis; Computed tomography; Endoscopic ultrasound; Vessel bleeding; Case report

accordance with the Creative Commons Attribution NonCommercial (CC BY-NC 4.0) license, which permits others to distribute, remix, adapt, build upon this work non-commercially, and license their derivative works on different terms, provided the original work is properly cited and the use is non-commercial. See: <http://creativecommons.org/licenses/by-nc/4.0/>

Manuscript source: Unsolicited manuscript

Specialty type: Gastroenterology and hepatology

Country/Territory of origin: China

Peer-review report's scientific quality classification

Grade A (Excellent): 0
Grade B (Very good): 0
Grade C (Good): C
Grade D (Fair): 0
Grade E (Poor): 0

Received: May 8, 2021

Peer-review started: May 8, 2021

First decision: June 6, 2021

Revised: June 17, 2021

Accepted: July 5, 2021

Article in press: July 5, 2021

Published online: September 26, 2021

P-Reviewer: Nishikawa K

S-Editor: Wang LL

L-Editor: Wang TQ

P-Editor: Zhang YL



©The Author(s) 2021. Published by Baishideng Publishing Group Inc. All rights reserved.

Core Tip: Walled-off necrosis (WON) is difficult to differentiate from pancreatic pseudocysts in clinical practice. Imaging modalities such as computed tomography show a lower accuracy than endoscopic ultrasound (EUS) in confirming the diagnosis. With the worldwide application of electrocautery lumen-apposing metal stents, direct endoscopic necrosectomy has emerged as the most effective approach for treating WON. However, bleeding might be induced by direct damage. Here, we present two cases of WON in which the diagnosis was revised by intraoperative EUS and high-risk bleeding was successfully prevented.

Citation: Xu N, Zhai YQ, Li LS, Chai NL. Multiple hidden vessels in walled-off necrosis with high-risk bleeding: Report of two cases. *World J Clin Cases* 2021; 9(27): 8214-8219

URL: <https://www.wjgnet.com/2307-8960/full/v9/i27/8214.htm>

DOI: <https://dx.doi.org/10.12998/wjcc.v9.i27.8214>

INTRODUCTION

Walled-off necrosis (WON) and pancreatic pseudocysts (PPCs) are local complications of acute pancreatitis according to the updated Atlanta classification[1]. WON is defined as a partially liquefied collection containing solid luminal content, which could be used to differentiate it from PPCs on imaging, with an accuracy of 79.5%-83.6%[2]. Unfortunately, WON is frequently misdiagnosed as PPCs by radiologists. Bleeding is the most common complication of endoscopic drainage. The existence of a vessel within an area of WON, which might increase the risk of hemorrhage, has rarely been reported in the literature. The presence of multiple vessels multiplies the risk of vascular rupture. Herein, we present the cases of two patients who underwent direct endoscopic necrosectomy (DEN) with a novel lumen-apposing metal stent (LAMS) whose diagnoses were revised by intraoperative endoscopic ultrasound (EUS). In these cases, careful intervention prevented traumatic bleeding from multiple vessels.

CASE PRESENTATION

Chief complaints

Case 1: A 34-year-old woman with intermittent abdominal pain over 1 year was initially diagnosed with PPCs according to contrast-enhanced CT and admitted to our hospital on November 17, 2020.

Case 2: A 32-year-old man with recurrent pancreatitis was diagnosed with a growing pancreatic fluid collection (PFC) by CT and admitted to our hospital for further treatment on January 6, 2021.

History of present illness

Case 1: Contrast-enhanced abdominal CT showed a heterogeneous fluid collection in the peripancreatic area, with an approximate diameter of 11 cm, on October 22, 2019.

Case 2: The patient was initially diagnosed with a PPC at another hospital 4 mo prior and transferred to our hospital for EUS-guided LAMS therapy.

History of past illness

Case 1: The patient had a history of acute pancreatitis approximately 1 year prior.

Case 2: Five years prior, the patient suffered from pancreatitis for the first time.

Personal and family history

Cases 1 and 2: The personal and family histories were unremarkable.

Physical examination

Case 1: The patient was suffering from intermittent abdominal pain on admission to our hospital. Upon physical examination, her temperature was 36.6 °C, her respiratory rate was 22 breaths per minute, her blood pressure was 124/78 mmHg, and her pulse rate was 135 bpm. The other tests did not show obvious abnormal manifestations.

Case 2: The patient had mild abdominal pain. All vital signs were normal.

Laboratory examinations

Case 1: No pancreatitis-related abnormalities were found by blood biochemical examination.

Case 2: A significant increase in the carbohydrate antigen 19-9 level was found by blood biochemical examination, as well as a slight increase in the carbohydrate antigen 125 level.

Imaging examinations

Case 1: Contrast-enhanced abdominal CT at our hospital still showed a heterogeneous fluid collection, with negligible changes in the dimensions of the lesion (Figure 1A). Linear EUS (GF-UCT260, Olympus, Japan), as a routine procedure to localize the blood vessels surrounding a cyst and detect the morphological features of a lesion, was first performed. Surprisingly, we found some high-density shadows during the procedure (Figure 2A), which confirmed the incorrect diagnosis determined on CT. Simultaneously, no signs of blood vessels in or around the cyst were observed.

Case 2: The patient was diagnosed with a PPC, with an approximate diameter of 5 cm, 3 mo prior by abdominal CT and magnetic resonance cholangiopancreatography (Figure 1B and C). On December 18, 2020, contrast-enhanced CT showed that the dimensions of the lesion had increased to 7.12 cm × 3.99 cm. Linear EUS showed signs of high-density shadows inside of the cyst (Figure 2B). No signs of vessels were found.

FINAL DIAGNOSIS

Based on the two patient's medical histories and EUS examination findings, we arranged for them to undergo EUS-guided cystogastrostomy followed by the placement of an electrocautery LAMS (16 mm × 26 mm, Micro-Tech Co., Ltd., Nanjing, China). Under direct visualization, a large amount of necrotic debris and the presence of multiple hidden vessels (Figure 3) were observed. Based on the endoscopy findings, the diagnosis of these two patients was revised to WON with the presence of multiple hidden vessels.

TREATMENT

After multiple hidden vessels were detected by direct visualization under endoscopy, irrigation with sterile water alone was performed. Subsequent monitoring for postoperative infection showed that the temperature of both patients remained in the normal range. Using rat-tooth forceps, two consecutive DEN sessions were performed prudentially.

OUTCOME AND FOLLOW-UP

No active bleeding was found in these two patients during hospitalization. Within 1 mo, the metal stent was carefully extracted without complications. Two months after DEN, these two patients reported no abdominal pain. The last follow-up contrast-enhanced CT of the abdomen indicated disappearance of the PPCs and no signs of recurrence.

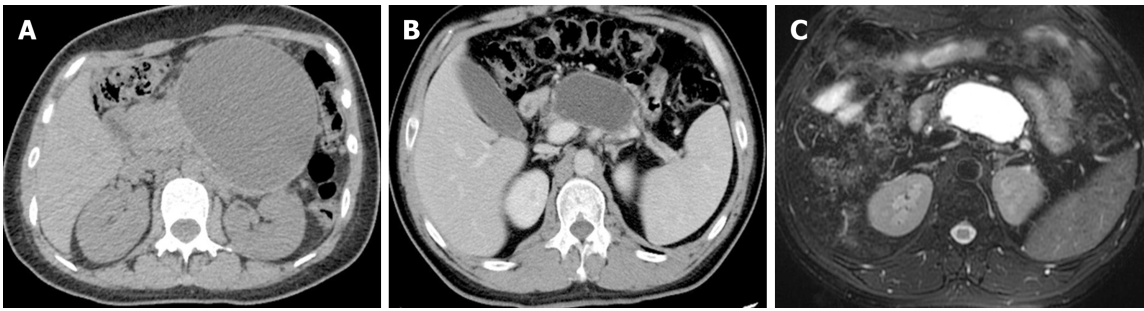


Figure 1 Perioperative images. A: Perioperative computed tomography (CT) angiogram of the female patient; B and C: Perioperative magnetic resonance cholangiopancreatography and CT images of the male patient.

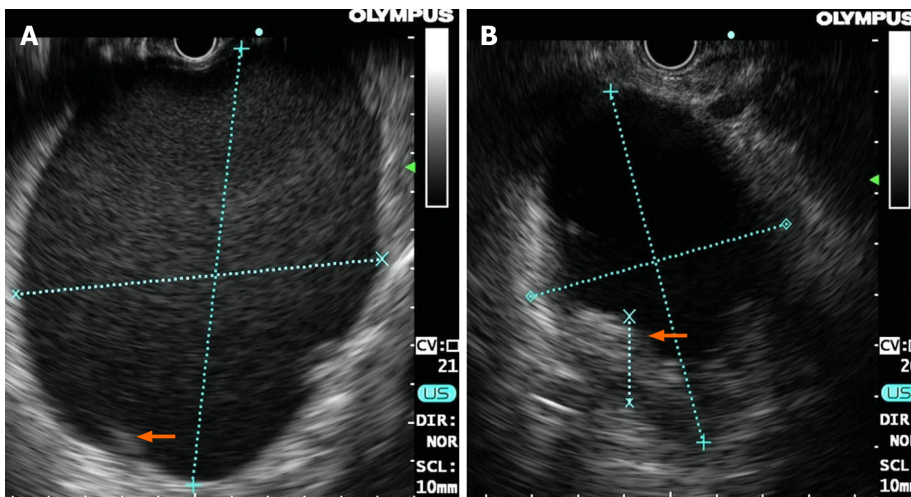


Figure 2 Endoscopic ultrasound images of the lesion in each patient. A: The size and high-density shadows (arrow) of the lesion in the female on endoscopic ultrasound (EUS); B: The size and high-density shadows (arrow) of the lesion in the male on EUS.

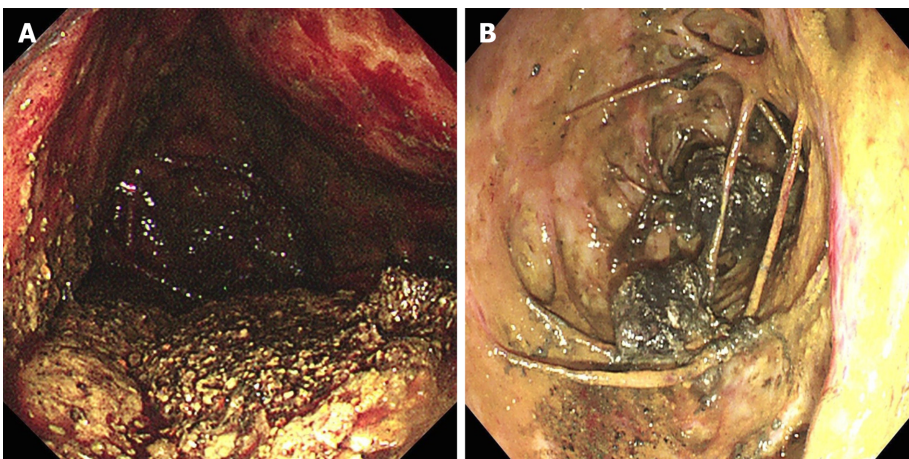


Figure 3 Direct observation of multiple hidden vessels under endoscopy. A: Multiple hidden vessels in the female; B: Multiple hidden vessels in the male.

DISCUSSION

PPCs and WON are both local complications of acute pancreatitis with similar morphological features on imaging modalities[3]. Abdominal CT is recommended as the first-line imaging modality on admission in the absence of contraindications[4]. However, in some situations, a definite diagnosis of WON or PPCs is difficult for radiologists to achieve due to their similarities[5]. Reviewing the CT scans

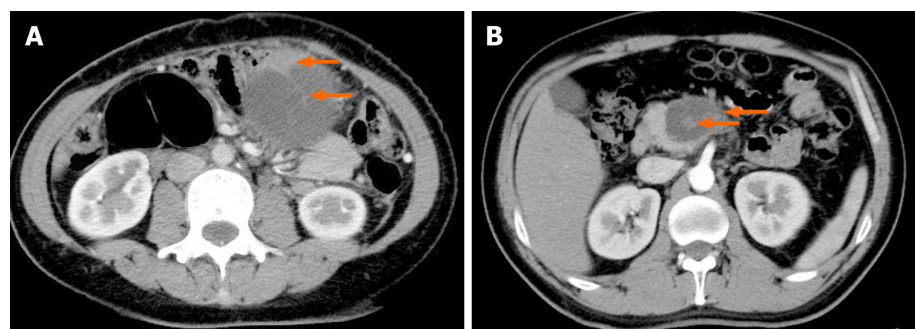


Figure 4 Retrospective observation of computed tomography images. A: Radiological signs of nonliquid contents and some cord-like shadows (arrow) in the female; B: Solid debris (arrow) in the male.

retrospectively, we detected some subtle radiological signs of nonliquid contents and some cord-like shadows (Figure 4), which should be recognized by radiologists as well as endoscopists.

Although more invasive, EUS has been highlighted for assessing solid debris in WON[6]. The application of EUS to evaluate the morphological features of WON, including size and contents, has significant therapeutic implications[7]. With evidence of solid contents on EUS, the misdiagnosis of PPCs could be revised. Furthermore, localizing the blood vessels surrounding a cyst is of great importance to confirm the optimal puncture site for EUS-guided drainage. Color Doppler can also be used to avoid vascular structures if needed[8].

The management of WON is challenging, and its treatment strategy has shifted from surgery to endoscopy. Recently, a novel LAMS has further promoted the popularity of this approach. Owing to the formation of a drainage channel between the gastrointestinal tract and the PFC, DEN, which has been proven to be a more effective and less invasive approach, is commonly used in the treatment of symptomatic WON [9]. EUS-guided transluminal drainage with an LAMS has a significantly higher rate of clinical success than that with a traditional double pigtail plastic stent[10].

However, gastrointestinal bleeding, as the most common complication of LAMS therapy, could be induced by direct damage or pseudoaneurysm formation[11]. A case of large crossing blood vessels within an area of WON has already been reported[12]. A retrospective study of EUS-mediated drainage with an LAMS showed an increased incidence of pseudoaneurysm bleeding[13]. Thus, if the presence of multiple hidden vessels is identified, conservative treatment by irrigation with sterile water instead of direct necrosectomy should be performed, and if an LAMS is present *in vivo*, monitoring for delayed bleeding should be considered.

CONCLUSION

This is the first report of multiple vessels crossing within an area of WON in two cases. Due to intraoperative EUS before cystogastrostomy and simple irrigation, we successfully avoided damaging hidden vessels and thus reduced the risk of intraoperative bleeding.

REFERENCES

- 1 Yasuda I, Takahashi K. Endoscopic management of walled-off pancreatic necrosis. *Dig Endosc* 2021; **33**: 335-341 [PMID: 32306430 DOI: 10.1111/den.13699]
- 2 Takahashi N, Papachristou GI, Schmit GD, Chahal P, LeRoy AJ, Sarr MG, Vege SS, Mandrekar JN, Baron TH. CT findings of walled-off pancreatic necrosis (WOPN): differentiation from pseudocyst and prediction of outcome after endoscopic therapy. *Eur Radiol* 2008; **18**: 2522-2529 [PMID: 18563416 DOI: 10.1007/s00330-008-1039-1]
- 3 Stamatakis M, Stefanaki C, Kontzoglou K, Stergiopoulos S, Giannopoulos G, Safioleas M. Walled-off pancreatic necrosis. *World J Gastroenterol* 2010; **16**: 1707-1712 [PMID: 20380001 DOI: 10.3748/wjg.v16.i14.1707]
- 4 Arvanitakis M, Dumonceau JM, Albert J, Badaoui A, Bali MA, Barthet M, Besselink M, Deviere J, Oliveira Ferreira A, Gyökeres T, Hritz I, Hucl T, Milashka M, Papanikolaou IS, Poley JW, Seewald S, Vanbiervliet G, van Lienden K, van Santvoort H, Voermans R, Delhaye M, van Hooft J.

- Endoscopic management of acute necrotizing pancreatitis: European Society of Gastrointestinal Endoscopy (ESGE) evidence-based multidisciplinary guidelines. *Endoscopy* 2018; **50**: 524-546 [PMID: 29631305 DOI: 10.1055/a-0588-5365]
- 5 **Abou Karam A**, Bagherpour A, Calleros J, Laks S. Imaging of endoscopic cystogastrostomy in pancreatic walled-off necrosis: what the radiologist needs to know. *Abdom Radiol (NY)* 2018; **43**: 3043-3053 [PMID: 29619526 DOI: 10.1007/s00261-018-1584-2]
- 6 **Rana SS**, Chaudhary V, Sharma R, Sharma V, Chhabra P, Bhasin DK. Comparison of abdominal ultrasound, endoscopic ultrasound and magnetic resonance imaging in detection of necrotic debris in walled-off pancreatic necrosis. *Gastroenterol Rep (Oxf)* 2016; **4**: 50-53 [PMID: 25573950 DOI: 10.1093/gastro/gou088]
- 7 **Rana SS**, Bhasin DK, Sharma RK, Kathiresan J, Gupta R. Do the morphological features of walled off pancreatic necrosis on endoscopic ultrasound determine the outcome of endoscopic transmural drainage? *Endosc Ultrasound* 2014; **3**: 118-122 [PMID: 24955341 DOI: 10.4103/2303-9027.131039]
- 8 **Mitrovic M**, Dugalic V, Kovac J, Tadic B, Milosevic S, Lukic B, Lekic N, Cvetic V. Successful Embolization of Posterior Inferior Pancreaticoduodenal Artery Pseudoaneurysm on the Grounds of Chronic Pancreatitis-Case Report and Literature Review. *Medicina (Kaunas)* 2020; **56** [PMID: 33207736 DOI: 10.3390/medicina56110617]
- 9 **Rerknimitr R**. Endoscopic Transmural Necrosectomy: Timing, Indications, and Methods. *Clin Endosc* 2020; **53**: 49-53 [PMID: 31530792 DOI: 10.5946/ce.2019.131]
- 10 **Bang JY**, Varadarajulu S. Endoscopic ultrasound-guided management of pancreatic pseudocysts and walled-off necrosis. *Clin Endosc* 2014; **47**: 429-431 [PMID: 25325003 DOI: 10.5946/ce.2014.47.5.429]
- 11 **Rana SS**. An overview of walled-off pancreatic necrosis for clinicians. *Expert Rev Gastroenterol Hepatol* 2019; **13**: 331-343 [PMID: 30791769 DOI: 10.1080/17474124.2019.1574568]
- 12 **Alhasan F**, Hoilat GJ, Malas W, Mahmood SK, Zivny J, Alsayid M. Endoscopic Management of Giant Walled-Off Pancreatic Necrosis With a High Risk of Bleeding. *ACG Case Rep J* 2019; **6**: e00199 [PMID: 31737728 DOI: 10.14309/crj.0000000000000199]
- 13 **Brimhall B**, Han S, Tatman PD, Clark TJ, Wani S, Brauer B, Edmundowicz S, Wagh MS, Attwell A, Hammad H, Shah RJ. Increased Incidence of Pseudoaneurysm Bleeding With Lumen-Apposing Metal Stents Compared to Double-Pigtail Plastic Stents in Patients With Peripancreatic Fluid Collections. *Clin Gastroenterol Hepatol* 2018; **16**: 1521-1528 [PMID: 29474970 DOI: 10.1016/j.cgh.2018.02.021]



Published by **Baishideng Publishing Group Inc**
7041 Koll Center Parkway, Suite 160, Pleasanton, CA 94566, USA

Telephone: +1-925-3991568

E-mail: bpgoffice@wjgnet.com

Help Desk: <https://www.f6publishing.com/helpdesk>

<https://www.wjgnet.com>

