

World Journal of *Clinical Cases*

World J Clin Cases 2021 September 26; 9(27): 7963-8279



Contents

Thrice Monthly Volume 9 Number 27 September 26, 2021

EDITORIAL

7963 *Exophiala dermatitidis*

Usuda D, Higashikawa T, Hotchi Y, Usami K, Shimozaawa S, Tokunaga S, Osugi I, Katou R, Ito S, Yoshizawa T, Asako S, Mishima K, Kondo A, Mizuno K, Takami H, Komatsu T, Oba J, Nomura T, Sugita M

REVIEW

7973 Gastric neuroendocrine neoplasms: A review

Köseoglu H, Duzenli T, Sezikli M

MINIREVIEWS

7986 Coronavirus disease 2019 and renal transplantation

Nassar M, Nso N, Ariyaratnam J, Sandhu J, Mohamed M, Baraka B, Ibrahim A, Alfshawy M, Zheng D, Bhangoo H, Soliman KM, Li M, Rizzo V, Daoud A

7998 Impact of COVID-19 on liver

Su YJ, Chang CW, Chen MJ, Lai YC

ORIGINAL ARTICLE

Case Control Study

8008 Association of gestational anemia with pregnancy conditions and outcomes: A nested case-control study

Sun Y, Shen ZZ, Huang FL, Jiang Y, Wang YW, Zhang SH, Ma S, Liu JT, Zhan YL, Lin H, Chen YL, Shi YJ, Ma LK

Retrospective Cohort Study

8020 Clinical stages of recurrent hepatocellular carcinoma: A retrospective cohort study

Yao SY, Liang B, Chen YY, Tang YT, Dong XF, Liu TQ

Retrospective Study

8027 Accuracy of ultrasonography in diagnosis of fetal central nervous system malformation

Pang B, Pan JJ, Li Q, Zhang X

8035 Analysis of ocular structural parameters and higher-order aberrations in Chinese children with myopia

Li X, Hu Q, Wang QR, Feng ZQ, Yang F, Du CY

8044 Radial nerve recovery following closed nailing of humeral shaft fractures without radial nerve exploration: A retrospective study

Yeh KL, Liaw CK, Wu TY, Chen CP

8051 Bridging therapy and direct mechanical thrombectomy in the treatment of cardiogenic cerebral infarction with anterior circulation macrovascular occlusion

Ding HJ, Ma C, Ye FP, Zhang JF

- 8061** Endu combined with concurrent chemotherapy and radiotherapy for stage IIB-IVA cervical squamous cell carcinoma patients

Zhao FJ, Su Q, Zhang W, Yang WC, Zhao L, Gao LY

CASE REPORT

- 8071** Primary pancreatic paraganglioma harboring lymph node metastasis: A case report

Jiang CN, Cheng X, Shan J, Yang M, Xiao YQ

- 8082** Retraction of lumbar disc herniation achieved by noninvasive techniques: A case report

Wang P, Chen C, Zhang QH, Sun GD, Wang CA, Li W

- 8090** Mixed neuroendocrine carcinoma of the gastric stump: A case report

Zhu H, Zhang MY, Sun WL, Chen G

- 8097** Diploic vein as a newly treatable cause of pulsatile tinnitus: A case report

Zhao PF, Zeng R, Qiu XY, Ding HY, Lv H, Li XS, Wang GP, Li D, Gong SS, Wang ZC

- 8104** Acute myocardial infarction and extensive systemic thrombosis in thrombotic thrombocytopenic purpura: A case report and review of literature

Şalaru DL, Adam CA, Marcu DTM, Şimon IV, Macovei L, Ambrosie L, Chirita E, Sascau RA, Statescu C

- 8114** Limited thoracoplasty and free musculocutaneous flap transposition for postpneumonectomy empyema: A case report

Huang QQ, He ZL, Wu YY, Liu ZJ

- 8120** Paraneoplastic focal segmental glomerulosclerosis associated with gastrointestinal stromal tumor with cutaneous metastasis: A case report

Zhou J, Yang Z, Yang CS, Lin H

- 8127** Acute coronary syndrome with severe atherosclerotic and hyperthyroidism: A case report

Zhu HM, Zhang Y, Tang Y, Yuan H, Li ZX, Long Y

- 8135** Gastric cancer with calcifications: A case report

Lin YH, Yao W, Fei Q, Wang Y

- 8142** Value of eosinophil count in bronchoalveolar lavage fluid for diagnosis of allergic bronchopulmonary aspergillosis: A case report

Wang WY, Wan SH, Zheng YL, Zhou LM, Zhang H, Jiang LB

- 8147** Asymptomatic gastric adenomyoma and heterotopic pancreas in a patient with pancreatic cancer: A case report and review of the literature

Li K, Xu Y, Liu NB, Shi BM

- 8157** Successful treatment of gastrointestinal infection-induced septic shock using the oXiris® hemofilter: A case report

Li Y, Ji XJ, Jing DY, Huang ZH, Duan ML

- 8164** Streptococcal pneumonia-associated hemolytic uremic syndrome treated by T-antibody-negative plasma exchange in children: Two case reports
Wang XL, Du Y, Zhao CG, Wu YB, Yang N, Pei L, Wang LJ, Wang QS
- 8171** Subclavian steal syndrome associated with Sjogren's syndrome: A case report
Hao LJ, Zhang J, Naveed M, Chen KY, Xiao PX
- 8177** Metachronous mixed cellularity classical Hodgkin's lymphoma and T-cell leukemia/lymphoma: A case report
Dong Y, Deng LJ, Li MM
- 8186** Duodenal perforation after organophosphorus poisoning: A case report
Lu YL, Hu J, Zhang LY, Cen XY, Yang DH, Yu AY
- 8192** Surgical treatment of abnormal systemic artery to the left lower lobe: A case report
Zhang YY, Gu XY, Li JL, Liu Z, Lv GY
- 8199** Madelung's disease with alcoholic liver disease and acute kidney injury: A case report
Wu L, Jiang T, Zhang Y, Tang AQ, Wu LH, Liu Y, Li MQ, Zhao LB
- 8207** Anesthetic technique for awake artery malformation clipping with motor evoked potential and somatosensory evoked potential: A case report
Zhou HY, Chen HY, Li Y
- 8214** Multiple hidden vessels in walled-off necrosis with high-risk bleeding: Report of two cases
Xu N, Zhai YQ, Li LS, Chai NL
- 8220** Non-small-cell lung cancer with epidermal growth factor receptor L861Q-L833F compound mutation benefits from both afatinib and osimertinib: A case report
Zhang Y, Shen JQ, Shao L, Chen Y, Lei L, Wang JL
- 8226** Successful removal of two magnets in the small intestine by laparoscopy and colonoscopy: A case report
Oh RG, Lee CG, Park YN, Lee YM
- 8232** Acute lower extremity arterial thrombosis after intraocular foreign body removal under general anesthesia: A case report and review of literature
Jeon S, Hong JM, Lee HJ, Kim E, Lee H, Kim Y, Ri HS, Lee JJ
- 8242** Low-intensity extracorporeal shock wave therapy for midshaft clavicular delayed union: A case report and review of literature
Yue L, Chen H, Feng TH, Wang R, Sun HL
- 8249** Treatment of bilateral granulomatous lobular mastitis during lactation with traditional Chinese medicine: A case report
Li ZY, Sun XM, Li JW, Liu XF, Sun ZY, Chen HH, Dong YL, Sun XH
- 8260** Early acute fat embolism syndrome caused by femoral fracture: A case report
Yang J, Cui ZN, Dong JN, Lin WB, Jin JT, Tang XJ, Guo XB, Cui SB, Sun M, Ji CC

- 8268** Combined fascia iliaca compartment block and monitored anesthesia care for geriatric patients with hip fracture: Two case reports
Zhan L, Zhang YJ, Wang JX
- 8274** Bell's palsy after inactivated COVID-19 vaccination in a patient with history of recurrent Bell's palsy: A case report
Yu BY, Cen LS, Chen T, Yang TH

ABOUT COVER

Editorial Board Member of *World Journal of Clinical Cases*, Sunil Kumar Gupta, MBBS, MD, Reader (Associate Professor), Department of Dermatology, Venereology and Leprology, All India Institute of Medical Sciences, Gorakhpur, Gorakhpur 273008, Uttar Pradesh, India. dr.sunil_30@yahoo.co.in

AIMS AND SCOPE

The primary aim of *World Journal of Clinical Cases* (WJCC, *World J Clin Cases*) is to provide scholars and readers from various fields of clinical medicine with a platform to publish high-quality clinical research articles and communicate their research findings online.

WJCC mainly publishes articles reporting research results and findings obtained in the field of clinical medicine and covering a wide range of topics, including case control studies, retrospective cohort studies, retrospective studies, clinical trials studies, observational studies, prospective studies, randomized controlled trials, randomized clinical trials, systematic reviews, meta-analysis, and case reports.

INDEXING/ABSTRACTING

The WJCC is now indexed in Science Citation Index Expanded (also known as SciSearch®), Journal Citation Reports/Science Edition, Scopus, PubMed, and PubMed Central. The 2021 Edition of Journal Citation Reports® cites the 2020 impact factor (IF) for WJCC as 1.337; IF without journal self cites: 1.301; 5-year IF: 1.742; Journal Citation Indicator: 0.33; Ranking: 119 among 169 journals in medicine, general and internal; and Quartile category: Q3. The WJCC's CiteScore for 2020 is 0.8 and Scopus CiteScore rank 2020: General Medicine is 493/793.

RESPONSIBLE EDITORS FOR THIS ISSUE

Production Editor: Ji-Hong Lin; Production Department Director: Xiang Li; Editorial Office Director: Jin-Lai Wang.

NAME OF JOURNAL

World Journal of Clinical Cases

ISSN

ISSN 2307-8960 (online)

LAUNCH DATE

April 16, 2013

FREQUENCY

Thrice Monthly

EDITORS-IN-CHIEF

Dennis A Bloomfield, Sandro Vento, Bao-Gan Peng

EDITORIAL BOARD MEMBERS

<https://www.wjgnet.com/2307-8960/editorialboard.htm>

PUBLICATION DATE

September 26, 2021

COPYRIGHT

© 2021 Baishideng Publishing Group Inc

INSTRUCTIONS TO AUTHORS

<https://www.wjgnet.com/bpg/gerinfo/204>

GUIDELINES FOR ETHICS DOCUMENTS

<https://www.wjgnet.com/bpg/GerInfo/287>

GUIDELINES FOR NON-NATIVE SPEAKERS OF ENGLISH

<https://www.wjgnet.com/bpg/gerinfo/240>

PUBLICATION ETHICS

<https://www.wjgnet.com/bpg/GerInfo/288>

PUBLICATION MISCONDUCT

<https://www.wjgnet.com/bpg/gerinfo/208>

ARTICLE PROCESSING CHARGE

<https://www.wjgnet.com/bpg/gerinfo/242>

STEPS FOR SUBMITTING MANUSCRIPTS

<https://www.wjgnet.com/bpg/GerInfo/239>

ONLINE SUBMISSION

<https://www.f6publishing.com>



Non-small-cell lung cancer with epidermal growth factor receptor L861Q-L833F compound mutation benefits from both afatinib and osimertinib: A case report

Yao Zhang, Ji-Qiao Shen, Lin Shao, Yan Chen, Lei Lei, Jia-Lei Wang

ORCID number: Yao Zhang 0000-0003-1174-7049; Ji-Qiao Shen 0000-0001-5547-8800; Lin Shao 0000-0002-2659-4551; Yan Chen 0000-0002-4474-7574; Lei Lei 0000-0003-4667-0504; Jia-Lei Wang 0000-0001-6944-9613.

Author contributions: Zhang Y and Wang JL contributed to the conception and design; Zhang Y and Shen JQ contributed to the provision of study materials; Zhang Y, Shen JQ, Chen Y, and Lei L contributed to collection and assembly of the data; Chen Y and Lei L contributed to the experiment methods; Shao L wrote the manuscript; all authors contributed to the revision and final approval of the manuscript.

Informed consent statement:

Written informed consent was obtained from the patient for publication of this case report and any accompanying images in an anonymised manner.

Conflict-of-interest statement: The authors declare that there is no conflict of interest to report.

CARE Checklist (2016) statement:

The authors have read the CARE Checklist (2016), and the manuscript was prepared and revised according to the CARE

Yao Zhang, Ji-Qiao Shen, Jia-Lei Wang, Department of Medical Oncology, Fudan University Shanghai Cancer Center, Shanghai 200032, China

Yao Zhang, Ji-Qiao Shen, Jia-Lei Wang, Department of Oncology, Shanghai Medical College, Fudan University, Shanghai 200032, China

Yao Zhang, Ji-Qiao Shen, Jia-Lei Wang, Institute of Thoracic Oncology, Fudan University, Shanghai 200032, China

Lin Shao, Yan Chen, Lei Lei, Burning Rock Biotech, Guangzhou 510300, Guangdong Province, China

Corresponding author: Jia-Lei Wang, MD, Chief Physician, Department of Medical Oncology, Fudan University Shanghai Cancer Center, No. 270 Dongan Road, Shanghai 200032, China. m18017312369@163.com

Abstract

BACKGROUND

Epidermal growth factor receptor (EGFR) tyrosine kinase inhibitors (TKIs) have been adopted as the standard of care for non-small cell lung cancer (NSCLC) patients harboring *EGFR* sensitizing mutations. Besides the two common mutations exon 19 deletion and L858R, which together comprise approximately 85% of *EGFR* mutations in NSCLC, rare *EGFR* mutations also exist, including point mutations, deletions, and insertions spanning *EGFR* exons 18-25. However, the responsiveness of uncommon *EGFR* mutations to EGFR TKIs remains elusive and attracts increasing interest.

CASE SUMMARY

Herein, we report a 55-year-old male patient with stage IV NSCLC harboring a rare *EGFR* L833F-L861Q compound mutation *in cis*. The patient achieved a partial response to first-line treatment with afatinib and a progression-free survival of 10 mo. After afatinib failure, the patient received multiple line treatments with chemotherapy. Upon disease progression, the heavily pretreated patient was treated with osimertinib and bevacizumab, and both lung lesion and brain metastases were stable for more than 3 mo. He had an overall survival of 25 mo.

CONCLUSION

Checklist (2016).

Open-Access: This article is an open-access article that was selected by an in-house editor and fully peer-reviewed by external reviewers. It is distributed in accordance with the Creative Commons Attribution NonCommercial (CC BY-NC 4.0) license, which permits others to distribute, remix, adapt, build upon this work non-commercially, and license their derivative works on different terms, provided the original work is properly cited and the use is non-commercial. See: <http://creativecommons.org/licenses/by-nc/4.0/>

Manuscript source: Unsolicited manuscript

Specialty type: Oncology

Country/Territory of origin: China

Peer-review report's scientific quality classification

Grade A (Excellent): 0
Grade B (Very good): B
Grade C (Good): 0
Grade D (Fair): D
Grade E (Poor): 0

Received: May 8, 2021

Peer-review started: May 8, 2021

First decision: June 5, 2021

Revised: June 17, 2021

Accepted: July 5, 2021

Article in press: July 5, 2021

Published online: September 26, 2021

P-Reviewer: Ko R, Syahputra DA

S-Editor: Wang LL

L-Editor: Wang TQ

P-Editor: Wu RR



Our case revealed that both afatinib and the osimertinib + bevacizumab combination demonstrated clinical efficacy in NSCLC harboring an *EGFR* L833F-L861Q compound mutation. The results provide more therapeutic options for patients with rare compound mutations.

Key Words: Afatinib; Osimertinib; Epidermal growth factor receptor; L861Q-L833F; Non-small cell lung cancer; Case report

©The Author(s) 2021. Published by Baishideng Publishing Group Inc. All rights reserved.

Core Tip: Our case revealed that both afatinib and the osimertinib + bevacizumab combination demonstrated clinical efficacy in a non-small cell lung cancer patient harboring a rare epidermal growth factor receptor (*EGFR*) L833F-L861Q compound mutation. The results provide more options for the clinical management of patients with rare *EGFR* compound mutations.

Citation: Zhang Y, Shen JQ, Shao L, Chen Y, Lei L, Wang JL. Non-small-cell lung cancer with epidermal growth factor receptor L861Q-L833F compound mutation benefits from both afatinib and osimertinib: A case report. *World J Clin Cases* 2021; 9(27): 8220-8225

URL: <https://www.wjgnet.com/2307-8960/full/v9/i27/8220.htm>

DOI: <https://dx.doi.org/10.12998/wjcc.v9.i27.8220>

INTRODUCTION

Epidermal growth factor receptor (*EGFR*) tyrosine kinase inhibitors (TKIs) have been adopted as the standard of care for non-small cell lung cancer (NSCLC) patients harboring *EGFR* sensitizing mutations. Besides the two common mutations exon 19 deletion and L858R, which together comprise approximately 85% of *EGFR* mutations in NSCLC[1], rare *EGFR* mutations also exist, including point mutations, deletions, and insertions spanning *EGFR* exons 18-25. However, the responsiveness of these uncommon mutations to *EGFR* TKIs has not been well elucidated and attracts increasing interest.

Located within *EGFR* exon 21, L861Q accounts for approximately 3% of *EGFR* mutations in NSCLC[2]. L861Q often exists as a single mutation, while under rare circumstances, it occurs concomitantly with other *EGFR* mutations (mostly with G719X)[3]. *Post hoc* analysis of LUX lung trials showed a response rate of 56% and a median progression-free survival (PFS) of 8.2 mo for afatinib treatment in L861Q mutant positive patients[4], which ultimately drove the Food and Drug Administration approval for afatinib for NSCLC harboring this mutation. L833F, a more rare *EGFR* mutation, has only been reported in a few cases[5]. The therapeutic relevance of L833F remains largely unknown.

In the present study, we describe a stage IV NSCLC patient harboring a rare *EGFR* L833F-L861Q compound mutation *in cis*, who benefited from osimertinib after progressing on afatinib treatment and multiple lines of chemotherapy.

CASE PRESENTATION

Chief complaints

A 55-year-old man with a 30-year smoking history (1 pack/d) was admitted to our hospital with the chief complaint of a hoarse voice.

History of present illness

The patient's symptoms started 3 mo ago.

History of past illness

The patient denied any history of present illness.

Personal and family history

No personal or family history was reported.

Physical examination

Physical examination indicated a performance status score of 1.

Laboratory examinations

Laboratory examinations revealed elevated serum carcinoembryonic antigen (CEA) and soluble fragment of cytokeratin 19 (CYFRA21-1) levels.

Imaging examinations

A chest computerized tomography (CT) scan detected a space-occupying lesion on the left lung (Figure 1A) in September 2018. Brain magnetic resonance imaging (MRI) suggested multiple brain metastases. Bone metastasis was not detected.

FINAL DIAGNOSIS

Histopathological test of the percutaneous lung puncture biopsy specimen indicated adenocarcinoma. Amplification refractory mutation system polymerase chain reaction (ARMS-PCR) with the biopsied tissue identified an *EGFR* L861Q mutation. The patient was diagnosed with stage IV (T1N2M1c) lung adenocarcinoma.

TREATMENT

The patient's treatment history is summarized in Figure 2A. The patient started first-line treatment with afatinib (40 mg qd) in October 2018. Three months later, a chest CT scan showed shrinkage of the lung lesion (from 4 cm to 2.8 cm in diameter, Figure 1B) and a partial response (PR) was evaluated according to the Response Evaluation Criteria in Solid Tumors 1.1 (RECIST 1.1). In August 2019, the lung lesion remained as PR but brain MRI revealed a progressive disease (PD) on the right occipital lobe lesion (Figure 1C). The patient received MRI-guided brain stereotactic radiosurgery in August and September 2019. Disease progression was observed on brain lesions in October 2019 when the lung lesion remained stable. He subsequently underwent a combined treatment of afatinib (40 mg qd) and bevacizumab (15 mg/kg) but brain metastases progressed rapidly. Next-generation sequencing (NGS) was performed with the re-biopsy of lung lesion at PD using a capture-based panel including 168-cancer related genes (Burning Rock Biotech, Guangzhou, Guangdong Province, China) and identified *EGFR* L833F (allele frequency: 43.02%) *in cis* with L861Q (allele frequency: 40.77%) (Figure 2B). *TP53* L194_I195delinsV and *CCNE1* amplification (copy number: 9.2) were also detected. From December 2019, the patient received six cycles of bevacizumab + pemetrexed + carboplatin (BAC) chemotherapy and achieved stable disease (SD) with a PFS of 4 mo. After PD, he was switched to docetaxel for four cycles (cycle 1: 140 mg d1; cycles 2-4: 110 mg d1 q3w) and brain lesions progressed. In May 2020, a regimen of docetaxel (110 mg d1) and bevacizumab (15 mg/kg) was administrated and a PD was observed (Figure 3A). Starting from June 2020, the patient received the combinatorial treatment of osimertinib (160 mg, qd) and bevacizumab (15 mg/kg).

OUTCOME AND FOLLOW-UP

After two cycles of treatment, the patient achieved shrinkage on the lung lesion which was evaluated as SD and brain lesions were stable (Figure 3B). The disease remained stable until the last flow-up in September 2020 (Figure 3C). The patient passed away in October 2020. He achieved a PFS of more than 3 mo and an overall survival of 25 mo.

DISCUSSION

In the present case, NGS detected an L833F-L861Q compound mutation *in cis* after afatinib failure. However, according to the two allele frequencies (Figure 2B), it is

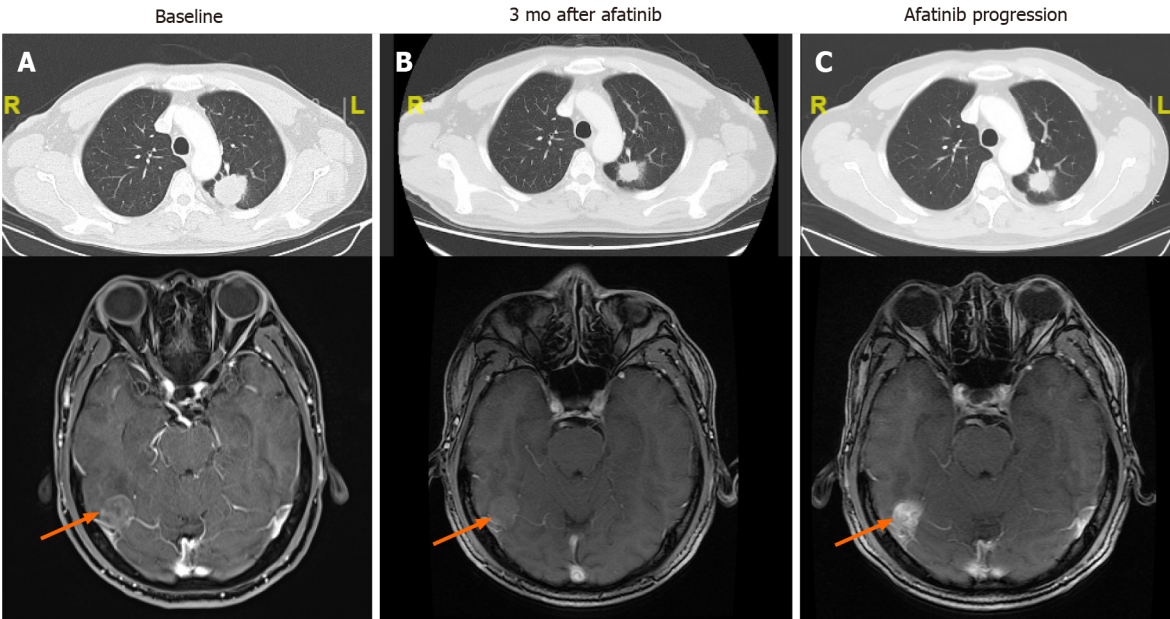


Figure 1 Responses of lung and brain lesions to afatinib. A: Baseline before treatment; B: After 3 mo of afatinib treatment: Lung lesion responded partially and brain lesion was stable; C: After 10 mo of afatinib treatment: Lung lesion remained stable and brain lesion progressed. Only the target brain metastatic lesion was displayed and indicated by the orange arrow.

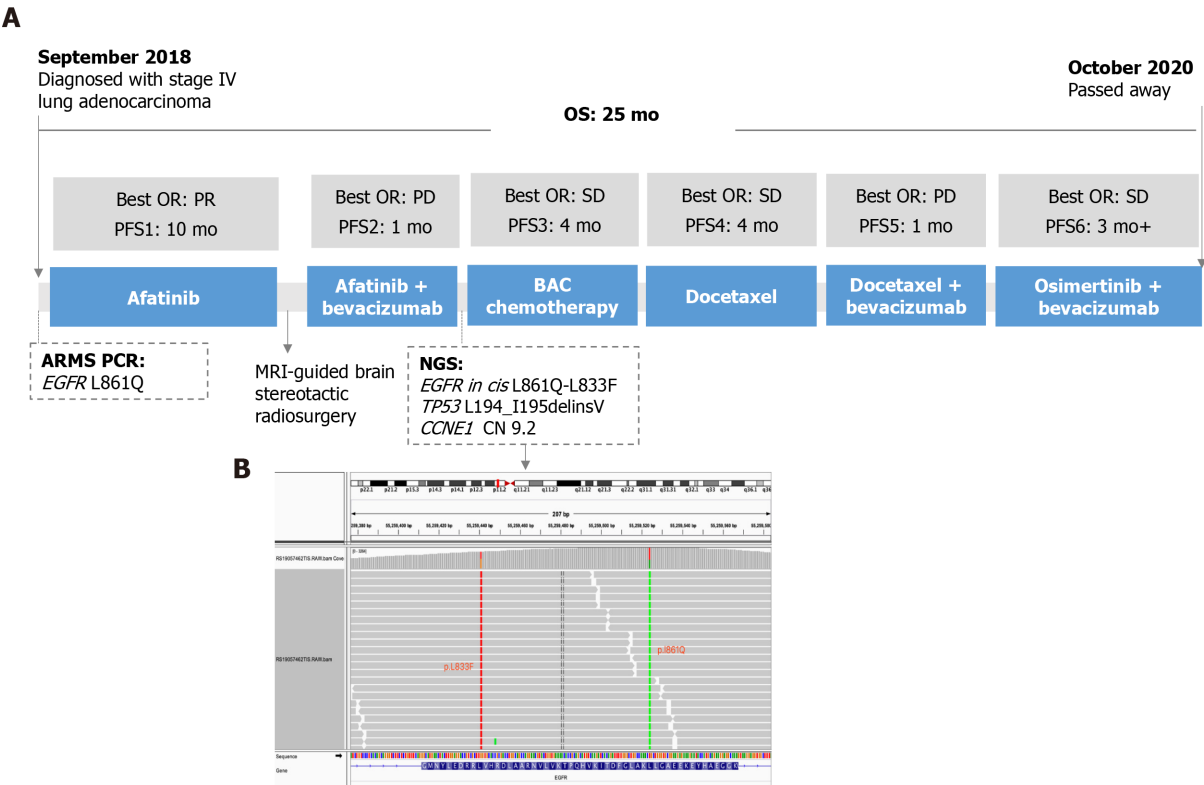

Figure 2 Treatment history and timeline of the patient's best objective response. A: Treatment history and timeline; B: Illustration of epidermal growth factor receptor L833F mutation *in cis* with L861Q mutation. BAC: Bevacizumab + pemetrexed + carboplatin; ARMS PCR: Amplification refractory mutation system polymerase chain reaction; NGS: Next generation sequencing; PFS: Progression-free survival; OS: Overall survival; EGFR: Epidermal growth factor receptor; SD: Stable disease; PD: Progressive disease.

deduced that this compound mutation actually presented at baseline before afatinib treatment, which ARMS-PCR failed to detect. The results support the advantage of NGS over PCR-based methods for detecting more complex mutations. PCR can only detect known mutations and those for which the PCR primers are designed, while NGS is able to simultaneously identify multiple mutations including unknown ones

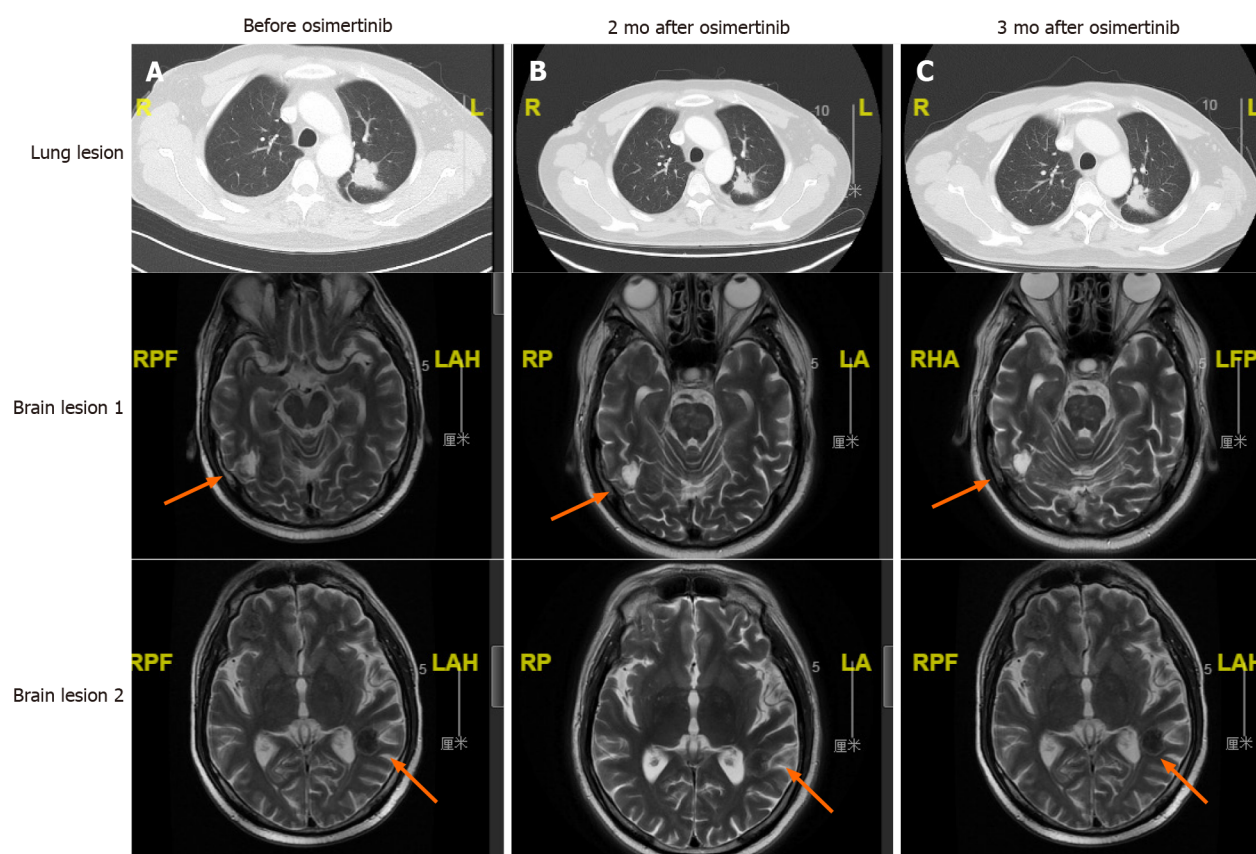


Figure 3 Responses of lung and brain lesions to osimertinib + bevacizumab regimen. A: At docetaxel + bevacizumab failure, before osimertinib treatment; B: 2 mo after treatment initiation, both lung and brain lesions were stable; C: 3 mo after treatment, both lesions remained stable. RAH: Right/anterior/head; RPF: Right/posterior/feet; RP: Right/posterior; LA: Left/anterior; RHA: Right/head/anterior; LFP: Left/feet/posterior.

and reveal the configuration in the case that mutations are present within one sequencing read. NGS can also detect some structure rearrangements that might also serve as therapeutic targets for patients (ALK, RET fusion, *etc.*). Therefore, NGS is strongly recommended if conventional methods fail to detect any actionable alterations.

Our case demonstrated a durable response of 10 mo to first-line treatment with afatinib, suggesting the clinical activity of this TKI against the rare compound mutation L833F-L861Q. In line with our observation, a pooled analysis revealed that afatinib resulted in an objective response rate (ORR) of 77.1% and a median time to treatment failure (TTF) of 14.7 mo [95% confidence interval (CI): 6.8-18.5 mo] in EGFR TKI-naïve patients harboring compound mutations[6]. A recent retrospective study also shows that afatinib is associated with a more favorable PFS compared with gefitinib [hazard ratio (HR) = 2.01; 95%CI: 1.11-3.62] and erlotinib [HR = 2.61; 95%CI: 1.31-5.22] in patients with *EGFR* compound mutations[7]. Especially in those with uncommon patterns (without 19 deletion and L858R), afatinib yielded a higher response rate (afatinib *vs* gefitinib *vs* erlotinib: 78.9% *vs* 38.9% *vs* 20.0%, $P = 0.013$) and significantly longer PFS (afatinib *vs* gefitinib *vs* erlotinib: 10.5 mo *vs* 3.0 mo *vs* 0.9 mo).

Li *et al*[5] reported a stage IV lung adenocarcinoma patient harboring *EGFR* L833F-L861R compound mutation, who achieved a PFS of 193 d to gefitinib treatment. In another study, icotinib resulted in a 0% response rate and a 100% disease control rate in L833F positive NSCLC patients with a median PFS of 4.2 mo[8]. An *in vivo* study has shown that L861Q retains sensitivity to both afatinib and osimertinib[2]. In a phase II trial (KCSG-LU15-09) to investigate osimertinib efficacy in NSCLCs with uncommon *EGFR* mutations, the ORR and median PFS were 78% and 15.2 mo, respectively, in the nine L861Q-positive patients (7 with L861Q single mutation and 2 with L861Q-G719X compound mutation)

A recent retrospective study recruiting 51 NSCLC patients with uncommon *EGFR* mutations (including 2 with L833F-L861Q) showed a median time of 7.1 mo on osimertinib treatment. However, the detailed clinical outcomes of the two L833F-L861Q positive patients were not described[9]. In our case, the L833F-L861Q mutant patient achieved SD on the osimertinib + bevacizumab regimen. Of note, our case had

brain metastases and was heavily pre-treated. This might in part explain the short duration of effectiveness of the osimertinib regimen.

CONCLUSION

In conclusion, our case revealed that both afatinib and the osimertinib + bevacizumab combination demonstrated clinical efficacy in NSCLC harboring an *EGFR* L833F-L861Q compound mutation. The results provide more options for the clinical management of patients with rare compound mutations.

REFERENCES

- 1 **Harrison PT**, Vyse S, Huang PH. Rare epidermal growth factor receptor (EGFR) mutations in non-small cell lung cancer. *Semin Cancer Biol* 2020; **61**: 167-179 [PMID: [31562956](#) DOI: [10.1016/j.semcancer.2019.09.015](#)]
- 2 **Banno E**, Togashi Y, Nakamura Y, Chiba M, Kobayashi Y, Hayashi H, Terashima M, de Velasco MA, Sakai K, Fujita Y, Mitsudomi T, Nishio K. Sensitivities to various epidermal growth factor receptor-tyrosine kinase inhibitors of uncommon epidermal growth factor receptor mutations L861Q and S768I: What is the optimal epidermal growth factor receptor-tyrosine kinase inhibitor? *Cancer Sci* 2016; **107**: 1134-1140 [PMID: [27240419](#) DOI: [10.1111/cas.12980](#)]
- 3 **Cho JH**, Lim SH, An HJ, Kim KH, Park KU, Kang EJ, Choi YH, Ahn MS, Lee MH, Sun JM, Lee SH, Ahn JS, Park K, Ahn MJ. Osimertinib for Patients With Non-Small-Cell Lung Cancer Harboring Uncommon EGFR Mutations: A Multicenter, Open-Label, Phase II Trial (KCSG-LU15-09). *J Clin Oncol* 2020; **38**: 488-495 [PMID: [31825714](#) DOI: [10.1200/JCO.19.00931](#)]
- 4 **Wood DE**, Kazerooni E, Baum SL, Dransfield MT, Eapen GA, Ettinger DS, Hou L, Jackman DM, Klippenstein D, Kumar R, Lackner RP, Leard LE, Leung AN, Makani SS, Massion PP, Meyers BF, Otterson GA, Peairs K, Pipavath S, Pratt-Pozo C, Reddy C, Reid ME, Rotter AJ, Sachs PB, Schabath MB, Sequist LV, Tong BC, Travis WD, Yang SC, Gregory KM, Hughes M; National comprehensive cancer network. Lung cancer screening, version 1.2015: featured updates to the NCCN guidelines. *J Natl Compr Canc Netw* 2015; **13**: 23-34; quiz 34 [PMID: [25583767](#) DOI: [10.6004/jnccn.2015.0006](#)]
- 5 **Li M**, Zhou CZ, Yang JJ, Lu S, Zheng D, Hu J, Zeng H, Lu Y, Lu KH, Li SA, Mao XR, Han-Zhang H, Lizaso A, Ye JY, Hu CP. The *in cis* compound *EGFR* mutations in Chinese advanced non-small cell lung cancer patients. *Cancer Biol Ther* 2019; **20**: 1097-1104 [PMID: [30990107](#) DOI: [10.1080/15384047.2019.1595280](#)]
- 6 **Yang JC**, Schuler M, Popat S, Miura S, Heeke S, Park K, Märten A, Kim ES. Afatinib for the Treatment of NSCLC Harboring Uncommon EGFR Mutations: A Database of 693 Cases. *J Thorac Oncol* 2020; **15**: 803-815 [PMID: [31931137](#) DOI: [10.1016/j.jtho.2019.12.126](#)]
- 7 **Wu SG**, Yu CJ, Yang JC, Shih JY. The effectiveness of afatinib in patients with lung adenocarcinoma harboring complex epidermal growth factor receptor mutation. *Ther Adv Med Oncol* 2020; **12**: 1758835920946156 [PMID: [32843903](#) DOI: [10.1177/1758835920946156](#)]
- 8 **Xu C**, Wang WX, Fang M, Zhuang W, Lin G, Chen XH, Zhu YC, Du KQ, Huang YI, Xu HP, Chen YP, Chen G, Lv TF, Song Y. Clinical efficacy of icotinib in patients with advanced non-small cell lung cancer harboring EGFR exon 18, 20 and 21 uncommon mutations. *J Clin Oncol* 2017; **35**: e14050-e14050 [DOI: [10.1200/JCO.2017.35.15_suppl.e14050](#)]
- 9 **Ji J**, Aredo JV, Piper-Vallillo A, Huppert L, Rotow JK, Husain H, Stewart SL, Cobb R, Wakelee HA, Blakely CM, Wong ML, Gubens MA, Chen J, Oxnard GR, McCoach CE, Piotrowska Z, Neal JW, Riess JW. Osimertinib in non-small cell lung cancer (NSCLC) with atypical EGFR activating mutations: A retrospective multicenter study. *J Clin Oncol* 2020; **38**: 9570-9570 [DOI: [10.1200/JCO.2020.38.15_suppl.9570](#)]



Published by **Baishideng Publishing Group Inc**
7041 Koll Center Parkway, Suite 160, Pleasanton, CA 94566, USA

Telephone: +1-925-3991568

E-mail: bpgoffice@wjgnet.com

Help Desk: <https://www.f6publishing.com/helpdesk>

<https://www.wjgnet.com>

