

# World Journal of *Clinical Cases*

*World J Clin Cases* 2021 October 6; 9(28): 8280-8626



Contents

Thrice Monthly Volume 9 Number 28 October 6, 2021

REVIEW

- 8280** Transmission of severe acute respiratory syndrome coronavirus 2 via fecal-oral: Current knowledge  
*Silva FAFD, de Brito BB, Santos MLC, Marques HS, da Silva Júnior RT, de Carvalho LS, de Sousa Cruz S, Rocha GR, Santos GLC, de Souza KC, Maciel RGA, Lopes DS, Silva NOE, Oliveira MV, de Melo FF*
- 8295** Nutrition, nutritional deficiencies, and schizophrenia: An association worthy of constant reassessment  
*Onaolapo OJ, Onaolapo AY*

MINIREVIEWS

- 8312** Grounded theory qualitative approach from Foucault's ethical perspective: Deconstruction of patient self-determination in the clinical setting  
*Molina-Mula J*
- 8327** Diabetes mellitus and COVID-19: Understanding the association in light of current evidence  
*Sen S, Chakraborty R, Kalita P, Pathak MP*

ORIGINAL ARTICLE

Case Control Study

- 8340** Pregnancy complications effect on the nickel content in maternal blood, placenta blood and umbilical cord blood during pregnancy  
*Ding AL, Hu H, Xu FP, Liu LY, Peng J, Dong XD*

Retrospective Study

- 8349** Clinical observation of Kuntai capsule combined with Fenmotong in treatment of decline of ovarian reserve function  
*Lin XM, Chen M, Wang QL, Ye XM, Chen HF*
- 8358** Short-term effect and long-term prognosis of neuroendoscopic minimally invasive surgery for hypertensive intracerebral hemorrhage  
*Wei JH, Tian YN, Zhang YZ, Wang XJ, Guo H, Mao JH*
- 8366** Ultrasonographic assessment of cardiac function and disease severity in coronary heart disease  
*Zhang JF, Du YH, Hu HY, Han XQ*
- 8374** COVID-19 among African Americans and Hispanics: Does gastrointestinal symptoms impact the outcome?  
*Ashktorab H, Folake A, Pizuorno A, Oskrochi G, Oppong-Twene P, Tamanna N, Mehdipour Dalivand M, Umeh LN, Moon ES, Kone AM, Banson A, Federman C, Ramos E, Awoyemi EO, Wonni BJ, Otto E, Maskalo G, Velez AO, Rankine S, Thrift C, Ekwunazu C, Scholes D, Chirumamilla LG, Ibrahim ME, Mitchell B, Ross J, Curtis J, Kim R, Gilliard C, Mathew J, Laiyemo A, Kibreab A, Lee E, Sherif Z, Shokrani B, Aduli F, Brim H*

**Observational Study**

- 8388** Validated tool for early prediction of intensive care unit admission in COVID-19 patients  
*Huang HF, Liu Y, Li JX, Dong H, Gao S, Huang ZY, Fu SZ, Yang LY, Lu HZ, Xia LY, Cao S, Gao Y, Yu XX*
- 8404** Comparison of the impact of endoscopic retrograde cholangiopancreatography between pre-COVID-19 and current COVID-19 outbreaks in South Korea: Retrospective survey  
*Kim KH, Kim SB*

**Randomized Controlled Trial**

- 8413** Effect of family caregiver nursing education on patients with rheumatoid arthritis and its impact factors: A randomized controlled trial  
*Li J, Zhang Y, Kang YJ, Ma N*

**SYSTEMATIC REVIEWS**

- 8425** Dealing with hepatic artery traumas: A clinical literature review  
*Dilek ON, Atay A*
- 8441** Clinical considerations for critically ill COVID-19 cancer patients: A systematic review  
*Ramasamy C, Mishra AK, John KJ, Lal A*

**CASE REPORT**

- 8453** Atypical granular cell tumor of the urinary bladder: A case report  
*Wei MZ, Yan ZJ, Jiang JH, Jia XL*
- 8461** Hepatocyte nuclear factor 1B mutation in a Chinese family with renal cysts and diabetes syndrome: A case report  
*Xiao TL, Zhang J, Liu L, Zhang B*
- 8470** Ultrasound features of primary non-Hodgkin's lymphoma of the palatine tonsil: A case report  
*Jiang R, Zhang HM, Wang LY, Pian LP, Cui XW*
- 8476** Percutaneous drainage in the treatment of intrahepatic pancreatic pseudocyst with Budd-Chiari syndrome: A case report  
*Zhu G, Peng YS, Fang C, Yang XL, Li B*
- 8482** Postmenopausal women with hyperandrogenemia: Three case reports  
*Zhu XD, Zhou LY, Jiang J, Jiang TA*
- 8492** Extremely high titer of hepatitis B surface antigen antibodies in a primary hepatocellular carcinoma patient: A case report  
*Han JJ, Chen Y, Nan YC, Yang YL*
- 8498** Surgical treatment of liver metastasis with uveal melanoma: A case report  
*Kim YH, Choi NK*

- 8504** Intermittent appearance of right coronary fistula and collateral circulation: A case report  
*Long WJ, Huang X, Lu YH, Huang HM, Li GW, Wang X, He ZL*
- 8509** Synchronous concomitant pancreatic acinar cell carcin and gastric adenocarcinoma: A case report and review of literature  
*Fang T, Liang TT, Wang YZ, Wu HT, Liu SH, Wang C*
- 8518** Spontaneous resolution of gallbladder hematoma in blunt traumatic injury: A case report  
*Jang H, Park CH, Park Y, Jeong E, Lee N, Kim J, Jo Y*
- 8524** Rupture of ovarian endometriotic cyst complicated with endometriosis: A case report  
*Wang L, Jiang YJ*
- 8531** Rotarex mechanical thrombectomy in renal artery thrombosis: A case report  
*Li WR, Liu MY, Chen XM, Zhang ZW*
- 8537** Necrotizing fasciitis of cryptoglandular infection treated with multiple incisions and thread-dragging therapy: A case report  
*Tao XC, Hu DC, Yin LX, Wang C, Lu JG*
- 8545** Endoscopic joint capsule and articular process excision to treat lumbar facet joint syndrome: A case report  
*Yuan HJ, Wang CY, Wang YF*
- 8552** Spinocerebellar ataxia type 3 with dopamine-responsive dystonia: A case report  
*Zhang XL, Li XB, Cheng FF, Liu SL, Ni WC, Tang FF, Wang QG, Wang XQ*
- 8557** Disseminated soft tissue diffuse large B-cell lymphoma involving multiple abdominal wall muscles: A case report  
*Lee CH, Jeon SY, Yhim HY, Kwak JY*
- 8563** Genetic characteristics of a patient with multiple primary cancers: A case report  
*Ouyang WW, Li QY, Yang WG, Su SF, Wu LJ, Yang Y, Lu B*
- 8571** Hypereosinophilia with cerebral venous sinus thrombosis and intracerebral hemorrhage: A case report and review of the literature  
*Song XH, Xu T, Zhao GH*
- 8579** Itraconazole therapy for infant hemangioma: Two case reports  
*Liu Z, Lv S, Wang S, Qu SM, Zhang GY, Lin YT, Yang L, Li FQ*
- 8587** One-stage total hip arthroplasty for advanced hip tuberculosis combined with developmental dysplasia of the hip: A case report  
*Zhu RT, Shen LP, Chen LL, Jin G, Jiang HT*
- 8595** *Pneumocystis jirovecii* and *Legionella pneumophila* coinfection in a patient with diffuse large B-cell lymphoma: A case report  
*Wu WH, Hui TC, Wu QQ, Xu CA, Zhou ZW, Wang SH, Zheng W, Yin QQ, Li X, Pan HY*

- 8602** Delayed massive cerebral infarction after perioperative period of anterior cervical discectomy and fusion: A case report  
*Jia F, Du CC, Liu XG*
- 8609** Cortical bone trajectory fixation in cemented vertebrae in lumbar degenerative disease: A case report  
*Chen MM, Jia P, Tang H*
- 8616** Primary intramedullary melanocytoma presenting with lower limbs, defecation, and erectile dysfunction: A case report and review of the literature  
*Liu ZQ, Liu C, Fu JX, He YQ, Wang Y, Huang TX*

**ABOUT COVER**

Editorial Board Member of *World Journal of Clinical Cases*, Domenico De Berardis, MD, PhD, Adjunct Professor, Chief Doctor, NHS, Department of Mental Health, Teramo 64100, Italy. domenico.deberardis@aslteramo.it

**AIMS AND SCOPE**

The primary aim of *World Journal of Clinical Cases* (WJCC, *World J Clin Cases*) is to provide scholars and readers from various fields of clinical medicine with a platform to publish high-quality clinical research articles and communicate their research findings online.

WJCC mainly publishes articles reporting research results and findings obtained in the field of clinical medicine and covering a wide range of topics, including case control studies, retrospective cohort studies, retrospective studies, clinical trials studies, observational studies, prospective studies, randomized controlled trials, randomized clinical trials, systematic reviews, meta-analysis, and case reports.

**INDEXING/ABSTRACTING**

The WJCC is now indexed in Science Citation Index Expanded (also known as SciSearch®), Journal Citation Reports/Science Edition, Scopus, PubMed, and PubMed Central. The 2021 Edition of Journal Citation Reports® cites the 2020 impact factor (IF) for WJCC as 1.337; IF without journal self cites: 1.301; 5-year IF: 1.742; Journal Citation Indicator: 0.33; Ranking: 119 among 169 journals in medicine, general and internal; and Quartile category: Q3. The WJCC's CiteScore for 2020 is 0.8 and Scopus CiteScore rank 2020: General Medicine is 493/793.

**RESPONSIBLE EDITORS FOR THIS ISSUE**

Production Editor: Yan-Xia Xing; Production Department Director: Yun-Jie Ma; Editorial Office Director: Jin-Lei Wang.

**NAME OF JOURNAL**

*World Journal of Clinical Cases*

**ISSN**

ISSN 2307-8960 (online)

**LAUNCH DATE**

April 16, 2013

**FREQUENCY**

Thrice Monthly

**EDITORS-IN-CHIEF**

Dennis A Bloomfield, Sandro Vento, Bao-Gan Peng

**EDITORIAL BOARD MEMBERS**

<https://www.wjgnet.com/2307-8960/editorialboard.htm>

**PUBLICATION DATE**

October 6, 2021

**COPYRIGHT**

© 2021 Baishideng Publishing Group Inc

**INSTRUCTIONS TO AUTHORS**

<https://www.wjgnet.com/bpg/gerinfo/204>

**GUIDELINES FOR ETHICS DOCUMENTS**

<https://www.wjgnet.com/bpg/GerInfo/287>

**GUIDELINES FOR NON-NATIVE SPEAKERS OF ENGLISH**

<https://www.wjgnet.com/bpg/gerinfo/240>

**PUBLICATION ETHICS**

<https://www.wjgnet.com/bpg/GerInfo/288>

**PUBLICATION MISCONDUCT**

<https://www.wjgnet.com/bpg/gerinfo/208>

**ARTICLE PROCESSING CHARGE**

<https://www.wjgnet.com/bpg/gerinfo/242>

**STEPS FOR SUBMITTING MANUSCRIPTS**

<https://www.wjgnet.com/bpg/GerInfo/239>

**ONLINE SUBMISSION**

<https://www.f6publishing.com>



## One-stage total hip arthroplasty for advanced hip tuberculosis combined with developmental dysplasia of the hip: A case report

Rang-Teng Zhu, Li-Ping Shen, Ling-Lin Chen, Gang Jin, Han-Tao Jiang

**ORCID number:** Rang-Teng Zhu 0000-0002-5651-1454; Li-Ping Shen 0000-0001-5092-0241; Ling-Lin Chen 0000-0002-4733-8848; Gang Jin 0000-0002-5622-3321; Han-Tao Jiang 0000-0002-7928-264X.

**Author contributions:** Zhu RT performed the surgery and wrote the manuscript; Shen LP performed the laboratory tests on the patient; Chen LL performed the pathological examination on the patient; Jin G followed up the patient and prepared the manuscript; Jiang HT contributed to the conception of the study.

**Supported by** Basic Public Welfare Research Project of Zhejiang Province, No. GF20H200021; and Luqiao Science and Technology Bureau Foundation, No. 2019A23005.

**Informed consent statement:** The informed consent was obtained from the patient.

**Conflict-of-interest statement:** We declare that we do not have any commercial or associative interest that represents a conflict of interest in connection with the work submitted.

**CARE Checklist (2016) statement:** The authors have read the CARE Checklist (2016), and the manuscript was prepared and

**Rang-Teng Zhu, Gang Jin, Han-Tao Jiang,** Department of Orthopedics, Taizhou Hospital of Zhejiang Province Affiliated to Wenzhou Medical University, Taizhou 317000, Zhejiang Province, China

**Rang-Teng Zhu, Gang Jin, Han-Tao Jiang,** Department of Orthopedics, Enze Hospital, Taizhou Enze Medical Center (Group), Taizhou 318000, Zhejiang Province, China

**Li-Ping Shen,** Clinical Laboratory, Taizhou Hospital of Zhejiang Province affiliated to Wenzhou Medical University, Taizhou 317000, Zhejiang Province, China

**Li-Ping Shen,** Clinical Laboratory, Enze Hospital, Taizhou Enze Medical Center (Group), Taizhou 318000, Zhejiang Province, China

**Ling-Lin Chen,** Department of Pathology, Taizhou Hospital of Zhejiang Province affiliated to Wenzhou Medical University, Taizhou 317000, Zhejiang Province, China

**Ling-Lin Chen,** Department of Pathology, Enze Hospital, Taizhou Enze Medical Center (Group), Taizhou 318000, Zhejiang Province, China

**Corresponding author:** Han-Tao Jiang, MA, Attending Doctor, Department of Orthopedics, Taizhou Hospital of Zhejiang Province Affiliated to Wenzhou Medical University, No. 150 Ximen Street, Linhai City, Taizhou 317000, Zhejiang Province, China.  
[jianght5652@enzemed.com](mailto:jianght5652@enzemed.com)

### Abstract

#### BACKGROUND

A patient with advanced tuberculosis of the hip joint combined with Crowe type IV developmental dysplasia of the hip (DDH) and a drainage sinus is a rare condition. There are no previous reports of this condition, and it is a complex challenge for surgeons to develop a treatment scheme.

#### CASE SUMMARY

We report a 73-year-old male patient with severe hip pain and drainage sinus of the left hip for one month. Approximately 40 years ago, a drainage sinus occurred at the lateral left hip was healed at the local hospital with anti-infectious therapy. After the sinus healed, gradual pain occurred in the left hip for 40 years. Approximately one month prior, hip pain was sharply aggravated, and a drainage sinus reoccurred in the left hip. The X-ray and computed tomography examinations showed destruction of the head and neck of the left femur, as well as an

revised according to the CARE Checklist (2016).

**Open-Access:** This article is an open-access article that was selected by an in-house editor and fully peer-reviewed by external reviewers. It is distributed in accordance with the Creative Commons Attribution NonCommercial (CC BY-NC 4.0) license, which permits others to distribute, remix, adapt, build upon this work non-commercially, and license their derivative works on different terms, provided the original work is properly cited and the use is non-commercial. See: <http://creativecommons.org/licenses/by-nc/4.0/>

**Manuscript source:** Unsolicited manuscript

**Specialty type:** Orthopedics

**Country/Territory of origin:** China

**Peer-review report's scientific quality classification**

Grade A (Excellent): 0  
Grade B (Very good): B  
Grade C (Good): 0  
Grade D (Fair): 0  
Grade E (Poor): 0

**Received:** May 25, 2021

**Peer-review started:** May 25, 2021

**First decision:** June 25, 2021

**Revised:** July 3, 2021

**Accepted:** August 12, 2021

**Article in press:** August 12, 2021

**Published online:** October 6, 2021

**P-Reviewer:** Yiğit Ş

**S-Editor:** Liu M

**L-Editor:** A

**P-Editor:** Zhang YL



acetabular deformity. The results of *Mycobacterium tuberculosis* antibody and Xpert were positive. Therefore, the patient was diagnosed with advanced TH combined with Crowe type IV DDH. After 22 d of treatment with anti-tuberculosis chemotherapy, the sinus healed, and the patient underwent one-stage total hip arthroplasty (THA) surgery consisting of debridement, osteotomy, and joint replacement. After surgery, the patient received anti-tuberculosis chemotherapy drugs for nine months, with no recurrent infection. After one year of follow-up, the Harris score of the patient increased from 21 pre-THA to 86.

## CONCLUSION

Although drainage sinuses are a contraindication to one-stage THA, one-stage THA is still an effective and safe surgical method after the sinus heals.

**Key Words:** Advanced tuberculosis of the hip joint; Developmental dysplasia of the hip; Total hip arthroplasty; Drainage sinus; Anti-tuberculosis treatment; Case report

©The Author(s) 2021. Published by Baishideng Publishing Group Inc. All rights reserved.

**Core Tip:** We report a 73-year-old male patient with severe hip pain and drainage sinus of the left hip for one month. The X-ray and computed tomography examinations showed destruction of the head and neck of the left femur, as well as an acetabular deformity. The results of *Mycobacterium tuberculosis* antibody and Xpert were positive. Therefore, the patient was diagnosed with advanced tuberculosis hip combined with Crowe type IV Developmental dysplasia of the hip. After 22 d of treatment with anti-tuberculosis chemotherapy, the sinus healed, and the patient underwent one-stage total hip arthroplasty surgery. After surgery, the patient received anti-tuberculosis chemotherapy drugs for nine months, with no recurrent infection.

**Citation:** Zhu RT, Shen LP, Chen LL, Jin G, Jiang HT. One-stage total hip arthroplasty for advanced hip tuberculosis combined with developmental dysplasia of the hip: A case report. *World J Clin Cases* 2021; 9(28): 8587-8594

**URL:** <https://www.wjgnet.com/2307-8960/full/v9/i28/8587.htm>

**DOI:** <https://dx.doi.org/10.12998/wjcc.v9.i28.8587>

## INTRODUCTION

Tuberculosis of the hip joint (TH) is a severe osteoarticular tuberculosis and always results in cartilage and bone destruction, causing pain, deformity, shortening, and instability[1]. In its early stages, symptoms and imaging changes are not typical, and the diagnosis is easily missed[2]. When severe hip bone destruction occurs, TH has reached advanced stages[1]. Total hip arthroplasty (THA) is always considered the preferred treatment option for advanced TH, which could provide a painless stable joint with normal gait and is generally divided into two-stage THA and one-stage THA[3]. Although two-stage THA achieves satisfactory clinical efficacy for treating advanced TH[4], the second-step replacement surgery must be performed several months after debridement, leading to poor joint mobility (even stiffness) and muscle atrophy, increasing the difficulty of the whole treatment procedure[5]. Therefore, surgeons prefer to choose one-stage THA that could attain satisfactory clinical efficacy and effectively shorten the treatment time[6], except for the presence of a drainage sinus, which is a contraindication to one-stage THA[7].

When the patient was admitted to our department for severe hip pain and a drainage sinus, we diagnosed advanced TH with Crowe type IV DDH of his left hip through a thorough examination. It was difficult for us to develop a suitable treatment scheme that could improve the function of the patient's TH and prevent tuberculosis. Although the patient was not qualified for one-stage THA because of sinus drainage, the first step of radical debridement and cement spacer implantation could destroy the pseudarthrosis between the ilium ala and proximal femur. If so, the stability of the left hip would be destroyed, and the patient would have to be confined to bed for at least three months, which could be fatal for the senior patient because of the severe complica-

ations resulting from bed rest.

Unfortunately, there is no previous literature or report teaching us how to develop a suitable scheme. Considering the probable serious complications of two-stage THA and improving joint function, we finally decided to carry out a one-stage THA consisting of debridement, osteotomy, and THA. In this report, we introduced our treatment plan in detail and showed the complications and recovery conditions of the patient in total.

---

## CASE PRESENTATION

---

### **Chief complaints**

A 73-year-old male patient was admitted to our department for a drainage sinus at the lateral skin surface of the left hip combined with severe joint pain.

### **History of present illness**

The sinus occurred lateral to the left hip 40 years ago and healed with anti-infective treatment and debridement at the local hospital. One month prior, the left hip pain was exacerbated and the sinus reoccurred. After ineffective anti-infective therapy (levofloxacin and ceftazidime) at the local hospital, the patient presented to our department.

### **History of past illness**

The patient was diagnosed with tuberculosis more than 40 years ago and has been cured in a local hospital.

### **Personal and family history**

The patient denied any other specific personal or family history of other disease.

### **Physical examination**

The physical examination showed plenty of fresh granulation tissue in a drainage sinus (Figure 1A). The patient had severe hip pain and was unable to move actively or passively. The left lower limb was approximately 3 cm shorter than the right lower limb. The patient could walk on the ground with the help of a crutch by himself. The Harris score of the patient's left hip was 21.

### **Laboratory examinations**

At the time of admission, the erythrocyte sedimentation rate (ESR) was 49 mm/h, and the C-reactive protein (CRP) level was 12.12 mg/L. Although a *Mycobacterium tuberculosis* smear was negative, we diagnosed the patient with TH according to both positive *Mycobacterium tuberculosis* antibody and Xpert results.

### **Imaging examinations**

The preoperative X-ray (Figure 2A) and computed tomography (Figure 2B and C) showed heavy destruction of the left femoral head and neck, pseudarthrosis between the proximal femur and iliac ala, and a smaller and more shallow original acetabulum. The preoperative magnetic resonance (Figure 2D and E) showed a slender localized sinus and no infective foci in the pelvic cavity.

---

## FINAL DIAGNOSIS

---

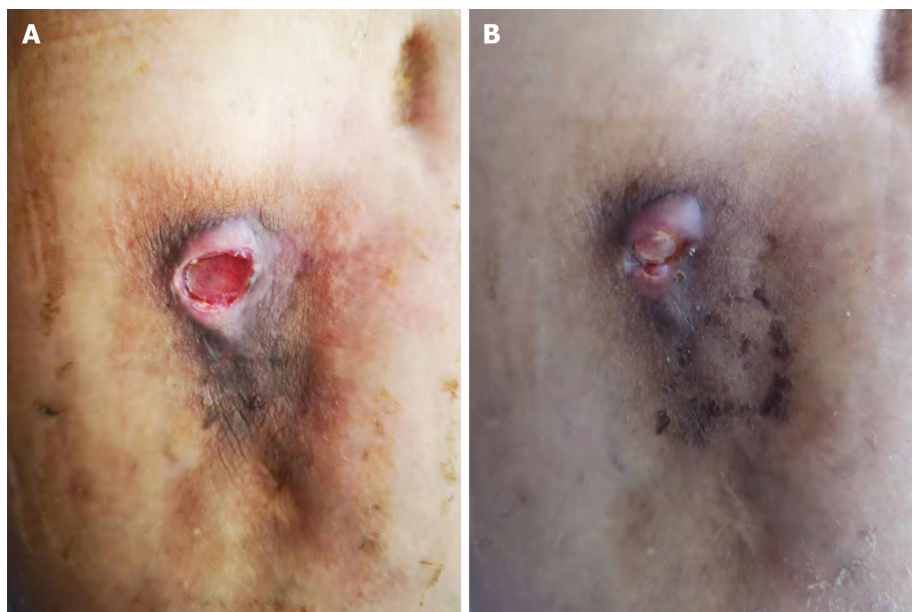
The patient was eventually diagnosed with advanced tuberculosis of the hip combined with Crowe type IV developmental dysplasia of the hip.

---

## TREATMENT

---

After undergoing anti-tuberculosis treatment (isoniazid, rifampin, pyrazinamide, and ethambutol) for 22 d, the sinus was almost healed (Figure 1B). Although a drainage sinus is a contraindication to THA, thinking of the healed sinus and difficulty of cement spacer placement in a severe hip malformation, we decided to carry out a one-stage THA on the patient.



**Figure 1 Performance of the drainage sinus.** A: There was plenty of fresh granulation tissue in a drainage sinus; B: After 22 d of anti-tuberculosis chemotherapy treatment, the sinus was almost healed.

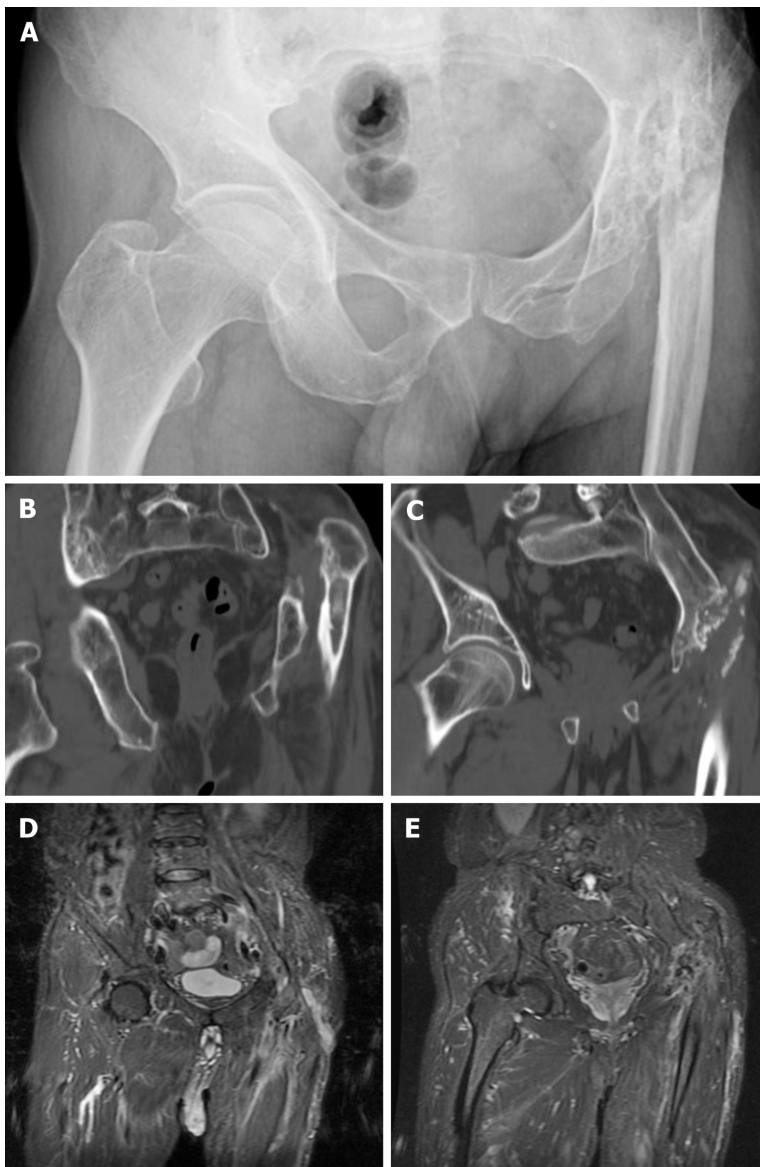
At the beginning of the operation process, the sinus was excised entirely, and sinus tissue was obtained to investigate histological changes. The intraoperative rapid pathological diagnosis showed no apparent active infection (Figure 3A). The operating field revealed complete necrosis of the gluteus maximus and gluteus medius, disappearance of the left femoral head and neck, partial structural destruction of the iliac crest, and apparent upward movement of the proximal femur. The lesion tissue was entirely excised with bone forceps, and the destroyed bone of the proximal femur, except the more significant trochanter part, was released with a wire saw. After repeatedly washing the wound with iodophor, hydrogen peroxide, and saline, we changed the operating garment and sterile towel. Then, a subtrochanteric osteotomy was carried out to protect the sciatic nerve by lessening the leg lengthening. Finally, we chose a cementless prosthesis to complete the THA surgery. The postoperative X-ray showed that the prosthesis was in a good position (Figure 4A). The lesion tissue of the left hip was sent to for pathological examination postoperatively, and the result showed evident caseous necrosis (Figure 3B).

Postoperatively, the patient received anti-tuberculosis drugs (isoniazid, rifampicin, pyrazinamide, and ethambutol) and was asked to remain in bed for six weeks after the procedure. Unfortunately, six weeks after surgery, the patient fell when he was walking to the toilet and was sent to our hospital immediately. The X-ray showed periprosthetic fractures, no loss of the prosthesis, and no destruction of the proximal femur (Figure 4B). Therefore, we carried out reduction and internal fixation of the fracture with a plate and wire. During the surgery, there was no loss of the prosthesis or reactive tuberculosis in the surgical field. Three months after internal fixation, the X-ray of the left hip showed no recurrent bone destruction or prosthesis loss (Figure 4C and D).

After internal fixation surgery, the patient continually received anti-tuberculosis chemotherapy (isoniazid, rifampicin, pyrazinamide, and ethambutol) for nine months. Three months after internal fixation surgery, the patient could walk with a crutch, and six months after surgery, he was able to walk independently.

## OUTCOME AND FOLLOW-UP

Eighty-nine days after one-stage THA, the ESR and CRP levels returned to normal, and the tests were negative three times in a row (Figure 5). At 1-year follow-up, the Harris score of the patient was 86.

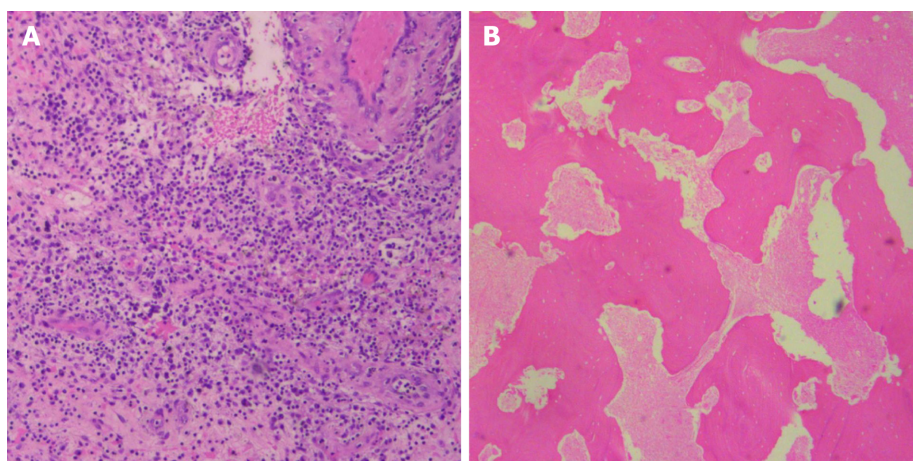


**Figure 2 Preoperative imaging finding.** A: The preoperative X-ray showed heavy destruction of the left femoral head and neck, pseudarthrosis between the proximal femur and iliac ala, and a smaller and shallower original acetabulum; B and C: The preoperative computed tomography showed heavy destruction of the left femoral head and neck, pseudarthrosis between the proximal femur and iliac ala, and a smaller and shallower original acetabulum; D and E: The preoperative magnetic resonance showed a slender form localized sinus and no infective foci in the pelvic cavity.

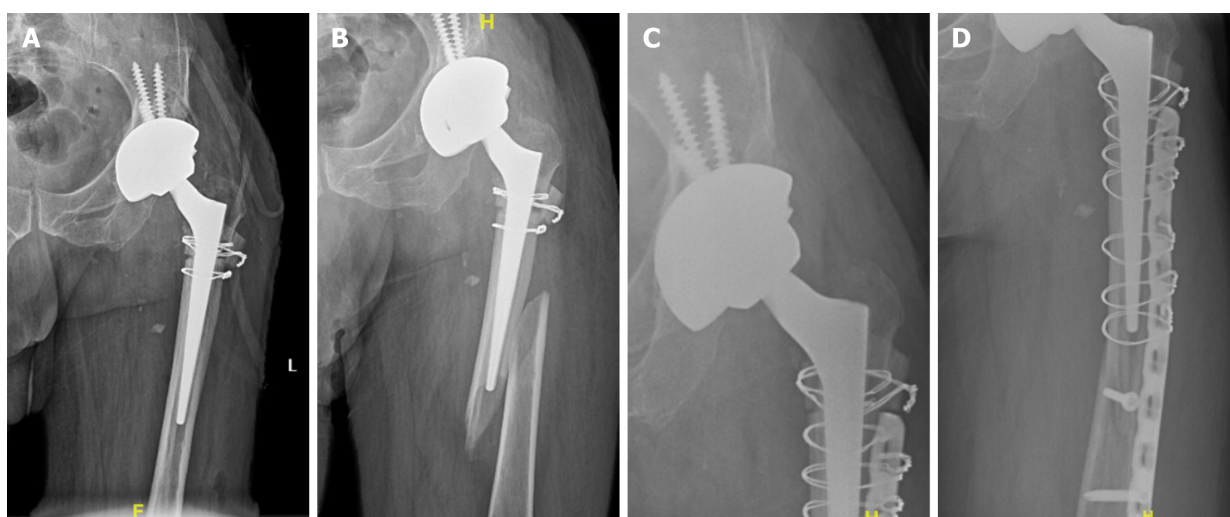## DISCUSSION

This is the first report of a patient with advanced TH with Crowe type IV DDH, especially with a drainage sinus at the affected hip. It was a challenge for us to develop a suitable clinical treatment scheme, preventing tuberculosis recurrence and preserving the function of the joint. We developed a one-stage THA plan through a literature review, including perioperative anti-tuberculosis chemotherapy, intraoperative debridement, and THA. At one-year follow-up, the patient's TH had good function, and the TH did not recur.

There are three treatment options for advanced TH: Excision arthroplasty, arthrodesis, and THA. Excision arthroplasty can offer a painless and mobile hip but finally results in hip instability and abnormal gait[8,9]. Arthrodesis offers a severely dysfunctional hip, back pain, and abnormal gait and is rarely chosen[10]. THA can provide a painless stable joint with normal gait and is generally divided into two forms: One-stage THA and two-stage THA. As a result of joint infectious disease, two-stage THA is the gold standard for treatment[4]. The first step involves radical debridement and implantation of the cement spacer. The second step is carried out after the infection is under control and involves additional debridement and implantation of the metal prosthesis. However, the second step must be performed



**Figure 3 Intraoperative rapid pathology and postoperative pathology.** A: The intraoperative rapid pathological diagnosis showed no apparent active infection; B: The pathological examination of lesion tissue showed evident caseous necrosis.

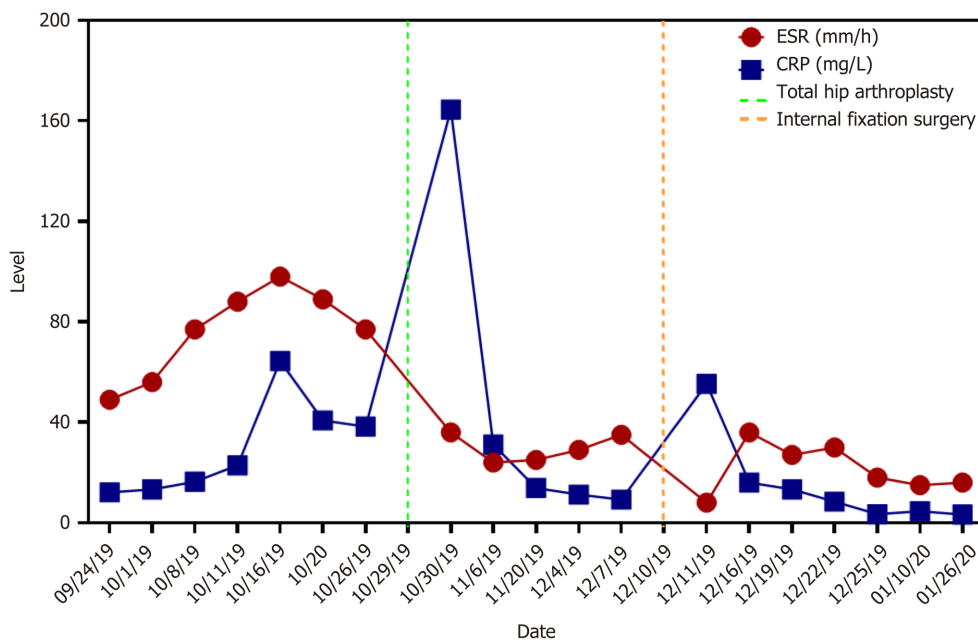


**Figure 4 Postoperative imaging findings.** A: The postoperative X-ray showed that the prosthesis was in a good position; B: The X-ray showed periprosthetic fractures, no loss of the prostheses, and no destruction of the proximal femur; C and D: Three months after internal fixation, the X-ray of the left hip showed no recurrent bone destruction or prosthesis loss.

several months after the first step, resulting in poor joint mobility (even stiffness) and muscle atrophy, increasing the difficulty of the whole treatment procedure[5].

The difference in pathogenic bacteria characteristics between pyogenic pathogens and tuberculosis bacilli creates the conditions for one-stage surgery. Bacteria covered by biofilms have strong resistance to antibiotics and host immune attacks, leading to severe surgical failure[11]. Contrary to common purulent pathogens, tuberculosis bacilli have unique biological characteristics, including slow growth, no adhesion to metal surfaces, and little biofilm formation[11-13]. Furthermore, one-stage surgery with metal implantation for active spinal tuberculosis has been successful[14]. Therefore, an increasing number of surgeons have applied one-stage THA to treat TH and have achieved satisfactory results[6].

In addition, it is not easy to carry out two-stage THA on Crowe type IV DDH[15-17]. After debridement of the affected TH, the pseudarthrosis between the proximal femur and ilium was destroyed, and implantation of an antibiotic-loaded cement spacer could not reconstruct the stability of the affected TH. This may lead to an extended stay in the bed and many complications for patients, such as deep venous thrombosis, myophagism, and pressure sores. Therefore, the one-stage THA method might be the best choice in patients with advance TH combined with Crowe type IV DDH. However, many authors believe that a drainage sinus is a contraindication to one-stage THA, because the drainage sinus is often associated with a mixed infection of other common pyogenic pathogens[4,12,18]. In our report, although a drainage



**Figure 5** The trends of erythrocyte sedimentation rate and a C-reactive protein level showed that erythrocyte sedimentation rate and C-reactive protein returned to normal after 89 d of anti-tuberculosis chemotherapy after one-stage total hip arthroplasty. In addition, the tests were negative three times in a row. ESR: Erythrocyte sedimentation rate; CRP: C-reactive protein.

sinus was lateral to the left hip, when the sinus had healed and intraoperative rapid pathological examination showed no apparent active infection, we believed that it was safe and effective to carry out one-stage THA.

Moreover, regardless of the treatment method, it is essential that standard first-line anti-tuberculosis chemotherapy, including isoniazid, rifampicin, pyrazinamide, and ethambutol, be applied for every patient between 2 wk and 6 wk preoperatively and between 9 mo and 12 mo postoperatively[19,20]. Therefore, after the level of ESR and CRP returned to normal, the patient in our report continued to receive anti-tuberculosis chemotherapy until nine months after one-stage THA.

Finally, through our treatment, the patient could walk by himself six months after internal fixation surgery, and the levels of ESR and CRP returned to normal 89 d after one-stage THA. Meanwhile, the limitation of our study is obvious. First, because of the rarity of similar cases, only one case was too few to demonstrate the effectiveness of our treatment method. Second, the follow-up data in our study were only one year, and it could not prove the long-term effectiveness.

## CONCLUSION

In our opinion, to reduce complications caused by bed rest and reduce mortality, one-stage THA is more suitable for patients with advanced TH combined with Crowe type IV DDH. Moreover, although the drainage sinus was a contraindication for one-stage THA, when the sinus had healed and intraoperative rapid pathological examination showed no apparent active infection, we believed it was safe and effective to carry out one-stage THA.

## REFERENCES

1. Tan SM, Chin PL. Total hip arthroplasty for surgical management of advanced tuberculous hip arthritis: Case report. *World J Orthop* 2015; 6: 316-321 [PMID: 25793173 DOI: 10.5312/wjo.v6.i2.316]
2. Cansü E, Erdogan F, Ulusam AO. Incision infection with *Mycobacterium tuberculosis* after total hip arthroplasty without any primary tuberculosis focus. *J Arthroplasty* 2011; 26: 505.e1-505.e3 [PMID: 20304601 DOI: 10.1016/j.arth.2009.11.025]
3. Zhang J, Liang L, Yang B, Li S, Yang X, Li J, Sun L, Han W. Total hip arthroplasty for tuberculosis: a case series. *Ann Palliat Med* 2021; 10: 495-500 [PMID: 33545780 DOI: 10.21037/apm-20-2544]

- 4 **Li L**, Chou K, Deng J, Shen F, He Z, Gao S, Li Y, Lei G. Two-stage total hip arthroplasty for patients with advanced active tuberculosis of the hip. *J Orthop Surg Res* 2016; **11**: 38 [PMID: [27029638](#) DOI: [10.1186/s13018-016-0364-3](#)]
- 5 **Chang CH**, Hu CC, Chang Y, Hsieh PH, Shih HN, Ueng SW. Two-stage revision arthroplasty for Mycobacterium Tuberculosis periprosthetic joint infection: An outcome analysis. *PLoS One* 2018; **13**: e0203585 [PMID: [30192830](#) DOI: [10.1371/journal.pone.0203585](#)]
- 6 **Zhang YC**, Zhang H. One-stage total joint arthroplasty for patients with active tuberculosis. *Orthopedics* 2013; **36**: 328-330 [PMID: [23672889](#) DOI: [10.3928/01477447-20130426-02](#)]
- 7 **Bhosale PB**, Jaiswal R, Purohit S, Arte SM. Total Hip Arthroplasty in 52 Active Advanced Tubercular Arthritic Hips. *J Arthroplasty* 2021; **36**: 1035-1042 [PMID: [33097338](#) DOI: [10.1016/j.arth.2020.09.016](#)]
- 8 **Tuli SM**, Mukherjee SK. Excision arthroplasty for tuberculous and pyogenic arthritis of the hip. *J Bone Joint Surg Br* 1981; **63-B**: 29-32 [PMID: [7204469](#) DOI: [10.1302/0301-620X.63B1.7204469](#)]
- 9 **Clegg J**. The results of the pseudarthrosis after removal of an infected total hip prosthesis. *J Bone Joint Surg Br* 1977; **59**: 298-301 [PMID: [893508](#) DOI: [10.1302/0301-620X.59B3.893508](#)]
- 10 **Riggins RS**, Kraus JF, Lipscomb PR. Osteoarthritis of the hip. A survey of treatment. *Clin Orthop Relat Res* 1975; **(106)**: 56-59 [PMID: [1126091](#) DOI: [10.1097/00003086-197501000-00008](#)]
- 11 **Stewart PS**, Costerton JW. Antibiotic resistance of bacteria in biofilms. *Lancet* 2001; **358**: 135-138 [PMID: [11463434](#) DOI: [10.1016/s0140-6736\(01\)05321-1](#)]
- 12 **Neogi DS**, Yadav CS, Ashok Kumar, Khan SA, Rastogi S. Total hip arthroplasty in patients with active tuberculosis of the hip with advanced arthritis. *Clin Orthop Relat Res* 2010; **468**: 605-612 [PMID: [19568823](#) DOI: [10.1007/s11999-009-0957-9](#)]
- 13 **Ha KY**, Chung YG, Ryoo SJ. Adherence and biofilm formation of Staphylococcus epidermidis and Mycobacterium tuberculosis on various spinal implants. *Spine (Phila Pa 1976)* 2005; **30**: 38-43 [PMID: [15626979](#) DOI: [10.1097/01.brs.0000147801.63304.8a](#)]
- 14 **Govender S**. The outcome of allografts and anterior instrumentation in spinal tuberculosis. *Clin Orthop Relat Res* 2002; **(398)**: 60-66 [PMID: [11964632](#) DOI: [10.1097/00003086-200205000-00009](#)]
- 15 **Harris WH**. Etiology of osteoarthritis of the hip. *Clin Orthop Relat Res* 1986; **(213)**: 20-33 [PMID: [3780093](#) DOI: [10.1097/00003086-198612000-00004](#)]
- 16 **Cooperman DR**, Wallenstein R, Stulberg SD. Acetabular dysplasia in the adult. *Clin Orthop Relat Res* 1983; **(175)**: 79-85 [PMID: [6839611](#) DOI: [10.1016/0303-8467\(83\)90078-1](#)]
- 17 **Lloyd-Roberts GC**. Osteoarthritis of the hip; a study of the clinical pathology. *J Bone Joint Surg Br* 1955; **37-B**: 8-47 [PMID: [14353950](#) DOI: [10.1302/0301-620X.37B1.8](#)]
- 18 **Oztürkmen Y**, Karamehmetoğlu M, Leblebici C, Gökçe A, Caniklioğlu M. Cementless total hip arthroplasty for the management of tuberculosis coxitis. *Arch Orthop Trauma Surg* 2010; **130**: 197-203 [PMID: [19784661](#) DOI: [10.1007/s00402-009-0967-9](#)]
- 19 **Sultan AA**, Dalton SE, Umpierrez E, Samuel LT, Rose E, Tamer P, Rabin JM, Mont MA. Total hip arthroplasty in the setting of tuberculosis infection of the hip: a systematic analysis of the current evidence. *Expert Rev Med Devices* 2019; **16**: 363-371 [PMID: [31007099](#) DOI: [10.1080/17434440.2019.1606710](#)]
- 20 **Saraf SK**, Tuli SM. Tuberculosis of hip: A current concept review. *Indian J Orthop* 2015; **49**: 1-9 [PMID: [25593352](#) DOI: [10.4103/0019-5413.143903](#)]



Published by **Baishideng Publishing Group Inc**  
7041 Koll Center Parkway, Suite 160, Pleasanton, CA 94566, USA

**Telephone:** +1-925-3991568

**E-mail:** [bpgoffice@wjgnet.com](mailto:bpgoffice@wjgnet.com)

**Help Desk:** <https://www.f6publishing.com/helpdesk>

<https://www.wjgnet.com>

