

World Journal of *Clinical Cases*

World J Clin Cases 2021 October 6; 9(28): 8280-8626



Contents

Thrice Monthly Volume 9 Number 28 October 6, 2021

REVIEW

- 8280** Transmission of severe acute respiratory syndrome coronavirus 2 *via* fecal-oral: Current knowledge
Silva FAFD, de Brito BB, Santos MLC, Marques HS, da Silva Júnior RT, de Carvalho LS, de Sousa Cruz S, Rocha GR, Santos GLC, de Souza KC, Maciel RGA, Lopes DS, Silva NOE, Oliveira MV, de Melo FF
- 8295** Nutrition, nutritional deficiencies, and schizophrenia: An association worthy of constant reassessment
Onaolapo OJ, Onaolapo AY

MINIREVIEWS

- 8312** Grounded theory qualitative approach from Foucault's ethical perspective: Deconstruction of patient self-determination in the clinical setting
Molina-Mula J
- 8327** Diabetes mellitus and COVID-19: Understanding the association in light of current evidence
Sen S, Chakraborty R, Kalita P, Pathak MP

ORIGINAL ARTICLE

Case Control Study

- 8340** Pregnancy complications effect on the nickel content in maternal blood, placenta blood and umbilical cord blood during pregnancy
Ding AL, Hu H, Xu FP, Liu LY, Peng J, Dong XD

Retrospective Study

- 8349** Clinical observation of Kuntai capsule combined with Fenmotong in treatment of decline of ovarian reserve function
Lin XM, Chen M, Wang QL, Ye XM, Chen HF
- 8358** Short-term effect and long-term prognosis of neuroendoscopic minimally invasive surgery for hypertensive intracerebral hemorrhage
Wei JH, Tian YN, Zhang YZ, Wang XJ, Guo H, Mao JH
- 8366** Ultrasonographic assessment of cardiac function and disease severity in coronary heart disease
Zhang JF, Du YH, Hu HY, Han XQ
- 8374** COVID-19 among African Americans and Hispanics: Does gastrointestinal symptoms impact the outcome?
Ashktorab H, Folake A, Pizuorno A, Oskrochi G, Oppong-Twene P, Tamanna N, Mehdipour Dalivand M, Umeh LN, Moon ES, Kone AM, Banson A, Federman C, Ramos E, Awoyemi EO, Wonni BJ, Otto E, Maskalo G, Velez AO, Rankine S, Thrift C, Ekwunazu C, Scholes D, Chirumamilla LG, Ibrahim ME, Mitchell B, Ross J, Curtis J, Kim R, Gilliard C, Mathew J, Laiyemo A, Kibreab A, Lee E, Sherif Z, Shokrani B, Aduli F, Brim H

Observational Study

- 8388** Validated tool for early prediction of intensive care unit admission in COVID-19 patients
Huang HF, Liu Y, Li JX, Dong H, Gao S, Huang ZY, Fu SZ, Yang LY, Lu HZ, Xia LY, Cao S, Gao Y, Yu XX
- 8404** Comparison of the impact of endoscopic retrograde cholangiopancreatography between pre-COVID-19 and current COVID-19 outbreaks in South Korea: Retrospective survey
Kim KH, Kim SB

Randomized Controlled Trial

- 8413** Effect of family caregiver nursing education on patients with rheumatoid arthritis and its impact factors: A randomized controlled trial
Li J, Zhang Y, Kang YJ, Ma N

SYSTEMATIC REVIEWS

- 8425** Dealing with hepatic artery traumas: A clinical literature review
Dilek ON, Atay A
- 8441** Clinical considerations for critically ill COVID-19 cancer patients: A systematic review
Ramasamy C, Mishra AK, John KJ, Lal A

CASE REPORT

- 8453** Atypical granular cell tumor of the urinary bladder: A case report
Wei MZ, Yan ZJ, Jiang JH, Jia XL
- 8461** Hepatocyte nuclear factor 1B mutation in a Chinese family with renal cysts and diabetes syndrome: A case report
Xiao TL, Zhang J, Liu L, Zhang B
- 8470** Ultrasound features of primary non-Hodgkin's lymphoma of the palatine tonsil: A case report
Jiang R, Zhang HM, Wang LY, Pian LP, Cui XW
- 8476** Percutaneous drainage in the treatment of intrahepatic pancreatic pseudocyst with Budd-Chiari syndrome: A case report
Zhu G, Peng YS, Fang C, Yang XL, Li B
- 8482** Postmenopausal women with hyperandrogenemia: Three case reports
Zhu XD, Zhou LY, Jiang J, Jiang TA
- 8492** Extremely high titer of hepatitis B surface antigen antibodies in a primary hepatocellular carcinoma patient: A case report
Han JJ, Chen Y, Nan YC, Yang YL
- 8498** Surgical treatment of liver metastasis with uveal melanoma: A case report
Kim YH, Choi NK

- 8504** Intermittent appearance of right coronary fistula and collateral circulation: A case report
Long WJ, Huang X, Lu YH, Huang HM, Li GW, Wang X, He ZL
- 8509** Synchronous concomitant pancreatic acinar cell carcin and gastric adenocarcinoma: A case report and review of literature
Fang T, Liang TT, Wang YZ, Wu HT, Liu SH, Wang C
- 8518** Spontaneous resolution of gallbladder hematoma in blunt traumatic injury: A case report
Jang H, Park CH, Park Y, Jeong E, Lee N, Kim J, Jo Y
- 8524** Rupture of ovarian endometriotic cyst complicated with endometriosis: A case report
Wang L, Jiang YJ
- 8531** Rotarex mechanical thrombectomy in renal artery thrombosis: A case report
Li WR, Liu MY, Chen XM, Zhang ZW
- 8537** Necrotizing fasciitis of cryptoglandular infection treated with multiple incisions and thread-dragging therapy: A case report
Tao XC, Hu DC, Yin LX, Wang C, Lu JG
- 8545** Endoscopic joint capsule and articular process excision to treat lumbar facet joint syndrome: A case report
Yuan HJ, Wang CY, Wang YF
- 8552** Spinocerebellar ataxia type 3 with dopamine-responsive dystonia: A case report
Zhang XL, Li XB, Cheng FF, Liu SL, Ni WC, Tang FF, Wang QG, Wang XQ
- 8557** Disseminated soft tissue diffuse large B-cell lymphoma involving multiple abdominal wall muscles: A case report
Lee CH, Jeon SY, Yhim HY, Kwak JY
- 8563** Genetic characteristics of a patient with multiple primary cancers: A case report
Ouyang WW, Li QY, Yang WG, Su SF, Wu LJ, Yang Y, Lu B
- 8571** Hypereosinophilia with cerebral venous sinus thrombosis and intracerebral hemorrhage: A case report and review of the literature
Song XH, Xu T, Zhao GH
- 8579** Itraconazole therapy for infant hemangioma: Two case reports
Liu Z, Lv S, Wang S, Qu SM, Zhang GY, Lin YT, Yang L, Li FQ
- 8587** One-stage total hip arthroplasty for advanced hip tuberculosis combined with developmental dysplasia of the hip: A case report
Zhu RT, Shen LP, Chen LL, Jin G, Jiang HT
- 8595** *Pneumocystis jirovecii* and *Legionella pneumophila* coinfection in a patient with diffuse large B-cell lymphoma: A case report
Wu WH, Hui TC, Wu QQ, Xu CA, Zhou ZW, Wang SH, Zheng W, Yin QQ, Li X, Pan HY

- 8602** Delayed massive cerebral infarction after perioperative period of anterior cervical discectomy and fusion: A case report
Jia F, Du CC, Liu XG
- 8609** Cortical bone trajectory fixation in cemented vertebrae in lumbar degenerative disease: A case report
Chen MM, Jia P, Tang H
- 8616** Primary intramedullary melanocytoma presenting with lower limbs, defecation, and erectile dysfunction: A case report and review of the literature
Liu ZQ, Liu C, Fu JX, He YQ, Wang Y, Huang TX

ABOUT COVER

Editorial Board Member of *World Journal of Clinical Cases*, Domenico De Berardis, MD, PhD, Adjunct Professor, Chief Doctor, NHS, Department of Mental Health, Teramo 64100, Italy. domenico.deberardis@aslteramo.it

AIMS AND SCOPE

The primary aim of *World Journal of Clinical Cases* (WJCC, *World J Clin Cases*) is to provide scholars and readers from various fields of clinical medicine with a platform to publish high-quality clinical research articles and communicate their research findings online.

WJCC mainly publishes articles reporting research results and findings obtained in the field of clinical medicine and covering a wide range of topics, including case control studies, retrospective cohort studies, retrospective studies, clinical trials studies, observational studies, prospective studies, randomized controlled trials, randomized clinical trials, systematic reviews, meta-analysis, and case reports.

INDEXING/ABSTRACTING

The WJCC is now indexed in Science Citation Index Expanded (also known as SciSearch®), Journal Citation Reports/Science Edition, Scopus, PubMed, and PubMed Central. The 2021 Edition of Journal Citation Reports® cites the 2020 impact factor (IF) for WJCC as 1.337; IF without journal self cites: 1.301; 5-year IF: 1.742; Journal Citation Indicator: 0.33; Ranking: 119 among 169 journals in medicine, general and internal; and Quartile category: Q3. The WJCC's CiteScore for 2020 is 0.8 and Scopus CiteScore rank 2020: General Medicine is 493/793.

RESPONSIBLE EDITORS FOR THIS ISSUE

Production Editor: Yan-Xia Xing; Production Department Director: Yun-Jie Ma; Editorial Office Director: Jin-Lei Wang.

NAME OF JOURNAL

World Journal of Clinical Cases

ISSN

ISSN 2307-8960 (online)

LAUNCH DATE

April 16, 2013

FREQUENCY

Thrice Monthly

EDITORS-IN-CHIEF

Dennis A Bloomfield, Sandro Vento, Bao-Gan Peng

EDITORIAL BOARD MEMBERS

<https://www.wjgnet.com/2307-8960/editorialboard.htm>

PUBLICATION DATE

October 6, 2021

COPYRIGHT

© 2021 Baishideng Publishing Group Inc

INSTRUCTIONS TO AUTHORS

<https://www.wjgnet.com/bpg/gerinfo/204>

GUIDELINES FOR ETHICS DOCUMENTS

<https://www.wjgnet.com/bpg/GerInfo/287>

GUIDELINES FOR NON-NATIVE SPEAKERS OF ENGLISH

<https://www.wjgnet.com/bpg/gerinfo/240>

PUBLICATION ETHICS

<https://www.wjgnet.com/bpg/GerInfo/288>

PUBLICATION MISCONDUCT

<https://www.wjgnet.com/bpg/gerinfo/208>

ARTICLE PROCESSING CHARGE

<https://www.wjgnet.com/bpg/gerinfo/242>

STEPS FOR SUBMITTING MANUSCRIPTS

<https://www.wjgnet.com/bpg/GerInfo/239>

ONLINE SUBMISSION

<https://www.f6publishing.com>

Delayed massive cerebral infarction after perioperative period of anterior cervical discectomy and fusion: A case report

Fei Jia, Chuan-Chao Du, Xiao-Guang Liu

ORCID number: Fei Jia 0000-0002-2800-1537; Chuan-Chao Du 0000-0002-7893-8846; Xiao-Guang Liu 0000-0002-5663-5238.

Author contributions: Jia F contributed to the conceptualization, investigation, and project administration, and wrote the original draft; Du CC contributed to the data curation, resources, formal analysis, and visualization, and reviewed and edited the manuscript; Liu XG contributed to methodology and supervision; all authors approved the final manuscript.

Supported by Capital's Funds for Health Improvement and Research, No. 2020-2-4091.

Informed consent statement: Written informed consent was obtained from the patient for publication of this report and any accompanying images.

Conflict-of-interest statement: The authors declare that they have no conflicts of interest to report.

CARE Checklist (2016) statement: The authors have read the CARE Checklist (2016), and the manuscript was prepared according to the CARE Checklist (2016).

Open-Access: This article is an

Fei Jia, Chuan-Chao Du, Xiao-Guang Liu, Department of Orthopedics, Peking University Third Hospital, Beijing 100191, China

Corresponding author: Xiao-Guang Liu, MD, Professor, Department of Orthopedics, Peking University Third Hospital, No. 49 North Garden Street, Beijing 100191, China.
xgliudocor@163.com

Abstract

BACKGROUND

Cerebral infarction is an extremely rare postoperative complication of anterior cervical discectomy and fusion (ACDF), particularly in the delayed setting. We present a case who had a sudden stroke on day 18 after surgery. By sharing our experience with this case, we hope to provide new information about stroke after anterior cervical surgery.

CASE SUMMARY

We present the case of a 61-year-old man with more than 20 years of hypertension and 14 years of coronary heart disease who had suffered a stroke 11 years ago. The patient was admitted for a multiple ACDF due to symptoms of cervical spondylotic myelopathy and had a sudden stroke on day 18 after surgery. Imaging findings showed a large-area infarct of his left cerebral hemisphere and thrombosis in his left common carotid artery. With the consent of his family, the thrombus was removed and a vascular stent was implanted through an interventional operation. Forty days later, the patient was transferred to a rehabilitation hospital for further treatment. He had normal consciousness but slurred speech at the 1-year follow-up evaluation. The motor and sensory functions of his hemiplegic limbs partially recovered.

CONCLUSION

This case illustrated that a postoperative stroke related to anterior cervical surgery may be attributed to prolonged carotid retraction and might have a long silent period. Preventive measures include careful preoperative and postoperative examination for high-risk patients as well as gentle and intermittent retraction of carotid artery sheath during operation.

Key Words: Anterior cervical discectomy and fusion; Cerebral infarction; Carotid artery; Postoperative complication; Case report

open-access article that was selected by an in-house editor and fully peer-reviewed by external reviewers. It is distributed in accordance with the Creative Commons Attribution NonCommercial (CC BY-NC 4.0) license, which permits others to distribute, remix, adapt, build upon this work non-commercially, and license their derivative works on different terms, provided the original work is properly cited and the use is non-commercial. See: <http://creativecommons.org/licenses/by-nc/4.0/>

Manuscript source: Unsolicited manuscript

Specialty type: Orthopedics

Country/Territory of origin: China

Peer-review report's scientific quality classification

Grade A (Excellent): 0
Grade B (Very good): 0
Grade C (Good): 0
Grade D (Fair): 0
Grade E (Poor): 0

Received: May 25, 2021

Peer-review started: May 25, 2021

First decision: June 24, 2021

Revised: July 8, 2021

Accepted: August 12, 2021

Article in press: August 12, 2021

Published online: October 6, 2021

P-Reviewer: MacCormick AP

S-Editor: Ma YJ

L-Editor: Wang TQ

P-Editor: Zhang YL



©The Author(s) 2021. Published by Baishideng Publishing Group Inc. All rights reserved.

Core Tip: A postoperative stroke related to anterior cervical surgery is rare and may have a long silent period during which a carotid thrombus had formed at the surgical site. Preventive measures include gentle and intermittent retraction of carotid artery sheath during surgery, careful preoperative risk assessment and grading, and continuous postoperative monitoring of blood pressure, coagulation state, and condition changes of special patients.

Citation: Jia F, Du CC, Liu XG. Delayed massive cerebral infarction after perioperative period of anterior cervical discectomy and fusion: A case report. *World J Clin Cases* 2021; 9(28): 8602-8608

URL: <https://www.wjgnet.com/2307-8960/full/v9/i28/8602.htm>

DOI: <https://dx.doi.org/10.12998/wjcc.v9.i28.8602>

INTRODUCTION

Anterior cervical discectomy and fusion (ACDF) is an important surgical option in the treatment of cervical degenerative disease, which has a good clinical efficacy and safety with a low incidence of complications[1]. However, since the anterior cervical approach requires intraoperative retraction of carotid artery sheath to expose adequate surgical field, it may affect the hemodynamics of carotid artery and even cause some serious complications in atherosclerotics[2]. In fact, the references from the academic search were limited and insufficient to explain the incidence and timing of cerebral infarction after ACDF. There are only three previous case reports on postoperative cerebral infarction related to cervical spine surgery. Two reports showed cases of stroke occurring immediately after surgery, and the remaining one reported the occurrence at postoperative day 3[3-5]. There has been no report about delayed cerebral infarction occurring after the whole perioperative period of an ACDF.

Herein, we report a case who had a sudden stroke on day 18 after a multilevel ACDF. To the best of our knowledge, this is the first case of massive brain infarction reported after a whole perioperative period. We remind surgeons of this causal relationship segmented by time intervals, discuss the etiology of this rare entity, and report notes on the management.

CASE PRESENTATION

Chief complaints

A 61-year-old man was sent to the emergency room (ER) due to aphasia and right limb dyskinesia when he was doing exercises at home in the early morning.

History of present illness

Eighty days ago, the patient sought treatment for a chief complaint of discomfort in the neck and shoulders accompanied with weakness of both upper and lower limbs. The symptoms did not relieve after a full rest. On physical examination, no obvious tenderness but dysfunction of flexion was found in his neck. Pain and hypoesthesia were found in C4, C5, and C6 dermatomes. The muscle strength of scapula stabilization, shoulder abduction, elbow flexion and extension, wrist flexion and extension, and finger flexion was all grade 3 according to the ASIA Grading System. Bilateral Hoffmann's sign was positive and knee tendon reflex was hyperactive. No significant abnormal findings were noted in blood tests. Magnetic resonance imaging (MRI) showed herniated C3-7 discs and hypertrophy of the ligamentum flavum at the C3-6 levels with a wasp-waisted spinal cord (Figure 1A and B). No preoperative vascular examination of the head and neck was performed because it was not a routine item. As a patient with cervical spondylotic myelopathy, he was hospitalized for cervical spine surgery. A multilevel ACDF was performed at the C3-4, C4-5, and C5-6 segments.

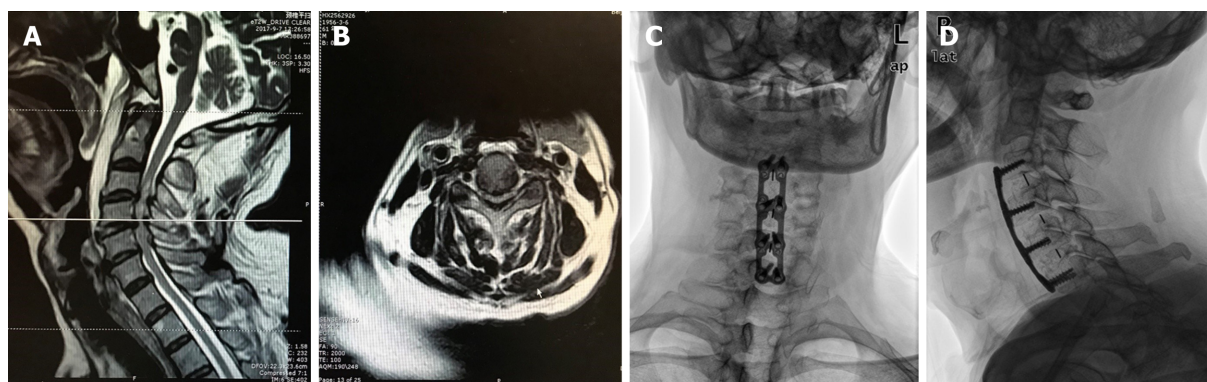


Figure 1 Representative images of the patient before and after surgery. A and B: Sagittal and axial T2-weighted magnetic resonance imaging showed C3-6 disc herniations and spinal canal stenosis; C and D: Postoperative anteroposterior and lateral X-ray images showing a good cervical curvature and appropriate internal fixation position of a multilevel anterior cervical discectomy and fusion.

During operation, the patient lied in supine position with cervical mild extension, then a left anterior transverse incision at the level of thyroid cartilage was made. After adequate exposure, responsible segments were confirmed with C-arm X-ray images and discectomy was performed with curets and rongeurs. Appropriate cages were implanted into the corresponding disc spaces after sufficient decompression and an anterior cervical plate system was applied. Anterior retraction system was used constantly during the operation. The retractors (self-retaining retractors, WEGO, China) were not always stable at their positions and were adjusted three times. No neurophysiological monitoring techniques were used. Blood pressure, heart rate, and other vital signs were stable during the operation. The operating time was 2 h and the blood loss was about 200 mL.

Postoperatively, the rehabilitation process was satisfactory and the patient was free of complaints about cervical discomfort, but his muscle strength did not recover significantly. The Japanese Orthopaedic Association (JOA) score increased from 8 to 13. Radiographs showed a good cervical curvature and well-positioned internal fixations (Figure 1C and D). No complications developed during his hospital stay. Antihypertensive drugs, aspirin, and low molecular weight heparin were given regularly from the second day after surgery.

At postoperative day 18, when the patient was exercising at home in the early morning, he suddenly developed aphasia, deviated mouth, weakness of the right limbs, urinary incontinence, and unresponsiveness without obvious inducement. There was no headache, dizziness, cough, unconsciousness, or convulsion. Then he was rushed to the emergency room.

History of past illness

The patient had more than 20 years of hypertension while the blood pressure was said to be stable (130-140 mmHg/70-90 mmHg) for years. Besides, he had a 14-year history of coronary heart disease and underwent coronary stent implantation 13 years ago. He took aspirin tablets regularly and was ranked in New York Heart Association (NYHA) class I. The patient had also suffered a cerebral stroke 11 years ago but did not have obvious residual sequelae. Aspirin was stopped after his initial admission.

Personal and family history

The patient denied any other relevant personal or family history.

Physical examination

The patient was urgently sent to the ER for evaluation and was found to have a score of 15 on the NIH Stroke Scale. His left internal carotid pulse became weak and a vascular murmur was audible on auscultation. His blood pressure was 160/100 mmHg and speech was slurred. He was conscious but unresponsive. The right nasolabial fold was shallow and the tongue was deviated to the right on extension. The muscle strength of the right limbs decreased significantly, accompanied by superficial hypoesthesia. Hypertonia appeared on his right side. Bilateral Kernig's sign, Brudzinski's sign, and Babinski's sign were all negative.

Laboratory examinations

During the ER treatment period, his counts of white blood cells, red blood cells, and platelets as well as the level of blood glucose were normal. The serum test results were: Homocysteine, 15.65 $\mu\text{mol/L}$; triglycerides, 2.12 mmol/L; low-density lipoprotein, 4.23 mmol/L; and total cholesterol, 6.42 mmol/L. His D-dimer was 3.92 mg/L and fibrinogen was 4.24 g/L, which were higher than the reference range.

Imaging examinations

A brain computed tomography (CT) scan showed a diffuse low-density region in his left hemisphere with a periventricular high-density hemorrhage focus (Figure 2A). The patient's condition worsened over time, so a carotid angiography was performed, which showed severe stenosis at the initial segment of his left common carotid artery. The contrast agent could not pass through the stenotic site to the distal end (Figure 2B). The percentage of arteriostenosis was reported at 92% and thrombosis of the left common carotid artery was reported.

FINAL DIAGNOSIS

Based on the above findings, a diagnosis of common carotid artery thrombosis and a new left hemispheric infarct after cervical spine surgery was established.

TREATMENT

With the consent of his family, the thrombus was removed and a vascular stent was implanted with an emergency interventional operation.

OUTCOME AND FOLLOW-UP

Forty days later, the patient was transferred to a rehabilitation hospital for further treatment and exercise. He had normal consciousness but slurred speech at the 1-year follow-up evaluation. The motor and sensory functions of his hemiplegic limbs were partially restored.

DISCUSSION

We present a case of massive cerebral infarction that occurred 18 d after a multilevel ACDF. It is clear that he had several risk factors for cerebral infarction, including atherosclerotic lesion in the carotid artery, hypertension, coronary heart disease, and previous stroke history[6-9]. On the basis of these factors, discontinuation of aspirin, surgical stress, acute dehydration, and blood pressure fluctuation might collectively precipitate the carotid thrombosis[10,11]. According to the Essen-Stroke-Risk-Score (ESRS) system, the patient should be quantified as median risk (7/9) based on his preoperative status[8,12].

Theoretically, prolonged retraction of the atherosclerotic carotid artery would influence the stability of plaques or even damage the fibrous caps of atheromas, which eventually brought about serious cerebrovascular accidents[13-15]. This is an obvious defect of a long-standing anterior cervical spine surgery. Retraction could also cause changes in carotid artery hemodynamics by reducing cross-sectional area of local vessels but increasing turbulent blood flow[2]. Coupled with perioperative hypercoagulability, all three factors of Virchow were present on one patient and caused the carotid thrombosis[16]. Therefore, we thought that gentle manipulation and intermittent relaxation of retraction should be given in surgery to avoid excessive mechanical stimulation on vessels.

According to the search results of Google Scholar, only three case reports of acute cerebral infarction following cervical spine surgery have been published[3-5]. Afana *et al*[3] deemed that intraoperative surgical manipulation, hypotensive anesthesia, and prolonged neck hyperextension might contribute to their patients' stroke. Graffeo *et al* [5] expressed similar sentiments and speculated that the true incidence of cerebral ischemia might be underestimated by current reports, particularly in the delayed

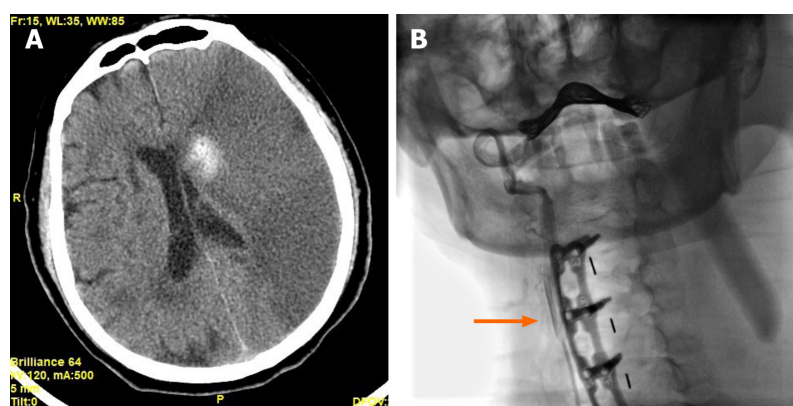


Figure 2 Representative images of the patient after an episode of cerebral infarction. A: Axial computed tomography image showing a massive low-density region in the left hemisphere and a high-density focus beside the left ventricle, indicating that a large-area ischemic cerebral infarct occurred with a focal hemorrhagic cerebral infarct; B: Carotid angiography showed that the right common carotid was present (arrow) but the left common carotid artery was invisible, indicating that the vascular occlusion was at the initial segment of the left common carotid artery.

setting. Perhaps that was the fact - to the best of our knowledge, this is the first report of cerebral infarction occurring 2 wk after a cervical spine surgery.

It cannot be concluded with certainty that the cerebral infarction was due to mechanical stimulation during the operation, but available evidence tended to prove the point. The angiographic images showed that the thrombus was at the initial segment of the patient's left common carotid artery, which was exactly the site of intraoperative retraction. It was not the common multiple lacunar infarcts that caused the stroke in this patient but a massive infarct of the left hemisphere. In addition, the case illustrated that a stroke related to anterior cervical spine surgery might have a long silent period during which a carotid thrombus had formed. Patients were at high risk of strokes with few symptoms in this stage and blood pressure fluctuation might play the role of trigger. Besides, the rise of blood pressure could also lead to hemorrhagic strokes with severe symptoms equally[17].

Several studies have shown that aspirin should not be suspended before surgery in patients who have been taking aspirin for a long time, because aspirin has no significant effect on intraoperative and postoperative bleeding[18,19]. Perioperative discontinuation of aspirin may affect coagulation status, thereby increasing the incidence of cardiovascular and cerebrovascular accidents, especially in patients with previous coronary heart diseases or strokes[20]. Perioperative use of anticoagulants such as low molecular weight heparin may also be useful in preventing serious complications[21]. In addition, lipid-lowering drugs can stabilize atheromatous plaques and limit the formation and expansion of thrombosis[22,23]. Preoperative coagulation tests are valuable in evaluating the coagulation status of patients.

Adequate preoperative risk assessment and examination can help identify risk factors for stroke and screen out patients with atherosclerosis. Carotid, transcranial, and cardiac Doppler ultrasound should be performed in high-risk patients before cervical spine surgery to assess the condition of their vessels and the possibility of stroke[24]. If it is clear that there exists severe atherosclerosis unilaterally, an incision from the contralateral side or the feasibility of posterior approach should be considered.

The case has certain warning significance on the postoperative course. The use of antihypertensive agents, lipid-lowering drugs, and anticoagulants should be promptly resumed after surgery[7,21-23]. For patients with definite carotid atherosclerosis, carotid ultrasound can be repeated after surgery to determine the presence of thrombus. For high-risk patients with dizziness, headache, or nausea after surgery, relevant examinations should be performed to exclude cerebral ischemia or infarction. Once it is clear that a patient has carotid thrombosis, aggressive interventions such as thrombectomy or thrombolytic therapy should be used to avoid the occurrence of subsequent stroke with poor clinical outcome[25,26].

CONCLUSION

This case illustrated that a postoperative stroke related to anterior cervical surgery

may be attributed to prolonged carotid retraction and might have a long silent period during which a carotid thrombus had formed at the surgical site. Preventive measures include careful preoperative and postoperative examination for high-risk patients as well as gentle and intermittent retraction of carotid artery sheath during surgery.

REFERENCES

- 1 **Romano PS**, Campa DR, Rainwater JA. Elective cervical discectomy in California: postoperative in-hospital complications and their risk factors. *Spine (Phila Pa 1976)* 1997; **22**: 2677-2692 [PMID: 9399456 DOI: 10.1097/00007632-199711150-00018]
- 2 **Pollard ME**, Little PW. Changes in carotid artery blood flow during anterior cervical spine surgery. *Spine (Phila Pa 1976)* 2002; **27**: 152-155 [PMID: 11805660 DOI: 10.1097/00007632-200201150-00006]
- 3 **Afana HB**, Abuhadrous NMM, Elsharkawy AE. Bithalamic Infarction (Artery of Percheron Occlusion) after Anterior Cervical Discectomy and Fusion. *Case Rep Neurol Med* 2019; **2019**: 9438089 [PMID: 31011457 DOI: 10.1155/2019/9438089]
- 4 **Chin KR**, Seale J, Butron V, Cumming V. Postoperative cervical haematoma complicated by ipsilateral carotid thrombosis and aphasia after anterior cervical fusion: a case report. *Case Rep Med* 2013; **2013**: 590639 [PMID: 23533432 DOI: 10.1155/2013/590639]
- 5 **Graffeo CS**, Puffer RC, Wijdicks EF, Krauss WE. Delayed cerebral infarct following anterior cervical discectomy and fusion. *Surg Neurol Int* 2016; **7**: 86 [PMID: 27713852 DOI: 10.4103/2152-7806.191022]
- 6 **Ellekjaer EF**, Wyller TB, Sverre JM, Holmen J. Lifestyle factors and risk of cerebral infarction. *Stroke* 1992; **23**: 829-834 [PMID: 1595100 DOI: 10.1161/01.str.23.6.829]
- 7 **Xiong H**, Liu X, Tian X, Pu L, Zhang H, Lu M, Huang W, Zhang YT. A numerical study of the effect of varied blood pressure on the stability of carotid atherosclerotic plaque. *Biomed Eng Online* 2014; **13**: 152 [PMID: 25413300 DOI: 10.1186/1475-925X-13-152]
- 8 **Weimar C**, Goertler M, Röther J, Ringelstein EB, Darius H, Nabavi DG, Kim IH, Benemann J, Diener HC; SCALA Study Group. Predictive value of the Essen Stroke Risk Score and Ankle Brachial Index in acute ischaemic stroke patients from 85 German stroke units. *J Neurol Neurosurg Psychiatry* 2008; **79**: 1339-1343 [PMID: 18586863 DOI: 10.1136/jnnp.2008.146092]
- 9 **Warsz-Wianecka A**, Lasek-Bal A, Kazibutowska Z. Cerebral microembolism in patients with segmental left ventricular wall motion abnormalities. *Neurol Neurochir Pol* 2014; **48**: 98-104 [PMID: 24821634 DOI: 10.1016/j.pjnns.2013.12.009]
- 10 **Vasivej T**, Sathirapanya P, Kongkamol C. Incidence and Risk Factors of Perioperative Stroke in Noncardiac, and Nonaortic and Its Major Branches Surgery. *J Stroke Cerebrovasc Dis* 2016; **25**: 1172-1176 [PMID: 26922129 DOI: 10.1016/j.jstrokecerebrovasdis.2016.01.051]
- 11 **Gao Y**, Guo Q, Zhang J, Feng Y, Yan B, Su D, Zhu X, Wang G. The underlying risks of circadian blood pressure variation for carotid plaque in treated hypertensive patients with normal blood pressure. *Blood Press Monit* 2017; **22**: 191-195 [PMID: 28257292 DOI: 10.1097/MBP.0000000000000253]
- 12 **Meng X**, Wang Y, Zhao X, Wang C, Li H, Liu L, Zhou Y, Xu J. Validation of the Essen Stroke Risk Score and the Stroke Prognosis Instrument II in Chinese patients. *Stroke* 2011; **42**: 3619-3620 [PMID: 22020029 DOI: 10.1161/STROKEAHA.111.624148]
- 13 **Badimon L**, Chesebro JH, Badimon JJ. Thrombus formation on ruptured atherosclerotic plaques and rethrombosis on evolving thrombi. *Circulation* 1992; **86**: III74-III85 [PMID: 1424053 DOI: 10.1016/0021-9150(92)90134-3]
- 14 **Arroyo LH**, Lee RT. Mechanisms of plaque rupture: mechanical and biologic interactions. *Cardiovasc Res* 1999; **41**: 369-375 [PMID: 10341836 DOI: 10.1016/s0008-6363(98)00308-3]
- 15 **Tripoten MI**, Pogorelova OA, Rogoza AN, Balakhonova TV. Comparative investigation of mechanical characteristics of stable and unstable carotid atherosclerotic plaques. *Artery Res* 2011; **5**: 191 [DOI: 10.1016/j.artres.2011.10.152]
- 16 **Bennett PC**, Silverman SH, Gill PS, Lip GY. Peripheral arterial disease and Virchow's triad. *Thromb Haemost* 2009; **101**: 1032-1040 [PMID: 19492144 DOI: 10.1160/TH08-08-0518]
- 17 **Guo R**, Xie Y, Zheng J, Wang Y, Dai Y, Sun Z, Xing L, Zhang X, Sun Y, Zheng L. Short-term blood pressure changes have a more strong impact on stroke and its subtypes than long-term blood pressure changes. *Clin Cardiol* 2019; **42**: 925-933 [PMID: 31361034 DOI: 10.1002/clc.23242]
- 18 **Gerstein NS**, Schulman PM, Gerstein WH, Petersen TR, Tawil I. Should more patients continue aspirin therapy perioperatively? *Ann Surg* 2012; **255**: 811-819 [PMID: 22470078 DOI: 10.1097/SLA.0b013e318250504e]
- 19 **Cheng A**, Poon MTC, Demetriades AK. Aspirin therapy discontinuation and intraoperative blood loss in spinal surgery: a systematic review. *Neurosurg Rev* 2018; **41**: 1029-1036 [PMID: 29362950 DOI: 10.1007/s10143-018-0945-1]
- 20 **Oscarsson A**, Gupta A, Fredrikson M, Järhult J, Nyström M, Pettersson E, Darvish B, Krook H, Swahn E, Eintrei C. To continue or discontinue aspirin in the perioperative period: a randomized, controlled clinical trial. *Br J Anaesth* 2010; **104**: 305-312 [PMID: 20150346 DOI: 10.1093/bja/aeq003]

- 21 **Kai AM**, Vadivelu N, Urman RD, Shukla S, Schonberger R, Banack T. Perioperative Considerations in the Management of Anticoagulation Therapy for Patients Undergoing Surgery. *Curr Pain Headache Rep* 2019; **23**: 13 [PMID: [30796535](#) DOI: [10.1007/s11916-019-0747-3](#)]
- 22 **Koh KK**. Effects of statins on vascular wall: vasomotor function, inflammation, and plaque stability. *Cardiovasc Res* 2000; **47**: 648-657 [PMID: [10974215](#) DOI: [10.1016/s0008-6363\(00\)00146-2](#)]
- 23 **Trubelja N**, Vaughan C, Coplan NL. The role of statins in preventing stroke. *Prev Cardiol* 2005; **8**: 98-101 [PMID: [15860985](#) DOI: [10.1111/j.1520-037x.2005.3568.x](#)]
- 24 **Topcuoglu MA**. Transcranial Doppler ultrasound in neurovascular diseases: diagnostic and therapeutic aspects. *J Neurochem* 2012; **123** Suppl 2: 39-51 [PMID: [23050641](#) DOI: [10.1111/j.1471-4159.2012.07942.x](#)]
- 25 **Brott TG**, Haley EC Jr, Levy DE, Barsan W, Broderick J, Sheppard GL, Spilker J, Kongable GL, Massey S, Reed R. Urgent therapy for stroke. Part I. Pilot study of tissue plasminogen activator administered within 90 minutes. *Stroke* 1992; **23**: 632-640 [PMID: [1579958](#) DOI: [10.1161/01.str.23.5.632](#)]
- 26 **Derex L**, Cho TH. Mechanical thrombectomy in acute ischemic stroke. *Rev Neurol (Paris)* 2017; **173**: 106-113 [PMID: [28238346](#) DOI: [10.1016/j.neurol.2016.06.008](#)]



Published by **Baishideng Publishing Group Inc**
7041 Koll Center Parkway, Suite 160, Pleasanton, CA 94566, USA

Telephone: +1-925-3991568

E-mail: bpgoffice@wjgnet.com

Help Desk: <https://www.f6publishing.com/helpdesk>

<https://www.wjgnet.com>

