

# World Journal of *Clinical Cases*

*World J Clin Cases* 2021 October 16; 9(29): 8627-8952



## Contents

Thrice Monthly Volume 9 Number 29 October 16, 2021

## REVIEW

- 8627 Time to give up traditional methods for the management of gastrointestinal neuroendocrine tumours  
*Yozgat A, Kekilli M, Altay M*

## MINIREVIEWS

- 8647 Healthcare practice strategies for integrating personalized medicine: Management of COVID-19  
*Liu WY, Chien CW, Tung TH*
- 8658 Clinical application of repetitive transcranial magnetic stimulation for post-traumatic stress disorder: A literature review  
*Cheng P, Zhou Y, Xu LZ, Chen YF, Hu RL, Zou YL, Li ZX, Zhang L, Shun Q, Yu X, Li LJ, Li WH*
- 8666 Pros and cons of continuous glucose monitoring in the intensive care unit  
*Sun MT, Li IC, Lin WS, Lin GM*

## ORIGINAL ARTICLE

## Clinical and Translational Research

- 8671 Prognostic implications of ferroptosis-associated gene signature in colon adenocarcinoma  
*Miao YD, Kou ZY, Wang JT, Mi DH*

## Retrospective Study

- 8694 Cefoperazone sodium/sulbactam sodium *vs* piperacillin sodium/tazobactam sodium for treatment of respiratory tract infection in elderly patients  
*Wang XX, Ma CT, Jiang YX, Ge YJ, Liu FY, Xu WG*
- 8702 Modified Gant procedure for treatment of internal rectal prolapse in elderly women  
*Xu PP, Su YH, Zhang Y, Lu T*
- 8710 Clinical and imaging features of desmoid tumors of the extremities  
*Shi Z, Zhao XM, Jiang JM, Li M, Xie LZ*
- 8718 Retrospective analysis of surgically treated pT4b gastric cancer with pancreatic head invasion  
*Jin P, Liu H, Ma FH, Ma S, Li Y, Xiong JP, Kang WZ, Hu HT, Tian YT*
- 8729 Development of a random forest model for hypotension prediction after anesthesia induction for cardiac surgery  
*Li XF, Huang YZ, Tang JY, Li RC, Wang XQ*

**Clinical Trials Study**

- 8740** Effects of mindful breathing combined with sleep-inducing exercises in patients with insomnia  
*Su H, Xiao L, Ren Y, Xie H, Sun XH*

**Observational Study**

- 8749** Chronic hepatitis-C infection in COVID-19 patients is associated with in-hospital mortality  
*Ronderos D, Omar AMS, Abbas H, Makker J, Baiomi A, Sun H, Mantri N, Choi Y, Fortuzi K, Shin D, Patel H, Chilimuri S*
- 8763** Midazolam dose is associated with recurrence of paradoxical reactions during endoscopy  
*Jin EH, Song JH, Lee J, Bae JH, Chung SJ*

**CASE REPORT**

- 8773** Isolated mass-forming IgG4-related sclerosing cholangitis masquerading as extrahepatic cholangiocarcinoma: A case report  
*Song S, Jo S*
- 8782** *Samonella typhi* infection-related appendicitis: A case report  
*Zheng BH, Hao WM, Lin HC, Shang GG, Liu H, Ni XJ*
- 8789** ACTA2 mutation is responsible for multisystemic smooth muscle dysfunction syndrome with seizures: A case report and review of literature  
*Yang WX, Zhang HH, Hu JN, Zhao L, Li YY, Shao XL*
- 8797** Whole-genome amplification/preimplantation genetic testing for propionic acidemia of successful pregnancy in an obligate carrier Mexican couple: A case report  
*Neumann A, Alcantara-Ortigoza MA, González-del Angel A, Zarate Díaz NA, Santana JS, Porchia LM, López-Bayghen E*
- 8804** Is mannitol combined with furosemide a new treatment for refractory lymphedema? A case report  
*Kim HS, Lee JY, Jung JW, Lee KH, Kim MJ, Park SB*
- 8812** Successful treatment of floating splenic volvulus: Two case reports and a literature review  
*Sun C, Li SL*
- 8820** Removal of "ruptured" pulmonary artery infusion port catheter by pigtail catheter combined with gooseneck trap: A case report  
*Chen GQ, Wu Y, Zhao KF, Shi RS*
- 8825** Isolated neutropenia caused by copper deficiency due to jejunal feeding and excessive zinc intake: A case report  
*Ohmori H, Kodama H, Takemoto M, Yamasaki M, Matsumoto T, Kumode M, Miyachi T, Sumimoto R*
- 8831** Diagnosis and treatment of eosinophilic fasciitis: Report of two cases  
*Song Y, Zhang N, Yu Y*
- 8839** Familial left cervical neurofibromatosis 1 with scoliosis: A case report  
*Mu X, Zhang HY, Shen YH, Yang HY*

- 8846** Successful treatment after toxic epidermal necrolysis induced by AZD-9291 in a patient with non-small cell lung cancer: A case report  
*Li W, He X, Liu H, Zhu J, Zhang HM*
- 8852** Anesthesia management in a pediatric patient with Becker muscular dystrophy undergoing laparoscopic surgery: A case report  
*Peng L, Wei W*
- 8858** Diagnosis of upper gastrointestinal perforation complicated with fistula formation and subphrenic abscess by contrast-enhanced ultrasound: A case report  
*Qiu TT, Fu R, Luo Y, Ling WW*
- 8864** Adenomyoepithelioma of the breast with malignant transformation and repeated local recurrence: A case report  
*Oda G, Nakagawa T, Mori M, Fujioka T, Onishi I*
- 8871** Primary intracranial synovial sarcoma with hemorrhage: A case report  
*Wang YY, Li ML, Zhang ZY, Ding JW, Xiao LF, Li WC, Wang L, Sun T*
- 8879** Lumbar infection caused by *Mycobacterium paragordoniae*: A case report  
*Tan YZ, Yuan T, Tan L, Tian YQ, Long YZ*
- 8888** Primary intratracheal neurilemmoma in a 10-year-old girl: A case report  
*Wu L, Sha MC, Wu XL, Bi J, Chen ZM, Wang YS*
- 8894** Ovarian pregnancy rupture following ovulation induction and intrauterine insemination: A case report  
*Wu B, Li K, Chen XF, Zhang J, Wang J, Xiang Y, Zhou HG*
- 8901** Delayed diagnosis of imperforate hymen with huge hematocolpometra: A case report  
*Jang E, So KA, Kim B, Lee AJ, Kim NR, Yang EJ, Shim SH, Lee SJ, Kim TJ*
- 8906** Acute pancreatitis with hypercalcemia caused by primary hyperparathyroidism associated with paraneoplastic syndrome: A case report and review of literature  
*Yang L, Lin Y, Zhang XQ, Liu B, Wang JY*
- 8915** Use of a modified tracheal tube in a child with traumatic bronchial rupture: A case report and review of literature  
*Fan QM, Yang WG*
- 8923** Isolated liver metastasis detected 11 years after the curative resection of rectal cancer: A case report  
*Yonenaga Y, Yokoyama S*
- 8932** Severe bleeding after operation of preauricular fistula: A case report  
*Tian CH, Chen XJ*
- 8938** Secondary aorto-esophageal fistula initially presented with empyema after thoracic aortic stent grafting: A case report  
*Wang DQ, Liu M, Fan WJ*

- 8946**    Disruption of sensation-dependent bladder emptying due to bladder overdistension in a complete spinal cord injury: A case report

*Yoon JY, Kim DS, Kim GW, Won YH, Park SH, Ko MH, Seo JH*

**ABOUT COVER**

Editorial Board Member of *World Journal of Clinical Cases*, Jjiang-Huei Jeng, DDS, PhD, Professor, School of Dentistry and Department of Dentistry, National Taiwan University Medical College and National Taiwan University Hospital, School of Dentistry, College of Dental Medicine, Kaohsiung Medical University, Taipei 100, Taiwan. [jhjeng@ntu.edu.tw](mailto:jhjeng@ntu.edu.tw)

**AIMS AND SCOPE**

The primary aim of *World Journal of Clinical Cases* (*WJCC*, *World J Clin Cases*) is to provide scholars and readers from various fields of clinical medicine with a platform to publish high-quality clinical research articles and communicate their research findings online.

*WJCC* mainly publishes articles reporting research results and findings obtained in the field of clinical medicine and covering a wide range of topics, including case control studies, retrospective cohort studies, retrospective studies, clinical trials studies, observational studies, prospective studies, randomized controlled trials, randomized clinical trials, systematic reviews, meta-analysis, and case reports.

**INDEXING/ABSTRACTING**

The *WJCC* is now indexed in Science Citation Index Expanded (also known as SciSearch®), Journal Citation Reports/Science Edition, Scopus, PubMed, and PubMed Central. The 2021 Edition of Journal Citation Reports® cites the 2020 impact factor (IF) for *WJCC* as 1.337; IF without journal self cites: 1.301; 5-year IF: 1.742; Journal Citation Indicator: 0.33; Ranking: 119 among 169 journals in medicine, general and internal; and Quartile category: Q3. The *WJCC*'s CiteScore for 2020 is 0.8 and Scopus CiteScore rank 2020: General Medicine is 493/793.

**RESPONSIBLE EDITORS FOR THIS ISSUE**

Production Editor: Jia-Hui Li; Production Department Director: Xiang Li; Editorial Office Director: Jin-Lei Wang.

**NAME OF JOURNAL**

*World Journal of Clinical Cases*

**ISSN**

ISSN 2307-8960 (online)

**LAUNCH DATE**

April 16, 2013

**FREQUENCY**

Thrice Monthly

**EDITORS-IN-CHIEF**

Dennis A Bloomfield, Sandro Vento, Bao-Gan Peng

**EDITORIAL BOARD MEMBERS**

<https://www.wjgnet.com/2307-8960/editorialboard.htm>

**PUBLICATION DATE**

October 16, 2021

**COPYRIGHT**

© 2021 Baishideng Publishing Group Inc

**INSTRUCTIONS TO AUTHORS**

<https://www.wjgnet.com/bpg/gerinfo/204>

**GUIDELINES FOR ETHICS DOCUMENTS**

<https://www.wjgnet.com/bpg/GerInfo/287>

**GUIDELINES FOR NON-NATIVE SPEAKERS OF ENGLISH**

<https://www.wjgnet.com/bpg/gerinfo/240>

**PUBLICATION ETHICS**

<https://www.wjgnet.com/bpg/GerInfo/288>

**PUBLICATION MISCONDUCT**

<https://www.wjgnet.com/bpg/gerinfo/208>

**ARTICLE PROCESSING CHARGE**

<https://www.wjgnet.com/bpg/gerinfo/242>

**STEPS FOR SUBMITTING MANUSCRIPTS**

<https://www.wjgnet.com/bpg/GerInfo/239>

**ONLINE SUBMISSION**

<https://www.f6publishing.com>





Retrospective Study

# Modified Gant procedure for treatment of internal rectal prolapse in elderly women

Peng-Peng Xu, Yong-Hong Su, Yan Zhang, Tong Lu

**ORCID number:** Peng-Peng Xu 0000-0002-0356-3146; Yong-Hong Su 0000-0003-1393-6134; Yan Zhang 0000-0003-1242-9982; Tong Lu 0000-0003-0657-1835.

**Author contributions:** Xu PP and Lu T designed the study; Su YH performed the research; Zhang Y analyzed the data and wrote the manuscript; all authors have read and approve the final manuscript.

**Supported by** Jinan Health Commission Science and Technology Project, No. 2019-1-61.

**Institutional review board statement:** The study was reviewed and approved by the Jinan Huaiyin People's Hospital Institutional Review Board.

**Informed consent statement:** All study participants provided informed written consent prior to study enrollment.

**Conflict-of-interest statement:** No conflict of interest to be declare.

**Data sharing statement:** No additional data are available.

**Open-Access:** This article is an open-access article that was selected by an in-house editor and fully peer-reviewed by external reviewers. It is distributed in

**Peng-Peng Xu**, Department of Anorectal, Shandong Provincial Hospital (Group) Huaiyin People's Hospital, Jinan 250021, Shandong Province, China

**Yong-Hong Su, Tong Lu**, Department of Anorectal, Central Hospital Affiliated to Shandong First Medical University, Jinan 250013, Shandong Province, China

**Yan Zhang**, Department of Anorectal, Shanghe People's Hospital, Shanghe 251600, Shandong Province, China

**Corresponding author:** Yong-Hong Su, MHSc, Chief Physician, Department of Anorectal, Central Hospital Affiliated to Shandong First Medical University, No. 105 Jiefang Road, Lixia District, Jinan 250013, Shandong Province, China. [suyonghong126@126.com](mailto:suyonghong126@126.com)

## Abstract

### BACKGROUND

Although rectal prolapse is not a life-threatening condition, it can cause defecation disorders, anal incontinence, sensory abnormalities, and other problems that can seriously affect quality of life.

### AIM

To study the efficacy of the modified Gant procedure for elderly women with internal rectal prolapse.

### METHODS

Sixty-three elderly female patients with internal rectal prolapse underwent the modified Gant procedure. The preoperative and postoperative anal symptoms, Patient Assessment of Constipation Quality of Life (PAC-QOL), Wexner incontinence score, incontinence quality of life score, and complications (massive hemorrhage, infection, anorectal stenosis, and anorectal fistula) were compared.

### RESULTS

The improvement rates of postoperative symptoms were defecation disorders (84.5%), anal distention (69.6%), defecation sensation (81.4%), frequent defecation (88.7%), and anal incontinence (42.9%) ( $P < 0.05$ ). All dimensions and total scores of the PAC-QOL after the procedure were lower than those before the operation ( $P < 0.05$ ). The postoperative anal incontinence score and Wexner score were significantly lower than those before the procedure ( $P < 0.05$ ). The quality of life and total scores of postoperative anal incontinence were significantly higher than

accordance with the Creative Commons Attribution NonCommercial (CC BY-NC 4.0) license, which permits others to distribute, remix, adapt, build upon this work non-commercially, and license their derivative works on different terms, provided the original work is properly cited and the use is non-commercial. See: <http://creativecommons.org/licenses/by-nc/4.0/>

**Manuscript source:** Unsolicited manuscript

**Specialty type:** Gastroenterology and hepatology

**Country/Territory of origin:** China

**Peer-review report's scientific quality classification**

Grade A (Excellent): 0  
Grade B (Very good): B  
Grade C (Good): 0  
Grade D (Fair): 0  
Grade E (Poor): 0

**Received:** June 10, 2021

**Peer-review started:** June 10, 2021

**First decision:** July 5, 2021

**Revised:** July 13, 2021

**Accepted:** August 6, 2021

**Article in press:** August 6, 2021

**Published online:** October 16, 2021

**P-Reviewer:** Brochard C

**S-Editor:** Wang JL

**L-Editor:** Kerr C

**P-Editor:** Wang LYT



those before the procedure ( $P < 0.05$ ). There were no serious complications and no deaths.

## CONCLUSION

The modified Gant procedure has significant advantages in the treatment of elderly women with internal rectal prolapse.

**Key Words:** Modified Gant procedure; Intrarectal prolapse; Rectal; Prolapse; Elderly women

©The Author(s) 2021. Published by Baishideng Publishing Group Inc. All rights reserved.

**Core Tip:** Intrarectal prolapse in elderly patients, who have low tolerance for surgery, is often complicated by medical diseases. In this study, we explored a new kind of operation with a reliable curative effect, few postoperative complications and tolerance by elderly women with intrarectal prolapse.

**Citation:** Xu PP, Su YH, Zhang Y, Lu T. Modified Gant procedure for treatment of internal rectal prolapse in elderly women. *World J Clin Cases* 2021; 9(29): 8702-8709

**URL:** <https://www.wjgnet.com/2307-8960/full/v9/i29/8702.htm>

**DOI:** <https://dx.doi.org/10.12998/wjcc.v9.i29.8702>

## INTRODUCTION

Intrarectal prolapse (IRP) is defined as the intraluminal intussusception of a part of, or the whole rectal wall, in which no external lesions can be observed on the flat surface of the anus[1]. IRP commonly tends to affect older women. Some patients need surgical treatment when conservative treatment does not improve the condition. However, serious complications such as anastomotic fistula, rectal stricture, and pelvic infection may occur despite the many surgical options for IRP. IRP in elderly patients, who have low tolerance for surgery, is often complicated by medical diseases[2]. This study investigated a new type of procedure with a reliable curative effect, few postoperative complications, and tolerance in elderly women with IRP.

## MATERIALS AND METHODS

### Clinical data

From September 2018 to April 2020, 63 elderly female patients with IRP were selected according to the previously published diagnostic criteria[3]. The patients were aged 60 to 82 years, with an average age of  $67.19 \pm 5.57$  years, and six patients presented with serious medical diseases (Table 1). Inclusion criteria: (1) patients who met the diagnostic criteria of IRP with clinical symptoms; (2) patients aged  $\geq 60$  years; and (3) patients who had multidisciplinary treatment (gastroenterology, urology and gynecology) and were cured by long-term conservative treatment. The exclusion criteria were: (1) patients with perianal diseases such as perianal abscess, anal fissure, anal fistula, and perianal condyloma acuminatum; (2) patients with gynecological diseases, urinary diseases or colorectal tumors; (3) patients with mental illness; and (4) judgment of the efficacy or safety of the procedure was affected by incomplete data.

### Preoperative preparation

A detailed medical history was taken, comprehensive physical examination and investigations (routine examination, urine, stool, blood biochemistry, five items of liver disease, electrogram, and electric colonoscopy) were made, and all the patients were treated. They were also examined by defecography and graded according to the Oxford Rectal Prolapse Grade (ORPG). A detailed explanation of the procedure was provided to all the patients, who were reassured in order to enhance compliance with the treatment. Written informed consent was obtained from each of the patients.



**Table 1 Patient characteristics**

Characteristics	n
Age (yr)	
60–69	36
70–79	25
≥ 80	2
Preoperative complication of serious disease	
Coronary atherosclerotic heart disease	2
Chronic obstructive pulmonary disease	1
Liver cirrhosis	1
Diabetes	2
Oxford Rectal Prolapse Grade (ORPG)	
ORPG-1 (High rectal)	1
ORPG-2 (Low rectal)	6
ORPG-3 (High anal)	25
ORPG-4 (Low anal)	31

### Operation method

Patients were placed in the right lateral position and the operation site was exposed. Routine disinfection and anorectal iodophor cotton ball disinfection were performed. Digital rectal examination was conducted to rule out rectal space-occupying lesions and anal fistulae, and an anal retractor was used to keep the anal canal open for exploration. Guided by a finger, an Alice tissue forceps was used to clamp the loose rectal mucosa from the anal margin to the proximal end of the rectum and to pull it outward along the same point. The loose and prolapsed rectal mucosa was pulled out to the maximum extent, with a total length of ~6 cm. Using the Alice tissue forceps, the rectal mucosa was longitudinally clamped at the uppermost end of the intestinal mucosa and ligated with No. 10 mu silk line to form a mucosal ball. By repeating these steps, several mucosal balls were formed on the mucous membrane, 1 cm from the tooth line, and approximately three mucosal balls were flattened with the same forceps. There were 3–5 mucosal balls from the top of the rectum at the same point. We ensured that two fingers could be inserted into the rectal cavity, even with the mucosal balls, and that there was tension between the flat mucous balls during the ligation process (Figure 1).

### Observation index

The preoperative and postoperative anal symptoms, the Patient Assessment of Constipation Quality of Life (PAC-QOL), the Wexner anal incontinence score, the anal incontinence quality score, and the postoperative complications (massive hemorrhage, infection, anorectal stricture, anorectal fistula) were recorded.

### Statistical analyses

SPSS 20.0 software (IBM Corp., Armonk, NY, USA) was used for statistical analyses. The measurement data were expressed as mean ± SD and compared by single factor analysis of variance, while the numerical data was expressed as the number of cases (constituent ratio) and compared by  $\chi^2$  or Fisher's exact test ( $\alpha = 0.05$ ).

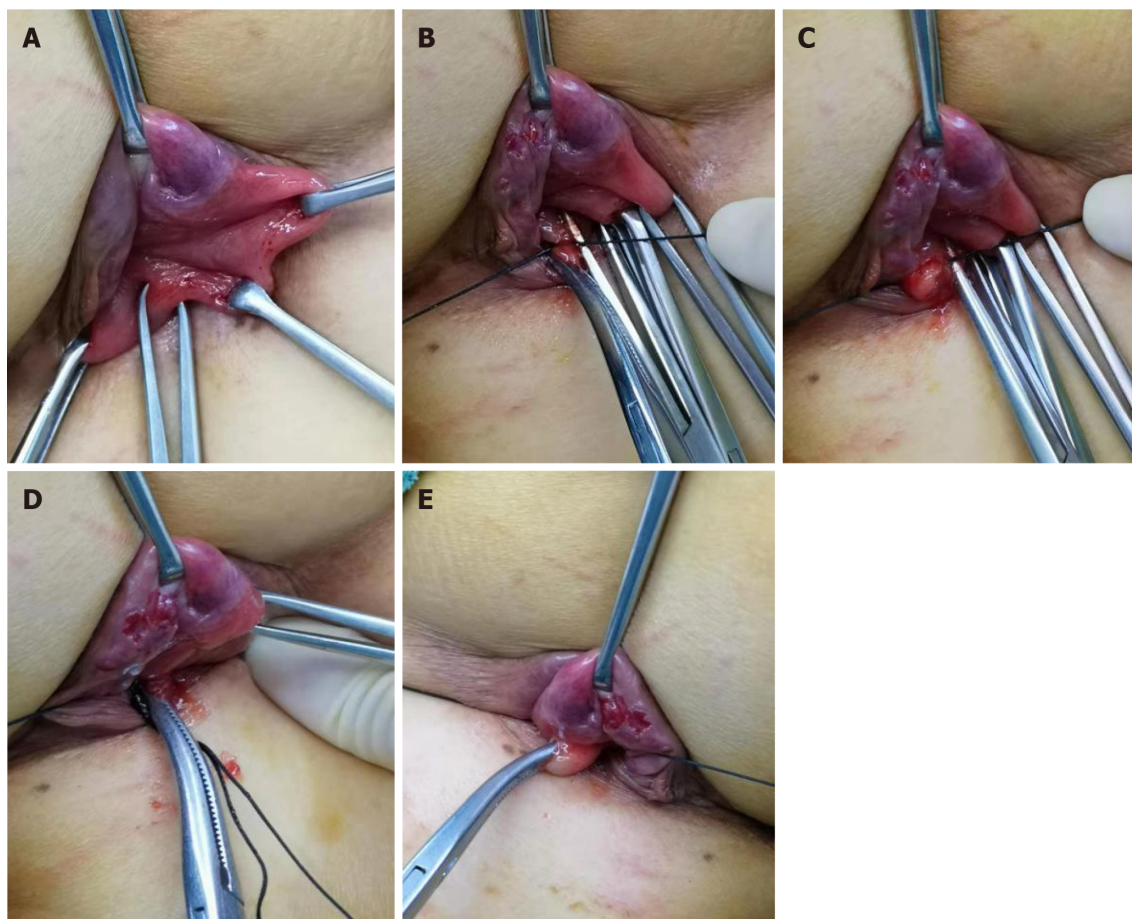
## RESULTS

### Comparison of symptoms before and after the procedure

The improvement rates of postoperative symptoms were as follows: defecation disorders, 84.5%; anal distention, 69.6%; defecation sensation, 81.4%; frequent defecation, 88.7%; and anal incontinence, 42.9% ( $P < 0.05$ ) (Table 2).

**Table 2** Five common symptoms of intrarectal prolapse, *n* (%)

Symptoms	Proportion		Improvement rate (%)	$\chi^2$	<i>P</i>
	Before procedure ( <i>n</i> = 63)	After procedure ( <i>n</i> = 63)			
Defecation disorder	58 (92.1)	9 (14.3)	84.5	76.531	0.000
Anal distension	56 (88.9)	17 (27.0)	69.6	49.537	0.000
Inexhaustible sense of defecation	59 (93.7)	11 (17.5)	81.4	74.057	0.000
Frequent defecation	53 (84.1)	6 (9.5)	88.7	61.050	0.000
Anal incontinence	35 (55.6)	20 (31.7)	42.9	7.260	0.007



**Figure 1 Operation method.** A: Tissue forceps pulling rectal mucosa outside the anus; B: Longitudinal clamp of mucous membrane with tube forceps and ligation of silk thread; C: Ligation of prolapsed rectal mucosa to form the first mucosal ball; D: Layered ligation of prolapsed rectal mucosa to form the second and third mucous bulbs; E: Ligation of the prolapsed rectal mucosa to form the fourth mucous membrane ball.

### **Comparison of dimensions and total scores of PAC-QOL before and after the procedure**

All dimensions and total scores of PAC-QOL after the procedure were lower than those before the procedure ( $P < 0.05$ ). The postoperative anal incontinence score and Wexner score were significantly lower than those before the procedure ( $P < 0.05$ ). The quality of life and total score of postoperative anal incontinence were significantly higher than those before the procedure ( $P < 0.05$ ) (Table 3).

### **Postoperative complications**

There were no serious postoperative complications or deaths (Table 4).

**Table 3 Comparison of PAC-QOL, dimensions, and total scores of anal incontinences (mean  $\pm$  SD)**

	Before procedure (n = 63)	After procedure (n = 63)	t	P
PAC-QOL score				
Physiology (4 items)	8.41 $\pm$ 2.18	5.48 $\pm$ 1.41	8.966	0.000
Social psychology (8 items)	18.79 $\pm$ 4.05	12.16 $\pm$ 3.23	10.157	0.000
Worry (11 items)	20.58 $\pm$ 5.59	15.49 $\pm$ 4.35	5.672	0.000
Satisfaction (5 items)	16.87 $\pm$ 4.39	11.52 $\pm$ 3.24	7.788	0.000
Total score	64.63 $\pm$ 14.05	44.65 $\pm$ 10.60	9.012	0.000
Wexner score of anal incontinence	8.54 $\pm$ 3.19	5.70 $\pm$ 3.33	3.129	0.003
Quality of life score of anal incontinence				
Lifestyle (10 items)	26.83 $\pm$ 7.23	31.25 $\pm$ 8.81	-2.013	0.049
Coping/behavior (9 items)	20.06 $\pm$ 6.06	25.05 $\pm$ 5.52	-3.032	0.004
Depression/self-perception (7 items)	14.91 $\pm$ 5.79	18.10 $\pm$ 4.24	-2.149	0.036
Awkward (3 items)	5.46 $\pm$ 1.82	6.85 $\pm$ 1.76	-2.764	0.008
Total score	67.26 $\pm$ 13.56	81.25 $\pm$ 13.95	-3.644	0.001

PAC-QOL: Patient Assessment of Constipation Quality of Life.

**Table 4 Postoperative complications**

Complications	n	Incidence rate
Massive hemorrhage	0	0
Infection	0	0
Anorectal stenosis	0	0
Anorectal fistula	0	0

## DISCUSSION

IRP is a condition that affects the pelvic floor, and its pathogenesis remains unclear[4]. In the clinical setting, rectal prolapse syndrome is the main manifestation and includes defecation disorder, auxiliary defecation, repeated trips to the restroom, and a feeling that the anus is falling out. Due to the low sensitivity and specificity of the clinical manifestations and limited understanding of IRP in the past, the diagnosis mainly depended on a detailed medical history[5]. In the past 20 years, IRP has been further diagnosed with the development of imaging techniques such as defecography and rectal ultrasound, and especially dynamic pelvic floor magnetic resonance[6]. The ORPG is an internationally recognized grading system for IRP based on imaging findings. According to the degree of prolapse, IRP can be divided into five grades: 1 and 2 indicate rectal intussusception; 3 and 4 indicate rectoanal intussusception; and 5 indicates external rectal prolapse. There is a correlation between the severity of prolapse and age[7]. The degree of prolapse increases and has more obvious clinical symptoms with increasing age. Female sex and multiparity are also risk factors for IRP [8].

Surgical treatment can be considered for patients with IRP in whom conservative treatments have been ineffective. In addition, many procedures to treat IRP are performed during surgery for external rectal prolapse, including laparoscopic ventral rectal repair and fixation (LVMR)[9], transanal surgeries such as Delorme's procedure, and transanal rectal anastomosis (STARR). One study showed that the improvement rates for constipation and fecal incontinence treated by LVMR for IRP were 65%–92% (39%–43%) and 73%–97% (39%–40%), respectively. The incidence of complications is low, ranging from 0% to 23% (44%). Most complications are mild, but there are also serious complications (vaginal erosion with prosthesis exposure, infection, intestinal obstruction, rectal perforation, and hernia)[10,11]. The improvement rate of clinical

constipation after Delorme's procedure is 76%, but the risk of incomplete defecation and fecal incontinence increases (24%)[12,13]. STARR is often recommended for the treatment of obstructive constipation, with an efficacy rate of 80%[14,15]. However, because of the decrease in rectal volume and changes in sensitivity, there is an increased risk of fecal incontinence as well as serious complications such as nail line rupture, abnormal pelvic cellulitis, and rectovaginal fistula[16]. The present study showed that the improvement rates for constipation and anal incontinence after the modified Gant procedure for elderly female patients with IRP were 84.5% and 42.9%, respectively, and there were no serious complications. Compared to the above-mentioned surgical methods for IRP, there was no significant difference in the improvement rate of constipation; there was a certain advantage in the convenience of correcting anal incontinence; and there were no serious complications caused by other surgical methods.

Although anorectal measurement is an objective means of examination, it cannot precisely evaluate the severity of anal incontinence and/or defecation disorders in patients with IRP. For patients with IRP with anal incontinence or defecation disorders, the subjective constipation/anal incontinence quality of life questionnaire can precisely reflect the severity of the complaints and help surgeons formulate treatment strategies and evaluate treatment outcomes for clinical and research objectives. Therefore, the present study used the PAC-QOL scale[17], the Wexner anal incontinence score scale[18], and the anal incontinence quality score to evaluate the clinical efficacy of the procedure[19]. The results showed that the modified Gant procedure could significantly improve constipation, anal incontinence, and the quality of life of patients with IRP.

The modified Gant procedure used in this study for treatment of IRP can shorten the rectal mucosa and fix it to the muscular layer by ligating the scar. In addition, the procedure is limited to the loose rectal mucosa, as the surrounding tissue is damaged. It can relieve defecation disorders and anal incontinence caused by rectal intussusception and reduce the stimulation to the rectal defecation receptor by the prolapsed tissue[20]. As a result, the modified Gant procedure can improve clinical symptoms such as anal distension and incomplete defecation and quality of life, postoperative pain, and serious complications caused by other procedures. This procedure does not require general anesthesia, and as a palliative procedure, it is particularly suitable for elderly patients with internal diseases and low surgical tolerance. During the procedure, attention to the following points is required: The prolapsed tissue must be pulled out gently to avoid mucosal tear. In addition, the index finger should be extended into the rectum under guidance to ensure that the pulled rectal mucosa is located on the same longitudinal axis. Moreover, a digital rectal examination should be performed before ligating the mucosa, to ensure that the rectal cavity at the point of ligation is greater than two fingers wide to avoid rectal stricture.

The long-term effect of this procedure needs to be observed and measured as the short follow-up time of the study was a limitation. The treatment of IRP requires a multidisciplinary management. In future studies, we will investigate whether comprehensive postoperative treatment, such as pelvic floor muscle training, traditional Chinese medicine, and psychological intervention, would benefit patients with rectal prolapse.

## CONCLUSION

The modified Gant procedure has significant advantages in the treatment of elderly women with IRP, a reliable curative effect, few postoperative complications, and is easily tolerated.

## ARTICLE HIGHLIGHTS

### Research background

Intrarectal prolapse (IRP) is defined as the intraluminal intussusception of part of, or the whole rectal wall, in which no external lesions can be observed on the flat surface of the anus.

### Research motivation

IRP tends to commonly affect older women. Some patients need surgical treatment

when conservative treatment does not improve the condition.

### Research objectives

To explore a new type of procedure with a reliable curative effect, few postoperative complications, and easy tolerance by elderly women with IRP.

### Research methods

Sixty-three elderly female patients with IRP underwent the modified Gant procedure.

### Research results

The quality of life and total score of postoperative anal incontinence were significantly higher than those before the procedure.

### Research conclusions

The modified Gant procedure has significant advantages in the treatment of elderly women with IRP. It has reliable curative effect, few postoperative complications, and is easily tolerated by elderly patients.

### Research perspectives

In future studies, the authors will investigate whether comprehensive postoperative treatment, such as pelvic floor muscle training, traditional Chinese medicine, and psychological intervention, would be of benefit to patients with IRP.

## REFERENCES

- 1 **Cariou de Vergie L**, Venara A, Duchalais E, Frampas E, Lehur PA. Internal rectal prolapse: Definition, assessment and management in 2016. *J Visc Surg* 2017; **154**: 21-28 [PMID: [27865742](#) DOI: [10.1016/j.jvisurg.2016.10.004](#)]
- 2 **Iida Y**, Honda K, Saitou H, Munemoto Y, Tanaka H. Modified Gant-Miwa-Thiersch procedure (mucosal plication with anal encircling) for rectal prolapse. *Colorectal Dis* 2019; **21**: 588-594 [PMID: [30673147](#) DOI: [10.1111/codi.14565](#)]
- 3 **van der Schans EM**, Paulides TJC, Wijffels NA, Consten ECJ. Management of patients with rectal prolapse: the 2017 Dutch guidelines. *Tech Coloproctol* 2018; **22**: 589-596 [PMID: [30099626](#) DOI: [10.1007/s10151-018-1830-1](#)]
- 4 **Collinson R**, Cunningham C, D'Costa H, Lindsey I. Rectal intussusception and unexplained faecal incontinence: findings of a proctographic study. *Colorectal Dis* 2009; **11**: 77-83 [PMID: [18462221](#) DOI: [10.1111/j.1463-1318.2008.01539.x](#)]
- 5 **Wijffels NA**, Jones OM, Cunningham C, Bemelman WA, Lindsey I. What are the symptoms of internal rectal prolapse? *Colorectal Dis* 2013; **15**: 368-373 [PMID: [22823279](#) DOI: [10.1111/j.1463-1318.2012.03183.x](#)]
- 6 **Faucheron JL**, Barot S, Collomb D, Hohn N, Anglade D, Dubreuil A. Dynamic cystocolpoproctography is superior to functional pelvic MRI in the diagnosis of posterior pelvic floor disorders: results of a prospective study. *Colorectal Dis* 2014; **16**: O240-O247 [PMID: [24506228](#) DOI: [10.1111/codi.12586](#)]
- 7 **Wijffels NA**, Collinson R, Cunningham C, Lindsey I. What is the natural history of internal rectal prolapse? *Colorectal Dis* 2010; **12**: 822-830 [PMID: [19508530](#) DOI: [10.1111/j.1463-1318.2009.01891.x](#)]
- 8 **Joshi HM**, Woods AK, Smyth E, Gosselink MP, Cunningham C, Lindsey I, Urban J, Jones OM, Vollrath F. Histological and mechanical differences in the skin of patients with rectal prolapse. *Int J Colorectal Dis* 2015; **30**: 1117-1122 [PMID: [25922144](#) DOI: [10.1007/s00384-015-2222-x](#)]
- 9 **D'Hoore A**, Cadoni R, Penninckx F. Long-term outcome of laparoscopic ventral rectopexy for total rectal prolapse. *Br J Surg* 2004; **91**: 1500-1505 [PMID: [15499644](#) DOI: [10.1002/bjs.4779](#)]
- 10 **Portier G**, Kirzin S, Cabarrot P, Queralto M, Lazorthes F. The effect of abdominal ventral rectopexy on faecal incontinence and constipation in patients with internal intra-anal rectal intussusception. *Colorectal Dis* 2011; **13**: 914-917 [PMID: [20497199](#) DOI: [10.1111/j.1463-1318.2010.02327.x](#)]
- 11 **Franceschilli L**, Varvaras D, Capuano I, Ciangola CI, Giorgi F, Boehm G, Gaspari AL, Sileri P. Laparoscopic ventral rectopexy using biologic mesh for the treatment of obstructed defaecation syndrome and/or faecal incontinence in patients with internal rectal prolapse: a critical appraisal of the first 100 cases. *Tech Coloproctol* 2015; **19**: 209-219 [PMID: [25577276](#) DOI: [10.1007/s10151-014-1255-4](#)]
- 12 **Liberman H**, Hughes C, Dippolito A. Evaluation and outcome of the delorme procedure in the treatment of rectal outlet obstruction. *Dis Colon Rectum* 2000; **43**: 188-192 [PMID: [10696892](#) DOI: [10.1007/BF02236980](#)]
- 13 **Pescatori M**, Zbar AP. Tailored surgery for internal and external rectal prolapse: functional results of 268 patients operated upon by a single surgeon over a 21-year period\*. *Colorectal Dis* 2009; **11**: 410-



- 419 [PMID: [18637923](#) DOI: [10.1111/j.1463-1318.2008.01626.x](#)]
- 14 **Ribaric G**, D'Hoore A, Schiffhorst G, Hempel E; TRANSTAR Registry Study Group. STARR with CONTOUR® TRANSTAR™ device for obstructed defecation syndrome: one-year real-world outcomes of the European TRANSTAR registry. *Int J Colorectal Dis* 2014; **29**: 611-622 [PMID: [24554148](#) DOI: [10.1007/s00384-014-1836-8](#)]
- 15 **Ren XH**, Yaseen SM, Cao YL, Liu WC, Shrestha S, Ding Z, Wu YH, Zheng KY, Qian Q, Jiang CQ. A transanal procedure using TST STARR Plus for the treatment of Obstructed Defecation Syndrome: 'A mid-term study'. *Int J Surg* 2016; **32**: 58-64 [PMID: [27345262](#) DOI: [10.1016/j.ijssu.2016.06.039](#)]
- 16 **Kim M**, Meurette G, Ragu R, Lehur PA. Current surgical treatment of obstructed defecation among selected European opinion leaders in pelvic floor surgery. *Tech Coloproctol* 2016; **20**: 395-399 [PMID: [27170284](#) DOI: [10.1007/s10151-016-1473-z](#)]
- 17 **Mokhtare M**, Ghafoori SM, Soltani-Kermanshahi M, Boghratian AH, Agah S, Sheikhvatan M. Reliability and validity of the Persian version of patient assessment of constipation- quality of life (PAC-QOL) questionnaire. *Gastroenterol Hepatol Bed Bench* 2017; **10**: 289-294 [PMID: [29379594](#)]
- 18 **Fonseca AM**, Meinberg MF, Lucas DV, Monteiro MV, Figueiredo EM, Fonseca L, Filho AL. Cultural adaptation and validation of the Wexner scale in patients with anal incontinence in a Brazilian population. *Int Urogynecol J* 2016; **27**: 959-963 [PMID: [26740200](#) DOI: [10.1007/s00192-015-2927-y](#)]
- 19 **Tejedor P**, Bodega-Quiroga I, Plaza J, Ortega López M, Gutierrez C, García Olmo D, Pastor C. Quality of life and 3D-EUS assessment for anal incontinence after childbirth. *Rev Esp Enferm Dig* 2019; **111**: 453-459 [PMID: [31021166](#) DOI: [10.17235/reed.2019.6040/2018](#)]
- 20 **Tranchart H**, Valverde A, Goasguen N, Gravié JF, Mosnier H. Conservative treatment of intrarectal mesh migration after ventral laparoscopic rectopexy for rectal prolapse. *Int J Colorectal Dis* 2013; **28**: 1563-1566 [PMID: [23836114](#) DOI: [10.1007/s00384-013-1740-7](#)]





Published by **Baishideng Publishing Group Inc**  
7041 Koll Center Parkway, Suite 160, Pleasanton, CA 94566, USA

**Telephone:** +1-925-3991568

**E-mail:** [bpgoffice@wjgnet.com](mailto:bpgoffice@wjgnet.com)

**Help Desk:** <https://www.f6publishing.com/helpdesk>

<https://www.wjgnet.com>

