

World Journal of *Clinical Cases*

World J Clin Cases 2021 October 16; 9(29): 8627-8952



Contents

Thrice Monthly Volume 9 Number 29 October 16, 2021

REVIEW

- 8627 Time to give up traditional methods for the management of gastrointestinal neuroendocrine tumours
Yozgat A, Kekilli M, Altay M

MINIREVIEWS

- 8647 Healthcare practice strategies for integrating personalized medicine: Management of COVID-19
Liu WY, Chien CW, Tung TH
- 8658 Clinical application of repetitive transcranial magnetic stimulation for post-traumatic stress disorder: A literature review
Cheng P, Zhou Y, Xu LZ, Chen YF, Hu RL, Zou YL, Li ZX, Zhang L, Shun Q, Yu X, Li LJ, Li WH
- 8666 Pros and cons of continuous glucose monitoring in the intensive care unit
Sun MT, Li IC, Lin WS, Lin GM

ORIGINAL ARTICLE

Clinical and Translational Research

- 8671 Prognostic implications of ferroptosis-associated gene signature in colon adenocarcinoma
Miao YD, Kou ZY, Wang JT, Mi DH

Retrospective Study

- 8694 Cefoperazone sodium/sulbactam sodium *vs* piperacillin sodium/tazobactam sodium for treatment of respiratory tract infection in elderly patients
Wang XX, Ma CT, Jiang YX, Ge YJ, Liu FY, Xu WG
- 8702 Modified Gant procedure for treatment of internal rectal prolapse in elderly women
Xu PP, Su YH, Zhang Y, Lu T
- 8710 Clinical and imaging features of desmoid tumors of the extremities
Shi Z, Zhao XM, Jiang JM, Li M, Xie LZ
- 8718 Retrospective analysis of surgically treated pT4b gastric cancer with pancreatic head invasion
Jin P, Liu H, Ma FH, Ma S, Li Y, Xiong JP, Kang WZ, Hu HT, Tian YT
- 8729 Development of a random forest model for hypotension prediction after anesthesia induction for cardiac surgery
Li XF, Huang YZ, Tang JY, Li RC, Wang XQ

Clinical Trials Study

- 8740** Effects of mindful breathing combined with sleep-inducing exercises in patients with insomnia
Su H, Xiao L, Ren Y, Xie H, Sun XH

Observational Study

- 8749** Chronic hepatitis-C infection in COVID-19 patients is associated with in-hospital mortality
Ronderos D, Omar AMS, Abbas H, Makker J, Baiomi A, Sun H, Mantri N, Choi Y, Fortuzi K, Shin D, Patel H, Chilimuri S
- 8763** Midazolam dose is associated with recurrence of paradoxical reactions during endoscopy
Jin EH, Song JH, Lee J, Bae JH, Chung SJ

CASE REPORT

- 8773** Isolated mass-forming IgG4-related sclerosing cholangitis masquerading as extrahepatic cholangiocarcinoma: A case report
Song S, Jo S
- 8782** *Salmonella typhi* infection-related appendicitis: A case report
Zheng BH, Hao WM, Lin HC, Shang GG, Liu H, Ni XJ
- 8789** ACTA2 mutation is responsible for multisystemic smooth muscle dysfunction syndrome with seizures: A case report and review of literature
Yang WX, Zhang HH, Hu JN, Zhao L, Li YY, Shao XL
- 8797** Whole-genome amplification/preimplantation genetic testing for propionic acidemia of successful pregnancy in an obligate carrier Mexican couple: A case report
Neumann A, Alcantara-Ortigoza MA, González-del Angel A, Zarate Díaz NA, Santana JS, Porchia LM, López-Bayghen E
- 8804** Is mannitol combined with furosemide a new treatment for refractory lymphedema? A case report
Kim HS, Lee JY, Jung JW, Lee KH, Kim MJ, Park SB
- 8812** Successful treatment of floating splenic volvulus: Two case reports and a literature review
Sun C, Li SL
- 8820** Removal of "ruptured" pulmonary artery infusion port catheter by pigtail catheter combined with gooseneck trap: A case report
Chen GQ, Wu Y, Zhao KF, Shi RS
- 8825** Isolated neutropenia caused by copper deficiency due to jejunal feeding and excessive zinc intake: A case report
Ohmori H, Kodama H, Takemoto M, Yamasaki M, Matsumoto T, Kumode M, Miyachi T, Sumimoto R
- 8831** Diagnosis and treatment of eosinophilic fasciitis: Report of two cases
Song Y, Zhang N, Yu Y
- 8839** Familial left cervical neurofibromatosis 1 with scoliosis: A case report
Mu X, Zhang HY, Shen YH, Yang HY

- 8846** Successful treatment after toxic epidermal necrolysis induced by AZD-9291 in a patient with non-small cell lung cancer: A case report
Li W, He X, Liu H, Zhu J, Zhang HM
- 8852** Anesthesia management in a pediatric patient with Becker muscular dystrophy undergoing laparoscopic surgery: A case report
Peng L, Wei W
- 8858** Diagnosis of upper gastrointestinal perforation complicated with fistula formation and subphrenic abscess by contrast-enhanced ultrasound: A case report
Qiu TT, Fu R, Luo Y, Ling WW
- 8864** Adenomyoepithelioma of the breast with malignant transformation and repeated local recurrence: A case report
Oda G, Nakagawa T, Mori M, Fujioka T, Onishi I
- 8871** Primary intracranial synovial sarcoma with hemorrhage: A case report
Wang YY, Li ML, Zhang ZY, Ding JW, Xiao LF, Li WC, Wang L, Sun T
- 8879** Lumbar infection caused by *Mycobacterium paragordoniae*: A case report
Tan YZ, Yuan T, Tan L, Tian YQ, Long YZ
- 8888** Primary intratracheal neurilemmoma in a 10-year-old girl: A case report
Wu L, Sha MC, Wu XL, Bi J, Chen ZM, Wang YS
- 8894** Ovarian pregnancy rupture following ovulation induction and intrauterine insemination: A case report
Wu B, Li K, Chen XF, Zhang J, Wang J, Xiang Y, Zhou HG
- 8901** Delayed diagnosis of imperforate hymen with huge hematocolpometra: A case report
Jang E, So KA, Kim B, Lee AJ, Kim NR, Yang EJ, Shim SH, Lee SJ, Kim TJ
- 8906** Acute pancreatitis with hypercalcemia caused by primary hyperparathyroidism associated with paraneoplastic syndrome: A case report and review of literature
Yang L, Lin Y, Zhang XQ, Liu B, Wang JY
- 8915** Use of a modified tracheal tube in a child with traumatic bronchial rupture: A case report and review of literature
Fan QM, Yang WG
- 8923** Isolated liver metastasis detected 11 years after the curative resection of rectal cancer: A case report
Yonenaga Y, Yokoyama S
- 8932** Severe bleeding after operation of preauricular fistula: A case report
Tian CH, Chen XJ
- 8938** Secondary aorto-esophageal fistula initially presented with empyema after thoracic aortic stent grafting: A case report
Wang DQ, Liu M, Fan WJ

- 8946** Disruption of sensation-dependent bladder emptying due to bladder overdistension in a complete spinal cord injury: A case report

Yoon JY, Kim DS, Kim GW, Won YH, Park SH, Ko MH, Seo JH

ABOUT COVER

Editorial Board Member of *World Journal of Clinical Cases*, Jjiang-Huei Jeng, DDS, PhD, Professor, School of Dentistry and Department of Dentistry, National Taiwan University Medical College and National Taiwan University Hospital, School of Dentistry, College of Dental Medicine, Kaohsiung Medical University, Taipei 100, Taiwan. jhjeng@ntu.edu.tw

AIMS AND SCOPE

The primary aim of *World Journal of Clinical Cases* (*WJCC*, *World J Clin Cases*) is to provide scholars and readers from various fields of clinical medicine with a platform to publish high-quality clinical research articles and communicate their research findings online.

WJCC mainly publishes articles reporting research results and findings obtained in the field of clinical medicine and covering a wide range of topics, including case control studies, retrospective cohort studies, retrospective studies, clinical trials studies, observational studies, prospective studies, randomized controlled trials, randomized clinical trials, systematic reviews, meta-analysis, and case reports.

INDEXING/ABSTRACTING

The *WJCC* is now indexed in Science Citation Index Expanded (also known as SciSearch®), Journal Citation Reports/Science Edition, Scopus, PubMed, and PubMed Central. The 2021 Edition of Journal Citation Reports® cites the 2020 impact factor (IF) for *WJCC* as 1.337; IF without journal self cites: 1.301; 5-year IF: 1.742; Journal Citation Indicator: 0.33; Ranking: 119 among 169 journals in medicine, general and internal; and Quartile category: Q3. The *WJCC*'s CiteScore for 2020 is 0.8 and Scopus CiteScore rank 2020: General Medicine is 493/793.

RESPONSIBLE EDITORS FOR THIS ISSUE

Production Editor: Jia-Hui Li; Production Department Director: Xiang Li; Editorial Office Director: Jin-Lei Wang.

NAME OF JOURNAL

World Journal of Clinical Cases

ISSN

ISSN 2307-8960 (online)

LAUNCH DATE

April 16, 2013

FREQUENCY

Thrice Monthly

EDITORS-IN-CHIEF

Dennis A Bloomfield, Sandro Vento, Bao-Gan Peng

EDITORIAL BOARD MEMBERS

<https://www.wjgnet.com/2307-8960/editorialboard.htm>

PUBLICATION DATE

October 16, 2021

COPYRIGHT

© 2021 Baishideng Publishing Group Inc

INSTRUCTIONS TO AUTHORS

<https://www.wjgnet.com/bpg/gerinfo/204>

GUIDELINES FOR ETHICS DOCUMENTS

<https://www.wjgnet.com/bpg/GerInfo/287>

GUIDELINES FOR NON-NATIVE SPEAKERS OF ENGLISH

<https://www.wjgnet.com/bpg/gerinfo/240>

PUBLICATION ETHICS

<https://www.wjgnet.com/bpg/GerInfo/288>

PUBLICATION MISCONDUCT

<https://www.wjgnet.com/bpg/gerinfo/208>

ARTICLE PROCESSING CHARGE

<https://www.wjgnet.com/bpg/gerinfo/242>

STEPS FOR SUBMITTING MANUSCRIPTS

<https://www.wjgnet.com/bpg/GerInfo/239>

ONLINE SUBMISSION

<https://www.f6publishing.com>



Primary intratracheal neurilemmoma in a 10-year-old girl: A case report

Lei Wu, Mi-Cun Sha, Xi-Ling Wu, Jing Bi, Zhi-Min Chen, Ying-Shuo Wang

ORCID number: Lei Wu 0000-0003-1329-010X; Mi-Cun Sha 0000-0002-7643-2075; Xi-Ling Wu 0000-0002-6268-3738; Jing Bi 0000-0002-8413-5900; Zhi-Min Chen 0000-0001-9417-0999; Ying-Shuo Wang 0000-0003-4813-1678.

Author contributions: Wu L, Sha MC and Bi J contributed to manuscript drafting; Wu L and Sha MC reviewed the literature and contributed equally to this work; Wu L and Bi J performed the surgery; Wu XL contributed to revising the manuscript for important intellectual content; All authors issued final approval for the version to be submitted.

Informed consent statement: Informed consent was obtained from the patient for publication of this report and any accompanying images.

Conflict-of-interest statement: The authors declare no conflicts of interest for this article.

CARE Checklist (2016) statement: The authors have read the CARE Checklist (2016), and the manuscript was prepared and revised according to the CARE Checklist (2016).

Open-Access: This article is an open-access article that was selected by an in-house editor and

Lei Wu, Department of Pulmonology and Endoscopy Center, The Children's Hospital, Zhejiang University School of Medicine, National Clinical Research Center for Child Health, Hangzhou 310003, Zhejiang Province, China

Mi-Cun Sha, Department of Pediatrics, Suqian People's Hospital of Nanjing Drum-Tower Hospital Group, Suqian 223800, Jiangsu Province, China

Xi-Ling Wu, Department of Respiratory Medicine, The Children's Hospital, Zhejiang University School of Medicine, National Clinical Research Center for Child Health, Hangzhou 310002, Zhejiang Province, China

Jing Bi, Department of Otorhinolaryngology Head and Neck Surgery, The Children's Hospital, Zhejiang University School of Medicine, National Clinical Research Center for Child Health, Hangzhou 310000, Zhejiang Province, China

Zhi-Min Chen, Ying-Shuo Wang, Department of Pediatric Pulmonology, The Children's Hospital, Zhejiang University School of Medicine, National Clinical Research Center for Child Health, Hangzhou 310000, Zhejiang Province, China

Corresponding author: Ying-Shuo Wang, MD, Doctor, Department of Pediatric Pulmonology, The Children's Hospital, Zhejiang University School of Medicine, National Clinical Research Center for Child Health, No. 3333 Binsheng Road, Hangzhou 310052, Zhejiang Province, China. wangyingshuo@zju.edu.cn

Abstract

BACKGROUND

Tracheal tumors are relatively rare in adults and uncommon in children. Tracheal neurilemmoma is a rare condition in adults that usually affects middle-aged people, but it can also occur in children. Because the clinical presentation is nonspecific and insidious, diagnosis is often delayed. The most common symptoms in these patients are stridor or wheezing (especially positional) and cough. A few patients are misdiagnosed and mistakenly treated for asthma.

CASE SUMMARY

A 10-year-old girl was admitted to our unit with a 2-mo history of recurrent cough, dyspnea, and tachypnea. Her condition was more severe after exercise. Her symptoms progressed despite treatment with inhaled fluticasone/salmeterol. Flexible electronic laryngoscopy showed a red, smooth, and round mushroom-shaped mass in the trachea, about 1 cm below the vocal cords. The surface of the

fully peer-reviewed by external reviewers. It is distributed in accordance with the Creative Commons Attribution NonCommercial (CC BY-NC 4.0) license, which permits others to distribute, remix, adapt, build upon this work non-commercially, and license their derivative works on different terms, provided the original work is properly cited and the use is non-commercial. See: <http://creativecommons.org/licenses/by-nc/4.0/>

Manuscript source: Unsolicited manuscript

Specialty type: Medicine, research and experimental

Country/Territory of origin: China

Peer-review report's scientific quality classification

Grade A (Excellent): 0
Grade B (Very good): 0
Grade C (Good): 0
Grade D (Fair): 0
Grade E (Poor): 0

Received: June 8, 2021

Peer-review started: June 8, 2021

First decision: June 25, 2021

Revised: July 8, 2021

Accepted: August 4, 2021

Article in press: August 4, 2021

Published online: October 16, 2021

P-Reviewer: Velikova TV

S-Editor: Wang LL

L-Editor: Filipodia

P-Editor: Liu JH



mass was covered with several small and discontinuous blood vessels. About 90% of the tracheal lumen was occupied by the mass. A multidisciplinary operation was performed. The surgically resected mass was diagnosed as benign neurilemmoma by immunohistochemical analysis.

CONCLUSION

Intratracheal neurilemmoma is fairly rare in children. The main symptoms include coughing, wheezing, and dyspnea. The tumor's size, location, and degree of intratracheal and extratracheal invasion can be measured by chest computed tomography. The main treatment strategies used for tracheal neurilemmoma are surgical resection and endoscopic excision. Long-term follow-up is warranted for the evaluation of outcomes and complications.

Key Words: Airway obstruction; Trachea; Neurilemmoma; Therapeutic bronchoscopy; Child; Case report

©The Author(s) 2021. Published by Baishideng Publishing Group Inc. All rights reserved.

Core Tip: Tracheal neurilemmoma is a rare condition in children. Because the clinical presentation is nonspecific and insidious, diagnosis is often delayed. This case report describes a 10-year-old girl with tracheal neurilemmoma.

Citation: Wu L, Sha MC, Wu XL, Bi J, Chen ZM, Wang YS. Primary intratracheal neurilemmoma in a 10-year-old girl: A case report. *World J Clin Cases* 2021; 9(29): 8888-8893

URL: <https://www.wjgnet.com/2307-8960/full/v9/i29/8888.htm>

DOI: <https://dx.doi.org/10.12998/wjcc.v9.i29.8888>

INTRODUCTION

Tracheal tumors are relatively rare in adults and uncommon in children[1]. About two-thirds of such tumors are malignant or moderately malignant, and the remaining one-third are benign lesions[2]. Tracheal neurilemmoma, also known as schwannoma, is a rare condition in adults that usually affects middle-aged people; however, it can also occur in children[3]. Common symptoms of this condition are stridor or wheezing and coughing. Some patients are misdiagnosed and mistakenly treated for asthma. This report describes a case involving a 10-year-old girl with tracheal neurilemmoma.

CASE PRESENTATION

Chief complaints

A 2-mo history of recurrent cough, dyspnea, and tachypnea.

History of present illness

A 10-year-old girl was admitted to our unit with a 2-mo history of recurrent cough, dyspnea, and tachypnea. Her condition was more severe after exercise. She had been hospitalized twice in a local unit and diagnosed with bronchitis and asthma. Her symptoms progressed despite treatment with inhaled fluticasone/salmeterol.

History of past illness

The patient had been previously healthy, and she denied a history of asthma and seasonal allergic rhinitis.

Personal and family history

The patient had no relevant family history.

Physical examination

On admission, the patient was dyspneic and characterized by biphasic stridor with a percutaneous saturation of 95% on room air. An examination showed a body temperature of 36.7 °C, a pulse rate of 92 beats/min, a respiration rate of 34 breaths/min, and a blood pressure of 107/74 mmHg.

Laboratory examinations

The patient's leukocyte count was $6.07 \times 10^9/L$ (reference range: $4.0\text{--}12.0 \times 10^9/L$). Her lymphocyte count was $3.09 \times 10^9/L$ (reference range: $0.7\text{--}4.9 \times 10^9/L$). An immune function test showed that her immunoglobulins were within the reference range.

Imaging examinations

Contrast-enhanced computed tomography (CT) revealed an obviously enhanced mass, occluding about 90% of the tracheal lumen (Figure 1A and B). Under conscious and local anesthesia, flexible electronic laryngoscopy showed a red, smooth, and round mushroom-shaped mass. The surface of the mass was covered with several small and discontinuous blood vessels. The base of the mass was in the trachea, about 1 cm below the vocal cords at the 4- to 7-o'clock position (Figure 2A).

Pulmonary function examinations indicated that the patient, who had exhibited no marked response to bronchodilators, had severe inspiratory obstructive ventilation dysfunction.

FINAL DIAGNOSIS

According to the pathological and immunohistochemical examination findings, the patient was diagnosed with tracheal neurilemmoma.

TREATMENT

The multidisciplinary consensus met the performance of endoscopy for a definitive diagnosis and determined prognosis and guide management. After the patient's parents had been fully notified of surgical options and possible complications associated with the various surgical modalities, they agreed to endoscopic tumor resection. There was a rigid bronchoscope available as well as a low-temperature plasma therapy device, argon plasma coagulation device, cryotherapy device, and holmium laser if necessary. The patient's parents also consented that, in case of failed endoscopic tumor resection, surgical resection would be conducted instantly.

Otolaryngologists, pulmonologists, anesthesiologists, thoracic surgeons, and doctors of the pediatric intensive care department were on-call in the operating room, ensuring the patient's safety. The loading dose of dexamethasone was 1 µg/kg, and the maintenance rate was 0.3 µg/kg/h. The patient was maintained with 3% sevoflurane inhalation, remifentanyl at 0.2 µg/kg/min, intravenous methylprednisolone at 30 mg, intravenous atropine at 0.25 mg, and intravenous lidocaine at 25 mg. After deep sedation and spontaneous breathing were achieved, 10 mg of etomidate was added to deepen the anesthesia. A flexible bronchoscope (FB) with a 2.8 mm outer diameter (Olympus XP260; Olympus Corp., Tokyo, Japan) was inserted into the trachea over the mass and used to guide intubation of a 4.5 mm endotracheal tube. The 4.5-mm tube could not prevent blood from flowing into the lower airway; therefore, we decided to perform a tracheotomy below the mass. The anesthesia ventilator controlled the patient's breathing through a tracheotomy cannula. After extubation of the endotracheal tube, a laryngoscope was placed in the vallecula, exposing the supraglottic and glottic larynx. An FB with a 4.9 mm outer diameter (Olympus 260; Olympus Corp.) was then passed into the subglottic region. A flexible electrocautery snare with a 1.9 mm outer diameter (Olympus CD-6C-1; Olympus Corp.) was then inserted *via* the working channel of the FB. The electrocautery snare was applied in a blended way at 12 W for cutting and coagulating the spherical part of the mass (Figure 2B). Because the mass base was too wide to be removed by the electric snare, it was ablated using a low-temperature plasma therapy device (EIC7070-01; Smith and Nephew, London, United Kingdom) under the laryngoscope (Figure 2C). To prevent a tracheoesophageal fistula, the base of the tumor was not completely removed (Figure 2D). The extracorporeal membrane oxygenation team was present to administer emergency treatment if intubation was difficult or asphyxia occurred.

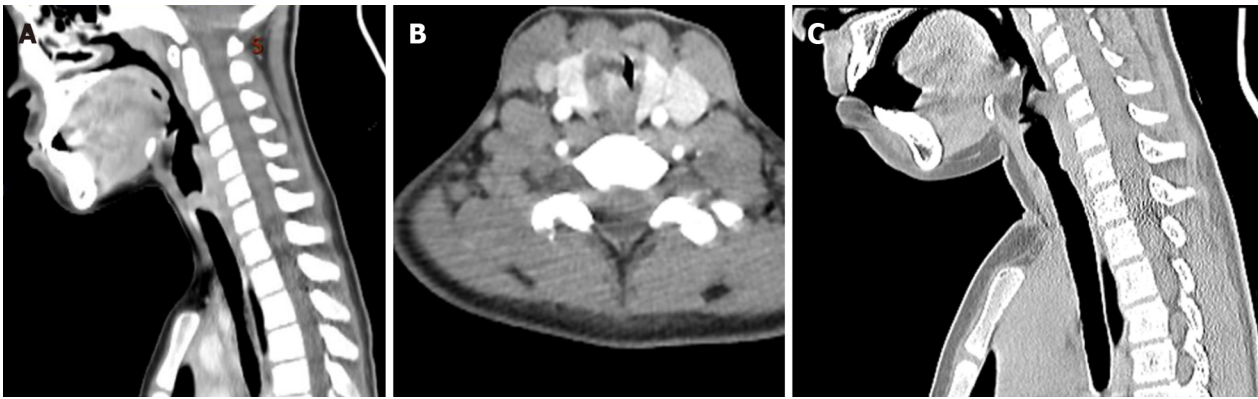

Figure 1 Preoperative and postoperative imaging. A: Computed tomography (CT) revealed a mass occluding about 90% of the tracheal lumen; B: Contrast-enhanced CT a soft tissue mass with obvious enhancement on the right posterolateral wall of the trachea; C: CT indicated a slight protrusion at the position of the incision.

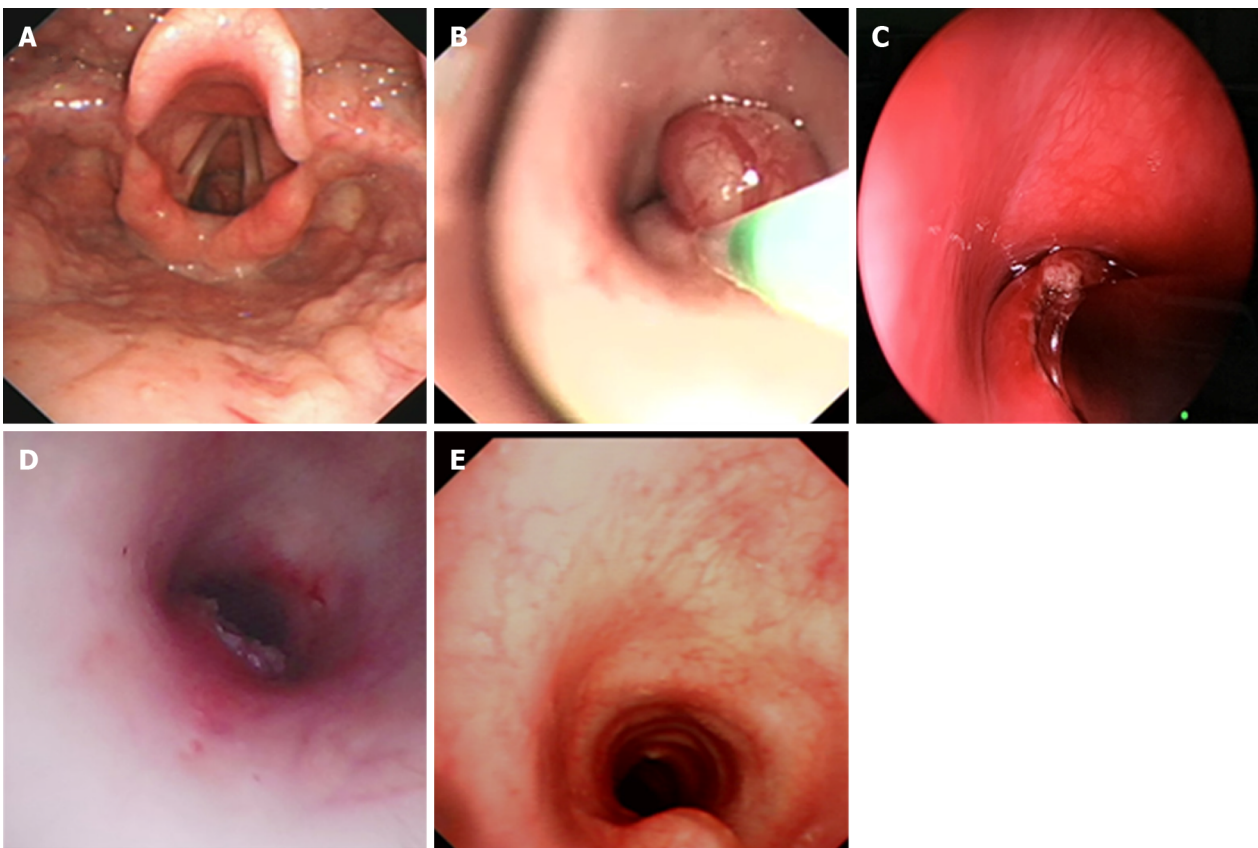


Figure 2 Fiberoptic bronchoscopy findings. A: A mass was located in the trachea at the 4- to 7-o'clock position about 1 cm below the vocal cords; B: The spherical part of the mass was removed by an electrocautery snare; C: The base was ablated by a low-temperature ion probe; D: Most of the base was removed; E: There was a slight protrusion at the position of the incision.

Pathological results

The tumor consisting of bundles of spindle cells with slender palisade nuclei, as shown by staining with hematoxylin and eosin (Figure 3A). Immunohistochemical analysis showed that the positive indicator of the tumor was S-100, and the results of CD117, desmin, smooth muscle actin, and CD34 were negative for the tumor (Figure 3B). The histological and immunohistochemical findings were consistent with benign schwannoma.

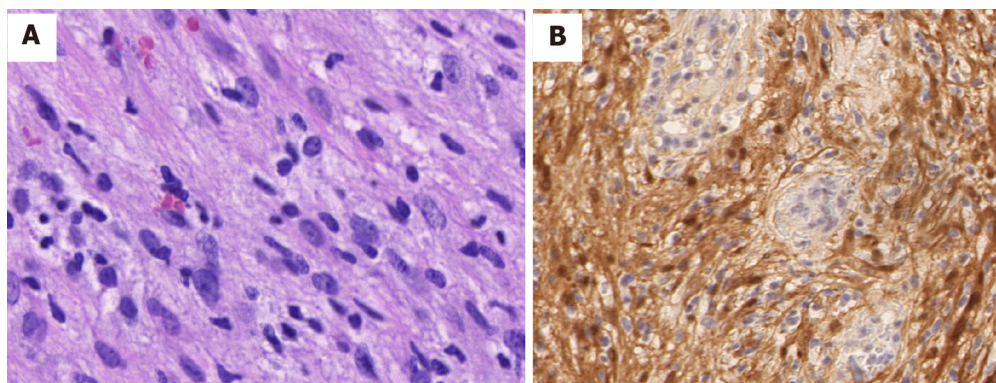


Figure 3 Pathological images of tumor cells. A: A histologic section from the tumor shows that the tumor cells were spindled with elongated palisading nuclei (hematoxylin–eosin stain, 400 ×); B: The tumor cells showed diffuse and positive S-100 staining by immunohistochemistry (streptavidin peroxidase method, 200 ×).

OUTCOME AND FOLLOW-UP

The patient's clinical manifestations disappeared after removal of the tumor, and the tracheotomy cannula was successfully removed 1 wk after the operation. Repeat bronchoscopy and chest CT examinations were conducted for 6 mo after the procedure (Figure 1C). A slight protrusion was present at the position of the incision (Figure 2E).

DISCUSSION

Neurilemmomas, also known as schwannomas, originate from Schwann cells in the peripheral nerve tissues and are usually benign. They are more commonly reported in the head, retroperitoneum, neck, lungs, and extremities[2]. However, tracheal neurilemmomas are rare in children.

In general, neurilemmomas grow slowly. Because their clinical presentation is nonspecific and insidious, diagnosis is often delayed. Only when the tumor attains a large size can patients be diagnosed. The main symptoms include coughing, wheezing, and dyspnea[4]. Pulmonary function testing is an effective method to distinguish tracheal neurilemmomas from asthma[5,6]. Chest CT or magnetic resonance imaging can be used to measure the tumor's size, location, and degree of intratracheal and extratracheal invasion. In this case, we reviewed the examination results before admission. Two months previously, we had discovered a mass in the upper part of the trachea. Lung function testing had also indicated an inspiratory phase obstruction, but it was initially ignored. In patients with an atypical presentation of asthma but with no response to anti-asthma treatment, bronchoscopy can detect airway tumors early and avoid misdiagnosis.

Because of the high degree of airway obstruction in this patient, extensive preoperative planning was necessary in case of an airway emergency during the operation. We planned to insert a 4.5-mm endotracheal tube under bronchoscopic guidance after anesthetic induction. Because the endotracheal intubation affected the exposure of the tumor, it would have been difficult to repeat the intubation in case of intraoperative decannulation. The 4.5-mm tube could not prevent blood from flowing into the lower airway, so we performed a tracheotomy below the tumor. If it had been difficult to intubate the patient by bronchoscopy, we would have attempted rigid bronchoscopy. Once a patient has developed obvious airway obstruction or asphyxia after induction of anesthesia, emergency tracheotomy or extracorporeal membrane oxygenation should be considered.

The tumor's size, location, depth of tracheal wall invasion, and extratracheal involvement should be considered when treating primary tracheal neurilemmoma[7]. The main treatment strategies are surgical resection and endoscopic excision[8]. Traditionally, the best conduit for the management of endotracheal tumors is probably rigid bronchoscopy[8]. Because the tumor in our patient was in the upper trachea and occupied most of the airway, we initially attempted to use an electric snare to remove the tumor. Electrocautery snares can sever large masses quickly with concomitant hemostasis. However, because the base of the tumor was broad, the snare could not remove it. We chose coblation to remove the base of the tumor and reduce the probability of recurrence after electrocautery snaring. The advantages of coblation

include rapid and precise ablation, minor thermal damage, and the integrated function of suction and coagulation[9]. Because of these characteristics of coblation technology, there was minimal surrounding tissue damage, which minimized the likelihood of postoperative stenosis.

Although a small part of the tumor remained after its removal, the patient displayed no symptoms and her parents were opposed to further invasive open surgery. Nearly one-fourth of patients who undergo endoscopic resection develop recurrence. The time of recurrence is variable, but there is a chance of late recurrence. Given that these tumors grow slowly, it is preferable to performed yearly bronchoscopic observations. If the tumor continues to grow, tracheal resection is the best option. Outcomes and complications, such as airway stenosis and tumor recurrence, should be consistently evaluated under long-term follow-up.

CONCLUSION

Intratracheal neurilemmoma is relatively rare in children. Primary symptoms include coughing, wheezing, and dyspnea. Chest CT can be used to measure the tumor's size, location, and degree of intratracheal and extratracheal invasiveness. The primary treatment strategies used for tracheal neurilemmoma are surgical resection and endoscopic excision. Long-term follow-up is warranted for the evaluation of outcomes and complications.

REFERENCES

- 1 **Nio M**, Sano N, Kotera A, Shimanuki Y, Takeyama J, Ohi R. Primary tracheal schwannoma (neurilemmoma) in a 9-year-old girl. *J Pediatr Surg* 2005; **40**: E5-E7 [PMID: [15852265](#) DOI: [10.1016/j.jpedsurg.2005.01.031](#)]
- 2 **Sharma PV**, Jobanputra YB, Perdomo Miquel T, Schroeder JR, Wellikoff A. Primary intratracheal schwannoma resected during bronchoscopy using argon plasma coagulation. *BMJ Case Rep* 2018; **2018** [PMID: [30232068](#) DOI: [10.1136/bcr-2018-225140](#)]
- 3 **Tang LF**, Chen ZM, Zou CC. Primary intratracheal neurilemmoma in children: case report and literature review. *Pediatr Pulmonol* 2005; **40**: 550-553 [PMID: [16175598](#) DOI: [10.1002/ppul.20279](#)]
- 4 **Hamouri S**, Novotny NM. Primary tracheal schwannoma a review of a rare entity: current understanding of management and followup. *J Cardiothorac Surg* 2017; **12**: 105 [PMID: [29183345](#) DOI: [10.1186/s13019-017-0677-2](#)]
- 5 **Weiner DJ**, Weatherly RA, DiPietro MA, Sanders GM. Tracheal schwannoma presenting as status asthmaticus in a sixteen-year-old boy: airway considerations and removal with the CO2 laser. *Pediatr Pulmonol* 1998; **25**: 393-397 [PMID: [9671167](#) DOI: [10.1002/\(sici\)1099-0496\(199806\)25:6<393::aid-ppul7>3.0.co;2-i](#)]
- 6 **Chen H**, Zhang K, Bai M, Li H, Zhang J, Gu L, Wu W. Recurrent transmural tracheal schwannoma resected by video-assisted thoracoscopic window resection: A case report. *Medicine (Baltimore)* 2019; **98**: e18180 [PMID: [31860964](#) DOI: [10.1097/MD.00000000000018180](#)]
- 7 **Ge X**, Han F, Guan W, Sun J, Guo X. Optimal treatment for primary benign intratracheal schwannoma: A case report and review of the literature. *Oncol Lett* 2015; **10**: 2273-2276 [PMID: [26622833](#) DOI: [10.3892/ol.2015.3521](#)]
- 8 **Diaz-Mendoza J**, Debiase L, Peralta AR, Simoff M. Tracheal tumors. *Curr Opin Pulm Med* 2019; **25**: 336-343 [PMID: [30973357](#) DOI: [10.1097/MCP.0000000000000585](#)]
- 9 **Kitsko DJ**, Chi DH. Coblation removal of large suprastomal tracheal granulomas. *Laryngoscope* 2009; **119**: 387-389 [PMID: [19172629](#) DOI: [10.1002/lary.20035](#)]



Published by **Baishideng Publishing Group Inc**
7041 Koll Center Parkway, Suite 160, Pleasanton, CA 94566, USA

Telephone: +1-925-3991568

E-mail: bpgoffice@wjgnet.com

Help Desk: <https://www.f6publishing.com/helpdesk>

<https://www.wjgnet.com>

