

World Journal of *Clinical Cases*

World J Clin Cases 2021 October 16; 9(29): 8627-8952



Contents

Thrice Monthly Volume 9 Number 29 October 16, 2021

REVIEW

- 8627 Time to give up traditional methods for the management of gastrointestinal neuroendocrine tumours
Yozgat A, Kekilli M, Altay M

MINIREVIEWS

- 8647 Healthcare practice strategies for integrating personalized medicine: Management of COVID-19
Liu WY, Chien CW, Tung TH
- 8658 Clinical application of repetitive transcranial magnetic stimulation for post-traumatic stress disorder: A literature review
Cheng P, Zhou Y, Xu LZ, Chen YF, Hu RL, Zou YL, Li ZX, Zhang L, Shun Q, Yu X, Li LJ, Li WH
- 8666 Pros and cons of continuous glucose monitoring in the intensive care unit
Sun MT, Li IC, Lin WS, Lin GM

ORIGINAL ARTICLE

Clinical and Translational Research

- 8671 Prognostic implications of ferroptosis-associated gene signature in colon adenocarcinoma
Miao YD, Kou ZY, Wang JT, Mi DH

Retrospective Study

- 8694 Cefoperazone sodium/sulbactam sodium *vs* piperacillin sodium/tazobactam sodium for treatment of respiratory tract infection in elderly patients
Wang XX, Ma CT, Jiang YX, Ge YJ, Liu FY, Xu WG
- 8702 Modified Gant procedure for treatment of internal rectal prolapse in elderly women
Xu PP, Su YH, Zhang Y, Lu T
- 8710 Clinical and imaging features of desmoid tumors of the extremities
Shi Z, Zhao XM, Jiang JM, Li M, Xie LZ
- 8718 Retrospective analysis of surgically treated pT4b gastric cancer with pancreatic head invasion
Jin P, Liu H, Ma FH, Ma S, Li Y, Xiong JP, Kang WZ, Hu HT, Tian YT
- 8729 Development of a random forest model for hypotension prediction after anesthesia induction for cardiac surgery
Li XF, Huang YZ, Tang JY, Li RC, Wang XQ

Clinical Trials Study

- 8740** Effects of mindful breathing combined with sleep-inducing exercises in patients with insomnia
Su H, Xiao L, Ren Y, Xie H, Sun XH

Observational Study

- 8749** Chronic hepatitis-C infection in COVID-19 patients is associated with in-hospital mortality
Ronderos D, Omar AMS, Abbas H, Makker J, Baiomi A, Sun H, Mantri N, Choi Y, Fortuzi K, Shin D, Patel H, Chilimuri S
- 8763** Midazolam dose is associated with recurrence of paradoxical reactions during endoscopy
Jin EH, Song JH, Lee J, Bae JH, Chung SJ

CASE REPORT

- 8773** Isolated mass-forming IgG4-related sclerosing cholangitis masquerading as extrahepatic cholangiocarcinoma: A case report
Song S, Jo S
- 8782** *Salmonella typhi* infection-related appendicitis: A case report
Zheng BH, Hao WM, Lin HC, Shang GG, Liu H, Ni XJ
- 8789** ACTA2 mutation is responsible for multisystemic smooth muscle dysfunction syndrome with seizures: A case report and review of literature
Yang WX, Zhang HH, Hu JN, Zhao L, Li YY, Shao XL
- 8797** Whole-genome amplification/preimplantation genetic testing for propionic acidemia of successful pregnancy in an obligate carrier Mexican couple: A case report
Neumann A, Alcantara-Ortigoza MA, González-del Angel A, Zarate Díaz NA, Santana JS, Porchia LM, López-Bayghen E
- 8804** Is mannitol combined with furosemide a new treatment for refractory lymphedema? A case report
Kim HS, Lee JY, Jung JW, Lee KH, Kim MJ, Park SB
- 8812** Successful treatment of floating splenic volvulus: Two case reports and a literature review
Sun C, Li SL
- 8820** Removal of "ruptured" pulmonary artery infusion port catheter by pigtail catheter combined with gooseneck trap: A case report
Chen GQ, Wu Y, Zhao KF, Shi RS
- 8825** Isolated neutropenia caused by copper deficiency due to jejunal feeding and excessive zinc intake: A case report
Ohmori H, Kodama H, Takemoto M, Yamasaki M, Matsumoto T, Kumode M, Miyachi T, Sumimoto R
- 8831** Diagnosis and treatment of eosinophilic fasciitis: Report of two cases
Song Y, Zhang N, Yu Y
- 8839** Familial left cervical neurofibromatosis 1 with scoliosis: A case report
Mu X, Zhang HY, Shen YH, Yang HY

- 8846** Successful treatment after toxic epidermal necrolysis induced by AZD-9291 in a patient with non-small cell lung cancer: A case report
Li W, He X, Liu H, Zhu J, Zhang HM
- 8852** Anesthesia management in a pediatric patient with Becker muscular dystrophy undergoing laparoscopic surgery: A case report
Peng L, Wei W
- 8858** Diagnosis of upper gastrointestinal perforation complicated with fistula formation and subphrenic abscess by contrast-enhanced ultrasound: A case report
Qiu TT, Fu R, Luo Y, Ling WW
- 8864** Adenomyoepithelioma of the breast with malignant transformation and repeated local recurrence: A case report
Oda G, Nakagawa T, Mori M, Fujioka T, Onishi I
- 8871** Primary intracranial synovial sarcoma with hemorrhage: A case report
Wang YY, Li ML, Zhang ZY, Ding JW, Xiao LF, Li WC, Wang L, Sun T
- 8879** Lumbar infection caused by *Mycobacterium paragordoniae*: A case report
Tan YZ, Yuan T, Tan L, Tian YQ, Long YZ
- 8888** Primary intratracheal neurilemmoma in a 10-year-old girl: A case report
Wu L, Sha MC, Wu XL, Bi J, Chen ZM, Wang YS
- 8894** Ovarian pregnancy rupture following ovulation induction and intrauterine insemination: A case report
Wu B, Li K, Chen XF, Zhang J, Wang J, Xiang Y, Zhou HG
- 8901** Delayed diagnosis of imperforate hymen with huge hematocolpometra: A case report
Jang E, So KA, Kim B, Lee AJ, Kim NR, Yang EJ, Shim SH, Lee SJ, Kim TJ
- 8906** Acute pancreatitis with hypercalcemia caused by primary hyperparathyroidism associated with paraneoplastic syndrome: A case report and review of literature
Yang L, Lin Y, Zhang XQ, Liu B, Wang JY
- 8915** Use of a modified tracheal tube in a child with traumatic bronchial rupture: A case report and review of literature
Fan QM, Yang WG
- 8923** Isolated liver metastasis detected 11 years after the curative resection of rectal cancer: A case report
Yonenaga Y, Yokoyama S
- 8932** Severe bleeding after operation of preauricular fistula: A case report
Tian CH, Chen XJ
- 8938** Secondary aorto-esophageal fistula initially presented with empyema after thoracic aortic stent grafting: A case report
Wang DQ, Liu M, Fan WJ

- 8946** Disruption of sensation-dependent bladder emptying due to bladder overdistension in a complete spinal cord injury: A case report

Yoon JY, Kim DS, Kim GW, Won YH, Park SH, Ko MH, Seo JH

ABOUT COVER

Editorial Board Member of *World Journal of Clinical Cases*, Jjiang-Huei Jeng, DDS, PhD, Professor, School of Dentistry and Department of Dentistry, National Taiwan University Medical College and National Taiwan University Hospital, School of Dentistry, College of Dental Medicine, Kaohsiung Medical University, Taipei 100, Taiwan. jhjeng@ntu.edu.tw

AIMS AND SCOPE

The primary aim of *World Journal of Clinical Cases* (*WJCC*, *World J Clin Cases*) is to provide scholars and readers from various fields of clinical medicine with a platform to publish high-quality clinical research articles and communicate their research findings online.

WJCC mainly publishes articles reporting research results and findings obtained in the field of clinical medicine and covering a wide range of topics, including case control studies, retrospective cohort studies, retrospective studies, clinical trials studies, observational studies, prospective studies, randomized controlled trials, randomized clinical trials, systematic reviews, meta-analysis, and case reports.

INDEXING/ABSTRACTING

The *WJCC* is now indexed in Science Citation Index Expanded (also known as SciSearch®), Journal Citation Reports/Science Edition, Scopus, PubMed, and PubMed Central. The 2021 Edition of Journal Citation Reports® cites the 2020 impact factor (IF) for *WJCC* as 1.337; IF without journal self cites: 1.301; 5-year IF: 1.742; Journal Citation Indicator: 0.33; Ranking: 119 among 169 journals in medicine, general and internal; and Quartile category: Q3. The *WJCC*'s CiteScore for 2020 is 0.8 and Scopus CiteScore rank 2020: General Medicine is 493/793.

RESPONSIBLE EDITORS FOR THIS ISSUE

Production Editor: Jia-Hui Li; Production Department Director: Xiang Li; Editorial Office Director: Jin-Lei Wang.

NAME OF JOURNAL

World Journal of Clinical Cases

ISSN

ISSN 2307-8960 (online)

LAUNCH DATE

April 16, 2013

FREQUENCY

Thrice Monthly

EDITORS-IN-CHIEF

Dennis A Bloomfield, Sandro Vento, Bao-Gan Peng

EDITORIAL BOARD MEMBERS

<https://www.wjgnet.com/2307-8960/editorialboard.htm>

PUBLICATION DATE

October 16, 2021

COPYRIGHT

© 2021 Baishideng Publishing Group Inc

INSTRUCTIONS TO AUTHORS

<https://www.wjgnet.com/bpg/gerinfo/204>

GUIDELINES FOR ETHICS DOCUMENTS

<https://www.wjgnet.com/bpg/GerInfo/287>

GUIDELINES FOR NON-NATIVE SPEAKERS OF ENGLISH

<https://www.wjgnet.com/bpg/gerinfo/240>

PUBLICATION ETHICS

<https://www.wjgnet.com/bpg/GerInfo/288>

PUBLICATION MISCONDUCT

<https://www.wjgnet.com/bpg/gerinfo/208>

ARTICLE PROCESSING CHARGE

<https://www.wjgnet.com/bpg/gerinfo/242>

STEPS FOR SUBMITTING MANUSCRIPTS

<https://www.wjgnet.com/bpg/GerInfo/239>

ONLINE SUBMISSION

<https://www.f6publishing.com>



Disruption of sensation-dependent bladder emptying due to bladder overdistension in a complete spinal cord injury: A case report

Ju-Yul Yoon, Da-Sol Kim, Gi-Wook Kim, Yu Hui Won, Sung-Hee Park, Myoung-Hwan Ko, Jeong-Hwan Seo

ORCID number: Ju-Yul Yoon 0000-0002-2379-6158; Da-Sol Kim 0000-0002-7745-978X; Gi-Wook Kim 0000-0002-1628-8382; Yu Hui Won 0000-0003-2007-9652; Sung-Hee Park 0000-0002-4743-2551; Myoung-Hwan Ko 0000-0002-0566-3677; Jeong-Hwan Seo 0000-0002-6915-6674.

Author contributions: Seo JH contributed to the concept; Kim DS, Kim GW, and Won YH contributed to the design of the study and acquisition of data; Park SH and Ko MH contributed to the analysis and interpretation of data; Seo JH and Yoon JY contributed to the drafting of the article and revising it critically for important intellectual content; all authors have read and approved the final manuscript.

Informed consent statement: Informed written consent was obtained from the patient for the publication of this report and any accompanying images.

Conflict-of-interest statement: The authors declare that they have no conflicts of interest.

CARE Checklist (2016) statement: The authors have read the CARE Checklist (2016), and the manuscript was prepared and revised according to the CARE Checklist (2016).

Ju-Yul Yoon, Department of Physical Medicine and Rehabilitation, Jeonbuk National University Medical School, Jeonju 54097, Jeonbuk, South Korea

Da-Sol Kim, Gi-Wook Kim, Yu Hui Won, Sung-Hee Park, Myoung-Hwan Ko, Jeong-Hwan Seo, Department of Physical Medicine and Rehabilitation, Jeonbuk National University Medical School, Korea Research Institute of Clinical Medicine of Jeonbuk National University – Biomedical Research Institute of Jeonbuk National University Hospital, Jeonju 54097, Jeonbuk, South Korea

Corresponding author: Jeong-Hwan Seo, MD, PhD, Professor, Department of Physical Medicine and Rehabilitation, Jeonbuk National University Medical School, Korea Research Institute of Clinical Medicine of Jeonbuk National University – Biomedical Research Institute of Jeonbuk National University Hospital, Geonjiro 20, Deokjin-gu, Jeonju 54097, Jeonbuk, South Korea. vivaseo@jbnu.ac.kr

Abstract

BACKGROUND

Autonomic dysreflexia (AD) can be a life-threatening condition in patients with spinal cord injury. It is important to prevent bladder overdistension in these patients as it may trigger AD. Sensation-dependent bladder emptying (SDBE), as a method of bladder management, improves the quality of life and allows physiologic voiding. In this study, we report disruption of the SDBE habit after bladder overdistension leading to AD with chest pain.

CASE SUMMARY

A 47-year-old male with a diagnosis of C4 American Spinal Cord Injury Association impairment scale A had been emptying his bladder using the clean intermittent catheterization method with an itchy sensation in the nose as a sensory indication for a full bladder for 23 years, and the usual urine volume was about 300-400 mL. At the time of this study, the patient had delayed catheterization for approximately five hours. He developed severe abdominal pain and headache and had to visit the emergency room for bladder overdistension (800 mL) and a high systolic blood pressure (205 mmHg). After control of AD, a hypersensitive bladder was observed despite using anticholinergic agents. The sensation indicating bladder fullness changed from nose itching to pain in the abdomen and precordial area. Moreover, the volume of the painful bladder filling sensation became highly variable and was noted when the bladder urine volume exceeded only 100 mL. The patient refused intermittent clean catheterization.

Open-Access: This article is an open-access article that was selected by an in-house editor and fully peer-reviewed by external reviewers. It is distributed in accordance with the Creative Commons Attribution NonCommercial (CC BY-NC 4.0) license, which permits others to distribute, remix, adapt, build upon this work non-commercially, and license their derivative works on different terms, provided the original work is properly cited and the use is non-commercial. See: <http://creativecommons.org/licenses/by-nc/4.0/>

Manuscript source: Unsolicited manuscript

Specialty type: Medicine, research and experimental

Country/Territory of origin: South Korea

Peer-review report's scientific quality classification

Grade A (Excellent): 0
Grade B (Very good): B
Grade C (Good): C
Grade D (Fair): 0
Grade E (Poor): 0

Received: July 10, 2021

Peer-review started: July 10, 2021

First decision: July 26, 2021

Revised: July 27, 2021

Accepted: August 18, 2021

Article in press: August 18, 2021

Published online: October 16, 2021

P-Reviewer: Mizuno H, Sikiric P

S-Editor: Yan JP

L-Editor: A

P-Editor: Li X



Finally, a cystostomy was performed, which relieved the symptoms.

CONCLUSION

Patients using physiologic feedback, such as SDBE, for bladder management are recommended to avoid bladder overdistension.

Key Words: Neurogenic bladder; Sensation-dependent bladder emptying; Spinal cord injury; Autonomic dysreflexia; Bladder overdistension; Bladder management; Case report

©The Author(s) 2021. Published by Baishideng Publishing Group Inc. All rights reserved.

Core Tip: In this report, sensation-dependent bladder emptying (SDBE), which had been maintained for 23 years, was disrupted after bladder overdistension that led to autonomic dysreflexia (AD) in a patient with complete spinal cord injury (SCI). After the AD due to bladder overdistension, the bladder was oversensitive to even a small amount of urine, resulting in unbearable discomfort. Cystostomy was later performed. Patients using physiologic feedback, such as SDBE, for bladder management should follow a strict bladder emptying regimen. In addition, by considering the effect of AD on bladder filling sensation in this case, we provide additional information about the mechanism of AD and "discomplete SCI."

Citation: Yoon JY, Kim DS, Kim GW, Won YH, Park SH, Ko MH, Seo JH. Disruption of sensation-dependent bladder emptying due to bladder overdistension in a complete spinal cord injury: A case report. *World J Clin Cases* 2021; 9(29): 8946-8952

URL: <https://www.wjgnet.com/2307-8960/full/v9/i29/8946.htm>

DOI: <https://dx.doi.org/10.12998/wjcc.v9.i29.8946>

INTRODUCTION

Neurogenic bladder is common in patients with spinal cord injury (SCI). Until recently, studies on the neurogenic bladder of patients with SCI, have been conducted in a search for the optimal treatment option. Because each patient's physical condition and methods of urination are different, a wider range of possible methods, both traditional and new, should be considered[1,2].

There are two main methods of bladder emptying in patients with SCI. First, time-dependent bladder emptying, by clean intermittent catheterization (CIC) at intervals of 4 to 6 h[3], is a commonly used method that facilitates bladder emptying. Second, sensation-dependent bladder emptying (SDBE) is a method in which bladder emptying is performed according to the filling sensation of the bladder using remaining sensory ability[4,5].

In SDBE, by reflecting the amount of urine produced according to fluid intake or temperature change, unnecessary catheterization can be avoided when the bladder is not adequately full. Overdistension can also be prevented even if unexpectedly rapid urine production occurs. In addition, there are reports that SDBE helps improve the quality of life[6] and reduces the probability of lower urinary tract infections[7].

In this case, we report disruption of bladder filling sensation after one event of autonomic dysreflexia (AD) due to bladder overdistension in a patient with complete SCI who had maintained SDBE for a long time.

CASE PRESENTATION

Chief complaints

A 47-year-old male presented to the emergency department with severe abdominal pain and headache.

History of present illness

The patient was diagnosed with C4 American Spinal Cord Injury Association (ASIA)

impairment scale A due to a car accident 23 years prior. The patient had a good motor grade at the C5 (elbow flexion) and C6 levels (wrist extensor), and zero grade at all levels below C6. For sensory grade, there was altered sensation below the C4 level on right side and C5 on left side, and no sensation below the T1 level (Figure 1). The patient had been using the CIC method for management of neurogenic bladder. He was able to sense bladder fullness by an itching sensation in the nose, at which time a caregiver would empty the bladder with CIC. This was maintained for approximately 23 years. The urine volume emptied by the bladder filling sense was usually 300-400 mL, and the discomfort of nasal itchiness was mild and measured two points on a visual analog scale (VAS). One day, the patient's catheterization was delayed for about five hours since the feeling of bladder fullness. Subsequently, he had to visit an emergency room for severe abdominal pain and headache.

History of past illness

At the time of the car accident with cervical cord injury 23 years earlier, the patient had a fracture of the left femur and underwent fixation surgery. Subsequently the patient underwent transfemoral amputation of the left lower extremity 7 years later due to malunion of the left distal femur fracture.

Personal and family history

The patient had an unremarkable family history.

Physical examination

Bladder overdistension (800 mL) and high systolic blood pressure (SBP, 205 mmHg) were noted. An indwelling catheter was inserted, and blood pressure was controlled with a calcium channel blocker (nifedipine 80 mg/d) and nitrates (isosorbide dinitrate 2.5 mg).

After the emergency treatment, the indwelling catheter was removed. Normal SDBE was expected as before the AD event. However, instead of the itching sensation in the nose, there was pain in the abdomen and precordial area (VAS 5), and the filling sensation did not result with a bladder volume of 300-400 mL as before. Instead, it fluctuated significantly between 100 and 400 mL (Figure 2). The patient wanted to restart the SDBE, but the change in the bladder filling sensation was very uncomfortable and unpredictable. Pain killers, including narcotics (tramadol, gabapentin, acetaminophen, celecoxib, and fentanyl), and anticholinergics (solifenacin 5 mg/d, propiverine 20 mg/d, and mirabegron 50 mg/d) did not relieve the pain or address the problem with the bladder volume. The patient underwent an urodynamic study (UDS) to examine the condition of the bladder.

Laboratory examinations

ECG and cardiac echocardiogram were performed for the precordial area pain, but no abnormal findings were observed. Urinalysis did not show pyuria or hematuria. A UDS was performed and in comparison with the UDS findings before the AD event, bladder capacity was reduced, and hypersensitivity was observed even with the use of anticholinergics (Table 1).

Imaging examinations

Abdominal computed tomography (CT) was performed for abdominal pain, and chest CT was performed on the precordial area. No abnormal findings were observed. Cystoscopy was performed to rule out bladder injuries due to overdistension. The patient did not show any abnormal findings other than chronic cystitis. The patient's cervical Magnetic resonance imaging (MRI) after the car accident is shown in Figure 1A.

FINAL DIAGNOSIS

The final diagnosis was complete SCI (C4 ASIA impairment scale A), with neurogenic bladder and persistent bladder hypersensitivity following bladder overdistension, which led to AD.

Table 1 Results of the urodynamic study

	Before AD	Post AD
Time	2018.07	2020.11
Maximal bladder volume (mL)	> 500 ¹	3702
PVR	500	370
Bladder filling sensation		
Initial feeling	350	280
Bladder fullness	400	319
Urgency	460	360
Peak detrusor pressure (mmHg)	16	15
V-U reflux	Negative	Negative

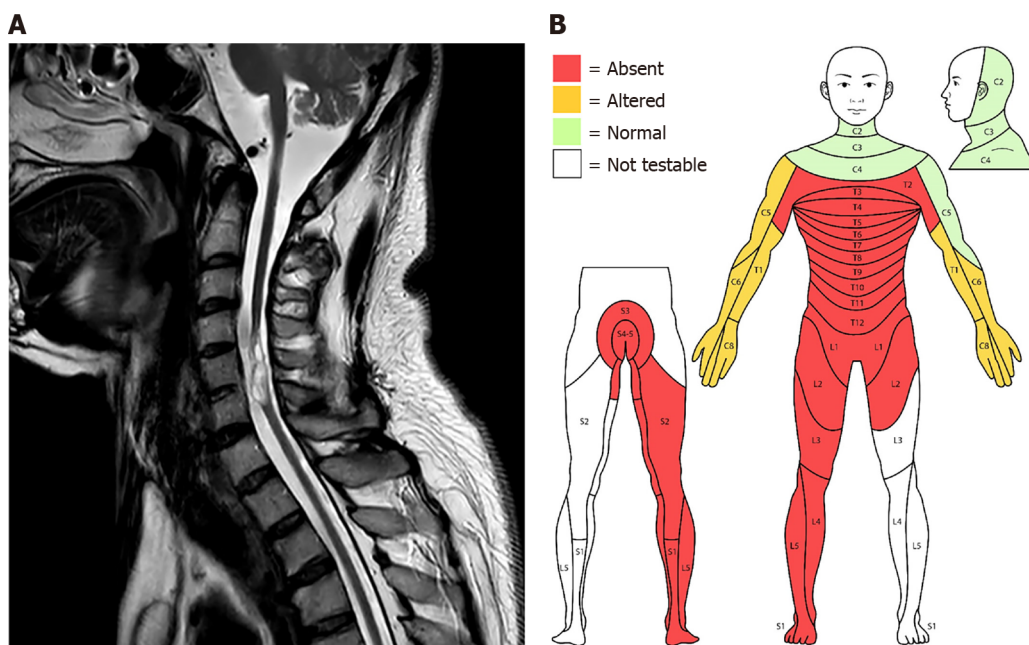
¹Infusion up to 500 mL.²Test stopped due to complaints of abdominal pain and headache. AD: Autonomic dysreflexia; PVR: Postvoid residual urine; V-U reflex: Vesicoureteral reflux.

Figure 1 Cervical magnetic resonance imaging and sensory impairment point distribution of patients. A: Severe volume loss of the spinal cord with cystic change (myelomalacia at the C5 and C6 vertebra level) was observed on magnetic resonance imaging at the time of admission with autonomic dysreflexia; B: Evaluation according to the International Standards for Neurological Classification of spinal cord injury. In the sensory test, anesthesia was observed in the region below T1. The patient underwent transfemoral amputation on the left lower extremity 16 years before.

TREATMENT

According to the results of UDS, additional anticholinergics (solifenacin 10 mg/d, propiverine 40 mg/d and mirabegron 50 mg/d) were administered, and lidocaine instillation was performed to reduce afferent noxious stimuli, but only minor improvement was observed. Timed bladder emptying with a Foley catheter at 1-2 h intervals was recommended at discharge.

OUTCOME AND FOLLOW-UP

At the three-month follow-up, the bladder filling sensation was still uncomfortable (VAS 5) and was unpredictable. The patient finally underwent cystostomy and the

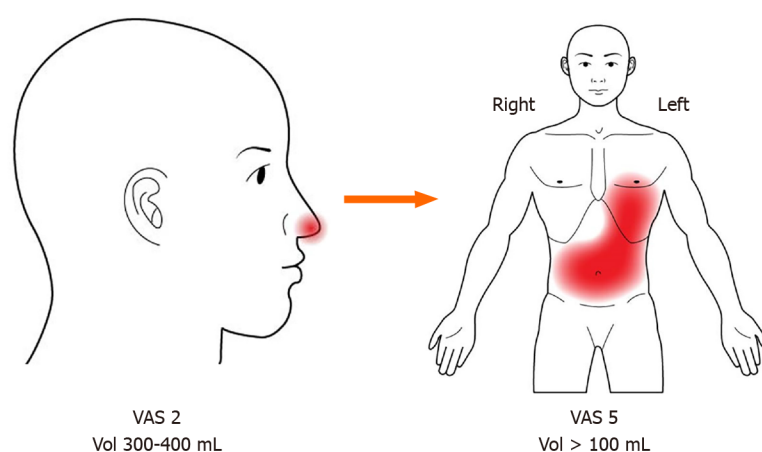


Figure 2 Changes in perception of bladder filling: Location, intensity, precision. After the onset of autonomic dysreflexia, the location of the senses for bladder fullness (nose → abdominal, precordial area) and the degree of discomfort [visual analog scale (VAS) 2 → VAS 5] changed. In addition, the bladder volume for sense of fullness became smaller and variable (300–400 mL → > 100 mL). VAS: Visual analog scale.

discomfort in the abdomen and precordial area improved slightly (VAS 5 to 4).

DISCUSSION

In this case report, a patient was diagnosed with C4 ASIA impairment scale A and maintained SDBE for approximately 23 years. An episode of AD with bladder overdistension caused detrimental changes to the bladder filling sensation (the position and intensity of the discomfort of the bladder filling changed; and fluctuation of the threshold of the bladder filling was observed), and SDBE could no longer be maintained. The patient wanted physiologic voiding through SDBE with CIC rather than surgical treatment, but ultimately cystostomy was performed.

In patients with complete SCI, SDBE is fundamentally possible under the premise that the patient is aware of bladder fullness[5]. A previous study using fMRI suggested that the perception of bladder fullness in patients with complete SCI is possible through extraspinal sensory pathways[8,9]. Furthermore, in recent studies, the concept of “discomplete SCI” has emerged. According to the ASIA impairment scale classification of SCI, the existence of a reproducible ambiguous sense can be referred to as sensory discomplete SCI, which might exist between ‘complete SCI’ and ‘incomplete SCI’. This has been proven in several studies using somatosensory evoked potential and fMRI[8,10,11]. These results provide a rationale for performing SDBE even in patients with complete SCI, such as this case.

AD is a clinical emergency that often occurs in patients with SCI above the T6 level. Among various symptoms, an increase in SBP is the most common, and clinical guidelines define it as an increase of more than 20–40 mmHg of SBP from the baseline [1,12]. Additionally, symptoms such as headache, sweating, flushing of skin, piloerection, nasal congestion, blurred vision, and anxiety may accompany elevated SBP. Headache and night sweats are observed in 88% of patients with AD[12]. Several studies have identified loss of supraspinal control, reorganization of sympathetic neurons, propriospinal plasticity, primary afferent sprouting, and peripheral adrenergic hypersensitivity as mechanisms for AD[12,13]. These mechanisms can be fundamentally interpreted as hypersensitivity and overactivity of the sympathetic spinal circuitry.

Therefore, it is necessary to elucidate how AD and bladder overdistension in this patient affected SDBE. It might be thought that the symptoms of AD are ‘directly’ reflected in the bladder filling sensation because the activation threshold of the circuit is decreased or residual activation occurs repeatedly after one AD episode. However, in this case, it is unlikely that AD directly affected the senses as there was no usual increase in SBP, even with the altered sense of bladder filling. It is unreasonable to think that the bladder filling sensation maintained for 23 years was caused by AD.

Therefore, we focused on how the AD and bladder overdistension events may have affected the sensory pathway of SDBE and proposed possible hypotheses. First, hyperactivation of the bladder afferent pathway, a common cause of AD, may affect SDBE. Bladder overdistension causes micro-damage to the bladder's urothelial cells

(bladder barrier) and increases permeability, lowering the c-fiber activation threshold and consequently delivering more nociceptive stimulation[14]. As a result, the c-fibers can be activated even with a small amount of urine in the bladder. This was shown in the UDS findings of this case, as there was lower bladder capacity and hypersensitivity (Table 1). For the same reason, there is a possibility that the previous bladder fullness sensation may become perceived as pain (Figure 2; VAS 2 to 5), and fluctuations in the urine volume threshold for bladder fullness sensation may have occurred due to inconsistent activation of the c-fibers (Figure 2; bladder urine volume > 100 mL).

Second, the reorganization of several spinal pathways after AD affects the sensory pathways of SDBE. Reorganization of the sympathetic preganglionic neurons and propriospinal neurons is an established mechanism of AD[12,13], and it has been reported that activation of these pathways may affect sensory neurons[12,15]. This may be a clue to the changes of the body part reflecting bladder filling and the worsening of the discomfort level shown in this case (Figure 2; nose to precordial area & abdomen).

Third, as extraspinal sensory pathways, maladaptation of the vagus nerve after AD may affect SDBE. Kruhut *et al*[9] suggested that a sensory extraspinal pathway may develop following complete SCI, and the vagus nerve may play an important role in bladder re-innervation. The vagus nerve innervates the visceral sensory parts of the esophagus, lungs, heart, and most of the digestive system[16]. In this case, the fact that the sensory location reflecting bladder filling moved to the abdominal and precordial regions (Figure 2), which receive sensory innervation through the vagus nerve, supports this hypothesis. In addition, the vagus nerve has parasympathetic properties and is in a compensatory relationship with the sympathetic system. Overactivation or maladaptation of the vagal pathway might occur due to an overcompensatory response of the parasympathetic system to the overactivation of the sympathetic system such as in AD.

CONCLUSION

In a single episode of bladder overdistension causing AD, the pattern of SDBE, which had been well-maintained for many years, was disrupted in a patient with complete SCI. Therefore, we emphasize that avoidance of bladder overdistension in patients with SCI, especially with the use of SDBE.

ACKNOWLEDGMENTS

The authors thank all members of the Department of Physical Medicine & Rehabilitation and Translational Research and Clinical Trials Center for Medical Devices, Jeonbuk National University Hospital.

REFERENCES

- 1 Krassioukov A, Warburton DE, Teasell R, Eng JJ; Spinal Cord Injury Rehabilitation Evidence Research Team. A systematic review of the management of autonomic dysreflexia after spinal cord injury. *Arch Phys Med Rehabil* 2009; **90**: 682-695 [PMID: 19345787 DOI: 10.1016/j.apmr.2008.10.017]
- 2 Wyndaele JJ. The management of neurogenic lower urinary tract dysfunction after spinal cord injury. *Nat Rev Urol* 2016; **13**: 705-714 [PMID: 27779229 DOI: 10.1038/nrurol.2016.206]
- 3 Goldmark E, Niver B, Ginsberg DA. Neurogenic bladder: from diagnosis to management. *Curr Urol Rep* 2014; **15**: 448 [PMID: 25118855 DOI: 10.1007/s11934-014-0448-8]
- 4 Ersoz M, Akyuz M. Bladder-filling sensation in patients with spinal cord injury and the potential for sensation-dependent bladder emptying. *Spinal Cord* 2004; **42**: 110-116 [PMID: 14765144 DOI: 10.1038/sj.sc.3101525]
- 5 Shin JC, Chang WH, Jung TH, Yoo JH, Park SN. The determination of sensation-dependent bladder emptying time in patients with complete spinal cord injury above T11. *Spinal Cord* 2008; **46**: 210-215 [PMID: 17646839 DOI: 10.1038/sj.sc.3102102]
- 6 Adriaansen JJ, van Asbeck FW, Tepper M, Faber WX, Visser-Meily JM, de Kort LM, Post MW. Bladder-emptying methods, neurogenic lower urinary tract dysfunction and impact on quality of life in people with long-term spinal cord injury. *J Spinal Cord Med* 2017; **40**: 43-53 [PMID: 26446581 DOI: 10.1179/2045772315Y.0000000056]
- 7 Ersöz M, Sayılır S. Protective effect of preserved bladder-filling sensation on upper urinary tract in

- patients with spinal cord injury. *Neurol Sci* 2014; **35**: 1549-1552 [PMID: [24748479](#) DOI: [10.1007/s10072-014-1792-7](#)]
- 8 **Finnerup NB**, Gyldensted C, Fuglsang-Frederiksen A, Bach FW, Jensen TS. Sensory perception in complete spinal cord injury. *Acta Neurol Scand* 2004; **109**: 194-199 [PMID: [14763957](#) DOI: [10.1034/j.1600-0404.2003.00219.x](#)]
- 9 **Krhut J**, Tintera J, Bilkova K, Holy P, Zachoval R, Zvara P, Blok B. Brain activity on fMRI associated with urinary bladder filling in patients with a complete spinal cord injury. *Neurol Urodyn* 2017; **36**: 155-159 [PMID: [26445209](#) DOI: [10.1002/nau.22901](#)]
- 10 **Awad A**, Levi R, Waller M, Westling G, Lindgren L, Eriksson J. Preserved somatosensory conduction in complete spinal cord injury: Discomplete SCI. *Clin Neurophysiol* 2020; **131**: 1059-1067 [PMID: [32197128](#) DOI: [10.1016/j.clinph.2020.01.017](#)]
- 11 **Wrigley PJ**, Siddall PJ, Gustin SM. New evidence for preserved somatosensory pathways in complete spinal cord injury: A fMRI study. *Hum Brain Mapp* 2018; **39**: 588-598 [PMID: [29080262](#) DOI: [10.1002/hbm.23868](#)]
- 12 **Eldahan KC**, Rabchevsky AG. Autonomic dysreflexia after spinal cord injury: Systemic pathophysiology and methods of management. *Auton Neurosci* 2018; **209**: 59-70 [PMID: [28506502](#) DOI: [10.1016/j.autneu.2017.05.002](#)]
- 13 **Linsenmeyer TA**, Gibbs K, Solinsky R. Autonomic Dysreflexia After Spinal Cord Injury: Beyond the Basics. *Curr Physical Med Rehabil Rep* 2020; **8**: 1-9 [DOI: [10.1007/s40141-020-00300-5](#)]
- 14 **Apodaca G**, Kiss S, Ruiz W, Meyers S, Zeidel M, Birder L. Disruption of bladder epithelium barrier function after spinal cord injury. *Am J Physiol Renal Physiol* 2003; **284**: F966-F976 [PMID: [12527557](#) DOI: [10.1152/ajprenal.00359.2002](#)]
- 15 **Schramm LP**. Spinal sympathetic interneurons: their identification and roles after spinal cord injury. *Prog Brain Res* 2006; **152**: 27-37 [PMID: [16198691](#) DOI: [10.1016/S0079-6123\(05\)52002-8](#)]
- 16 **Craig AD**. Interoception: the sense of the physiological condition of the body. *Curr Opin Neurobiol* 2003; **13**: 500-505 [PMID: [12965300](#) DOI: [10.1016/s0959-4388\(03\)00090-4](#)]



Published by **Baishideng Publishing Group Inc**
7041 Koll Center Parkway, Suite 160, Pleasanton, CA 94566, USA

Telephone: +1-925-3991568

E-mail: bpgoffice@wjgnet.com

Help Desk: <https://www.f6publishing.com/helpdesk>

<https://www.wjgnet.com>

