

World Journal of *Clinical Cases*

World J Clin Cases 2021 January 26; 9(3): 521-763



Contents

Thrice Monthly Volume 9 Number 3 January 26, 2021

MINIREVIEWS

- 521 Role of argon plasma coagulation in treatment of esophageal varices
Song Y, Feng Y, Sun LH, Zhang BJ, Yao HJ, Qiao JG, Zhang SF, Zhang P, Liu B
- 528 Clinical features and potential mechanism of coronavirus disease 2019-associated liver injury
Han MW, Wang M, Xu MY, Qi WP, Wang P, Xi D

ORIGINAL ARTICLE

Retrospective Study

- 540 Circulating immune parameters-based nomogram for predicting malignancy in laryngeal neoplasm
Chen M, Fang Y, Yang Y, He PJ, Cheng L, Wu HT
- 552 Role of ammonia in predicting the outcome of patients with acute-on-chronic liver failure
Chiriac S, Stanciu C, Cojocariu C, Singeap AM, Sfarti C, Cuciureanu T, Girleanu I, Igna RA, Trifan A
- 565 Impact of different stereoisomers of inositol on insulin sensitivity of gestational diabetes mellitus patients
He J, Zhang YL, Wang LP, Liu XC

Observational Study

- 573 Fascial space odontogenic infections: Ultrasonography as an alternative to magnetic resonance imaging
Ghali S, Katti G, Shahbaz S, Chitroda PK, V Anukriti, Divakar DD, Khan AA, Naik S, Al-Kheraif AA, Jhugroo C

SYSTEMATIC REVIEWS

- 581 Clinical benefit of COX-2 inhibitors in the adjuvant chemotherapy of advanced non-small cell lung cancer: A systematic review and meta-analysis
Xu YQ, Long X, Han M, Huang MQ, Lu JF, Sun XD, Han W

CASE REPORT

- 602 Delayed cardiac tamponade diagnosed by point-of-care ultrasound in a neonate after peripherally inserted central catheter placement: A case report
Cui Y, Liu K, Luan L, Liang P
- 607 Facial microcystic adnexal carcinoma — treatment with a “jigsaw puzzle” advancement flap and immediate esthetic reconstruction: A case report
Xiao YD, Zhang MZ, Zeng A
- 614 Nephrotic syndrome in syngeneic hematopoietic stem cell transplantation recipients: A case report
Bai MC, Wu JJ, Miao KR, Zhu JF, Mao HJ

- 623** Compound heterozygous mutations in the neuraminidase 1 gene in type 1 sialidosis: A case report and review of literature
Cao LX, Liu Y, Song ZJ, Zhang BR, Long WY, Zhao GH
- 632** Dynamic biomechanical effect of lower body positive pressure treadmill training for hemiplegic gait rehabilitation after stroke: A case report
Tang HF, Yang B, Lin Q, Liang JJ, Mou ZW
- 639** Right-heart contrast echocardiography reveals missed patent ductus arteriosus in a postpartum woman with pulmonary embolism: A case report
Chen JL, Mei DE, Yu CG, Zhao ZY
- 644** Treatment of cervical spine metastasis with minimally invasive cervical spondylectomy: A case report and literature review
He LM, Ma X, Chen C, Zhang HY
- 651** Successful treatment of pyogenic ventriculitis caused by extensively drug-resistant *Acinetobacter baumannii* with multi-route tigecycline: A case report
Li W, Li DD, Yin B, Lin DD, Sheng HS, Zhang N
- 659** Radical resection of hepatic polycystic echinococcosis complicated with hepatocellular carcinoma: A case report
Kalifu B, Meng Y, Maimaitinijati Y, Ma ZG, Tian GL, Wang JG, Chen X
- 666** Pleural lump after paragonimiasis treated by thoracoscopy: A case report
Xie Y, Luo YR, Chen M, Xie YM, Sun CY, Chen Q
- 672** Deep vein thrombosis in patient with left-sided inferior vena cava draining into the hemiazygos vein: A case report
Zhang L, Guan WK
- 677** Recurrent Takotsubo cardiomyopathy triggered by emotionally stressful events: A case report
Wu HY, Cheng G, Liang L, Cao YW
- 685** Oral and perioral herpes simplex virus infection type I in a five-month-old infant: A case report
Aloyouny AY, Albagieh HN, Al-Serwi RH
- 690** Nasal septal foreign body as a complication of dental root canal therapy: A case report
Du XW, Zhang JB, Xiao SF
- 697** Coinheritance of *OLFM2* and *SIX6* variants in a Chinese family with juvenile-onset primary open-angle glaucoma: A case report
Yang X, Sun NN, Zhao ZN, He SX, Zhang M, Zhang DD, Yu XW, Zhang JM, Fan ZG
- 707** Systemic lupus erythematosus and antineutrophil cytoplasmic antibody-associated vasculitis overlap syndrome in a 77-year-old man: A case report
Xu ZG, Li WL, Wang X, Zhang SY, Zhang YW, Wei X, Li CD, Zeng P, Luan SD

- 714** Clinical cure and liver fibrosis reversal after postoperative antiviral combination therapy in hepatitis B-associated non-cirrhotic hepatocellular carcinoma: A case report
Yu XP, Lin Q, Huang ZP, Chen WS, Zheng MH, Zheng YJ, Li JL, Su ZJ
- 722** Severe skeletal bimaxillary protrusion treated with micro-implants and a self-made four-curvature torquing auxiliary: A case report
Liu R, Hou WB, Yang PZ, Zhu L, Zhou YQ, Yu X, Wen XJ
- 736** Cystic duct dilation through endoscopic retrograde cholangiopancreatography for treatment of gallstones and choledocholithiasis: Six case reports and review of literature
He YG, Gao MF, Li J, Peng XH, Tang YC, Huang XB, Li YM
- 748** Infectious complications during immunochemotherapy of post-transplantation lymphoproliferative disease—can we decrease the risk? Two case reports and review of literature
Gładys A, Kozak S, Wdowiak K, Winder M, Chudek J
- 758** Restenosis of a drug eluting stent on the previous bioresorbable vascular scaffold successfully treated with a drug-coated balloon: A case report
Jang HG, Kim K, Park HW, Koh JS, Jeong YH, Park JR, Kang MG

ABOUT COVER

Editorial Board Member of *World Journal of Clinical Cases*, Dr. Marcelo A F Ribeiro Jr. is Full Professor of Surgery at Pontifical Catholic University – PUC Sorocaba – General and Trauma Surgery, and Professor of the Post-Graduation Program in Surgery, IAMSPE São Paulo (Brazil). He serves as Member and Fellow of the Brazilian College of Surgeons, Brazilian College of Digestive Surgery, Brazilian Trauma Society (General Secretary), American College of Surgeons, American Association for the Surgery of Trauma, Eastern Association for the Surgery of Trauma, and Pan-American Trauma Society (being Chairman of the Education Committee and Member of the Board). (L-Editor: Filipodia)

AIMS AND SCOPE

The primary aim of *World Journal of Clinical Cases* (WJCC, *World J Clin Cases*) is to provide scholars and readers from various fields of clinical medicine with a platform to publish high-quality clinical research articles and communicate their research findings online.

WJCC mainly publishes articles reporting research results and findings obtained in the field of clinical medicine and covering a wide range of topics, including case control studies, retrospective cohort studies, retrospective studies, clinical trials studies, observational studies, prospective studies, randomized controlled trials, randomized clinical trials, systematic reviews, meta-analysis, and case reports.

INDEXING/ABSTRACTING

The WJCC is now indexed in Science Citation Index Expanded (also known as SciSearch®), Journal Citation Reports/Science Edition, Scopus, PubMed, and PubMed Central. The 2020 Edition of Journal Citation Reports® cites the 2019 impact factor (IF) for WJCC as 1.013; IF without journal self cites: 0.991; Ranking: 120 among 165 journals in medicine, general and internal; and Quartile category: Q3. The WJCC's CiteScore for 2019 is 0.3 and Scopus CiteScore rank 2019: General Medicine is 394/529.

RESPONSIBLE EDITORS FOR THIS ISSUE

Production Editor: Ji-Hong Lin; Production Department Director: Xiang Li; Editorial Office Director: Jin-Lai Wang.

NAME OF JOURNAL

World Journal of Clinical Cases

ISSN

ISSN 2307-8960 (online)

LAUNCH DATE

April 16, 2013

FREQUENCY

Thrice Monthly

EDITORS-IN-CHIEF

Dennis A Bloomfield, Sandro Vento, Bao-gan Peng

EDITORIAL BOARD MEMBERS

<https://www.wjgnet.com/2307-8960/editorialboard.htm>

PUBLICATION DATE

January 26, 2021

COPYRIGHT

© 2021 Baishideng Publishing Group Inc

INSTRUCTIONS TO AUTHORS

<https://www.wjgnet.com/bpg/gerinfo/204>

GUIDELINES FOR ETHICS DOCUMENTS

<https://www.wjgnet.com/bpg/GerInfo/287>

GUIDELINES FOR NON-NATIVE SPEAKERS OF ENGLISH

<https://www.wjgnet.com/bpg/gerinfo/240>

PUBLICATION ETHICS

<https://www.wjgnet.com/bpg/GerInfo/288>

PUBLICATION MISCONDUCT

<https://www.wjgnet.com/bpg/gerinfo/208>

ARTICLE PROCESSING CHARGE

<https://www.wjgnet.com/bpg/gerinfo/242>

STEPS FOR SUBMITTING MANUSCRIPTS

<https://www.wjgnet.com/bpg/GerInfo/239>

ONLINE SUBMISSION

<https://www.f6publishing.com>



Deep vein thrombosis in patient with left-sided inferior vena cava draining into the hemiazygos vein: A case report

Li Zhang, Wei-Kang Guan

ORCID number: Li Zhang 0000-0002-8229-9493; Wei-Kang Guan 0000-0002-6527-8930.

Author contributions: Zhang L designed the research study; Guan WK performed the research; Zhang L and Guan WK analyzed the data and wrote the manuscript; All authors have read and approve the final manuscript.

Informed consent statement: Informed written consent was obtained from the patient for publication of this report and any accompanying images.

Conflict-of-interest statement: The authors declare that they have no conflicts of interest related to this manuscript.

CARE Checklist (2016) statement: The authors have read the CARE Checklist (2016), and the manuscript was prepared and revised according to the CARE Checklist (2016).

Open-Access: This article is an open-access article that was selected by an in-house editor and fully peer-reviewed by external reviewers. It is distributed in accordance with the Creative Commons Attribution NonCommercial (CC BY-NC 4.0) license, which permits others to distribute, remix, adapt, build

Li Zhang, Wei-Kang Guan, Department of Vascular Surgery, Dazhou Central Hospital, Dazhou 635000, Sichuan Province, China

Corresponding author: Li Zhang, MD, Associate Chief Physician, Department of Vascular Surgery, Dazhou Central Hospital, No. 56 Nanyuemiao Street, Tongchuan District, Dazhou 635000, Sichuan Province, China. 50328731@qq.com

Abstract

BACKGROUND

Abnormalities of the inferior vena cava (IVC) are uncommon, and in many cases they are asymptomatic. Even so, it is vital that clinicians be aware of such anomalies prior to surgery in affected individuals. In the present report, we describe a rare anatomical variation of the IVC.

CASE SUMMARY

A 66-year-old male was admitted to the hospital due to deep vein thrombosis of the right lower extremity. Upon contrast-enhanced computed tomography imaging, we found that this patient presented with a case of left-sided IVC draining into the hemiazygos vein, while his hepatic vein was directly draining into the atrium.

CONCLUSION

Cases of left-sided IVC can increase patient susceptibility to thromboembolism owing to the resultant changes in blood flow and/or associated vascular compression.

Key Words: Left-sided inferior vena cava; Deep vein thrombosis; Hemiazygos vein; Anatomic variation; Case report

©The Author(s) 2021. Published by Baishideng Publishing Group Inc. All rights reserved.

Core Tip: We found that one patient with deep venous thrombosis had left-sided inferior vena cava draining into the hemiazygos vein, while his hepatic vein was directly draining into the atrium. It is vital that clinicians be aware of such anomalies prior to surgery in affected individuals.

upon this work non-commercially, and license their derivative works on different terms, provided the original work is properly cited and the use is non-commercial. See: <http://creativecommons.org/licenses/by-nc/4.0/>

Manuscript source: Unsolicited manuscript

Specialty type: Medicine, research and experimental

Country/Territory of origin: China

Peer-review report's scientific quality classification

Grade A (Excellent): 0
Grade B (Very good): B
Grade C (Good): C, C, C
Grade D (Fair): D
Grade E (Poor): 0

Received: September 5, 2020

Peer-review started: September 5, 2020

First decision: November 14, 2020

Revised: November 22, 2020

Accepted: December 6, 2020

Article in press: December 6, 2020

Published online: January 26, 2021

P-Reviewer: Hashimoto N, Sirin G, Teramoto-Matsubara OT

S-Editor: Huang P

L-Editor: Filipodia

P-Editor: Li JH



Citation: Zhang L, Guan WK. Deep vein thrombosis in patient with left-sided inferior vena cava draining into the hemiazygos vein: A case report. *World J Clin Cases* 2021; 9(3): 672-676

URL: <https://www.wjgnet.com/2307-8960/full/v9/i3/672.htm>

DOI: <https://dx.doi.org/10.12998/wjcc.v9.i3.672>

INTRODUCTION

As noninvasive vascular imaging technologies have become increasingly advanced, a number of different anatomic variations in the structure of the inferior vena cava (IVC) have been observed in clinical practice. The development of the IVC is complex and relies upon the formation of connections between three paired embryonic veins, resulting in multiple potential variations in the overall venous architecture. It is important that medical professionals understand these variations and their clinical implications so that they can properly diagnose and treat patients affected by conditions such as deep vein thrombosis (DVT).

CASE PRESENTATION

Chief complaints

A 66-year-old male presented with pain and edema of the right leg for 2 d.

History of present illness

Pain and edema of the right leg for 2 d prior to hospital admission, no fever, chest pain, or dyspnea.

History of past illness

Multiple soft tissue injuries caused by falls 12 d before admission.

Personal and family history

The patient had no remarkable personal or family history.

Physical examination

Swelling of the right lower extremity with palpable pitting edema, normal skin temperature, and a good arterial pulse within this extremity.

Laboratory examinations

At the time of admission, the patient had a D-dimer level of 2789 ng/mL (NG, 0-500 ng/mL).

Imaging examinations

At the time of admission, color Doppler ultrasonography revealed right iliac-femoral vein thrombosis with decreased distal blood flow velocity. In order to accurately assess the anatomy of the retroperitoneal venous system in this patient, contrast-enhanced computed tomography was conducted after the thrombolysis procedure, which revealed that the right common iliac vein was located behind the left common iliac artery and was clearly compressed and stenotic. Many collateral vessels had formed in the pelvic cavity, and the left iliac vein was significantly wider than that on the right side. Abnormal left-sided IVC drainage was the result of the union of the two common iliac veins at the level of the 4th lumbar vertebra. It ascended vertically to the left side of the abdominal aorta where it connected with the left and right renal vein at the levels of the 2nd and 3rd lumbar vertebrae, respectively. The right renal vein additionally crossed posteriorly to the abdominal aorta. The left-sided IVC continued to ascend and intersected with the hemiazygos vein at the level of the 2nd lumbar vertebra, after which it crossed posteriorly to the left diaphragm crura and entered the thorax. It then ascended through the posterior mediastinum to the left of the four inferior thoracic vertebrae, crossing posteriorly to the thoracic aorta and the azygos vein at the level of 8th thoracic vertebra, arching over the root of the right lung and joining the right superior vena cava at the level of the 5th thoracic vertebra. There was no retrohepatic IVC or right IVC in this patient, and the hepatic vein drained directly into the right atrium (Figures 1 and 2). No other anatomic anomalies were detected in

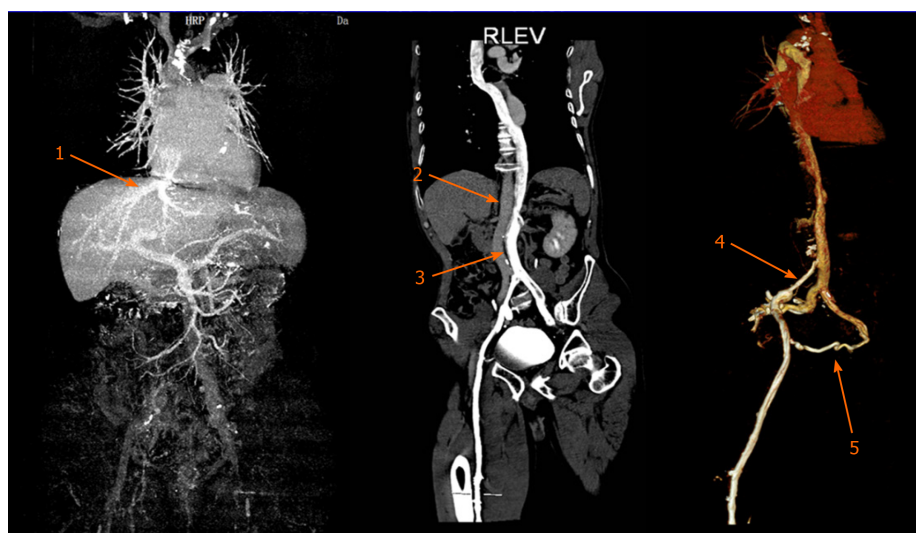


Figure 1 Contrast-enhanced computed tomography revealing a case of left-sided inferior vena cava draining into the hemiazygos vein with the hepatic vein directly draining into the atrium. 1: The hepatic vein directly draining into the atrium; 2: The abdominal aorta; 3: The left-sided inferior vena cava; 4: Right iliac vein stenosis; 5: Collateral vessels.

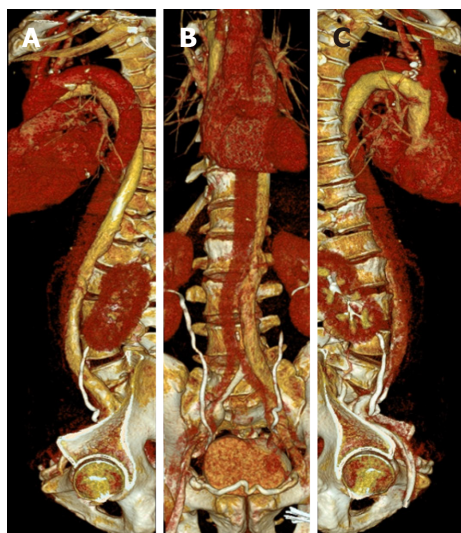


Figure 2 Three-dimensional reconstructed lateral and frontal views of the left inferior vena cava, vertebrae and the azygos venous system. A: T8: 8th thoracic vertebra; B: T12: 12th thoracic vertebra; C: T5: 5th thoracic vertebra.

this patient, and echocardiographic findings were normal.

FINAL DIAGNOSIS

DVT of right lower extremity, variation of IVC, multiple soft tissue injuries.

TREATMENT

When the patient underwent phlebography, a rare anatomical variation in the structure of the IVC was detected. Specifically, the patient exhibited a case of left-sided IVC draining into the hemiazygos vein. The renal vein drained into the left-sided IVC below its typical anatomic position. The patient was treated for DVT of the lower right extremity *via* catheter-directed thrombolysis and experienced significant symptom improvement after 4 d. Subsequent phlebography revealed right iliac vein stenosis with collateral vessel formation. As the primary symptoms associated with this case of

DVT had been alleviated, no further treatment of iliac vein stenosis was administered other than warfarin anticoagulant therapy.

OUTCOME AND FOLLOW-UP

The swelling of the right lower extremity disappeared, and the limbs were not swollen after exercise. Color Doppler ultrasound examination showed that the right lower extremity vein was unobstructed, and there was no recurrence of thrombus.

DISCUSSION

There have been several previous reports of anatomic IVC variability^[1]. Azygos continuation of the IVC has, in previous reports, been described as the absence of the hepatic segment of the IVC with azygos continuation. Overall, this anatomic variation has a 0.6% prevalence and is thought to arise due to a failure of right subcardinal-hepatic anastomosis during embryonic development, which ultimately causes the right subcardinal vein to atrophy. There have been even fewer reports of hemiazygos continuation of left-sided IVC^[2]. In most cases, IVC anomalies present from birth are asymptomatic and are only discovered incidentally when patients are undergoing abdominal surgery or imaging evaluations^[3-5]. As such, the true prevalence of IVC anomalies is likely higher than current estimates. These anomalies have been diagnosed and studied using a range of techniques, with helical computed tomography being an efficient and reliable modality that is commonly used for such evaluations^[6].

Hemiazygous IVC continuation can result in dilatation that may be misinterpreted as a mediastinal or paracardiac mass upon radiographic assessment. Patients with this continuation are additionally at risk of accidental ligation of the IVC during thoracic surgery^[7]. It is therefore essential that such anatomic variations be preoperatively identified using appropriate imaging techniques in order to minimize the risk of surgical complications in affected individuals.

In the present case, phlebography led to the diagnosis of DVT of the right leg as well as the presence of a rare anatomical variation wherein the patient exhibited left-sided IVC draining into the hemiazygos vein. Contrast-enhanced computed tomography imaging revealed that the right common iliac vein was behind the left common iliac artery with clear evidence of stenosis and compression. In addition, several collateral vessels were evident within the pelvic cavity, and the left iliac vein was significantly wider than that on the right side. Cases of left-sided IVC can increase patient susceptibility to thromboembolism owing to the resultant changes in blood flow and/or associated vascular compression.

CONCLUSION

There have been few prior reports of left-sided IVC draining into the hemiazygos vein, suggesting that this is a relatively rare anatomical variation. This structural anomaly may be clinically relevant to the development, treatment and prevention of venous thromboembolic events in affected individuals.

REFERENCES

- 1 **Ang WC**, Doyle T, Stringer MD. Left-sided and duplicate inferior vena cava: a case series and review. *Clin Anat* 2013; **26**: 990-1001 [PMID: 22576868 DOI: 10.1002/ca.22090]
- 2 **Berry CA**. Oblique Lumbar Interbody Fusion in Patient with Persistent Left-Sided Inferior Vena Cava: Case Report and Review of Literature. *World Neurosurg* 2019; **132**: 58-62 [PMID: 31479791 DOI: 10.1016/j.wneu.2019.08.176]
- 3 **Dilli A**, Ayaz UY, Kaplanoğlu H, Saltas H, Hekimoglu B. Evaluation of the left renal vein variations and inferior vena cava variations by means of helical computed tomography. *Clin Imaging* 2013; **37**: 530-535 [PMID: 23102929 DOI: 10.1016/j.clinimag.2012.09.012]
- 4 **Gandhi SP**, Modi P, Sutariya H, Patel K. Rare Anatomical Variation of Dual IVC with Left Sided IVC Draining into Hemiazygous Vein- A Case Report. *J Clin Diagn Res* 2016; **10**: TD14-TD15 [PMID: 27134969 DOI: 10.7860/JCDR/2016/16800.7476]

- 5 **Hong PS**, Cornett CA. Left-sided inferior vena cava in anterior lumbar spine surgery. *Spine J* 2015; **15**: 1674-1675 [PMID: [25108131](#) DOI: [10.1016/j.spinee.2014.07.024](#)]
- 6 **Spratt JD**. Inferior vena cava, portal and hepatic venous systems. In: Tubbs RS, Shoja MM, Loukas M. Bergman's Comprehensive Encyclopedia of Human Anatomic Variation. John Wiley & Sons, Inc. 2016; 877-889 [DOI: [10.1002/9781118430309.ch68](#)]
- 7 **Rajabnejad Y**, Aliakbarian M, Rajabnejad A, Motie MR. Left-Sided Inferior Vena Cava Encountered During Organ Retrieval Surgery: Report of Two Cases. *Int J Organ Transplant Med* 2016; **7**: 229-232 [PMID: [28078062](#)]



Published by **Baishideng Publishing Group Inc**
7041 Koll Center Parkway, Suite 160, Pleasanton, CA 94566, USA

Telephone: +1-925-3991568

E-mail: bpgoffice@wjgnet.com

Help Desk: <https://www.f6publishing.com/helpdesk>

<https://www.wjgnet.com>

