

World Journal of *Clinical Cases*

World J Clin Cases 2021 January 26; 9(3): 521-763



Contents

Thrice Monthly Volume 9 Number 3 January 26, 2021

MINIREVIEWS

- 521 Role of argon plasma coagulation in treatment of esophageal varices
Song Y, Feng Y, Sun LH, Zhang BJ, Yao HJ, Qiao JG, Zhang SF, Zhang P, Liu B
- 528 Clinical features and potential mechanism of coronavirus disease 2019-associated liver injury
Han MW, Wang M, Xu MY, Qi WP, Wang P, Xi D

ORIGINAL ARTICLE

Retrospective Study

- 540 Circulating immune parameters-based nomogram for predicting malignancy in laryngeal neoplasm
Chen M, Fang Y, Yang Y, He PJ, Cheng L, Wu HT
- 552 Role of ammonia in predicting the outcome of patients with acute-on-chronic liver failure
Chiriac S, Stanciu C, Cojocariu C, Singeap AM, Sfarti C, Cuciureanu T, Girleanu I, Igna RA, Trifan A
- 565 Impact of different stereoisomers of inositol on insulin sensitivity of gestational diabetes mellitus patients
He J, Zhang YL, Wang LP, Liu XC

Observational Study

- 573 Fascial space odontogenic infections: Ultrasonography as an alternative to magnetic resonance imaging
Ghali S, Katti G, Shahbaz S, Chitroda PK, V Anukriti, Divakar DD, Khan AA, Naik S, Al-Kheraif AA, Jhugroo C

SYSTEMATIC REVIEWS

- 581 Clinical benefit of COX-2 inhibitors in the adjuvant chemotherapy of advanced non-small cell lung cancer: A systematic review and meta-analysis
Xu YQ, Long X, Han M, Huang MQ, Lu JF, Sun XD, Han W

CASE REPORT

- 602 Delayed cardiac tamponade diagnosed by point-of-care ultrasound in a neonate after peripherally inserted central catheter placement: A case report
Cui Y, Liu K, Luan L, Liang P
- 607 Facial microcystic adnexal carcinoma — treatment with a “jigsaw puzzle” advancement flap and immediate esthetic reconstruction: A case report
Xiao YD, Zhang MZ, Zeng A
- 614 Nephrotic syndrome in syngeneic hematopoietic stem cell transplantation recipients: A case report
Bai MC, Wu JJ, Miao KR, Zhu JF, Mao HJ

- 623** Compound heterozygous mutations in the neuraminidase 1 gene in type 1 sialidosis: A case report and review of literature
Cao LX, Liu Y, Song ZJ, Zhang BR, Long WY, Zhao GH
- 632** Dynamic biomechanical effect of lower body positive pressure treadmill training for hemiplegic gait rehabilitation after stroke: A case report
Tang HF, Yang B, Lin Q, Liang JJ, Mou ZW
- 639** Right-heart contrast echocardiography reveals missed patent ductus arteriosus in a postpartum woman with pulmonary embolism: A case report
Chen JL, Mei DE, Yu CG, Zhao ZY
- 644** Treatment of cervical spine metastasis with minimally invasive cervical spondylectomy: A case report and literature review
He LM, Ma X, Chen C, Zhang HY
- 651** Successful treatment of pyogenic ventriculitis caused by extensively drug-resistant *Acinetobacter baumannii* with multi-route tigecycline: A case report
Li W, Li DD, Yin B, Lin DD, Sheng HS, Zhang N
- 659** Radical resection of hepatic polycystic echinococcosis complicated with hepatocellular carcinoma: A case report
Kalifu B, Meng Y, Maimaitinijati Y, Ma ZG, Tian GL, Wang JG, Chen X
- 666** Pleural lump after paragonimiasis treated by thoracoscopy: A case report
Xie Y, Luo YR, Chen M, Xie YM, Sun CY, Chen Q
- 672** Deep vein thrombosis in patient with left-sided inferior vena cava draining into the hemiazygos vein: A case report
Zhang L, Guan WK
- 677** Recurrent Takotsubo cardiomyopathy triggered by emotionally stressful events: A case report
Wu HY, Cheng G, Liang L, Cao YW
- 685** Oral and perioral herpes simplex virus infection type I in a five-month-old infant: A case report
Aloyouny AY, Albagieh HN, Al-Serwi RH
- 690** Nasal septal foreign body as a complication of dental root canal therapy: A case report
Du XW, Zhang JB, Xiao SF
- 697** Coinheritance of *OLFM2* and *SIX6* variants in a Chinese family with juvenile-onset primary open-angle glaucoma: A case report
Yang X, Sun NN, Zhao ZN, He SX, Zhang M, Zhang DD, Yu XW, Zhang JM, Fan ZG
- 707** Systemic lupus erythematosus and antineutrophil cytoplasmic antibody-associated vasculitis overlap syndrome in a 77-year-old man: A case report
Xu ZG, Li WL, Wang X, Zhang SY, Zhang YW, Wei X, Li CD, Zeng P, Luan SD

- 714** Clinical cure and liver fibrosis reversal after postoperative antiviral combination therapy in hepatitis B-associated non-cirrhotic hepatocellular carcinoma: A case report
Yu XP, Lin Q, Huang ZP, Chen WS, Zheng MH, Zheng YJ, Li JL, Su ZJ
- 722** Severe skeletal bimaxillary protrusion treated with micro-implants and a self-made four-curvature torquing auxiliary: A case report
Liu R, Hou WB, Yang PZ, Zhu L, Zhou YQ, Yu X, Wen XJ
- 736** Cystic duct dilation through endoscopic retrograde cholangiopancreatography for treatment of gallstones and choledocholithiasis: Six case reports and review of literature
He YG, Gao MF, Li J, Peng XH, Tang YC, Huang XB, Li YM
- 748** Infectious complications during immunochemotherapy of post-transplantation lymphoproliferative disease—can we decrease the risk? Two case reports and review of literature
Gładys A, Kozak S, Wdowiak K, Winder M, Chudek J
- 758** Restenosis of a drug eluting stent on the previous bioresorbable vascular scaffold successfully treated with a drug-coated balloon: A case report
Jang HG, Kim K, Park HW, Koh JS, Jeong YH, Park JR, Kang MG

ABOUT COVER

Editorial Board Member of *World Journal of Clinical Cases*, Dr. Marcelo A F Ribeiro Jr. is Full Professor of Surgery at Pontifical Catholic University – PUC Sorocaba – General and Trauma Surgery, and Professor of the Post-Graduation Program in Surgery, IAMSPE São Paulo (Brazil). He serves as Member and Fellow of the Brazilian College of Surgeons, Brazilian College of Digestive Surgery, Brazilian Trauma Society (General Secretary), American College of Surgeons, American Association for the Surgery of Trauma, Eastern Association for the Surgery of Trauma, and Pan-American Trauma Society (being Chairman of the Education Committee and Member of the Board). (L-Editor: Filipodia)

AIMS AND SCOPE

The primary aim of *World Journal of Clinical Cases* (*WJCC*, *World J Clin Cases*) is to provide scholars and readers from various fields of clinical medicine with a platform to publish high-quality clinical research articles and communicate their research findings online.

WJCC mainly publishes articles reporting research results and findings obtained in the field of clinical medicine and covering a wide range of topics, including case control studies, retrospective cohort studies, retrospective studies, clinical trials studies, observational studies, prospective studies, randomized controlled trials, randomized clinical trials, systematic reviews, meta-analysis, and case reports.

INDEXING/ABSTRACTING

The *WJCC* is now indexed in Science Citation Index Expanded (also known as SciSearch®), Journal Citation Reports/Science Edition, Scopus, PubMed, and PubMed Central. The 2020 Edition of Journal Citation Reports® cites the 2019 impact factor (IF) for *WJCC* as 1.013; IF without journal self cites: 0.991; Ranking: 120 among 165 journals in medicine, general and internal; and Quartile category: Q3. The *WJCC*'s CiteScore for 2019 is 0.3 and Scopus CiteScore rank 2019: General Medicine is 394/529.

RESPONSIBLE EDITORS FOR THIS ISSUE

Production Editor: Ji-Hong Lin; Production Department Director: Xiang Li; Editorial Office Director: Jin-Lai Wang.

NAME OF JOURNAL

World Journal of Clinical Cases

ISSN

ISSN 2307-8960 (online)

LAUNCH DATE

April 16, 2013

FREQUENCY

Thrice Monthly

EDITORS-IN-CHIEF

Dennis A Bloomfield, Sandro Vento, Bao-gan Peng

EDITORIAL BOARD MEMBERS

<https://www.wjgnet.com/2307-8960/editorialboard.htm>

PUBLICATION DATE

January 26, 2021

COPYRIGHT

© 2021 Baishideng Publishing Group Inc

INSTRUCTIONS TO AUTHORS

<https://www.wjgnet.com/bpg/gerinfo/204>

GUIDELINES FOR ETHICS DOCUMENTS

<https://www.wjgnet.com/bpg/GerInfo/287>

GUIDELINES FOR NON-NATIVE SPEAKERS OF ENGLISH

<https://www.wjgnet.com/bpg/gerinfo/240>

PUBLICATION ETHICS

<https://www.wjgnet.com/bpg/GerInfo/288>

PUBLICATION MISCONDUCT

<https://www.wjgnet.com/bpg/gerinfo/208>

ARTICLE PROCESSING CHARGE

<https://www.wjgnet.com/bpg/gerinfo/242>

STEPS FOR SUBMITTING MANUSCRIPTS

<https://www.wjgnet.com/bpg/GerInfo/239>

ONLINE SUBMISSION

<https://www.f6publishing.com>



Nasal septal foreign body as a complication of dental root canal therapy: A case report

Xiao-Wan Du, Jun-Bo Zhang, Shui-Fang Xiao

ORCID number: Xiao-Wan Du 0000-0002-0911-0084; Jun-Bo Zhang 0000-0002-5681-0147; Shui-Fang Xiao 0000-0003-1554-9859.

Author contributions: Xiao SF was the patient's surgeon, designed the study, and reviewed the literature; Du XW collected the information, performed the analyses and interpretation of the imaging findings, reviewed the literature, and drafted the manuscript; Zhang JB contributed to data interpretation and manuscript drafting; All authors issued final approval for the version to be submitted.

Informed consent statement: The patient provided informed written consent prior to the submission of the case.

Conflict-of-interest statement: The authors have no conflicts of interest to disclose.

CARE Checklist (2016) statement: The manuscript was edited according to CARE Checklist (2016).

Open-Access: This article is an open-access article that was selected by an in-house editor and fully peer-reviewed by external reviewers. It is distributed in accordance with the Creative Commons Attribution

Xiao-Wan Du, Jun-Bo Zhang, Shui-Fang Xiao, Department of Otolaryngology, Head and Neck Surgery, Peking University First Hospital, Beijing 100034, China

Corresponding author: Shui-Fang Xiao, MD, Chief Doctor, Professor, Department of Otolaryngology, Head and Neck Surgery, Peking University First Hospital, No. 8 Xishiku Street, Xicheng District, Beijing 100034, China. xiao_ent@163.com

Abstract

BACKGROUND

Currently, there have been no reports on foreign bodies found in the nasal septum after dental root canal therapy. Herein, we present an unusual case of a foreign body found in the nasal septum, which occurred after dental root canal therapy and two unsuccessful surgeries.

CASE SUMMARY

A 55-year-old man was referred to our department due to slight nasal discomfort that persisted for about 1 wk. Before consulting our department, the patient visited three different hospitals/clinics and underwent two surgeries that were not successful in removing a foreign body completely. A computed tomography scan was performed to detect the shift of the foreign body from dental root to the nasal septum, which resulted in the healing of oral inflammation and nasal septum discomfort. An endoscopic foreign body extraction surgery (3rd removal surgery) was then successfully performed, using a needle as the reference. No nasal reconstruction was required after the operation. Postoperative healing was uneventful.

CONCLUSION

Medical healthcare professionals should consider past medical history when dealing with foreign body cases. During septal foreign body extraction surgery, a needle could be used as a helpful reference.

Key Words: Foreign body; Nasal septum; Endodontic complications; Fractured instruments; Case report

©The Author(s) 2021. Published by Baishideng Publishing Group Inc. All rights reserved.

NonCommercial (CC BY-NC 4.0) license, which permits others to distribute, remix, adapt, build upon this work non-commercially, and license their derivative works on different terms, provided the original work is properly cited and the use is non-commercial. See: <http://creativecommons.org/licenses/by-nc/4.0/>

Manuscript source: Unsolicited manuscript

Specialty type: Medicine, research and experimental

Country/Territory of origin: China

Peer-review report's scientific quality classification

Grade A (Excellent): 0

Grade B (Very good): 0

Grade C (Good): C

Grade D (Fair): 0

Grade E (Poor): 0

Received: October 12, 2020

Peer-review started: October 12, 2020

First decision: October 27, 2020

Revised: November 6, 2020

Accepted: November 29, 2020

Article in press: November 29, 2020

Published online: January 26, 2021

P-Reviewer: Cianci P

S-Editor: Zhang L

L-Editor: Wang TQ

P-Editor: Yuan YY



Core Tip: In this case report, we present the case of a patient who visited four hospitals/clinics and underwent three surgical procedures for complete removal of a foreign body left during the dental root canal therapy. We consider this case suitable for publication for the following reasons: (1) This is an extremely unusual case. To the best of our knowledge, this is the first report on multiple nasal septal foreign bodies as a complication of dental root canal therapy; (2) It has educational value. This malpractice case calls for integrity reinforcement across medical institutions, as the foreign body left from the dental root canal therapy was deliberately covered up by the dentist until the foreign body broke. The patient visited four different hospitals/clinics and underwent three surgical procedures until the foreign bodies were totally removed; and (3) It has clinical value as it may provide an answer to the following questions: What should a dentist do when surgical instruments fracture? How to tell if there are two segments of a needle or if there is only one needle and the other segment is an artifact? Which surgical approach is the best for the patient?

Citation: Du XW, Zhang JB, Xiao SF. Nasal septal foreign body as a complication of dental root canal therapy: A case report. *World J Clin Cases* 2021; 9(3): 690-696

URL: <https://www.wjnet.com/2307-8960/full/v9/i3/690.htm>

DOI: <https://dx.doi.org/10.12998/wjcc.v9.i3.690>

INTRODUCTION

After dental root canal therapy, foreign bodies may end up in the nasal septum. In most cases, these materials enter the nasal septum *via* oronasal communication, while in some rare cases, they enter *via* tooth socket or *via* the pulp chamber of a tooth. It is suspected that the septal foreign body found after dental root canal therapy occurs following needle tip migration. If not timely treated, it can cause septal abscess and loss of a part of the septal cartilage. Herein, we present an unusual case of a foreign body in the septum, which occurred after dental root canal therapy and two unsuccessful surgeries. We describe the patient's course of events and treatment procedure, including his clinical and imaging findings.

CASE PRESENTATION

Chief complaints

A 55-year-old man was referred to the otorhinolaryngology department due to slight nasal discomfort that persisted for about 1 wk (timeline presented in [Table 1](#)).

History of present illness

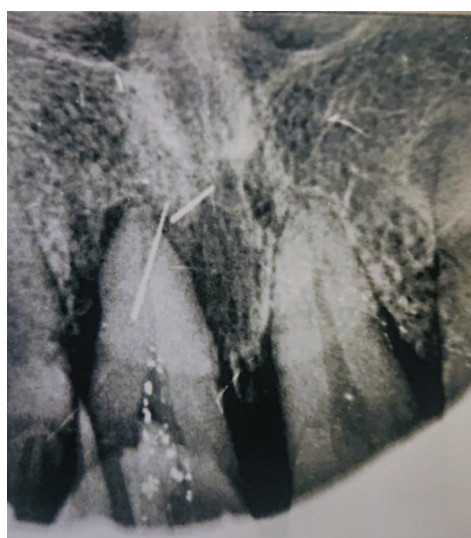Four weeks before the consultation, the patient underwent dental root canal therapy (position 21) in clinic A. Two days after surgery, the patient had swelling and pain in the upper gum and lip, which were suspected to be caused by postoperative inflammation. He was then prescribed antibiotics and nonsteroidal antiinflammatory drugs. Yet, these problems persisted for 1 wk. The patient was then transferred to clinic B. A dental film was taken, revealing two hyperdense and pin-like masses at position 21 ([Figure 1](#)). The second dentist suspected a fishbone and referred the patient to hospital C. According to the dental film ([Figure 1](#)), the patient was diagnosed with a foreign body (the other hyperdense mass was an artifact). Consequently, a dental root foreign body removal surgery was performed under general anesthesia by labiogingival incision, and one piece of pin-like foreign body was successfully removed.

On the second day post-operation, the dental radiography was repeated, revealing a foreign body residue of 29.4 mm from the left incisor ([Figure 2](#)). A second foreign body removal surgery was performed under local anesthesia *via* original labiogingival incision; however, the foreign body was not found despite the long intervention.

After the second surgery, the patient developed slight nasal discomfort that lasted for about 1 wk, after which the patient consulted our department. He underwent a computed tomography (CT) scan of the nasal sinuses. The axial ([Figure 3A](#)), sagittal

Table 1 Timeline of events

Event	Timeline
Dental root canal therapy (position 21) in clinic A	-4 wk
Swelling and pain in the upper gum and lip	-4 wk +1 d
Foreign bodies found at position 21 in clinic B	-3 wk
Dental root foreign body removal surgery in hospital C	-2 wk
Foreign body residue found, and the second removal surgery	-2 wk +1 d
Slight nasal discomfort	-1 wk
Presentation at our department	0 d
Foreign bodies found in the nasal septum	+1 d
Nasal septal foreign body removal surgery	+2 d

**Figure 1** Dental film showing the foreign body at position 21.

(Figure 3B), and coronal (Figure 3C) planes showed a pin-like foreign body with hyperdensity in the left side of the nasal septum; three-dimensional reconstruction (Figure 3D) reconfirmed the position.

History of past illness

The patient was otherwise healthy and had no record of previous surgical interventions or the use of medication.

Personal and family history

The patient had no relevant personal or family history.

Physical examination

The patient was immediately admitted. At the intraoral examination, granulation tissues were not evident in area 21. No sign of the foreign body was found following careful digital palpation, except for mild edema in the nasal septum.

Laboratory examinations

The patient's general condition was good, with normal hemoglobin levels and slightly elevated white blood cell count.

Imaging examinations

An emergency operation was scheduled. Before the septal foreign body extraction surgery, a needle was used as the reference (Figure 4A). A CT scan, which was performed to localize the foreign body and to avoid the same scenario from the last

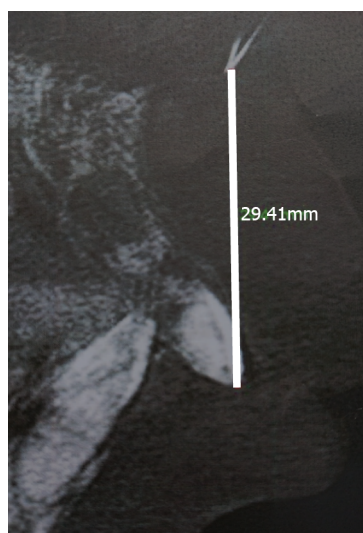


Figure 2 Postoperative dental film showing the foreign body residue 29.4 mm from the tip of the left incisor.

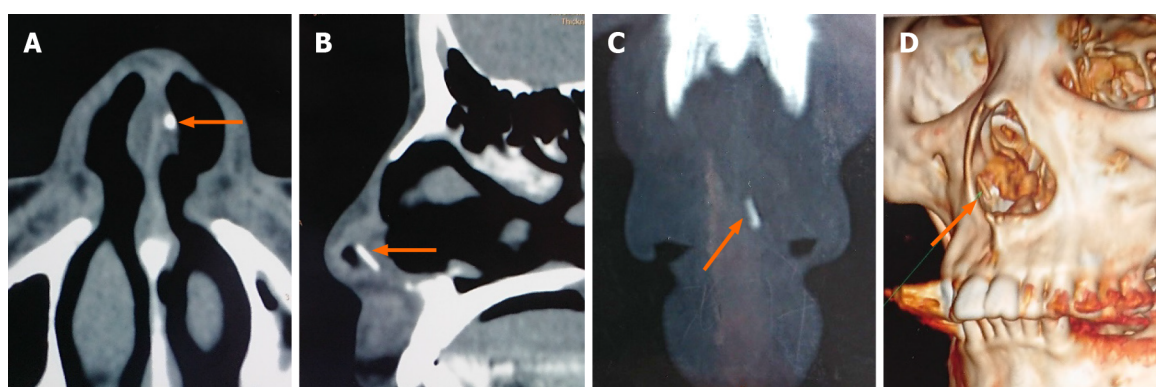


Figure 3 Computed tomography scan of the nasal sinuses before the third surgery. A: Axial plane; B: Sagittal plane; C: Coronal plane showing a pin-like foreign body with hyperdensity in the left side of the nasal septum; D: Three-dimensional reconstruction reconfirmed the position.

surgery, showed the needle pointing right to the pin-like foreign body (Figure 4B-D).

FINAL DIAGNOSIS

The diagnosis of a nasal septal foreign body was confirmed.

TREATMENT

With the needle reference's help, the surgery was completed in half an hour under local anesthesia. The patient underwent surgical treatment for endoscopic extraction of a foreign body that was confirmed to be a piece of a fractured instrument for root canal therapy (Figure 5). The septal cartilage was intact, and no reconstruction was required. The patient was discharged from the hospital the following morning, medicated with a 7-d antibiotic treatment with cefdinir, analgesics, and nasal irrigation therapy. The recovery was uneventful.

OUTCOME AND FOLLOW-UP

At the 1-mo follow-up visit, the patient reported complete resolution of symptoms and did not exhibit septal abscess or deformity.

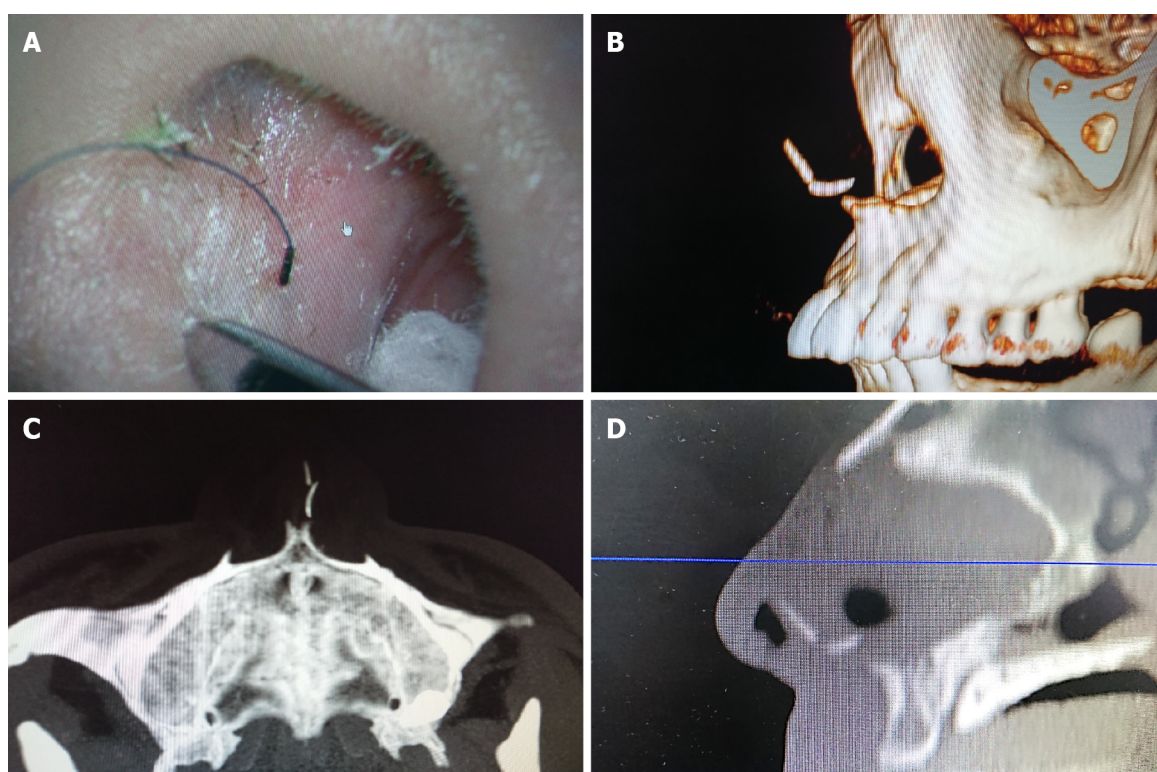


Figure 4 Computed tomography scan of the nasal sinuses after the third surgery. A: A needle was used as a reference; B: Three-dimensional reconstruction; C and D: Axial (C) and sagittal planes (D) showing that the needle was pointing right to the pin-like foreign body.




Figure 5 The gross of the foreign body confirmed to be a piece of the fractured instrument for root canal therapy.

DISCUSSION

To the best of our knowledge, this is the first case report of a nasal septal foreign body following dental root canal therapy without recent nasal trauma or rhinoseptoplasty. An instrument fracturing inside a root canal is a relatively frequent and undesirable mishap during endodontic treatment^[1]. Fractured instruments inside the root canal should be diagnosed, documented by an appropriate image examination, and recorded^[2]. Clinical and radiological examinations performed by the maxillofacial surgeon could be used to rule out the odontogenic infection. Though it may seem that retained fractured instruments do not reduce the prognosis of endodontically treated teeth in the absence of apical periodontitis, healing may be significantly reduced if the disease is present^[2]. Also, if an instrument fracture occurs, the patient should always be informed. The doctor can opt to leave the instrument inside the canal or remove it *via* the intracanal approach or surgery^[2-4]. If surgery is needed, transnasal approaches should be preferred for retrieval of the foreign body^[5].

Cases of foreign body migration into the paranasal sinus, orbit, and other adjacent craniofacial structures have been previously reported^[6,7]. Additionally, some patients

with implant migration have developed fungal infections and even cancer^[8]. Foreign bodies in the sinuses should be surgically addressed. If it is complicated with abscess, the treatment should also include surgical drainage of the abscess and nasal packing in the acute phase, followed by antibiotic treatment. Because the infection and accumulation of pus between the cartilage and mucoperichondrium lead to ischemia and necrosis of the cartilage within 24 h, there is a high risk of septal cartilage destruction causing cartilaginous saddle nose deformation if not instantly treated.

The migration can occur due to surgical inexperience, insufficient planning, changes in intranasal pressure, autoimmune reactions, bone resorption, improper occlusal forces, and/or bone deficiencies^[9-11]. In this case, a combination of several factors was probably responsible for this condition, including fracture of instruments inside a root canal and the subsequent surgeries. The route of the transposition of the foreign body from dental root to the nasal septum was assumed to be the following: Periodontal space → anterior space of the premaxillary bone → anterior nasal spine → nasal septum.

To avoid these inconveniences, dentists should be gentle in managing instruments, avoiding extreme angles, and keeping in mind the prevalence of instrument fractures, such as rotary nickel-titanium instruments (over stainless-steel hand), the third apical canals, and retreatment cases^[12]. Also, when the endodontic instrument fracture happens, it should be immediately addressed. Definitive management should be based on a thorough knowledge of each treatment option's success rates, balanced against potential risks of removal or file retention^[2]. Informing obligation must be seriously implemented, accompanied by appropriate record keeping. In addition, close follow-up is needed to check for the potential appearance of inflammation symptoms. Pain, redness, swelling, or purulent discharge requires medication and surgical treatment. Finally, thorough preoperative examination and operative exploration are essential if the remnant foreign body needs to be managed *via* the second procedure.

CONCLUSION

In summary, medical health care professionals should consider past medical history when dealing with a foreign body case. During septal foreign body removal endoscopic surgery, a needle as the reference could be very helpful. Also, CT imaging is crucial for an accurate diagnosis of entire foreign body fragments in the nasal cavity or sinuses.

REFERENCES

- 1 **Ramos Brito AC**, Verner FS, Junqueira RB, Yamasaki MC, Queiroz PM, Freitas DQ, Oliveira-Santos C. Detection of Fractured Endodontic Instruments in Root Canals: Comparison between Different Digital Radiography Systems and Cone-beam Computed Tomography. *J Endod* 2017; **43**: 544-549 [PMID: 28216273 DOI: 10.1016/j.joen.2016.11.017]
- 2 **McGuigan MB**, Louca C, Duncan HF. Clinical decision-making after endodontic instrument fracture. *Br Dent J* 2013; **214**: 395-400 [PMID: 23619858 DOI: 10.1038/sj.bdj.2013.379]
- 3 **Saunders JL**, Eleazer PD, Zhang P, Michalek S. Effect of a separated instrument on bacterial penetration of obturated root canals. *J Endod* 2004; **30**: 177-179 [PMID: 15055438 DOI: 10.1097/00004770-200403000-00012]
- 4 **Gandevivala A**, Parekh B, Poplai G, Sayed A. Surgical removal of fractured endodontic instrument in the periapex of mandibular first molar. *J Int Oral Health* 2014; **6**: 85-88 [PMID: 25214740]
- 5 **Levin M**, Sommer DD. Endoscopic removal of ectopic sinonasal teeth: a systematic review. *J Otolaryngol Head Neck Surg* 2019; **48**: 30 [PMID: 31277707 DOI: 10.1186/s40463-019-0353-8]
- 6 **González-García A**, González-García J, Diniz-Freitas M, García-García A, Bullón P. Accidental displacement and migration of endosseous implants into adjacent craniofacial structures: a review and update. *Med Oral Patol Oral Cir Bucal* 2012; **17**: e769-e774 [PMID: 22549685 DOI: 10.4317/medoral.18032]
- 7 **Sousa Menezes A**, Costa NDRMD, Moreira FC, Ribeiro D. Incisive dental implant migration into the nasal septum. *BMJ Case Rep* 2019; **12** [PMID: 31352375 DOI: 10.1136/bcr-2018-228325]
- 8 **Dundar S**, Karlidag T, Keles E. Endoscopic Removal of a Dental Implant from Maxillary Sinus. *J Craniofac Surg* 2017; **28**: 1003-1004 [PMID: 28212129 DOI: 10.1097/SCS.00000000000003552]
- 9 **Eltas A**, Dundar S, Eltas SD, Altun O, Yolcu U, Saybak A. Accidental Displacement of Dental Implants Into Both Maxillary Sinuses During Surgery. *J Oral Implantol* 2015; **41**: 601-603 [PMID: 23964688 DOI: 10.1563/AAID-JOI-D-13-00026]
- 10 **Galindo-Moreno P**, Padial-Molina M, Avila G, Rios HF, Hernández-Cortés P, Wang HL. Complications associated with implant migration into the maxillary sinus cavity. *Clin Oral Implants*

- Res* 2012; **23**: 1152-1160 [PMID: [22092923](#) DOI: [10.1111/j.1600-0501.2011.02278.x](#)]
- 11 **Nakajima Y**, Omori M, Inoue K, Nakano H, Fukui N, Kato-Kogoe N, Yamamoto K, Suwa Y, Sunano A, Ueno T. Removal of a Fixation Screw That Was Forced Into the Postsuperior Maxillary Sinus Wall: Case Report. *Implant Dent* 2019; **28**: 313-316 [PMID: [31124829](#) DOI: [10.1097/ID.0000000000000867](#)]
 - 12 **Tzanetakos GN**, Kontakiotis EG, Maurikou DV, Marzelou MP. Prevalence and management of instrument fracture in the postgraduate endodontic program at the Dental School of Athens: a five-year retrospective clinical study. *J Endod* 2008; **34**: 675-678 [PMID: [18498887](#) DOI: [10.1016/j.joen.2008.02.039](#)]



Published by **Baishideng Publishing Group Inc**
7041 Koll Center Parkway, Suite 160, Pleasanton, CA 94566, USA

Telephone: +1-925-3991568

E-mail: bpgoffice@wjgnet.com

Help Desk: <https://www.f6publishing.com/helpdesk>

<https://www.wjgnet.com>

