

# World Journal of *Clinical Cases*

*World J Clin Cases* 2021 November 16; 9(32): 9699-10051



## Contents

Thrice Monthly Volume 9 Number 32 November 16, 2021

### REVIEW

- 9699** Emerging role of long noncoding RNAs in recurrent hepatocellular carcinoma  
*Fang Y, Yang Y, Li N, Zhang XL, Huang HF*

### MINIREVIEWS

- 9711** Current treatment strategies for patients with only peritoneal cytology positive stage IV gastric cancer  
*Bausys A, Gricius Z, Aniukstyte L, Luksta M, Bickaite K, Bausys R, Strupas K*

### ORIGINAL ARTICLE

#### Case Control Study

- 9722** Botulinum toxin associated with fissurectomy and anoplasty for hypertonic chronic anal fissure: A case-control study  
*D'Orazio B, Geraci G, Famà F, Terranova G, Di Vita G*
- 9731** Correlation between circulating endothelial cell level and acute respiratory distress syndrome in postoperative patients  
*Peng M, Yan QH, Gao Y, Zhang Z, Zhang Y, Wang YF, Wu HN*

#### Retrospective Study

- 9741** Effects of early rehabilitation in improvement of paediatric burnt hands function  
*Zhou YQ, Zhou JY, Luo GX, Tan JL*
- 9752** Intracortical screw insertion plus limited open reduction in treating type 31A3 irreducible intertrochanteric fractures in the elderly  
*Huang XW, Hong GQ, Zuo Q, Chen Q*
- 9762** Treatment effects and periodontal status of chronic periodontitis after routine Er:YAG laser-assisted therapy  
*Gao YZ, Li Y, Chen SS, Feng B, Wang H, Wang Q*
- 9770** Risk factors for occult metastasis detected by inflammation-based prognostic scores and tumor markers in biliary tract cancer  
*Hashimoto Y, Ajiki T, Yanagimoto H, Tsugawa D, Shinozaki K, Toyama H, Kido M, Fukumoto T*
- 9783** Scapular bone grafting with allograft pin fixation for repair of bony Bankart lesions: A biomechanical study  
*Lu M, Li HP, Liu YJ, Shen XZ, Gao F, Hu B, Liu YF*
- 9792** High-resolution computed tomography findings independently predict epidermal growth factor receptor mutation status in ground-glass nodular lung adenocarcinoma  
*Zhu P, Xu XJ, Zhang MM, Fan SF*

- 9804** Colorectal cancer patients in a tertiary hospital in Indonesia: Prevalence of the younger population and associated factors

*Makmun D, Simadibrata M, Abdullah M, Syam AF, Shatri H, Fauzi A, Renaldi K, Maulahela H, Utari AP, Pribadi RR, Muzellina VN, Nursyirwan SA*

- 9815** Association between *Helicobacter pylori* infection and food-specific immunoglobulin G in Southwest China

*Liu Y, Shuai P, Liu YP, Li DY*

- 9825** Systemic immune inflammation index, ratio of lymphocytes to monocytes, lactate dehydrogenase and prognosis of diffuse large B-cell lymphoma patients

*Wu XB, Hou SL, Liu H*

### Clinical Trials Study

- 9835** Evaluating the efficacy of endoscopic sphincterotomy on biliary-type sphincter of Oddi dysfunction: A retrospective clinical trial

*Ren LK, Cai ZY, Ran X, Yang NH, Li XZ, Liu H, Wu CW, Zeng WY, Han M*

### Observational Study

- 9847** Management of pouch related symptoms in patients who underwent ileal pouch anal anastomosis surgery for adenomatous polyposis

*Gilad O, Rosner G, Brazowski E, Kariv R, Gluck N, Strul H*

- 9857** Presepsin as a biomarker for risk stratification for acute cholangitis in emergency department: A single-center study

*Zhang HY, Lu ZQ, Wang GX, Xie MR, Li CS*

### Prospective Study

- 9869** Efficacy of Yiqi Jianpi anti-cancer prescription combined with chemotherapy in patients with colorectal cancer after operation

*Li Z, Yin DF, Wang W, Zhang XW, Zhou LJ, Yang J*

### META-ANALYSIS

- 9878** Arthroplasty vs proximal femoral nails for unstable intertrochanteric femoral fractures in elderly patients: a systematic review and meta-analysis

*Chen WH, Guo WX, Gao SH, Wei QS, Li ZQ, He W*

### CASE REPORT

- 9889** Synchronous multiple primary malignancies of the esophagus, stomach, and jejunum: A case report

*Li Y, Ye LS, Hu B*

- 9896** Idiopathic acute superior mesenteric venous thrombosis after renal transplantation: A case report

*Zhang P, Li XJ, Guo RM, Hu KP, Xu SL, Liu B, Wang QL*

- 9903** Next-generation sequencing technology for diagnosis and efficacy evaluation of a patient with visceral leishmaniasis: A case report

*Lin ZN, Sun YC, Wang JP, Lai YL, Sheng LX*

- 9911** Cerebral air embolism complicating transbronchial lung biopsy: A case report  
*Herout V, Brat K, Richter S, Cundrle Jr I*
- 9917** Isolated synchronous Virchow lymph node metastasis of sigmoid cancer: A case report  
*Yang JQ, Shang L, Li LP, Jing HY, Dong KD, Jiao J, Ye CS, Ren HC, Xu QF, Huang P, Liu J*
- 9926** Clinical presentation and management of drug-induced gingival overgrowth: A case series  
*Fang L, Tan BC*
- 9935** Adult with mass burnt lime aspiration: A case report and literature review  
*Li XY, Hou HJ, Dai B, Tan W, Zhao HW*
- 9942** Massive hemothorax due to intercostal arterial bleeding after percutaneous catheter removal in a multiple-trauma patient: A case report  
*Park C, Lee J*
- 9948** Hemolymphangioma with multiple hemangiomas in liver of elderly woman with history of gynecological malignancy: A case report  
*Wang M, Liu HF, Zhang YZZ, Zou ZQ, Wu ZQ*
- 9954** Rare location and drainage pattern of right pulmonary veins and aberrant right upper lobe bronchial branch: A case report  
*Wang FQ, Zhang R, Zhang HL, Mo YH, Zheng Y, Qiu GH, Wang Y*
- 9960** Respiratory failure after scoliosis correction surgery in patients with Prader-Willi syndrome: Two case reports  
*Yoon JY, Park SH, Won YH*
- 9970** Computed tomography-guided chemical renal sympathetic nerve modulation in the treatment of resistant hypertension: A case report  
*Luo G, Zhu JJ, Yao M, Xie KY*
- 9977** Large focal nodular hyperplasia is unresponsive to arterial embolization: A case report  
*Ren H, Gao YJ, Ma XM, Zhou ST*
- 9982** Fine-needle aspiration cytology of an intrathyroidal nodule diagnosed as squamous cell carcinoma: A case report  
*Yu JY, Zhang Y, Wang Z*
- 9990** Extensive abdominal lymphangiomatosis involving the small bowel mesentery: A case report  
*Alhasan AS, Daqqaq TS*
- 9997** Gastrointestinal symptoms as the first sign of chronic granulomatous disease in a neonate: A case report  
*Meng EY, Wang ZM, Lei B, Shang LH*
- 10006** Screw penetration of the iliopsoas muscle causing late-onset pain after total hip arthroplasty: A case report  
*Park HS, Lee SH, Cho HM, Choi HB, Jo S*

- 10013** Uretero-lumbar artery fistula: A case report  
*Chen JJ, Wang J, Zheng QG, Sun ZH, Li JC, Xu ZL, Huang XJ*
- 10018** Rare mutation in *MKRN3* in two twin sisters with central precocious puberty: Two case reports  
*Jiang LQ, Zhou YQ, Yuan K, Zhu JF, Fang YL, Wang CL*
- 10024** Primary mucosal-associated lymphoid tissue extranodal marginal zone lymphoma of the bladder from an imaging perspective: A case report  
*Jiang ZZ, Zheng YY, Hou CL, Liu XT*
- 10033** Focal intramural hematoma as a potential pitfall for iatrogenic aortic dissection during subclavian artery stenting: A case report  
*Zhang Y, Wang JW, Jin G, Liang B, Li X, Yang YT, Zhan QL*
- 10040** Ventricular tachycardia originating from the His bundle: A case report  
*Zhang LY, Dong SJ, Yu HJ, Chu YJ*
- 10046** Posthepatectomy jaundice induced by paroxysmal nocturnal hemoglobinuria: A case report  
*Liang HY, Xie XD, Jing GX, Wang M, Yu Y, Cui JF*

**ABOUT COVER**

Editorial Board Member of *World Journal of Clinical Cases*, Jalaj Garg, FACC, MD, Academic Research, Assistant Professor, Division of Cardiology, Medical College of Wisconsin, Milwaukee, WI 53226, United States.  
garg.jalaj@yahoo.com

**AIMS AND SCOPE**

The primary aim of *World Journal of Clinical Cases* (WJCC, *World J Clin Cases*) is to provide scholars and readers from various fields of clinical medicine with a platform to publish high-quality clinical research articles and communicate their research findings online.

WJCC mainly publishes articles reporting research results and findings obtained in the field of clinical medicine and covering a wide range of topics, including case control studies, retrospective cohort studies, retrospective studies, clinical trials studies, observational studies, prospective studies, randomized controlled trials, randomized clinical trials, systematic reviews, meta-analysis, and case reports.

**INDEXING/ABSTRACTING**

The WJCC is now indexed in Science Citation Index Expanded (also known as SciSearch®), Journal Citation Reports/Science Edition, Scopus, PubMed, and PubMed Central. The 2021 Edition of Journal Citation Reports® cites the 2020 impact factor (IF) for WJCC as 1.337; IF without journal self cites: 1.301; 5-year IF: 1.742; Journal Citation Indicator: 0.33; Ranking: 119 among 169 journals in medicine, general and internal; and Quartile category: Q3. The WJCC's CiteScore for 2020 is 0.8 and Scopus CiteScore rank 2020: General Medicine is 493/793.

**RESPONSIBLE EDITORS FOR THIS ISSUE**

Production Editor: Jia-Hui Li; Production Department Director: Yu-Jie Ma; Editorial Office Director: Jin-Lei Wang.

**NAME OF JOURNAL**

*World Journal of Clinical Cases*

**ISSN**

ISSN 2307-8960 (online)

**LAUNCH DATE**

April 16, 2013

**FREQUENCY**

Thrice Monthly

**EDITORS-IN-CHIEF**

Dennis A Bloomfield, Sandro Vento, Bao-Gan Peng

**EDITORIAL BOARD MEMBERS**

<https://www.wjnet.com/2307-8960/editorialboard.htm>

**PUBLICATION DATE**

November 16, 2021

**COPYRIGHT**

© 2021 Baishideng Publishing Group Inc

**INSTRUCTIONS TO AUTHORS**

<https://www.wjnet.com/bpg/gerinfo/204>

**GUIDELINES FOR ETHICS DOCUMENTS**

<https://www.wjnet.com/bpg/GerInfo/287>

**GUIDELINES FOR NON-NATIVE SPEAKERS OF ENGLISH**

<https://www.wjnet.com/bpg/gerinfo/240>

**PUBLICATION ETHICS**

<https://www.wjnet.com/bpg/GerInfo/288>

**PUBLICATION MISCONDUCT**

<https://www.wjnet.com/bpg/gerinfo/208>

**ARTICLE PROCESSING CHARGE**

<https://www.wjnet.com/bpg/gerinfo/242>

**STEPS FOR SUBMITTING MANUSCRIPTS**

<https://www.wjnet.com/bpg/GerInfo/239>

**ONLINE SUBMISSION**

<https://www.f6publishing.com>





## Current treatment strategies for patients with only peritoneal cytology positive stage IV gastric cancer

Augustinas Bausys, Zilvinas Gričius, Laura Aniuksyte, Martynas Luksta, Klaudija Bickaite, Rimantas Bausys, Kestutis Strupas

**ORCID number:** Augustinas Bausys 0000-0003-1848-2960; Zilvinas Gričius 0000-0002-5428-4761; Laura Aniuksyte 0000-0002-3768-7382; Martynas Luksta 0000-0001-8023-9908; Klaudija Bickaite 0000-0003-3952-3223; Rimantas Bausys 0000-0003-4718-6810; Kestutis Strupas 0000-0002-1690-937X.

**Author contributions:** Bausys R and Strupas K conceptualized and designed the work; Bausys A, Gričius Z, Aniuksyte L, and Bickaite K performed the literature review and critical revision of the studies; Bausys A, Gričius Z, Bickaite K, and Aniuksyte L prepared the manuscript; Bausys R and Strupas K revised the manuscript; and all authors read and approved the final form of the manuscript.

**Conflict-of-interest statement:** The authors declare no conflicts of interest.

**Open-Access:** This article is an open-access article that was selected by an in-house editor and fully peer-reviewed by external reviewers. It is distributed in accordance with the Creative Commons Attribution NonCommercial (CC BY-NC 4.0) license, which permits others to distribute, remix, adapt, build upon this work non-commercially,

**Augustinas Bausys, Rimantas Bausys,** Department of Abdominal Surgery and Oncology, National Cancer Institute, Vilnius 08406, Lithuania

**Augustinas Bausys, Martynas Luksta,** Clinic of Gastroenterology, Nephrourology and Surgery, Institute of Clinical Medicine, Faculty of Medicine, Vilnius University, Vilnius 03101, Lithuania

**Zilvinas Gričius, Laura Aniuksyte, Klaudija Bickaite,** Faculty of Medicine, Vilnius University, Vilnius 08406, Lithuania

**Kestutis Strupas,** Clinic of Gastroenterology, Nephrourology and Surgery, Institute of Clinical Medicine, Vilnius University, Vilnius 03101, Lithuania

**Corresponding author:** Augustinas Bausys, MD, Surgeon, Department of Abdominal Surgery and Oncology, National Cancer Institute, Santariskiu str. 1, Vilnius 08406, Lithuania. [augustinas.bausys@gmail.com](mailto:augustinas.bausys@gmail.com)

### Abstract

Gastric cancer (GC) is one of the most common malignancies worldwide and surgery remains the only potentially curative treatment option for it. Although a significant proportion of GC patients are found with distant metastases already at the initial diagnosis. Peritoneal dissemination is the most common site of metastases. Positive peritoneal cytology (Cy1) is associated with poor long-term outcomes; thus, these patients are considered as stage IV even if macroscopic carcinomatosis is absent. Currently, there is no clear evidence for the most optimal treatment for this distinct subpopulation of the stage IV cohort. Available strategies vary from palliative chemotherapy to upfront gastrectomy. This comprehensive review summarized current evidence of different treatment strategies for Cy1 GC including roles of surgery, systemic and intraperitoneal chemotherapy.

**Key Words:** Gastric cancer; Positive peritoneal cytology; Gastrectomy; Systemic chemotherapy; Intraperitoneal chemotherapy

©The Author(s) 2021. Published by Baishideng Publishing Group Inc. All rights reserved.

and license their derivative works on different terms, provided the original work is properly cited and the use is non-commercial. See: <http://creativecommons.org/licenses/by-nc/4.0/>

**Specialty type:** Medicine, research and experimental

**Country/Territory of origin:**  
Lithuania

**Peer-review report's scientific quality classification**

Grade A (Excellent): A  
Grade B (Very good): 0  
Grade C (Good): 0  
Grade D (Fair): 0  
Grade E (Poor): 0

**Received:** June 20, 2021

**Peer-review started:** June 20, 2021

**First decision:** July 2, 2021

**Revised:** July 28, 2021

**Accepted:** September 15, 2021

**Article in press:** September 15, 2021

**Published online:** November 16, 2021

**P-Reviewer:** An T

**S-Editor:** Wang JJ

**L-Editor:** A

**P-Editor:** Xing YX



**Core Tip:** Positive peritoneal cytology (Cy1) is associated with poor long-term outcomes; thus, these patients are considered as stage IV even if macroscopic carcinomatosis is absent. The evidence for the most efficient treatment of these patients is conflicting. We herein review current knowledge and the outcomes of different approaches for Cy1 gastric cancers.

**Citation:** Bausys A, Gricius Z, Aniuksyte L, Luksta M, Bickaite K, Bausys R, Strupas K. Current treatment strategies for patients with only peritoneal cytology positive stage IV gastric cancer. *World J Clin Cases* 2021; 9(32): 9711-9721

**URL:** <https://www.wjgnet.com/2307-8960/full/v9/i32/9711.htm>

**DOI:** <https://dx.doi.org/10.12998/wjcc.v9.i32.9711>

## INTRODUCTION

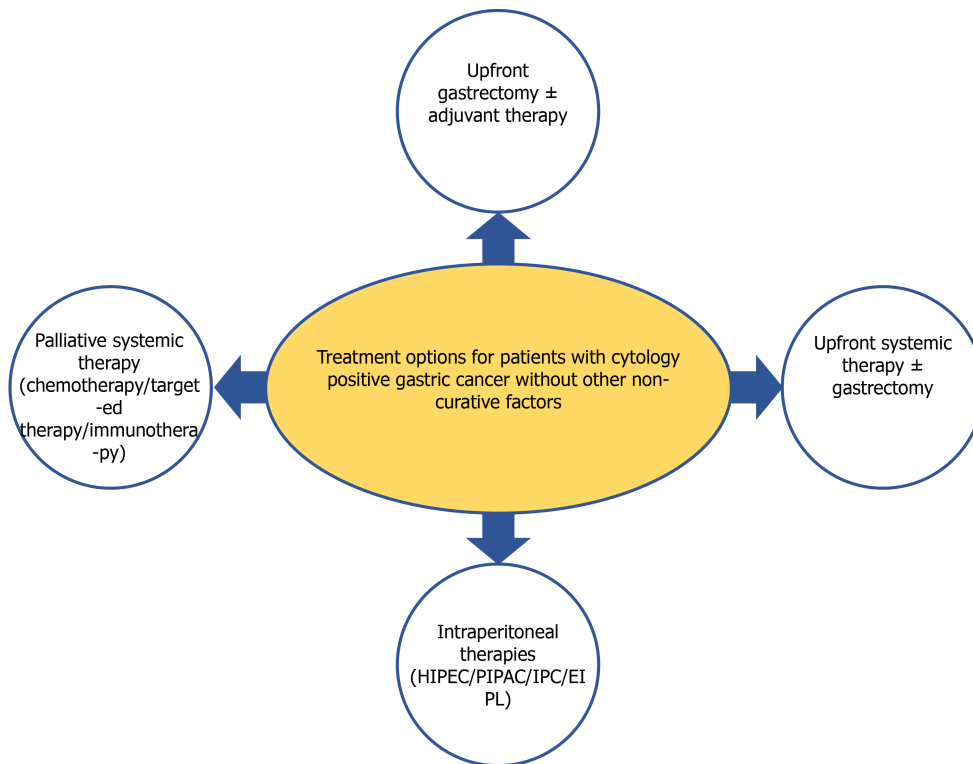
Gastric cancer (GC) remains an important health care issue as it is the fifth most common and the fourth most deadly cancer worldwide[1]. Surgery is the only potentially curative treatment option for it[2,3]. Although up to 30%-40% of GC patients already have distant metastases at the initial diagnosis and typically they are not candidates for radical surgery[4,5]. Peritoneal dissemination is the most common site of metastases[6]. Peritoneal lavage cytology at staging laparoscopy is the modern standard to detect peritoneal spread even before visible peritoneal carcinomatosis (PC) could be detected[7-9]. Positive cytology alone (Cy1) is a negative prognostic factor for recurrence and survival[10]; thus, it is defined as metastatic (M1) factor and Cy1 patients are considered as stage IV even in absence of macroscopic carcinomatosis.

Current clinical practice guidelines by the European Society for Medical Oncology (ESMO)[11] and National Comprehensive Cancer Network (NCCN) recommend palliative chemotherapy for Cy1 patients with a possibility for re-staging through treatment. Although, Japanese GC treatment guidelines distinguish Cy1 patients as a distinct subpopulation of the stage IV cohort and suggest considering neoadjuvant chemotherapy followed by D2 gastrectomy if other non-curative factors are absent [12]. Such discrepancies and a lack of standardization arise from the gap of current knowledge for the most efficient treatment of patients with only Cy1 stage IV GC. Therefore, this review aimed to summarize the current evidence for peritoneal dissemination in GC and various available treatment options for Cy1 stage IV patients.

## MECHANISMS OF PERITONEAL DISSEMINATION IN GC

Patients with locally advanced [that penetrates subserosal connective tissue, serosa, or adjacent structures (T3 or T4) or more advanced N-stage] GC, unfavorable histological subtypes (diffuse type and/or signet ring cell component), or primary scirrhous type GC are at higher risk for peritoneal metastases[13,14]. The development of these metastases is a multistep process which includes: (1) Cancer cells detachment from the primary tumor; (2) Survival in the microenvironment of the peritoneal cavity; (3) Malignant cells attachment to peritoneal mesothelial cells and invasion through basement membrane; and (4) Tumor growth and the onset of neoangiogenesis[15]. However, not all free intraperitoneal cancer cells seed into the peritoneum and turn into PC nodes. Most of these cells die even after successful attachment to the peritoneum, because of the peritoneal-blood barrier[15]. Further, mesothelium, the innermost monolayer of the peritoneum, has some basic protective mechanism against the adhesion of exogenous cells[15]. PC develops only after some sub-population of free GC cells manage to penetrate the submesothelial space by producing specific growth factors and matrix metalloproteinases, which induce the contraction of mesothelial cells, exposing the submesothelial basement membrane[15]. The presence of free GC cells in the peritoneal cavity represents the initial stages of PC development, however, currently, there are no methods to determine at what exact stage this multistep process has been diagnosed. Thus, it remains unclear if the treatment concept for Cy1 patients should aim to treat the present peritoneal disease or should aim to prevent its further development. Because of such controversies, different strategies have been adopted for Cy1 GC worldwide (Figure 1).





**Figure 1** Different available treatment options for patients with cytology positive gastric cancer without other non-curative factors. HIPEC: Hyperthermic intraperitoneal chemotherapy; PIPAC: Pressurized intraperitoneal chemotherapy; IPC: Intraperitoneal chemotherapy; EIPL: Extensive peritoneal lavage.

## UPFRONT SURGERY FOR CY1 GC PATIENTS

Surgery remains the only potentially curative treatment option for GC[3]. However, Cy1 represents stage IV disease, thus, despite it may be technically resectable, the biological rationale for surgery is controversial. The results of the randomized controlled trial (RCT) by the Japan Clinical Oncology Group (JCOG 0705) and Korea GC Association (KGCA01), comparing gastrectomy + chemotherapy *vs* chemotherapy alone in advanced GC with a single non-curative factor, showed no advantage of surgery for patients with PC[16,17]. Nonetheless, palliative chemotherapy is associated with disappointing long-term outcomes and Cy1 patients represent the distinct subpopulation of GC patients with peritoneal dissemination. Therefore, more aggressive treatment strategies including surgical resections are utilized for these patients in some centers.

Upfront radical gastrectomy followed by adjuvant S-1 monotherapy was investigated in a phase II single-arm (CCOG0301) study which enrolled 48 Cy1 GC patients across the multiple treatment centers in Japan[18]. Long-term follow-up showed 5-year overall (OS) and relapse-free survival rates were 26% and 21%, respectively. Peritoneal recurrence occurred in 62% of enrolled patients[18]. Similar results were confirmed by other groups from the East[19-21]. Kano *et al*[19] presented a retrospective study with a median follow-up of almost 10 years. Radical gastrectomy followed by adjuvant S-1 chemotherapy resulted in a 17.8% 5-year OS rate and peritoneal recurrence rate of 52.9%[19]. Further, the study documented the benefit of adjuvant S-1 monotherapy, as the median survival increased to 22.3 mo compared to 11.8 mo in the surgery alone group[19]. The benefit of adjuvant therapy was confirmed in another study from Korea by Shim *et al*[20]. Adjuvant chemotherapy by TS-1 ± cisplatin or oxaliplatin plus capecitabine (XELOX) or oxaliplatin + 5-FU (FOLFOX) improved median disease-free survival (DFS) (11.63 *vs* 6.98 mo,  $P < 0.001$ ) and OS (25.50 *vs* 12.11 mo,  $P < 0.001$ )[20]. No significant differences were observed between the regimen of postoperative chemotherapy and survival[20], thus the most optimal regimen remains unclear. Another retrospective study by Komatsu *et al*[21] analyzed upfront gastrectomy followed by adjuvant S-1 based chemotherapy in 51 Cy1 GC patients, with a special focus on the impact of surgical radicality. Radical gastrectomy with ≥ D2 Lymphonodectomy was superior compared to palliative gastrectomy with the 5-year OS of 48.2% *vs* 18.2%, respectively[21]. Further, the impact of surgery for Cy1 GC treatment

was presented in another recent study from China[22]. Forty-eight Cy1 GC patients underwent upfront gastrectomy (75%;  $n = 36$ ) or gastrectomy after neoadjuvant chemotherapy (25%;  $n = 12$ )[22]. The median OS and DFS were 22 and 16.5 mo, respectively[22]. However, the study did not provide a comparison of long-term outcomes between patients who received upfront surgery and neoadjuvant treatment [22]. In contrast, such a comparison was performed by Mezhir *et al*[23] In a Western cohort. Neoadjuvant therapy failed to improve DSS (1.7 *vs* 0.9,  $P = 0.76$ ), although the relatively small sample size in the upfront surgery ( $n = 29$ ) and neoadjuvant treatment groups ( $n = 23$ ) should be taken into consideration[23].

Together, the current evidence indicates that radical upfront gastrectomy is feasible for Cy1 GC patients, and adjuvant chemotherapy is necessary to improve long-term outcomes. Although, most of the evidence for the upfront surgery arises from small-scale Eastern studies. Such treatment strategy needs further investigation in large-scale high-quality surgical trials, including the patients from Western parts of the world.

## UPFRONT SYSTEMIC THERAPY FOR CY1 GC PATIENTS

As mentioned previously, Cy1 GC represents the stage IV disease, thus ESMO and NCCN guidelines suggest considering systemic treatment (chemotherapy) as it improves survival and quality of life compared to best supportive care[11]. Doublet or triplet platinum/fluoropyrimidine combinations  $\pm$  trastuzumab is recommended as a first-line palliative treatment[11]. Although there is no evidence for the most appropriate chemotherapy regimen to treat peritoneal metastases in GC[24], therefore, different schemes are adopted in clinical practice.

Several studies investigated the rates of conversion from positive to negative cytology following initial treatment by systemic chemotherapy[23-25]. The reported rates of conversion varied between 48.9% and 72.2% after treatment by various platinum/fluoropyrimidine combinations with or without docetaxel or trastuzumab [23-25]. Such conversion from positive to negative cytology results in improved oncological outcomes. Mezhir *et al*[23] showed increased disease-specific survival (2.5 *vs* 1.4 years) in those who converted to negative cytology. Similar, Yasufuku *et al*[25] and Aizawa *et al*[24] demonstrated improved 3-year (76.9% *vs* 10.5%) and 5-year (34.6% *vs* 17.6%) OS rates, respectively.

The high rate of conversions from positive to negative cytology and the clinical benefit of it proposes to consider the initial chemotherapy not as a palliative, but as neoadjuvant treatment. Further, the study by Badgwell *et al*[26] suggested, that palliative treatment may be inferior to neoadjuvant chemotherapy, despite only 41.6% of patients treated with it underwent surgery at some point of the treatment. Neoadjuvant therapy group showed a notably higher 3-year OS rate of 12% compared to 0% in patients who were considered as having incurable stage IV disease, therefore scheduled for palliative therapy only.

The upfront systemic therapy is the most promising when the conversion of cytological status is achieved, especially if converted patients can be allocated for further surgical treatment. The most effective chemotherapy regimens and the optimal number of cycles for conversions remain unknown, thus, future studies should elucidate these unclarities.

## INTRAPERITONEAL THERAPIES FOR CY1 GC PATIENTS

As shown previously, systemic chemotherapy in a neoadjuvant or adjuvant setting plays an important role to improve Cy1 GC patients' outcomes. Although, systemic chemotherapy is considered to be limited efficacy for peritoneal dissemination because of the peritoneal-plasma barrier[27]. Therefore, direct intraperitoneal therapies have been suggested as a more effective alternative for these patients.

## INTRAPERITONEAL CHEMOTHERAPY AND EXTENSIVE INTRAOPERATIVE PERITONEAL LAVAGE

The rationale for intraperitoneal chemotherapy (IPC) application is the possibility to achieve high local concentration while keeping the low systemic concentration of cytotoxic drug[28]. These pharmacokinetic features of the method increase the

therapeutic efficacy and decrease systemic toxicity. The possible limitation of IPC for the PC is the limited penetration of the drug. The maximum estimated depth of drug penetration is 3 to 5 mm, although actual penetration range from a few cell layers to a few millimeters[28]. Despite this shortcoming of the method for PC, it does not preclude the eradication of free intraperitoneal cancer cells. Thus, IPC was investigated as an attractive option for Cy1 GC patients.

Imano *et al*[29] conducted a pilot clinicopathological study to investigate intraperitoneal administration of 80 mg/m<sup>2</sup> paclitaxel at the end of the radical D2 gastrectomy for 10 Cy1 GC patients. Pharmacokinetic analysis showed that the peak plasma concentration of paclitaxel did not reach the cytotoxic threshold level of 0.1 mol/L, while intraperitoneal drug concentration was about 6773 folds higher[29]. Such IPC cleared the peritoneal cytology as no viable cancer cells were found at 24 and 48 h after IPC[29]. Following radical surgery with IPC majority of patients received adjuvant S1 based chemotherapy[29]. Long-term outcome analysis showed a promising 3-years survival rate of 56% and the peritoneal recurrence rate of 30%[29]. Further, the authors compared these survival outcomes with a historical cohort who received gastrectomy alone and concluded that IPC significantly improves the survival of Cy1 GC patients [29]. Another study on IPC for Cy1 GC investigated the additional benefit of extensive peritoneal lavage (EIPL)[30]. Shimada *et al*[30] study included 22 Cy1 GC patients who underwent: (1) Gastrectomy; (2) Gastrectomy + IPC with 100 mg cisplatin; or (3) Gastrectomy + IPC + EIPL by peritoneal cavity washing with 10 Liters of physiologic saline solution. Postoperatively all patients received adjuvant 5-FU based chemotherapy[30]. Long-term outcomes analysis showed 2-year OS rates of 0%, 14.3%, and 57.1% in groups 1, 2 and 3, respectively. Further EIPL reduced the peritoneal recurrence rate to 42.9% compared to 85.7% and 100% in gastrectomy + IPC and gastrectomy groups, respectively. Cancer cell detection analysis in the peritoneal lavage by reverse transcriptase-polymerase chain reaction (RT-PCR) suggested 10 Liters of physiologic saline as an optimal amount to flush out the free cancer cells from the peritoneal cavity[30]. Because of the promising results in the retrospective study, the gastrectomy + EIPL + IPC strategy was tested in the subsequent multicenter RCT [31]. The study included 88 Cy1 GC patients and randomly allocated them to three previously mentioned treatment strategies[31]. This prospective study confirmed the superiority of EIPL + IPC, as the 5-year OS increased to 43.8% compared to 4.6% and 0% in IPC and gastrectomy alone groups, respectively. Further EIPL + IPC significantly reduced the peritoneal recurrence rate to 40.0% compared to 79.3% in IPC and 89.7% in gastrectomy alone groups. After the promising results of the retrospective study were confirmed in the subsequent RCT, authors recommended considering EIPL-IPC therapy as a standard prophylactic strategy for peritoneal dissemination in Cy1 GC patients[31]. However, some conflicting data on the efficacy of EIPL was presented in a recent EXPEL study. This high-quality, open-label, multicentre, phase 3 surgical RCT, conducted at 22 hospitals from South Korea, China, Japan, Malaysia, Hong Kong, and Singapore enrolled 800 patients to evaluate the potential benefit of EIPL after upfront radical gastrectomy for cT3-4 GC[32]. However, EIPL by 10 Liters of saline did not improve 3-year OS [77.0% *vs* 76.7%; HR: 1.09 (95%CI: 0.78-1.52); *P* = 0.62], DFS [64.8% *vs* 69.4%; HR: 1.12 (95%CI: 0.86-1.47); *P* = 0.40], and 3-year cumulative incidence for peritoneal recurrence [7.9% *vs* 6.6%; HR: 1.33 (95%CI: 0.73-2.42); *P* = 0.35]. Moreover, EIPL was associated with higher risk of adverse events (RR = 1.58, *P* = 0.019)[32,33].

## HYPERTHERMIC IPC

Hyperthermic IPC (HIPEC) is another available method for peritoneal malignancy. It combines the benefit of IPC with the potential advantages of hyperthermia. Experimental and clinical evidence indicates that hyperthermia at a range of 41 to 43 °C destroys malignant cells by selectively increasing the number of lysosomes and lysosomal enzyme activity in malignant cells leading to increased destructive capacity [28]. Also, hyperthermia decrease blood flow in most of the malignant tumors in contrast to the opposite effect in normal tissues[28]. Such effects, together with inhibition of oxidative metabolism in malignant cells promote cell death of the more sensitive malignant cells[28]. Further, heat promotes the cytotoxic effect of the chemotherapeutic agents [28]. Thus, HIPEC was widely investigated for peritoneal disease treatment including studies in Cy1 GC patients. Meta-analysis of randomized and high-quality non-randomized trials on HIPEC for prevention and treatment of peritoneal disease in GC patients found no difference in the 3-year OS (RR = 0.99, *P* =

0.85) for patients with PC[34]. Although, HIPEC obtained advantages in preventing peritoneal metastases (RR = 0.63; 95%CI: 0.45-0.88;  $P < 0.01$ ) in high-risk patients, including Cy1 GC patients[34]. Also, HIPEC might be applied in a neoadjuvant setting as showed by Badgwell *et al*[35] in a single-arm phase II study. Nineteen stage IV GC patients only by positive cytology ( $n = 6$ ) or limited PC ( $n = 13$ ) received up to 5 cycles of neoadjuvant laparoscopic HIPEC after initial systemic chemotherapy. In total seven (36.8%) of these converted to negative cytology and no PC and 5 of them received radical gastrectomy[35]. It is important to emphasize that the conversion rate of 66.6% (4 of 6 patients) in Cy1 patients was considerably high[35]. This aggressive treatment resulted in a 3-year OS rate of 43.5%, and the median survival of patients who received gastrectomy was 29 mo. After encouraging results of the study Badgwell *et al*[36] conducted another single-arm phase II study for an even more aggressive approach. Twenty patients with limited PC ( $n = 14$ ) or Cy1 ( $n = 6$ ) were treated with initial systemic chemotherapy followed by 1-2 Laparoscopic HIPEC procedures and then subsequent gastrectomy with a cytoreduction and intraoperative HIPEC[36]. Such an aggressive treatment resulted in a 28% 3-year OS[36]. However, it is important to note, that subgroup of Cy1 patients had a very promising result of such treatment, as 50% ( $n = 3$ ) of Cy1 were alive and recurrence-free at 32-49 mo after diagnosis. Despite the encouraging initial results on HIPEC for Cy1 patients, there is a lack of data from high-quality large-scale RCTs. Currently, an ongoing phase III GASTRICHIP trial[37] is designed to evaluate the effect of HIPEC in patients with a high risk of peritoneal recurrence, including Cy1 patients after neoadjuvant chemotherapy[37]. The long-term outcomes will be available in 2023 and the results will elucidate some unclarities regarding HIPEC's role for Cy1 GC patients[34].

## PRESSURIZED IPC

Another new and emerging technique for a peritoneal disease is pressurized IPC (PIPAC). During PIPAC, laparoscopic access is obtained to create a pneumoperitoneum of 12 mmHg and nebulized chemotherapy is applied to create therapeutic capnoperitoneum for 30 min[38]. The rationale for PIPAC includes: (1) Optimization of drug distribution by applying an aerosol rather than a liquid solution; (2) Applying increased intraperitoneal hydrostatic pressure to increase drug penetration to the target; and (3) Limiting blood outflow during drug application[39,40]. Further, the minimally invasive approach of PIPAC allows multiple applications of the procedure and objective reassessment of the response through laparoscopy and biopsies[39]. Similar to laparoscopic HIPEC, PIPAC may be utilized in a neoadjuvant setting and also in combination with systemic therapy. Several retrospective and prospective phase II studies suggested that PIPAC may be a safe and promising option for GC patients with PC[41-44], although, there is a lack of data for its efficacy in a specific cohort of Cy1 patients.

## SYSTEMIC CHEMOTHERAPY, TARGETED THERAPY, AND IMMUNOTHERAPY FOR CY1 GC PATIENTS

All above-mentioned treatment strategies could be considered as experimental, as the standard treatment option for M1 GC remains palliative systemic therapy[11]. Doublet or triplet platinum/fluoropyrimidine combinations are recommended for fit patients with M1 GC (including Cy1 patients) as standard conventional chemotherapy options [11]. Although, such treatment remains associated with poor outcomes[45], thus novel treatment options, like targeted therapy and immunotherapy, are of interest for these patients.

One of the available options, already included in a clinical practice guideline is trastuzumab - a monoclonal antibody targeting human epidermal growth factor receptor 2 (HER2). It induces antibody-dependent cellular cytotoxicity, inhibits HER2-mediated signaling, and prevents cleavage of the extracellular domain of HER2[46]. Large scale ToGA RCT showed that trastuzumab in combination with chemotherapy increases the survival of advanced or M1 HER2-positive GC patients[47]. A recent study showed trastuzumab deruxtecan, a humanized monoclonal anti-HER2 antibody attached to a cytotoxic topoisomerase I inhibitor through a cleavable linker is available and effective as a third-line treatment for HER2 positive GC patients[48]. Some other HER-2 targeting agents such as lapatinib, trastuzumab emtansine, pertuzumab are

also available, although their efficacy remains controversial[49\_52]. Another available targeted therapy agent is ramucirumab, a fully humanized monoclonal antibody against vascular endothelial growth factor receptor 2[53]. This angiogenesis inhibitor was included in treatment guidelines as a second-line treatment option for patients with M1 GC after encouraging results of the REGARD and RAINBOW studies[54,55].

Another novel and promising drug class for M1 GC is immune checkpoint inhibitors. Some of these drugs improve antitumor T-cell activity by inhibiting immune checkpoints such as the programmed death-1 receptor (PD-1) and programmed death-ligand 1 (PDL1). PD1 is expressed on the surface of activated T cells that regulate their proliferation and activation and PDL1 is a major ligand for PD-1 expressed in some cancers, including GC cells[56,57]. Nivolumab is one of the available immune checkpoint inhibitors recommended in combination with fluorouracil/capecitabine and oxaliplatin for M1 HER2 negative GC, including Cy1 patients as recent RCTs demonstrated its efficacy for the first[58] and further lines treatment [59]. Pembrolizumab is another immune checkpoint inhibitor with antitumor activity in patients with PD-L1 positive GC. A phase II KEYNOTE-059 study showed promising activity and manageable safety of pembrolizumab monotherapy as a third-line treatment[60]. Although, the phase III RCT (KEYNOTE-062) failed to show improved survival with pembrolizumab or pembrolizumab plus chemotherapy compared to chemotherapy alone in previously untreated GC[61].

Despite some promising results of novel targeted therapy and immunotherapy drugs for M1 GC, the exact benefit for a distinct cohort of Cy1 GC patients remains unclear, as none of the current studies investigated this distinct subpopulation. Further studies are needed, to elucidate, the potential of novel systemic therapies for these patients.

## LIMITATIONS OF THE CURRENT KNOWLEDGE AND PERSPECTIVES FOR FUTURE RESEARCH

The knowledge provided by the current evidence has some limitations. First, most of the available studies are relatively small in sample size. Second, many different treatment strategies including upfront gastrectomy, surgery after neoadjuvant systemic therapy, and IPC have been described for Cy1 GC, however, there is a lack of studies that would have compared them with each other. Thus, further large-scale international cohort studies comparing different treatments are needed to establish the most promising options. After, these should be tested in subsequent multi-center randomized control trials to provide robust evidence on the most efficient treatment for Cy1 patients.

## CONCLUSION

Positive peritoneal cytology is associated with poor long-term outcomes in GC patients. Although, current evidence indicates, that this distinct subpopulation of the stage IV cohort may benefit from more aggressive treatment than palliative chemotherapy. Available strategies include upfront gastrectomy followed by adjuvant therapy, neoadjuvant chemotherapy option, and different methods of IPC utilization. Although, the most optimal treatment remains unclear because there is a lack of comparative studies. Thus, further clinical trials are needed to establish the best treatment option for Cy1 GC.

## REFERENCES

- 1 **Sung H**, Ferlay J, Siegel RL, Laversanne M, Soerjomataram I, Jemal A, Bray F. Global Cancer Statistics 2020: GLOBOCAN Estimates of Incidence and Mortality Worldwide for 36 Cancers in 185 Countries. *CA Cancer J Clin* 2021; **71**: 209-249 [PMID: 33538338 DOI: 10.3322/caac.21660]
- 2 **Stratilatovas E**, Baušys A, Baušys R, Sangaila E. Mortality after gastrectomy: a 10 year single institution experience. *Acta Chir Belg* 2015; **115**: 123-130 [PMID: 26021945 DOI: 10.1080/00015458.2015.11681081]
- 3 **Bausys R**, Bausys A, Vysniauskaite I, Maneikis K, Stratilatovas E, Strupas K. Surgical treatment outcomes of patients with T1-T2 gastric cancer: does the age matter when excellent treatment results are expected? *World J Surg Oncol* 2018; **16**: 79 [PMID: 29661204 DOI: 10.1186/s12957-018-1388-4]



- 4 **Bernards N**, Creemers GJ, Nieuwenhuijzen GA, Bosscha K, Pruijt JF, Lemmens VE. No improvement in median survival for patients with metastatic gastric cancer despite increased use of chemotherapy. *Ann Oncol* 2013; **24**: 3056-3060 [PMID: [24121120](#) DOI: [10.1093/annonc/mdt401](#)]
- 5 **Zhang Y**, Lin Y, Duan J, Xu K, Mao M, Wang X. A Population-Based Analysis of Distant Metastasis in Stage IV Gastric Cancer. *Med Sci Monit* 2020; **26**: e923867 [PMID: [32409630](#) DOI: [10.12659/MSM.923867](#)]
- 6 **Shi B**, Lin H, Zhang M, Lu W, Qu Y, Zhang H. Gene Regulation and Targeted Therapy in Gastric Cancer Peritoneal Metastasis: Radiological Findings from Dual Energy CT and PET/CT. *J Vis Exp* 2018 [PMID: [29443079](#) DOI: [10.3791/56526](#)]
- 7 **Nakajima T**, Harashima S, Hirata M, Kajitani T. Prognostic and therapeutic values of peritoneal cytology in gastric cancer. *Acta Cytol* 1978; **22**: 225-229 [PMID: [281825](#)]
- 8 **Bando E**, Yonemura Y, Takeshita Y, Taniguchi K, Yasui T, Yoshimitsu Y, Fushida S, Fujimura T, Nishimura G, Miwa K. Intraoperative lavage for cytological examination in 1,297 patients with gastric carcinoma. *Am J Surg* 1999; **178**: 256-262 [PMID: [10527450](#) DOI: [10.1016/s0002-9610\(99\)00162-2](#)]
- 9 **Yamaguchi T**, Takashima A, Nagashima K, Makuuchi R, Aizawa M, Ohashi M, Tashiro K, Yamada T, Kinoshita T, Hata H, Kawachi Y, Kawabata R, Tsuji T, Hihara J, Sakamoto T, Fukagawa T, Katai H, Higuchi K, Boku N. Efficacy of Postoperative Chemotherapy After Resection that Leaves No Macroscopically Visible Disease of Gastric Cancer with Positive Peritoneal Lavage Cytology (CY1) or Localized Peritoneum Metastasis (P1a): A Multicenter Retrospective Study. *Ann Surg Oncol* 2020; **27**: 284-292 [PMID: [31535301](#) DOI: [10.1245/s10434-019-07697-x](#)]
- 10 **Allen CJ**, Newhook TE, Vreeland TJ, Das P, Minsky BD, Blum M, Song S, Ajani J, Ikoma N, Mansfield PF, Roy-Chowdhuri S, Badgwell BD. Yield of peritoneal cytology in staging patients with gastric and gastroesophageal cancer. *J Surg Oncol* 2019; **120**: 1350-1357 [PMID: [31612494](#) DOI: [10.1002/jso.25729](#)]
- 11 **Smyth EC**, Verheij M, Allum W, Cunningham D, Cervantes A, Arnold D; ESMO Guidelines Committee. Gastric cancer: ESMO Clinical Practice Guidelines for diagnosis, treatment and follow-up. *Ann Oncol* 2016; **27**: v38-v49 [PMID: [27664260](#) DOI: [10.1093/annonc/mdw350](#)]
- 12 **Japanese Gastric Cancer Association**. Japanese gastric cancer treatment guidelines 2018 (5th edition). *Gastric Cancer* 2021; **24**: 1-21 [PMID: [32060757](#) DOI: [10.1007/s10120-020-01042-y](#)]
- 13 **Rau B**, Brandl A, Piso P, Pelz J, Busch P, Demtröder C, Schüle S, Schlitt HJ, Roitman M, Tepel J, Sulkowski U, Uzunoglu F, Hünerbein M, Hörbelt R, Ströhlein M, Beckert S, Königsrainer I, Königsrainer A; Peritoneum Surface Oncology Group and members of the StuDoQ|Peritoneum Registry of the German Society for General and Visceral Surgery (DGAV). Peritoneal metastasis in gastric cancer: results from the German database. *Gastric Cancer* 2020; **23**: 11-22 [PMID: [31228044](#) DOI: [10.1007/s10120-019-00978-0](#)]
- 14 **Thomassen I**, van Gestel YR, van Ramshorst B, Luyer MD, Bosscha K, Nienhuijs SW, Lemmens VE, de Hingh IH. Peritoneal carcinomatosis of gastric origin: a population-based study on incidence, survival and risk factors. *Int J Cancer* 2014; **134**: 622-628 [PMID: [23832847](#) DOI: [10.1002/ijc.28373](#)]
- 15 **Kanda M**, Kodera Y. Molecular mechanisms of peritoneal dissemination in gastric cancer. *World J Gastroenterol* 2016; **22**: 6829-6840 [PMID: [27570420](#) DOI: [10.3748/wjg.v22.i30.6829](#)]
- 16 **Fujitani K**, Yang HK, Kurokawa Y, Park DJ, Tsujinaka T, Park BJ, Fukuda H, Noh SH, Boku N, Bang YJ, Sasako M, Lee JI; Gastric Cancer Surgical Study Group of Japan Clinical Oncology Group; Korea Gastric Cancer Association. Randomized controlled trial comparing gastrectomy plus chemotherapy with chemotherapy alone in advanced gastric cancer with a single non-curable factor: Japan Clinical Oncology Group Study JCOG 0705 and Korea Gastric Cancer Association Study KGCA01. *Jpn J Clin Oncol* 2008; **38**: 504-506 [PMID: [18617536](#) DOI: [10.1093/jjco/hyn058](#)]
- 17 **Jamel S**, Markar SR, Malietzis G, Acharya A, Athanasiou T, Hanna GB. Prognostic significance of peritoneal lavage cytology in staging gastric cancer: systematic review and meta-analysis. *Gastric Cancer* 2018; **21**: 10-18 [PMID: [28779261](#) DOI: [10.1007/s10120-017-0749-y](#)]
- 18 **Kodera Y**, Ito S, Mochizuki Y, Ohashi N, Tanaka C, Kobayashi D, Kojima H, Matsui T, Kondo K, Fujiwara M. Long-term follow up of patients who were positive for peritoneal lavage cytology: final report from the CCOG0301 study. *Gastric Cancer* 2012; **15**: 335-337 [PMID: [22527184](#) DOI: [10.1007/s10120-012-0156-3](#)]
- 19 **Kano K**, Aoyama T, Maezawa Y, Nakajima T, Ikeda K, Yamada T, Sato T, Oshima T, Rino Y, Masuda M, Ogata T, Cho H, Yoshikawa T. The survival and prognosticators of peritoneal cytology-positive gastric cancer patients who received upfront gastrectomy and subsequent S-1 chemotherapy. *Int J Clin Oncol* 2017; **22**: 887-896 [PMID: [28456896](#) DOI: [10.1007/s10147-017-1128-8](#)]
- 20 **Shim HJ**, Kim HJ, Lee SH, Bae WK, Hwang EC, Cho SH, Chung JJ, Bang HJ, Hwang JE. Observational Study of Peritoneal Washing Cytology-Positive Gastric Cancer without Gross Peritoneal Metastasis in Patients who Underwent Radical D2 Gastrectomy. *Sci Rep* 2020; **10**: 9549 [PMID: [32533084](#) DOI: [10.1038/s41598-020-66637-y](#)]
- 21 **Komatsu S**, Shioaki Y, Furuke H, Ohta A, Tsuji R, Tanaka S, Kumano T, Imura KI, Shimomura K, Ikeda J, Taniguchi F, Ueshima Y, Lee CJ, Deguchi E, Ikeda E, Otsuji E. Is curative gastrectomy justified for gastric cancer with cytology positive as the only stage IV factor? *Langenbecks Arch Surg* 2019; **404**: 599-604 [PMID: [31073759](#) DOI: [10.1007/s00423-019-01791-0](#)]
- 22 **Kang WZ**, Zhong YX, Ma FH, Xue LY, Xiong JP, Ma S, Li Y, Xie YB, Quan X, Tian YT. Survival outcomes and prognostic indicators for gastric cancer patients with positive peritoneal wash cytology



- but no peritoneal metastasis after radical gastrectomy. *World J Gastrointest Oncol* 2021; **13**: 24-36 [PMID: 33510847 DOI: 10.4251/wjgo.v13.i1.24]
- 23 **Mezhir JJ**, Shah MA, Jacks LM, Brennan MF, Coit DG, Strong VE. Positive peritoneal cytology in patients with gastric cancer: natural history and outcome of 291 patients. *Ann Surg Oncol* 2010; **17**: 3173-3180 [PMID: 20585870 DOI: 10.1245/s10434-010-1183-0]
  - 24 **Aizawa M**, Nashimoto A, Yabusaki H, Nakagawa S, Matsuki A, Homma K, Kawasaki T. The clinical significance of potentially curative resection for gastric cancer following the clearance of free cancer cells in the peritoneal cavity by induction chemotherapy. *Surg Today* 2015; **45**: 611-617 [PMID: 25027056 DOI: 10.1007/s00595-014-0979-0]
  - 25 **Yasufuku I**, Nunobe S, Ida S, Kumagai K, Ohashi M, Hiki N, Sano T. Conversion therapy for peritoneal lavage cytology-positive type 4 and large type 3 gastric cancer patients selected as candidates for R0 resection by diagnostic staging laparoscopy. *Gastric Cancer* 2020; **23**: 319-327 [PMID: 31350702 DOI: 10.1007/s10120-019-00994-0]
  - 26 **Badgwell B**, Cormier JN, Krishnan S, Yao J, Staerkel GA, Lupo PJ, Pisters PW, Feig B, Mansfield P. Does neoadjuvant treatment for gastric cancer patients with positive peritoneal cytology at staging laparoscopy improve survival? *Ann Surg Oncol* 2008; **15**: 2684-2691 [PMID: 18649106 DOI: 10.1245/s10434-008-0055-3]
  - 27 **de Bree E**, Michelakis D, Stamatiou D, Romanos J, Zoras O. Pharmacological principles of intraperitoneal and bidirectional chemotherapy. *Pleura Peritoneum* 2017; **2**: 47-62 [PMID: 30911633 DOI: 10.1515/pp-2017-0010]
  - 28 **González-Moreno S**, González-Bayón LA, Ortega-Pérez G. Hyperthermic intraperitoneal chemotherapy: Rationale and technique. *World J Gastrointest Oncol* 2010; **2**: 68-75 [PMID: 21160924 DOI: 10.4251/wjgo.v2.i2.68]
  - 29 **Imano M**, Imamoto H, Itoh T, Satou T, Peng YF, Yasuda A, Kato H, Nishiki K, Shiraishi O, Shinkai M, Tsubaki M, Yasuda T, Nishida S, Takeyama Y, Okuno K, Shiozaki H. Impact of intraperitoneal chemotherapy after gastrectomy with positive cytological findings in peritoneal washings. *Eur Surg Res* 2011; **47**: 254-259 [PMID: 22067579 DOI: 10.1159/000333803]
  - 30 **Shimada S**, Tanaka E, Marutsuka T, Honmyo U, Tokunaga H, Yagi Y, Aoki N, Ogawa M. Extensive intraoperative peritoneal lavage and chemotherapy for gastric cancer patients with peritoneal free cancer cells. *Gastric Cancer* 2002; **5**: 168-172 [PMID: 12378344 DOI: 10.1007/s101200200029]
  - 31 **Kuramoto M**, Shimada S, Ikeshima S, Matsuo A, Yagi Y, Matsuda M, Yonemura Y, Baba H. Extensive intraoperative peritoneal lavage as a standard prophylactic strategy for peritoneal recurrence in patients with gastric carcinoma. *Ann Surg* 2009; **250**: 242-246 [PMID: 19638909 DOI: 10.1097/SLA.0b013e3181b0c80e]
  - 32 **Yang HK**, Ji J, Han SU, Terashima M, Li G, Kim HH, Law S, Shabbir A, Song KY, Hyung WJ, Kosai NR, Kono K, Misawa K, Yabusaki H, Kinoshita T, Lau PC, Kim YW, Rao JR, Ng E, Yamada T, Yoshida K, Park DJ, Tai BC, So JBY; EXPEL study group. Extensive peritoneal lavage with saline after curative gastrectomy for gastric cancer (EXPEL): a multicentre randomised controlled trial. *Lancet Gastroenterol Hepatol* 2021; **6**: 120-127 [PMID: 33253659 DOI: 10.1016/S2468-1253(20)30315-0]
  - 33 **Pocard M**, Reymond MA. "Peritoneal failure": A new concept to explain negative results of randomized trials evaluating intraperitoneal therapies. *Pleura Peritoneum* 2020; **5**: 20200117 [PMID: 32566729 DOI: 10.1515/pp-2020-0117]
  - 34 **Desiderio J**, Chao J, Melstrom L, Warner S, Tozzi F, Fong Y, Parisi A, Woo Y. The 30-year experience-A meta-analysis of randomised and high-quality non-randomised studies of hyperthermic intraperitoneal chemotherapy in the treatment of gastric cancer. *Eur J Cancer* 2017; **79**: 1-14 [PMID: 28456089 DOI: 10.1016/j.ejca.2017.03.030]
  - 35 **Badgwell B**, Blum M, Das P, Estrella J, Wang X, Ho L, Fournier K, Royal R, Mansfield P, Ajani J. Phase II Trial of Laparoscopic Hyperthermic Intraperitoneal Chemoperfusion for Peritoneal Carcinomatosis or Positive Peritoneal Cytology in Patients with Gastric Adenocarcinoma. *Ann Surg Oncol* 2017; **24**: 3338-3344 [PMID: 28799004 DOI: 10.1245/s10434-017-6047-4]
  - 36 **Badgwell B**, Ikoma N, Murphy MB, Wang X, Estrella J, Roy-Chowdhuri S, Das P, Minsky BD, Lano E, Song S, Mansfield P, Ajani J. A Phase II Trial of Cytoreduction, Gastrectomy, and Hyperthermic Intraperitoneal Perfusion with Chemotherapy for Patients with Gastric Cancer and Carcinomatosis or Positive Cytology. *Ann Surg Oncol* 2021; **28**: 258-264 [PMID: 32556731 DOI: 10.1245/s10434-020-08739-5]
  - 37 **Glehen O**, Passot G, Villeneuve L, Vaudoyer D, Bin-Dorel S, Boschetti G, Piaton E, Garofalo A. GASTRICHIP: D2 resection and hyperthermic intraperitoneal chemotherapy in locally advanced gastric carcinoma: a randomized and multicenter phase III study. *BMC Cancer* 2014; **14**: 183 [PMID: 24628950 DOI: 10.1186/1471-2407-14-183]
  - 38 **Gamboa AC**, Winer JH. Cytoreductive Surgery and Hyperthermic Intraperitoneal Chemotherapy for Gastric Cancer. *Cancers (Basel)* 2019; **11** [PMID: 31717799 DOI: 10.3390/cancers11111662]
  - 39 **Nadiradze G**, Horvath P, Sautkin Y, Archid R, Weinreich FJ, Königsrainer A, Reymond MA. Overcoming Drug Resistance by Taking Advantage of Physical Principles: Pressurized Intraperitoneal Aerosol Chemotherapy (PIPAC). *Cancers (Basel)* 2019; **12** [PMID: 31877647 DOI: 10.3390/cancers12010034]
  - 40 **Graversen M**, Detlefsen S, Bjerregaard JK, Fristrup CW, Pfeiffer P, Mortensen MB. Prospective, single-center implementation and response evaluation of pressurized intraperitoneal aerosol chemotherapy (PIPAC) for peritoneal metastasis. *Ther Adv Med Oncol* 2018; **10**: 1758835918777036

- [PMID: 29899763 DOI: 10.1177/1758835918777036]
- 41 **Struller F**, Horvath P, Solass W, Weinreich FJ, Strumberg D, Kokkalis MK, Fischer I, Meisner C, Königsrainer A, Reymond MA. Pressurized intraperitoneal aerosol chemotherapy with low-dose cisplatin and doxorubicin (PIPAC C/D) in patients with gastric cancer and peritoneal metastasis: a phase II study. *Ther Adv Med Oncol* 2019; **11**: 1758835919846402 [PMID: 31205501 DOI: 10.1177/1758835919846402]
  - 42 **Gockel I**, Jansen-Winkeln B, Haase L, Rhode P, Mehdorn M, Niebisch S, Moulla Y, Lyros O, Lordick F, Schierle K, Wittekind C, Thieme R. Pressurized Intraperitoneal Aerosol Chemotherapy (PIPAC) in Gastric Cancer Patients with Peritoneal Metastasis (PM): Results of a Single-Center Experience and Register Study. *J Gastric Cancer* 2018; **18**: 379-391 [PMID: 30607301 DOI: 10.5230/jgc.2018.18.e37]
  - 43 **Ellebæk SB**, Graversen M, Detlefsen S, Lundell L, Fristrup CW, Pfeiffer P, Mortensen MB. Pressurized intraperitoneal aerosol chemotherapy (PIPAC) of peritoneal metastasis from gastric cancer: a descriptive cohort study. *Clin Exp Metastasis* 2020; **37**: 325-332 [PMID: 32002724 DOI: 10.1007/s10585-020-10023-5]
  - 44 **Kurtz F**, Struller F, Horvath P, Solass W, Bösmüller H, Königsrainer A, Reymond MA. Feasibility, Safety, and Efficacy of Pressurized Intraperitoneal Aerosol Chemotherapy (PIPAC) for Peritoneal Metastasis: A Registry Study. *Gastroenterol Res Pract* 2018; **2018**: 2743985 [PMID: 30473706 DOI: 10.1155/2018/2743985]
  - 45 **Fratini F**, Rausei S, Chiappa C, Rovera F, Boni L, Dionigi G. Prognosis and treatment of patients with positive peritoneal cytology in advanced gastric cancer. *World J Gastrointest Surg* 2013; **5**: 135-137 [PMID: 23710290 DOI: 10.4240/wjgs.v5.i5.135]
  - 46 **Hudis CA**. Trastuzumab--mechanism of action and use in clinical practice. *N Engl J Med* 2007; **357**: 39-51 [PMID: 17611206 DOI: 10.1056/NEJMr043186]
  - 47 **Bang YJ**, Van Cutsem E, Feyereislova A, Chung HC, Shen L, Sawaki A, Lordick F, Ohtsu A, Omuro Y, Satoh T, Aprile G, Kulikov E, Hill J, Lehle M, Rüschoff J, Kang YK, ToGA Trial Investigators. Trastuzumab in combination with chemotherapy versus chemotherapy alone for treatment of HER2-positive advanced gastric or gastro-oesophageal junction cancer (ToGA): a phase 3, open-label, randomised controlled trial. *Lancet* 2010; **376**: 687-697 [PMID: 20728210 DOI: 10.1016/S0140-6736(10)61121-X]
  - 48 **Shitara K**, Bang YJ, Iwasa S, Sugimoto N, Ryu MH, Sakai D, Chung HC, Kawakami H, Yabusaki H, Lee J, Saito K, Kawaguchi Y, Kamio T, Kojima A, Sugihara M, Yamaguchi K, DESTINY-Gastric01 Investigators. Trastuzumab Deruxtecan in Previously Treated HER2-Positive Gastric Cancer. *N Engl J Med* 2020; **382**: 2419-2430 [PMID: 32469182 DOI: 10.1056/NEJMoa2004413]
  - 49 **Tabernero J**, Hoff PM, Shen L, Ohtsu A, Shah MA, Cheng K, Song C, Wu H, Eng-Wong J, Kim K, Kang YK. Pertuzumab plus trastuzumab and chemotherapy for HER2-positive metastatic gastric or gastro-oesophageal junction cancer (JACOB): final analysis of a double-blind, randomised, placebo-controlled phase 3 study. *Lancet Oncol* 2018; **19**: 1372-1384 [PMID: 30217672 DOI: 10.1016/S1470-2045(18)30481-9]
  - 50 **Thuss-Patience PC**, Shah MA, Ohtsu A, Van Cutsem E, Ajani JA, Castro H, Mansoor W, Chung HC, Bodoky G, Shitara K, Phillips GDL, van der Horst T, Harle-Yge ML, Althaus BL, Kang YK. Trastuzumab emtansine versus taxane use for previously treated HER2-positive locally advanced or metastatic gastric or gastro-oesophageal junction adenocarcinoma (GATSBY): an international randomised, open-label, adaptive, phase 2/3 study. *Lancet Oncol* 2017; **18**: 640-653 [PMID: 28343975 DOI: 10.1016/S1470-2045(17)30111-0]
  - 51 **Satoh T**, Xu RH, Chung HC, Sun GP, Doi T, Xu JM, Tsuji A, Omuro Y, Li J, Wang JW, Miwa H, Qin SK, Chung IJ, Yeh KH, Feng JF, Mukaiyama A, Kobayashi M, Ohtsu A, Bang YJ. Lapatinib plus paclitaxel versus paclitaxel alone in the second-line treatment of HER2-amplified advanced gastric cancer in Asian populations: TyTAN--a randomized, phase III study. *J Clin Oncol* 2014; **32**: 2039-2049 [PMID: 24868024 DOI: 10.1200/JCO.2013.53.6136]
  - 52 **Hecht JR**, Bang YJ, Qin SK, Chung HC, Xu JM, Park JO, Jeziorski K, Shparyk Y, Hoff PM, Sobrero A, Salman P, Li J, Protsenko SA, Wainberg ZA, Buyse M, Afenjar K, Houé V, Garcia A, Kaneko T, Huang Y, Khan-Wasti S, Santillana S, Press MF, Slamon D. Lapatinib in Combination With Capecitabine Plus Oxaliplatin in Human Epidermal Growth Factor Receptor 2-Positive Advanced or Metastatic Gastric, Esophageal, or Gastroesophageal Adenocarcinoma: TRIO-013/LOGiC--A Randomized Phase III Trial. *J Clin Oncol* 2016; **34**: 443-451 [PMID: 26628478 DOI: 10.1200/JCO.2015.62.6598]
  - 53 **Young K**, Smyth E, Chau I. Ramucirumab for advanced gastric cancer or gastro-oesophageal junction adenocarcinoma. *Therap Adv Gastroenterol* 2015; **8**: 373-383 [PMID: 26557893 DOI: 10.1177/1756283X15592586]
  - 54 **Fuchs CS**, Tomasek J, Yong CJ, Dumitru F, Passalacqua R, Goswami C, Safran H, Dos Santos LV, Aprile G, Ferry DR, Melichar B, Tehfe M, Topuzov E, Zalberg JR, Chau I, Campbell W, Sivanandan C, Pikiel J, Koshiji M, Hsu Y, Liepa AM, Gao L, Schwartz JD, Tabernero J; REGARD Trial Investigators. Ramucirumab monotherapy for previously treated advanced gastric or gastro-oesophageal junction adenocarcinoma (REGARD): an international, randomised, multicentre, placebo-controlled, phase 3 trial. *Lancet* 2014; **383**: 31-39 [PMID: 24094768 DOI: 10.1016/S0140-6736(13)61719-5]
  - 55 **Wilke H**, Muro K, Van Cutsem E, Oh SC, Bodoky G, Shimada Y, Hironaka S, Sugimoto N, Lipatov O, Kim TY, Cunningham D, Rougier P, Komatsu Y, Ajani J, Emig M, Carlesi R, Ferry D, Chandrawansa K, Schwartz JD, Ohtsu A; RAINBOW Study Group. Ramucirumab plus paclitaxel

- versus placebo plus paclitaxel in patients with previously treated advanced gastric or gastro-oesophageal junction adenocarcinoma (RAINBOW): a double-blind, randomised phase 3 trial. *Lancet Oncol* 2014; **15**: 1224-1235 [PMID: [25240821](#) DOI: [10.1016/S1470-2045\(14\)70420-6](#)]
- 56 **Sexton RE**, Al Hallak MN, Diab M, Azmi AS. Gastric cancer: a comprehensive review of current and future treatment strategies. *Cancer Metastasis Rev* 2020; **39**: 1179-1203 [PMID: [32894370](#) DOI: [10.1007/s10555-020-09925-3](#)]
- 57 **Akyala AI**, Verhaar AP, Peppelenbosch MP. Immune checkpoint inhibition in gastric cancer: A systematic review. *Journal of Cellular Immunotherapy* 2018; **4**: 49-55 [DOI: [10.1016/j.jocit.2018.05.001](#)]
- 58 **Janjigian YY**, Shitara K, Moehler M, Garrido M, Salman P, Shen L, Wyrwicz L, Yamaguchi K, Skoczylas T, Campos Bragagnoli A, Liu T, Schenker M, Yanez P, Tehfe M, Kowalyszyn R, Karamouzis MV, Bruges R, Zander T, Pazo-Cid R, Hitre E, Feeney K, Cleary JM, Poulart V, Cullen D, Lei M, Xiao H, Kondo K, Li M, Ajani JA. First-line nivolumab plus chemotherapy versus chemotherapy alone for advanced gastric, gastro-oesophageal junction, and oesophageal adenocarcinoma (CheckMate 649): a randomised, open-label, phase 3 trial. *Lancet* 2021; **398**: 27-40 [PMID: [34102137](#) DOI: [10.1016/S0140-6736\(21\)00797-2](#)]
- 59 **Kang YK**, Boku N, Satoh T, Ryu MH, Chao Y, Kato K, Chung HC, Chen JS, Muro K, Kang WK, Yeh KH, Yoshikawa T, Oh SC, Bai LY, Tamura T, Lee KW, Hamamoto Y, Kim JG, Chin K, Oh DY, Minashi K, Cho JY, Tsuda M, Chen LT. Nivolumab in patients with advanced gastric or gastro-oesophageal junction cancer refractory to, or intolerant of, at least two previous chemotherapy regimens (ONO-4538-12, ATTRACTION-2): a randomised, double-blind, placebo-controlled, phase 3 trial. *Lancet* 2017; **390**: 2461-2471 [PMID: [28993052](#) DOI: [10.1016/S0140-6736\(17\)31827-5](#)]
- 60 **Fuchs CS**, Doi T, Jang RW, Muro K, Satoh T, Machado M, Sun W, Jalal SI, Shah MA, Metges JP, Garrido M, Golan T, Mandala M, Wainberg ZA, Catenacci DV, Ohtsu A, Shitara K, Geva R, Blecker J, Ko AH, Ku G, Philip P, Enzinger PC, Bang YJ, Levitan D, Wang J, Rosales M, Dalal RP, Yoon HH. Safety and Efficacy of Pembrolizumab Monotherapy in Patients With Previously Treated Advanced Gastric and Gastroesophageal Junction Cancer: Phase 2 Clinical KEYNOTE-059 Trial. *JAMA Oncol* 2018; **4**: e180013 [PMID: [29543932](#) DOI: [10.1001/jamaoncol.2018.0013](#)]
- 61 **Shitara K**, Van Cutsem E, Bang YJ, Fuchs C, Wyrwicz L, Lee KW, Kudaba I, Garrido M, Chung HC, Lee J, Castro HR, Mansoor W, Braghiroli MI, Karaseva N, Caglevic C, Villanueva L, Goekkurt E, Satake H, Enzinger P, Alsina M, Benson A, Chao J, Ko AH, Wainberg ZA, Kher U, Shah S, Kang SP, Tabernero J. Efficacy and Safety of Pembrolizumab or Pembrolizumab Plus Chemotherapy vs Chemotherapy Alone for Patients With First-line, Advanced Gastric Cancer: The KEYNOTE-062 Phase 3 Randomized Clinical Trial. *JAMA Oncol* 2020; **6**: 1571-1580 [PMID: [32880601](#) DOI: [10.1001/jamaoncol.2020.3370](#)]



Published by **Baishideng Publishing Group Inc**  
7041 Koll Center Parkway, Suite 160, Pleasanton, CA 94566, USA

**Telephone:** +1-925-3991568

**E-mail:** [bpgoffice@wjgnet.com](mailto:bpgoffice@wjgnet.com)

**Help Desk:** <https://www.f6publishing.com/helpdesk>

<https://www.wjgnet.com>

