

World Journal of *Clinical Cases*

World J Clin Cases 2021 November 16; 9(32): 9699-10051



Contents

Thrice Monthly Volume 9 Number 32 November 16, 2021

REVIEW

- 9699 Emerging role of long noncoding RNAs in recurrent hepatocellular carcinoma
Fang Y, Yang Y, Li N, Zhang XL, Huang HF

MINIREVIEWS

- 9711 Current treatment strategies for patients with only peritoneal cytology positive stage IV gastric cancer
Bausys A, Gricius Z, Aniukstyte L, Luksta M, Bickaite K, Bausys R, Strupas K

ORIGINAL ARTICLE

Case Control Study

- 9722 Botulinum toxin associated with fissurectomy and anoplasty for hypertonic chronic anal fissure: A case-control study
D'Orazio B, Geraci G, Famà F, Terranova G, Di Vita G
- 9731 Correlation between circulating endothelial cell level and acute respiratory distress syndrome in postoperative patients
Peng M, Yan QH, Gao Y, Zhang Z, Zhang Y, Wang YF, Wu HN

Retrospective Study

- 9741 Effects of early rehabilitation in improvement of paediatric burnt hands function
Zhou YQ, Zhou JY, Luo GX, Tan JL
- 9752 Intracortical screw insertion plus limited open reduction in treating type 31A3 irreducible intertrochanteric fractures in the elderly
Huang XW, Hong GQ, Zuo Q, Chen Q
- 9762 Treatment effects and periodontal status of chronic periodontitis after routine Er:YAG laser-assisted therapy
Gao YZ, Li Y, Chen SS, Feng B, Wang H, Wang Q
- 9770 Risk factors for occult metastasis detected by inflammation-based prognostic scores and tumor markers in biliary tract cancer
Hashimoto Y, Ajiki T, Yanagimoto H, Tsugawa D, Shinozaki K, Toyama H, Kido M, Fukumoto T
- 9783 Scapular bone grafting with allograft pin fixation for repair of bony Bankart lesions: A biomechanical study
Lu M, Li HP, Liu YJ, Shen XZ, Gao F, Hu B, Liu YF
- 9792 High-resolution computed tomography findings independently predict epidermal growth factor receptor mutation status in ground-glass nodular lung adenocarcinoma
Zhu P, Xu XJ, Zhang MM, Fan SF

- 9804** Colorectal cancer patients in a tertiary hospital in Indonesia: Prevalence of the younger population and associated factors

Makmun D, Simadibrata M, Abdullah M, Syam AF, Shatri H, Fauzi A, Renaldi K, Maulahela H, Utari AP, Pribadi RR, Muzellina VN, Nursyirwan SA

- 9815** Association between *Helicobacter pylori* infection and food-specific immunoglobulin G in Southwest China

Liu Y, Shuai P, Liu YP, Li DY

- 9825** Systemic immune inflammation index, ratio of lymphocytes to monocytes, lactate dehydrogenase and prognosis of diffuse large B-cell lymphoma patients

Wu XB, Hou SL, Liu H

Clinical Trials Study

- 9835** Evaluating the efficacy of endoscopic sphincterotomy on biliary-type sphincter of Oddi dysfunction: A retrospective clinical trial

Ren LK, Cai ZY, Ran X, Yang NH, Li XZ, Liu H, Wu CW, Zeng WY, Han M

Observational Study

- 9847** Management of pouch related symptoms in patients who underwent ileal pouch anal anastomosis surgery for adenomatous polyposis

Gilad O, Rosner G, Brazowski E, Kariv R, Gluck N, Strul H

- 9857** Presepsin as a biomarker for risk stratification for acute cholangitis in emergency department: A single-center study

Zhang HY, Lu ZQ, Wang GX, Xie MR, Li CS

Prospective Study

- 9869** Efficacy of Yiqi Jianpi anti-cancer prescription combined with chemotherapy in patients with colorectal cancer after operation

Li Z, Yin DF, Wang W, Zhang XW, Zhou LJ, Yang J

META-ANALYSIS

- 9878** Arthroplasty vs proximal femoral nails for unstable intertrochanteric femoral fractures in elderly patients: a systematic review and meta-analysis

Chen WH, Guo WX, Gao SH, Wei QS, Li ZQ, He W

CASE REPORT

- 9889** Synchronous multiple primary malignancies of the esophagus, stomach, and jejunum: A case report

Li Y, Ye LS, Hu B

- 9896** Idiopathic acute superior mesenteric venous thrombosis after renal transplantation: A case report

Zhang P, Li XJ, Guo RM, Hu KP, Xu SL, Liu B, Wang QL

- 9903** Next-generation sequencing technology for diagnosis and efficacy evaluation of a patient with visceral leishmaniasis: A case report

Lin ZN, Sun YC, Wang JP, Lai YL, Sheng LX

- 9911** Cerebral air embolism complicating transbronchial lung biopsy: A case report
Herout V, Brat K, Richter S, Cundrle Jr I
- 9917** Isolated synchronous Virchow lymph node metastasis of sigmoid cancer: A case report
Yang JQ, Shang L, Li LP, Jing HY, Dong KD, Jiao J, Ye CS, Ren HC, Xu QF, Huang P, Liu J
- 9926** Clinical presentation and management of drug-induced gingival overgrowth: A case series
Fang L, Tan BC
- 9935** Adult with mass burnt lime aspiration: A case report and literature review
Li XY, Hou HJ, Dai B, Tan W, Zhao HW
- 9942** Massive hemothorax due to intercostal arterial bleeding after percutaneous catheter removal in a multiple-trauma patient: A case report
Park C, Lee J
- 9948** Hemolymphangioma with multiple hemangiomas in liver of elderly woman with history of gynecological malignancy: A case report
Wang M, Liu HF, Zhang YZZ, Zou ZQ, Wu ZQ
- 9954** Rare location and drainage pattern of right pulmonary veins and aberrant right upper lobe bronchial branch: A case report
Wang FQ, Zhang R, Zhang HL, Mo YH, Zheng Y, Qiu GH, Wang Y
- 9960** Respiratory failure after scoliosis correction surgery in patients with Prader-Willi syndrome: Two case reports
Yoon JY, Park SH, Won YH
- 9970** Computed tomography-guided chemical renal sympathetic nerve modulation in the treatment of resistant hypertension: A case report
Luo G, Zhu JJ, Yao M, Xie KY
- 9977** Large focal nodular hyperplasia is unresponsive to arterial embolization: A case report
Ren H, Gao YJ, Ma XM, Zhou ST
- 9982** Fine-needle aspiration cytology of an intrathyroidal nodule diagnosed as squamous cell carcinoma: A case report
Yu JY, Zhang Y, Wang Z
- 9990** Extensive abdominal lymphangiomatosis involving the small bowel mesentery: A case report
Alhasan AS, Daqqaq TS
- 9997** Gastrointestinal symptoms as the first sign of chronic granulomatous disease in a neonate: A case report
Meng EY, Wang ZM, Lei B, Shang LH
- 10006** Screw penetration of the iliopsoas muscle causing late-onset pain after total hip arthroplasty: A case report
Park HS, Lee SH, Cho HM, Choi HB, Jo S

- 10013** Uretero-lumbar artery fistula: A case report
Chen JJ, Wang J, Zheng QG, Sun ZH, Li JC, Xu ZL, Huang XJ
- 10018** Rare mutation in MKRN3 in two twin sisters with central precocious puberty: Two case reports
Jiang LQ, Zhou YQ, Yuan K, Zhu JF, Fang YL, Wang CL
- 10024** Primary mucosal-associated lymphoid tissue extranodal marginal zone lymphoma of the bladder from an imaging perspective: A case report
Jiang ZZ, Zheng YY, Hou CL, Liu XT
- 10033** Focal intramural hematoma as a potential pitfall for iatrogenic aortic dissection during subclavian artery stenting: A case report
Zhang Y, Wang JW, Jin G, Liang B, Li X, Yang YT, Zhan QL
- 10040** Ventricular tachycardia originating from the His bundle: A case report
Zhang LY, Dong SJ, Yu HJ, Chu YJ
- 10046** Posthepatectomy jaundice induced by paroxysmal nocturnal hemoglobinuria: A case report
Liang HY, Xie XD, Jing GX, Wang M, Yu Y, Cui JF

ABOUT COVER

Editorial Board Member of *World Journal of Clinical Cases*, Jalaj Garg, FACC, MD, Academic Research, Assistant Professor, Division of Cardiology, Medical College of Wisconsin, Milwaukee, WI 53226, United States.
garg.jalaj@yahoo.com

AIMS AND SCOPE

The primary aim of *World Journal of Clinical Cases* (WJCC, *World J Clin Cases*) is to provide scholars and readers from various fields of clinical medicine with a platform to publish high-quality clinical research articles and communicate their research findings online.

WJCC mainly publishes articles reporting research results and findings obtained in the field of clinical medicine and covering a wide range of topics, including case control studies, retrospective cohort studies, retrospective studies, clinical trials studies, observational studies, prospective studies, randomized controlled trials, randomized clinical trials, systematic reviews, meta-analysis, and case reports.

INDEXING/ABSTRACTING

The WJCC is now indexed in Science Citation Index Expanded (also known as SciSearch®), Journal Citation Reports/Science Edition, Scopus, PubMed, and PubMed Central. The 2021 Edition of Journal Citation Reports® cites the 2020 impact factor (IF) for WJCC as 1.337; IF without journal self cites: 1.301; 5-year IF: 1.742; Journal Citation Indicator: 0.33; Ranking: 119 among 169 journals in medicine, general and internal; and Quartile category: Q3. The WJCC's CiteScore for 2020 is 0.8 and Scopus CiteScore rank 2020: General Medicine is 493/793.

RESPONSIBLE EDITORS FOR THIS ISSUE

Production Editor: Jia-Hui Li; Production Department Director: Yu-Jie Ma; Editorial Office Director: Jin-Lei Wang.

NAME OF JOURNAL

World Journal of Clinical Cases

ISSN

ISSN 2307-8960 (online)

LAUNCH DATE

April 16, 2013

FREQUENCY

Thrice Monthly

EDITORS-IN-CHIEF

Dennis A Bloomfield, Sandro Vento, Bao-Gan Peng

EDITORIAL BOARD MEMBERS

<https://www.wjnet.com/2307-8960/editorialboard.htm>

PUBLICATION DATE

November 16, 2021

COPYRIGHT

© 2021 Baishideng Publishing Group Inc

INSTRUCTIONS TO AUTHORS

<https://www.wjnet.com/bpg/gerinfo/204>

GUIDELINES FOR ETHICS DOCUMENTS

<https://www.wjnet.com/bpg/GerInfo/287>

GUIDELINES FOR NON-NATIVE SPEAKERS OF ENGLISH

<https://www.wjnet.com/bpg/gerinfo/240>

PUBLICATION ETHICS

<https://www.wjnet.com/bpg/GerInfo/288>

PUBLICATION MISCONDUCT

<https://www.wjnet.com/bpg/gerinfo/208>

ARTICLE PROCESSING CHARGE

<https://www.wjnet.com/bpg/gerinfo/242>

STEPS FOR SUBMITTING MANUSCRIPTS

<https://www.wjnet.com/bpg/GerInfo/239>

ONLINE SUBMISSION

<https://www.f6publishing.com>

Respiratory failure after scoliosis correction surgery in patients with Prader-Willi syndrome: Two case reports

Ju-Yul Yoon, Sung-Hee Park, Yu Hui Won

ORCID number: Ju-Yul Yoon [0000-0002-2379-6158](https://orcid.org/0000-0002-2379-6158); Sung-Hee Park [0000-0002-4743-2551](https://orcid.org/0000-0002-4743-2551); Yu Hui Won [0000-0003-2007-9652](https://orcid.org/0000-0003-2007-9652).

Author contributions: Won YH and Park SH contributed to the conception and design of the study or acquisition of data, or analysis and interpretation of data; Won YH and Yoon JY contributed to the drafting of the article or revising it critically for important intellectual content; and all authors provided final approval of the version to be submitted.

Informed consent statement:

Informed written consent was obtained from the patient for publication of this report and any accompanying images.

Conflict-of-interest statement: The authors declare that they have no conflicts of interest.

CARE Checklist (2016) statement:

The authors have read the CARE Checklist (2016), and the manuscript was prepared and revised according to the CARE Checklist (2016).

Open-Access: This article is an open-access article that was selected by an in-house editor and fully peer-reviewed by external reviewers. It is distributed in accordance with the Creative

Ju-Yul Yoon, Sung-Hee Park, Yu Hui Won, Department of Physical Medicine and Rehabilitation, Jeonbuk National University Medical School, Jeonju 54907, Jeonbuk, South Korea

Sung-Hee Park, Yu Hui Won, Research Institute of Clinical Medicine of Jeonbuk National University - Biomedical Research Institute of Jeonbuk National University Hospital, Jeonju 54907, Jeonbuk, South Korea

Corresponding author: Yu Hui Won, MD, PhD, Professor, Department of Physical Medicine and Rehabilitation, Jeonbuk National University Medical School, 20 Geonjiro, Jeonju 54907, Jeonbuk, South Korea. wonyh@jbnu.ac.kr

Abstract

BACKGROUND

Sleep-disordered breathing, including hypoventilation and obstructive sleep apnea, is often observed in Prader-Willi syndrome (PWS). Particularly in adolescence, scoliosis causes a progressive restrictive pulmonary pattern, leading to hypoventilation, so timely corrective surgery is required. However, the effect is controversial. In addition, since mental retardation of PWS, patient effort-based respiratory tests may be less reliable. So far, no studies have accurately reported on the comparison of respiratory function before and after corrective surgery, and appropriate respiratory function measurement method in PWS.

CASE SUMMARY

We present two cases of adolescent PWS with typical characteristics, including obesity, mental retardation, and scoliosis. Two boys, aged 12 and 13, diagnosed with PWS, both underwent scoliosis correction surgery. Before and immediately after surgery, arterial blood tests showed no abnormalities and no respiratory symptoms occurred. However, after 6-7 mo, both patients complained of daytime sleepiness, difficulty sleeping at night, dyspnea on exertion, and showed cyanosis. Hypercapnia and hypoxia were confirmed by polysomnography and transcutaneous CO₂ monitoring during sleep and were diagnosed with obstructive sleep apnea and alveolar hypoventilation. It was corrected by nighttime noninvasive ventilation application and normal findings of arterial blood gas were maintained after 6-8 mo follow-up.

CONCLUSION

Even after scoliosis surgery, "periodic" monitoring of respiratory failure with an "objective" test method is needed for timely respiratory support.

Commons Attribution NonCommercial (CC BY-NC 4.0) license, which permits others to distribute, remix, adapt, build upon this work non-commercially, and license their derivative works on different terms, provided the original work is properly cited and the use is non-commercial. See: <http://creativecommons.org/licenses/by-nc/4.0/>

Specialty type: Medicine, research and experimental

Country/Territory of origin: South Korea

Peer-review report's scientific quality classification

Grade A (Excellent): 0
Grade B (Very good): 0
Grade C (Good): C, C
Grade D (Fair): 0
Grade E (Poor): 0

Received: June 14, 2021

Peer-review started: June 14, 2021

First decision: July 26, 2021

Revised: August 3, 2021

Accepted: September 15, 2021

Article in press: September 15, 2021

Published online: November 16, 2021

P-Reviewer: Bersot CD, Lv Y

S-Editor: Wang JJ

L-Editor: A

P-Editor: Wu RR



Key Words: Prader-Willi syndrome; Respiratory failure; Noninvasive ventilation; Obstructive sleep apnea; Scoliosis; Case report

©The Author(s) 2021. Published by Baishideng Publishing Group Inc. All rights reserved.

Core Tip: We describe two cases of adolescent Prader-Willi syndrome (PWS) with typical characteristics, such as obesity, mental retardation, and scoliosis, in which respiratory failure with severe desaturation and hypercapnia occurred after scoliosis correction surgery. Respiratory failure was confirmed and diagnosed by polysomnography (PSG) and transcutaneous CO₂ monitoring and successfully treated with overnight noninvasive ventilation. These cases highlight the need for objective respiratory tests and timely respiratory support through perioperative and periodic pulmonary check-ups in PWS patients with cognitive decline. Guidelines for full PSG studies, including CO₂ monitoring, should be framed to detect hypoventilation within a certain time post-surgery for scoliosis.

Citation: Yoon JY, Park SH, Won YH. Respiratory failure after scoliosis correction surgery in patients with Prader-Willi syndrome: Two case reports. *World J Clin Cases* 2021; 9(32): 9960-9969

URL: <https://www.wjgnet.com/2307-8960/full/v9/i32/9960.htm>

DOI: <https://dx.doi.org/10.12998/wjcc.v9.i32.9960>

INTRODUCTION

Prader-Willi syndrome (PWS) is a genetic disorder arising from chromosome 15q11-q13, which causes hypotonia and delayed development in infancy, mental retardation, obesity, short stature, and behavioral and psychiatric disturbances with further growth [1,2].

Sleep disordered breathing (SDB) is known to be a common cardiopulmonary complication in PWS [3]. The most two representative causative factors are obstructive sleep apnea (OSA) due to airway narrowing caused by obesity and hypotonia [3,4], and hypoventilation due to progressive deterioration of the restrictive pattern of the lungs caused by scoliosis [3,5,6]. Respiratory symptoms appear from infancy, and OSA is known to be a major contributing factor after 2 years of age [7]. Growing up, adolescents with PWS are known to be in a period in which scoliosis progresses rapidly [8], and consequently, a restrictive pattern of the pulmonary system can progress. Therefore, scoliosis correction surgery can be performed to prevent and correct respiratory deterioration [3,8]. However, there has been no accurate report on changes in respiratory function before and after scoliosis surgery, and the prevalence of nocturnal hypoventilation and the rate of progression to cor pulmonale in PWS patients. Therefore, in order to establish criteria for prophylactic scoliosis surgery and to properly monitor respiratory function in PWS patients, reliable respiratory function tests are needed. To date, one of the methods of respiratory function evaluation for pediatric scoliosis, including children with PWS, is known as the patient effort-based test such as forced expiratory volume in the first second (FEV₁) [4,9], total lung capacity (TLC) [5] and forced vital capacity (FVC) [6] in several studies. Even if reproducibility and reliability are improved through multiple test trials [10], results of patient effort-based tests such as FEV₁, FVC, and TLC have a fundamental limitation that results might vary depending on patient participation [6]. In particular, multiple trials of tests will be clinically difficult due to poor cooperation for children who have neurologic deficits accompanied by mental retardation, such as PWS, and the efforts to participate are likely to be inconsistent by circumstance (parental attendance, evaluation room environment, psychological state, etc.), which would lower the reliability of the tests.

On the other hand, as a patient non-effort-based respiratory tests, end-tidal CO₂ monitoring, transcutaneous CO₂ monitoring [6,11] or polysomnography (PSG) [6] can be tried, but it is not easy when compared to the patient effort-based pulmonary function test because monitoring is required for several hours during sleep and hospitalization is required. In the case of neuromuscular disease in which respiratory muscle weakness is common, these tests are conventionally performed according to

established guidelines[12,13]. Whereas for PWS, since scoliosis does not occur in all patients[3,8], and respiratory muscle weakness known to be not severe[3], there is no established evidence-based guideline for routine respiratory function monitoring, so somewhat burdensome non-effort-based respiratory test is not conventionally performed.

Taken together, there are two things to consider: (1) Whether scoliosis repair surgery is guaranteed to improve the respiratory system of the restrictive pattern of PWS; and (2) Search for reliable and objective measurement method of respiratory function of PWS.

We present cases of adolescent PWS in which hypercapnic respiratory failure with sleep apnea occurred after surgical treatment of scoliosis and treatment involved noninvasive ventilation (NIV). We aimed to highlight the need for clinical guidelines regarding the timely detection of respiratory failure through regular and objective respiratory monitoring in these patients, especially after scoliosis correction surgery.

CASE PRESENTATION

Chief complaints

Case 1: A 12-year-old male patient diagnosed with PWS complained of difficulty sleeping in the supine position, severe snoring, daytime sleepiness, sweating, and intermittent chest tightness at 6 mo after scoliosis correction surgery.

Case 2: A 13-year-old male patient diagnosed with PWS complained of shortness of breath even with light exertion, daytime sleepiness, and nighttime cyanosis and apnea at 7 mo after scoliosis correction surgery.

History of present illness

Case 1: The patient underwent surgery for scoliosis (thoracic Cobb's angle of 66.1°, lumbar Cobb angle of 34.5°) at 12 years of age (Figure 1A, Table 1). Immediately after correction surgery, the patient was transferred to the Department of Rehabilitation Medicine and received treatment for 4 wk. The patient was discharged without side effects or sequelae and followed up as an outpatient. However, 6 mo postoperatively, the patient complained of the above-mentioned respiratory symptoms and was subsequently admitted for pulmonary evaluation at the Department of Rehabilitation Medicine in a tertiary hospital.

Case 2: The patient underwent surgery for scoliosis (thoracic Cobb's angle of 82.6°, lumbar Cobb's angle of 54.9°) at 13 years of age (Figure 2A, Table 1). Immediately after correction surgery, there were no prominent respiratory symptoms, and the patient was discharged without any side effects or sequelae and followed up as an outpatient. Seven months postoperatively, the patient complained of the above-mentioned respiratory symptoms and was subsequently admitted for pulmonary evaluation at the Department of Rehabilitation Medicine in a tertiary hospital.

History of past illness

Case 1: The patient underwent surgery for scoliosis (thoracic Cobb's angle of 66.1°, lumbar Cobb angle of 34.5°) at 12 years of age (Figure 1A, Table 1). Immediately after correction surgery, the patient was transferred to the Department of Rehabilitation Medicine and received treatment for 4 wk. The patient was discharged without side effects or sequelae and followed up as an outpatient. However, 6 mo postoperatively, the patient complained of the above-mentioned respiratory symptoms and was subsequently admitted for pulmonary evaluation at the Department of Rehabilitation Medicine in a tertiary hospital.

Case 2: The patient underwent surgery for scoliosis (thoracic Cobb's angle of 82.6°, lumbar Cobb's angle of 54.9°) at 13 years of age (Figure 2A, Table 1). Immediately after correction surgery, there were no prominent respiratory symptoms, and the patient was discharged without any side effects or sequelae and followed up as an outpatient. Seven months postoperatively, the patient complained of the above-mentioned respiratory symptoms and was subsequently admitted for pulmonary evaluation at the Department of Rehabilitation Medicine in a tertiary hospital.

Personal and family history

Case 1: The patient had no remarkable family history.

Table 1 Demographics of two cases

| | Case 1 | | Case 2 | |
|----------------------------|------------------|----------------------------------|--------------|----------------------------------|
| Birth age (wk) | NSVD, 35 + 2 | | NSVD, 41 + 1 | |
| Weight at birth (g) | 2100 | | 3100 | |
| Age of PWS diagnosis | 5 mon | | 2 yr | |
| Sex | Male | | Male | |
| Growth hormone therapy | Ongoing for 4 yr | | Not applied | |
| Scoliosis surgery | Before OP | Post OP (At respiratory failure) | Before OP | Post OP (At respiratory failure) |
| Scoliosis Cobb's angle (°) | 66.1 | 54 | 82.6 | 71.8 |
| Height (cm) | 134 | 137 | 141 | 143 |
| Weight (kg) | 53.5 | 57 | 79.5 | 87 |
| BMI (kg/m ²) | 29.8 | 30.4 | 40.0 | 42.5 |
| Age (yr) | 12 | 12 | 13 | 13 |

BMI: Body mass index; OP: Scoliosis repair surgery; PWS: Prader-Willi syndrome; NSVD: Normal spontaneous vaginal delivery.

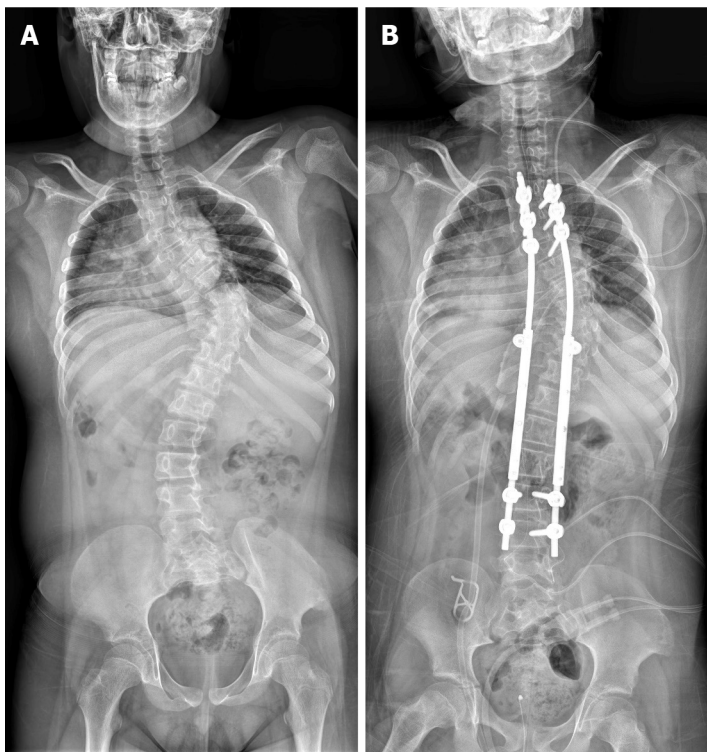


Figure 1 Case 1: Scoliosis X-ray before and after scoliosis correction operation. A: Scoliosis X-ray before scoliosis correction operation; B: Scoliosis X-ray after scoliosis correction operation.

Case 2: The patient had no remarkable family history.

Physical examination

Case 1: In terms of cognitive function, the intelligence test could not be performed due to the patient's inability to comprehend.

Regarding respiratory function, the pulmonary function test showed a FVC of 0.96 L (48% of predicted) performed before scoliosis correction surgery. At the time of symptom onset (6 mo after surgery), the FVC was 0.68 L (31% of predicted) (Table 2).

With regard to body weight, the patient weighed 53.5 kg [body mass index (BMI): 29.8 kg/m²] at the time of operation. Six months after surgery, the patient's weight was

Table 2 Respiratory status before and after noninvasive ventilator apply

| | Case 1 | | | | Case 2 | | | |
|------------------------------------|-------------------|--------------------|-------------------|------------|--------------------|--------------------|--------------------|-------------------|
| | Post OP | Before NIV | After NIV | F/U (5 mo) | Post OP | Before NIV | After NIV | F/U (12 mo) |
| ABG test¹ | | | | | | | | |
| pH | 7.55 | 7.347 ⁴ | 7.38 | 7.403 | 7.393 | 7.375 ⁴ | 7.372 ⁴ | 7.384 |
| PaO ₂ (mmHg) | 87 | 54.2 ⁴ | 106.9 | 83.3 | 63.4 | 37.2 ⁴ | 99.0 ⁴ | 65.5 |
| PaCO ₂ (mmHg) | 42 | 55.2 ⁴ | 47.7 | 36.0 | 56.3 | 53.4 ⁴ | 48.9 ⁴ | 48.9 |
| SaO ₂ (%) | 98 | 85.2 ⁴ | 98.0 | 96.3 | 91.1 | 68.1 ⁴ | 97.4 ⁴ | 92.8 |
| Transcutaneous monitoring | | | | | | | | |
| SaO ₂ min (%) | NT | 50 ⁴ | 90 ⁴ | 86 | NT | NT | 74 ⁴ | 86 ³ |
| SaO ₂ mean (%) | NT | 89 ⁴ | 98 ⁴ | 96 | NT | NT | 96 ⁴ | 98 ³ |
| TcCO ₂ mean (mmHg) | NT | 62.2 ⁴ | 52.2 ⁴ | 40.5 | NT | NT | 42.9 ⁴ | 41.7 ³ |
| TcCO ₂ max (mmHg) | NT | 71.6 ⁴ | 61.1 ⁴ | 48.1 | NT | NT | 53.1 ⁴ | 43 ³ |
| Pulmonary function test | | | | | | | | |
| FVC (L) | 0.96 ² | 0.68 | NT | 0.42 | 1.09 ² | 0.89 | 0.84 | 0.98 |
| FVC (%) | 48 ² | 31 | NT | 18 | 47 ² | 35 | 34 | 39 |
| Respiratory muscle strength | | | | | | | | |
| MIP (mmHg) | NT | 17 | NT | 17 | 45 ² | 59 | 62 | 53 |
| MIP (%) | NT | 19.5 | NT | 19.5 | 47.4 ² | 54.9 | 56.9 | 45.8 |
| MEP (mmHg) | NT | 14 | NT | 20 | 98 ² | 76 | 85 | 59 |
| MEP (%) | NT | 13.9 | NT | 19.8 | 102.6 ² | 71.4 | 79.8 | 52.7 |

¹Measured in the morning (reflecting respiration values during sleep).²Measured before surgery.³Measured 6 months after NIV application.⁴Measured value use of O₂. ABG: Arterial blood gas; F/U: Follow up; FVC: Forced vital capacity; MEP: Maximal expiratory pressure; MIP: Maximal inspiratory pressure; NIV: Noninvasive ventilation; NT: Not tested; PFT: Pulmonary function test; TcCO₂: Transcutaneous carbon dioxide pressure.

57 kg (BMI: 30.4 kg/m²), which was a 3.5 kg weight gain compared to the preoperative weight (Table 1).

Case 2: In terms of cognitive function, the Wechsler Intelligence Scale for Children-III showed moderate intellectual disability (verbal scale IQ: 51, performance scale IQ: 58, full-scale IQ: 50).

Regarding respiratory function, the pulmonary function test showed a FVC of 1.09 L (47% of predicted) performed before scoliosis correction surgery. At the time of symptom onset (7 mo after surgery), the FVC was 0.89 L (35% of predicted) (Table 2).

With regard to body weight, the patient weighed 79.5 kg (BMI: 40.0 kg/m²) at the time of operation. Six months after surgery, the patient's weight was 87 kg (BMI: 42.5 kg/m²), which was a 7.5 kg weight gain compared to the preoperative weight (Table 1).

Laboratory examinations

Case 1: The early morning arterial blood gas (ABG) test result at postoperative day 2 was within normal range with a pH 7.55, pCO₂ 42 mmHg, pO₂ 87 mmHg, SaO₂ 98.0% (Table 2). After 1 mo of rehabilitation, the ABG test result was also normal with pH 7.465, pCO₂ 32.6 mmHg, pO₂ 126.3 mmHg, and SaO₂ 99.1%. At the time of symptom onset (6 mo after surgery), even with 2 L/min of O₂ via nasal prong, the early morning ABG test revealed hypoxemia and hypercapnia with pH 7.347, pO₂ 54.2 mmHg, SaO₂ 85.2%, and pCO₂ 55.2 mmHg. Overnight transcutaneous CO₂ and O₂ monitoring also showed severe hypoxemia and hypercapnia (Table 2). In addition, daytime transcutaneous CO₂ and O₂ monitoring conducted without oxygen supplementation showed minimal SaO₂ 50%, mean SaO₂ 81%, maximal TcCO₂ 60.1 mmHg, and mean TcCO₂ 52.9 mmHg. PSG was performed but terminated early as oxygen saturation decreased

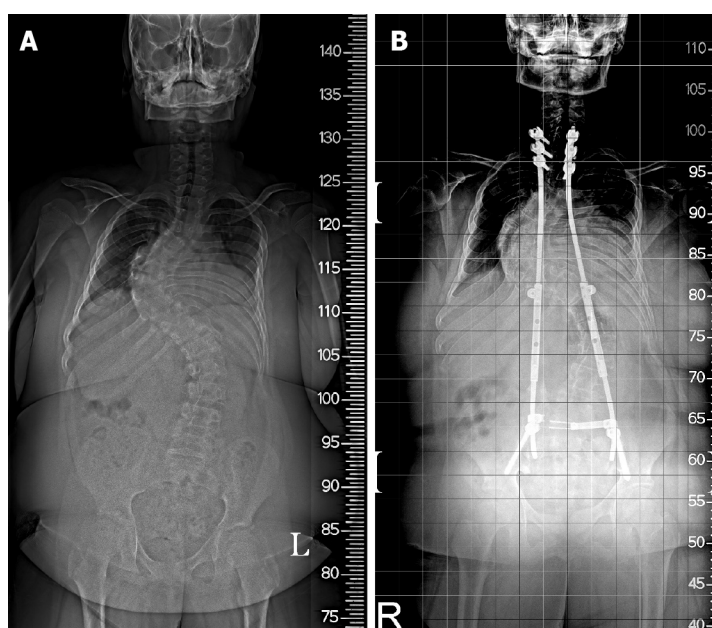


Figure 2 Case 2: Scoliosis X-ray before and after scoliosis correction operation. A: Scoliosis X-ray before scoliosis correction operation; B: Scoliosis X-ray after scoliosis correction operation.

below 50% at 1 h. Thus, only incomplete results were obtained showing an apnea-hypopnea index (AHI) of 91.2/h, which demonstrated severe OSA (Table 3). Echocardiography demonstrated findings of pulmonary hypertension.

Case 2: The preoperative ABG test showed normal findings: pH, 7.376; $p\text{CO}_2$ 43.9 mmHg; $p\text{O}_2$ 78.0 mmHg; and SaO_2 95.9%. Immediately after surgery, the ABG test exhibited the effect of atelectasis with pH 7.393, $p\text{CO}_2$ 56.3 mmHg, $p\text{O}_2$ 63.4 mmHg, and SaO_2 91.1% (Table 2). At the time of symptom onset (7 mo after surgery), even with 5 L/min of O_2 via nasal prong, the early morning ABG test showed findings of severe hypoxemia and moderate hypercapnia with pH 7.375, $p\text{O}_2$ 37.2 mmHg, SaO_2 68.1%, and $p\text{CO}_2$ 53.4 mmHg (Table 2). Overnight transcutaneous CO_2 and O_2 monitoring was not performed prior to treatment because the patient's symptoms and abnormality were so severe that treatment was immediately performed at the time of admission to the hospital. PSG demonstrated severe OSA at AHI 33.9/h and mean SaO_2 79.2% (Table 3). Echocardiography did not show any significant pulmonary hypertension.

Imaging examinations

Case 1: The patient's scoliosis radiographs before and after surgery are shown in Figure 1.

Case 2: The patient's scoliosis radiographs before and after surgery are shown in Figure 2.

FINAL DIAGNOSIS

Both patients were diagnosed with alveolar hypoventilation along with OSA.

TREATMENT

Case 1

Overnight NIV was initiated during admission. A nasal mask was used for ventilation, and the pressure support ventilation mode was used at an inspired positive airway pressure (IPAP) of 20 cm H_2O , positive end-expiratory pressure (PEEP) of 5 cm H_2O , and respiratory rate (RR) of 18 breaths/min without O_2 supply.

Table 3 Results of polysomnography

| | Case 1 | Case 2 |
|--------------------------------|---------------------|---------------------|
| Polysomnography | 6 mon after surgery | 7 mon after surgery |
| CAI (events/h) | 0 | 0 |
| Obstructive apnea (events/h) | 10 | 1.4 |
| Hypopnea (events/h) | 82 | 32.5 |
| AHI (events/h) | 91.2 | 33.9 |
| ODI | 90.2 | 31.8 |
| Total arousal index (events/h) | 4 | 9.9 |
| Mean sleep SaO ₂ % | 74.6 | 79.2 |
| Minimal SaO ₂ % | 50 | 50 |
| Neck circumference (cm) | 39 | 39 |

AHI: Apnea-hypopnea index; CAI: Central apnea index; ODI: Oxygen desaturation index; SaO₂: Oxygen saturation.

Case 2

The patient was initiated on overnight NIV on the day of admission. Pressure-synchronized intermittent mandatory ventilation at an IPAP of 10 cm H₂O, PEEP of 5 cm H₂O, pressure support of 6 cm H₂O, and RR of 16 breaths/min were applied *via* an oronasal mask with 2 L of O₂ supply.

OUTCOME AND FOLLOW-UP

Case 1

The previously mentioned nighttime NIV application improved sleeping difficulties and shortness of breath, and overnight transcutaneous ventilation monitoring showed that hypoxia and hypercapnia were corrected (Table 2). In addition, daytime monitoring results without NIV application were within normal ranges with minimal SaO₂ 85%, mean SaO₂ 94%, maximal TcCO₂ 52.5 mmHg, and mean TcCO₂ 44.7 mmHg. Therefore, the patient was discharged while NIV was maintained overnight. Five months later, under identical settings, ABG and overnight transcutaneous CO₂ and O₂ monitoring demonstrated normal respiration. Therefore, the setting was maintained, and the patient was using NIV overnight (Table 2). Although FVC measured at 5 mo decreased to 0.42 L (18%) from initiation of NIV, it increased to 1.3 L (50%) at 1 year and 0.96 L (37%) at 2 years.

Case 2

The previously mentioned nighttime NIV application improved nighttime cyanosis and apnea, and the patient was able to sleep well. In addition, as the shortness of breath with exertion decreased, daytime activity increased. Overnight transcutaneous monitoring showed improvements in ventilation with an O₂ supply (Table 2). In addition, daytime monitoring results without NIV application were within normal ranges with minimal SaO₂ 83%, mean SaO₂ 95%, maximal TcCO₂ 47.9 mmHg, and mean TcCO₂ 31.5 mmHg. Therefore, the patient was discharged while NIV was maintained overnight. After 6 mo, the setting was changed to assist control ventilation mode at a tidal volume of 760 mL, PEEP of 5 cm H₂O, and RR of 16 breaths/min for stable tidal volume. Transcutaneous CO₂ and O₂ monitoring demonstrated that respiration was well maintained. At follow-up (12 mo after NIV application), no significant respiratory gas abnormalities were observed compared to baseline in the ABG test.

DISCUSSION

This case series includes adolescent PWS patients with typical PWS characteristics,

such as obesity, mental retardation, short stature, and scoliosis; who had a respiratory failure with severe desaturation 6-7 mo after scoliosis correction surgery; and were successfully treated with overnight NIV. Although both patients were regularly followed by a rehabilitation physician, respiratory failure progressed 6-7 mo after surgical treatment of scoliosis, without any particular preoperative symptoms. On PSG and TcCO₂ monitoring, severe OSA and hypoventilation were observed in both cases. Although patient 1 had no nocturnal hypoventilation on the ABG test immediately after scoliosis surgery, the symptoms developed quickly, within 6 mo postoperatively. Patient 2 also had no respiratory symptoms or abnormalities on the ABG test before scoliosis surgery. However, 7 mo after surgery, daytime drowsiness, severe desaturation, and dyspnea on exertion began.

Mechanism of respiratory failure in PWS

OSA, central sleep apnea, and nocturnal hypoventilation are the three main mechanisms that lead to respiratory failure in PWS. Each mechanism is interrelated and not completely independent[3]. Obesity with hypotonia and scoliosis are factors that commonly affect OSA and nocturnal hypoventilation, both of which increase respiratory loading[14].

Most research has focused on the co-occurrence of OSA and PWS. Approximately 80% of children with PWS have OSA, and more than 50% of them show mild severity [15]. The severity of OSA increases in younger patients and those with a higher BMI [15]. Although severe OSA is not common in PWS patients[15], nocturnal hypoventilation is 33% more frequent in PWS patients with OSA than in those with primary OSA[11]. Therefore, it is necessary to consider that not only OSA but also other factors such as obesity, muscle hypotonia (possible respiratory involvement), and scoliosis have a complex effect on the respiratory issues of PWS[3].

Obesity in PWS

Obesity in PWS patients shows abnormal hypercapnic and hypoxic ventilator responses, which are the pathophysiology of SDB[4]. It has been shown that weight loss improves OSA and nocturnal hypoventilation[16]. Both patients gained weight (3.5 kg and 7.5 kg, respectively) after surgery. Postoperative immobility and pain may have decreased the amount of activity, and the amount of food for children who want secondary compensation may not have been adequately controlled. However, since the degree of weight gain was not rapid in this case, weight gain would not have a decisive effect on respiratory failure. We believe that the correction of scoliosis is more likely to have made a greater contribution to respiratory failure in this case.

Scoliosis in PWS

The incidence of PWS in scoliosis is reported to be 30%–70%[17], which is known to cause restrictive breathing patterns[10] and consequently, hypoventilation[18]. Considering its long-term effect, scoliosis repair surgery could be effective in relieving nocturnal hypoventilation and sleep apnea by reducing the restrictive pulmonary pattern[8]. However, the effect of scoliosis surgery on respiratory function remains controversial[5]. After surgery, atelectasis may occur, and since the thoracic spine is fixed (with thoracic ribs), it may cause immediate deterioration of the restrictive respiratory pattern[5]. In addition, factors such as respiratory depression due to pain during breathing after surgery[5] and maintenance of postoperative immobility posture for a certain period of time[5] could contribute to the worsening of breathing patterns.

Due to postoperative complications, multidisciplinary approaches associated with neuromuscular disease and PWS are required[17]. However, little research has been conducted on postoperative respiratory complications and the worsening of respiratory functions, especially in PWS.

In addition, regarding growth hormones, more attention should be given to the respiration of PWS. Research has focused on the relationship between scoliosis and growth hormone in cases of PWS, and recent consensus guidelines suggest that the incidence or progression of scoliosis is not influenced by growth hormone and that growth hormone therapy is not contraindicated[19]. However, there are studies on the possibility of sudden death from the use of growth hormones[1]. One of the possible leading causes of sudden death is respiratory issues due to abnormal arousal (insensitive to hypoxia) and cardiopulmonary response to hypoxia[3]. Therefore, respiratory monitoring of children with PWS using growth hormones is very important, which corresponds with patient 1.

In Duchenne muscular dystrophy or spinal muscular atrophy, which are typical pediatric neuromuscular disorders, there are age- and function-appropriate recommendations to test and prevent respiratory failure, thus enabling early detection[12, 13]. Although PWS patients show respiratory muscle impairment (hypotonia)[10], there seems to be no progressive respiratory muscle weakness, which is observed in Duchenne muscular dystrophy or spinal muscular atrophy. Therefore, it is difficult to follow these recommendations in patients with PWS.

As a patient effort-based test, FVC is known to reflect pulmonary function before and after repair surgery in patients with primary scoliosis rather than syndromic (secondary) scoliosis[5]. Moreover, since children with PWS typically show mental retardation, the reliability of patient effort-based pulmonary function tests is low. Therefore, it is necessary to perform “objective” tests such as TcCO₂ monitoring and PSG, and timely ventilatory support through “periodic” tests, as in neuromuscular diseases[14]. Thus, irreversible deterioration findings, such as cor pulmonale, could be prevented[8]. Although a previous study reported that preoperative PSG did not predict prolonged postoperative ventilator use after scoliosis surgery[20], a recent study revealed that before severe scoliosis repair surgery, severely compromised respiratory function could be confirmed in advance through PSG and overnight TcCO₂ monitoring, both of which measure hypoventilation. According to the PSG and TcCO₂ results, there was an advantage of the timely use of a non-invasive ventilator that could avoid tracheostomy[6].

It is presumed that the correction surgery contributed to the cause of the respiratory failure of the patients in this case, but we are not sure whether it is purely due to correction surgery or other features of the underlying PWS (hypotonia, obesity, OSA) affects[3]. Whatever the cause, the dangerous situation due to hypoventilation, that could lead to irreversible complications such as cor pulmonale, seen in this case should be prevented.

In contrast to great deal of research conducted on OSA in PWS patients, there has been no accurate report on the prevalence of alveolar hypoventilation or the progression to cor pulmonale; but recent guidelines for pediatric patients with PWS only recommend the use of PSG to evaluate residual OSA after adenotonsillectomy[21] and prior to growth hormone therapy[22]. Therefore, guidelines on conducting PSG and recommending concurrent CO₂ monitoring are required. Moreover, as is implied in the present case series, scoliosis surgery does not seem to guarantee improvement in respiratory function in PWS, and furthermore, respiratory-related monitoring must be performed for a certain period after surgery. Further PWS studies on the influence of the progression of surgical treatment for scoliosis on respiratory failure should be conducted in order to produce guidelines recommending a full PSG study, including CO₂ monitoring within a certain period of time after surgical treatment for scoliosis.

CONCLUSION

Even after scoliosis surgery to improve respiratory function in PWS patients, it is necessary to “periodic” monitor respiratory failure with an “objective” test method such as PSG or EtCO₂, and timely NIV support can prevent respiratory-related irreversible complications.

ACKNOWLEDGEMENTS

The authors thank all members of the Department of Physical Medicine & Rehabilitation and Translational Research and Clinical Trials Center for Medical Devices, Jeonbuk National University Hospital.

REFERENCES

- 1 Cassidy SB, Schwartz S, Miller JL, Driscoll DJ. Prader-Willi syndrome. *Genet Med* 2012; **14**: 10-26 [PMID: 22237428 DOI: 10.1038/gim.0b013e31822bead0]
- 2 Irizarry KA, Miller M, Freemark M, Haqq AM. Prader Willi Syndrome: Genetics, Metabolomics, Hormonal Function, and New Approaches to Therapy. *Adv Pediatr* 2016; **63**: 47-77 [PMID: 27426895 DOI: 10.1016/j.yapd.2016.04.005]
- 3 Tan HL, Urquhart DS. Respiratory Complications in Children with Prader Willi Syndrome. *Paediatr*

- Respir Rev* 2017; **22**: 52-59 [PMID: 27839656 DOI: 10.1016/j.prrv.2016.08.002]
- 4 **Arens R**, Gozal D, Omlin KJ, Livingston FR, Liu J, Keens TG, Ward SL. Hypoxic and hypercapnic ventilatory responses in Prader-Willi syndrome. *J Appl Physiol* (1985) 1994; **77**: 2224-2230 [PMID: 7868438 DOI: 10.1152/jappl.1994.77.5.2224]
 - 5 **Koumbourlis AC**. Scoliosis and the respiratory system. *Paediatr Respir Rev* 2006; **7**: 152-160 [PMID: 16765303 DOI: 10.1016/j.prrv.2006.04.009]
 - 6 **Al-Iede MM**, Al-Zayadneh E, Bridge C, Alqutawneh B, Waters K. Risk factors for postoperative pulmonary complications in children with severely compromised pulmonary function secondary to severe scoliosis. *Pediatr Pulmonol* 2020; **55**: 2782-2790 [PMID: 32729967 DOI: 10.1002/ppul.24997]
 - 7 **Cohen M**, Hamilton J, Narang I. Clinically important age-related differences in sleep related disordered breathing in infants and children with Prader-Willi Syndrome. *PLoS One* 2014; **9**: e101012 [PMID: 24979549 DOI: 10.1371/journal.pone.0101012]
 - 8 **van Bosse HJP**, Butler MG. Clinical Observations and Treatment Approaches for Scoliosis in Prader-Willi Syndrome. *Genes (Basel)* 2020; **11** [PMID: 32121146 DOI: 10.3390/genes11030260]
 - 9 **Haqq AM**, Stadler DD, Jackson RH, Rosenfeld RG, Purnell JQ, LaFranchi SH. Effects of growth hormone on pulmonary function, sleep quality, behavior, cognition, growth velocity, body composition, and resting energy expenditure in Prader-Willi syndrome. *J Clin Endocrinol Metab* 2003; **88**: 2206-2212 [PMID: 12727976 DOI: 10.1210/jc.2002-021536]
 - 10 **Hákonarson H**, Moskovitz J, Daigle KL, Cassidy SB, Cloutier MM. Pulmonary function abnormalities in Prader-Willi syndrome. *J Pediatr* 1995; **126**: 565-570 [PMID: 7699534 DOI: 10.1016/s0022-3476(95)70350-0]
 - 11 **Abel F**, Tan HL, Negro V, Bridges N, Carlisle T, Chan E, Laverty A, Miligkos M, Samuels M, Kaditis AG. Hypoventilation disproportionate to OSAS severity in children with Prader-Willi syndrome. *Arch Dis Child* 2019; **104**: 166-171 [PMID: 30007944 DOI: 10.1136/archdischild-2017-314282]
 - 12 **Birnkrant DJ**, Bushby K, Bann CM, Alman BA, Apkon SD, Blackwell A, Case LE, Cripe L, Hadjiyannakis S, Olson AK, Sheehan DW, Bolen J, Weber DR, Ward LM; DMD Care Considerations Working Group. Diagnosis and management of Duchenne muscular dystrophy, part 2: respiratory, cardiac, bone health, and orthopaedic management. *Lancet Neurol* 2018; **17**: 347-361 [PMID: 29395990 DOI: 10.1016/S1474-4422(18)30025-5]
 - 13 **Finkel RS**, Mercuri E, Meyer OH, Simonds AK, Schroth MK, Graham RJ, Kirschner J, Iannaccone ST, Crawford TO, Woods S, Muntoni F, Wirth B, Montes J, Main M, Mazzone ES, Vitale M, Snyder B, Quijano-Roy S, Bertini E, Davis RH, Qian Y, Sejersen T; SMA Care group. Diagnosis and management of spinal muscular atrophy: Part 2: Pulmonary and acute care; medications, supplements and immunizations; other organ systems; and ethics. *Neuromuscul Disord* 2018; **28**: 197-207 [PMID: 29305137 DOI: 10.1016/j.nmd.2017.11.004]
 - 14 **Mayer OH**. Scoliosis and the impact in neuromuscular disease. *Paediatr Respir Rev* 2015; **16**: 35-42 [PMID: 25434648 DOI: 10.1016/j.prrv.2014.10.013]
 - 15 **Sedky K**, Bennett DS, Pumariega A. Prader Willi syndrome and obstructive sleep apnea: co-occurrence in the pediatric population. *J Clin Sleep Med* 2014; **10**: 403-409 [PMID: 24733986 DOI: 10.5664/jcsm.3616]
 - 16 **Vgontzas AN**, Bixler EO, Kales A, Vela-Bueno A. Prader-Willi syndrome: effects of weight loss on sleep-disordered breathing, daytime sleepiness and REM sleep disturbance. *Acta Paediatr* 1995; **84**: 813-814 [PMID: 7549304 DOI: 10.1111/j.1651-2227.1995.tb13764.x]
 - 17 **Goldstone AP**, Holland AJ, Hauffa BP, Hokken-Koelega AC, Tauber M; speakers contributors at the Second Expert Meeting of the Comprehensive Care of Patients with PWS. Recommendations for the diagnosis and management of Prader-Willi syndrome. *J Clin Endocrinol Metab* 2008; **93**: 4183-4197 [PMID: 18697869 DOI: 10.1210/jc.2008-0649]
 - 18 **McPhail GL**, Ehsan Z, Howells SA, Boesch RP, Fenchel MC, Szczesniak R, Jain V, Agabegi S, Sturm P, Wall E, Redding GJ. Obstructive lung disease in children with idiopathic scoliosis. *J Pediatr* 2015; **166**: 1018-1021 [PMID: 25684085 DOI: 10.1016/j.jpeds.2014.12.070]
 - 19 **Deal CL**, Tony M, Höybye C, Allen DB, Tauber M, Christiansen JS; 2011 Growth Hormone in Prader-Willi Syndrome Clinical Care Guidelines Workshop Participants. GrowthHormone Research Society workshop summary: consensus guidelines for recombinant human growth hormone therapy in Prader-Willi syndrome. *J Clin Endocrinol Metab* 2013; **98**: E1072-E1087 [PMID: 23543664 DOI: 10.1210/jc.2012-3888]
 - 20 **Yuan N**, Skaggs DL, Davidson Ward SL, Platzker AC, Keens TG. Preoperative polysomnograms and infant pulmonary function tests do not predict prolonged postoperative mechanical ventilation in children following scoliosis repair. *Pediatr Pulmonol* 2004; **38**: 256-260 [PMID: 15274107 DOI: 10.1002/ppul.20021]
 - 21 **Aurora RN**, Zak RS, Karippot A, Lamm CI, Morgenthaler TI, Auerbach SH, Bista SR, Casey KR, Chowdhuri S, Kristo DA, Ramar K; American Academy of Sleep Medicine. Practice parameters for the respiratory indications for polysomnography in children. *Sleep* 2011; **34**: 379-388 [PMID: 21359087 DOI: 10.1093/sleep/34.3.379]
 - 22 **McCandless SE**; Committee on Genetics. Clinical report—health supervision for children with Prader-Willi syndrome. *Pediatrics* 2011; **127**: 195-204 [PMID: 21187304 DOI: 10.1542/peds.2010-2820]



Published by **Baishideng Publishing Group Inc**
7041 Koll Center Parkway, Suite 160, Pleasanton, CA 94566, USA

Telephone: +1-925-3991568

E-mail: bpgoffice@wjgnet.com

Help Desk: <https://www.f6publishing.com/helpdesk>

<https://www.wjgnet.com>

