

# World Journal of *Clinical Cases*

*World J Clin Cases* 2021 November 16; 9(32): 9699-10051



## Contents

Thrice Monthly Volume 9 Number 32 November 16, 2021

## REVIEW

- 9699 Emerging role of long noncoding RNAs in recurrent hepatocellular carcinoma  
*Fang Y, Yang Y, Li N, Zhang XL, Huang HF*

## MINIREVIEWS

- 9711 Current treatment strategies for patients with only peritoneal cytology positive stage IV gastric cancer  
*Bausys A, Gricius Z, Aniukstyte L, Luksta M, Bickaite K, Bausys R, Strupas K*

## ORIGINAL ARTICLE

## Case Control Study

- 9722 Botulinum toxin associated with fissurectomy and anoplasty for hypertonic chronic anal fissure: A case-control study  
*D'Orazio B, Geraci G, Famà F, Terranova G, Di Vita G*
- 9731 Correlation between circulating endothelial cell level and acute respiratory distress syndrome in postoperative patients  
*Peng M, Yan QH, Gao Y, Zhang Z, Zhang Y, Wang YF, Wu HN*

## Retrospective Study

- 9741 Effects of early rehabilitation in improvement of paediatric burnt hands function  
*Zhou YQ, Zhou JY, Luo GX, Tan JL*
- 9752 Intracortical screw insertion plus limited open reduction in treating type 31A3 irreducible intertrochanteric fractures in the elderly  
*Huang XW, Hong GQ, Zuo Q, Chen Q*
- 9762 Treatment effects and periodontal status of chronic periodontitis after routine Er:YAG laser-assisted therapy  
*Gao YZ, Li Y, Chen SS, Feng B, Wang H, Wang Q*
- 9770 Risk factors for occult metastasis detected by inflammation-based prognostic scores and tumor markers in biliary tract cancer  
*Hashimoto Y, Ajiki T, Yanagimoto H, Tsugawa D, Shinozaki K, Toyama H, Kido M, Fukumoto T*
- 9783 Scapular bone grafting with allograft pin fixation for repair of bony Bankart lesions: A biomechanical study  
*Lu M, Li HP, Liu YJ, Shen XZ, Gao F, Hu B, Liu YF*
- 9792 High-resolution computed tomography findings independently predict epidermal growth factor receptor mutation status in ground-glass nodular lung adenocarcinoma  
*Zhu P, Xu XJ, Zhang MM, Fan SF*

- 9804** Colorectal cancer patients in a tertiary hospital in Indonesia: Prevalence of the younger population and associated factors

*Makmun D, Simadibrata M, Abdullah M, Syam AF, Shatri H, Fauzi A, Renaldi K, Maulahela H, Utari AP, Pribadi RR, Muzellina VN, Nursyirwan SA*

- 9815** Association between *Helicobacter pylori* infection and food-specific immunoglobulin G in Southwest China

*Liu Y, Shuai P, Liu YP, Li DY*

- 9825** Systemic immune inflammation index, ratio of lymphocytes to monocytes, lactate dehydrogenase and prognosis of diffuse large B-cell lymphoma patients

*Wu XB, Hou SL, Liu H*

### Clinical Trials Study

- 9835** Evaluating the efficacy of endoscopic sphincterotomy on biliary-type sphincter of Oddi dysfunction: A retrospective clinical trial

*Ren LK, Cai ZY, Ran X, Yang NH, Li XZ, Liu H, Wu CW, Zeng WY, Han M*

### Observational Study

- 9847** Management of pouch related symptoms in patients who underwent ileal pouch anal anastomosis surgery for adenomatous polyposis

*Gilad O, Rosner G, Brazowski E, Kariv R, Gluck N, Strul H*

- 9857** Presepsin as a biomarker for risk stratification for acute cholangitis in emergency department: A single-center study

*Zhang HY, Lu ZQ, Wang GX, Xie MR, Li CS*

### Prospective Study

- 9869** Efficacy of Yiqi Jianpi anti-cancer prescription combined with chemotherapy in patients with colorectal cancer after operation

*Li Z, Yin DF, Wang W, Zhang XW, Zhou LJ, Yang J*

### META-ANALYSIS

- 9878** Arthroplasty vs proximal femoral nails for unstable intertrochanteric femoral fractures in elderly patients: a systematic review and meta-analysis

*Chen WH, Guo WX, Gao SH, Wei QS, Li ZQ, He W*

### CASE REPORT

- 9889** Synchronous multiple primary malignancies of the esophagus, stomach, and jejunum: A case report

*Li Y, Ye LS, Hu B*

- 9896** Idiopathic acute superior mesenteric venous thrombosis after renal transplantation: A case report

*Zhang P, Li XJ, Guo RM, Hu KP, Xu SL, Liu B, Wang QL*

- 9903** Next-generation sequencing technology for diagnosis and efficacy evaluation of a patient with visceral leishmaniasis: A case report

*Lin ZN, Sun YC, Wang JP, Lai YL, Sheng LX*

- 9911** Cerebral air embolism complicating transbronchial lung biopsy: A case report  
*Herout V, Brat K, Richter S, Cundrle Jr I*
- 9917** Isolated synchronous Virchow lymph node metastasis of sigmoid cancer: A case report  
*Yang JQ, Shang L, Li LP, Jing HY, Dong KD, Jiao J, Ye CS, Ren HC, Xu QF, Huang P, Liu J*
- 9926** Clinical presentation and management of drug-induced gingival overgrowth: A case series  
*Fang L, Tan BC*
- 9935** Adult with mass burnt lime aspiration: A case report and literature review  
*Li XY, Hou HJ, Dai B, Tan W, Zhao HW*
- 9942** Massive hemothorax due to intercostal arterial bleeding after percutaneous catheter removal in a multiple-trauma patient: A case report  
*Park C, Lee J*
- 9948** Hemolymphangioma with multiple hemangiomas in liver of elderly woman with history of gynecological malignancy: A case report  
*Wang M, Liu HF, Zhang YZZ, Zou ZQ, Wu ZQ*
- 9954** Rare location and drainage pattern of right pulmonary veins and aberrant right upper lobe bronchial branch: A case report  
*Wang FQ, Zhang R, Zhang HL, Mo YH, Zheng Y, Qiu GH, Wang Y*
- 9960** Respiratory failure after scoliosis correction surgery in patients with Prader-Willi syndrome: Two case reports  
*Yoon JY, Park SH, Won YH*
- 9970** Computed tomography-guided chemical renal sympathetic nerve modulation in the treatment of resistant hypertension: A case report  
*Luo G, Zhu JJ, Yao M, Xie KY*
- 9977** Large focal nodular hyperplasia is unresponsive to arterial embolization: A case report  
*Ren H, Gao YJ, Ma XM, Zhou ST*
- 9982** Fine-needle aspiration cytology of an intrathyroidal nodule diagnosed as squamous cell carcinoma: A case report  
*Yu JY, Zhang Y, Wang Z*
- 9990** Extensive abdominal lymphangiomatosis involving the small bowel mesentery: A case report  
*Alhasan AS, Daqqaq TS*
- 9997** Gastrointestinal symptoms as the first sign of chronic granulomatous disease in a neonate: A case report  
*Meng EY, Wang ZM, Lei B, Shang LH*
- 10006** Screw penetration of the iliopsoas muscle causing late-onset pain after total hip arthroplasty: A case report  
*Park HS, Lee SH, Cho HM, Choi HB, Jo S*

- 10013** Uretero-lumbar artery fistula: A case report  
*Chen JJ, Wang J, Zheng QG, Sun ZH, Li JC, Xu ZL, Huang XJ*
- 10018** Rare mutation in *MKRN3* in two twin sisters with central precocious puberty: Two case reports  
*Jiang LQ, Zhou YQ, Yuan K, Zhu JF, Fang YL, Wang CL*
- 10024** Primary mucosal-associated lymphoid tissue extranodal marginal zone lymphoma of the bladder from an imaging perspective: A case report  
*Jiang ZZ, Zheng YY, Hou CL, Liu XT*
- 10033** Focal intramural hematoma as a potential pitfall for iatrogenic aortic dissection during subclavian artery stenting: A case report  
*Zhang Y, Wang JW, Jin G, Liang B, Li X, Yang YT, Zhan QL*
- 10040** Ventricular tachycardia originating from the His bundle: A case report  
*Zhang LY, Dong SJ, Yu HJ, Chu YJ*
- 10046** Posthepatectomy jaundice induced by paroxysmal nocturnal hemoglobinuria: A case report  
*Liang HY, Xie XD, Jing GX, Wang M, Yu Y, Cui JF*

**ABOUT COVER**

Editorial Board Member of *World Journal of Clinical Cases*, Jalaj Garg, FACC, MD, Academic Research, Assistant Professor, Division of Cardiology, Medical College of Wisconsin, Milwaukee, WI 53226, United States.  
garg.jalaj@yahoo.com

**AIMS AND SCOPE**

The primary aim of *World Journal of Clinical Cases* (WJCC, *World J Clin Cases*) is to provide scholars and readers from various fields of clinical medicine with a platform to publish high-quality clinical research articles and communicate their research findings online.

WJCC mainly publishes articles reporting research results and findings obtained in the field of clinical medicine and covering a wide range of topics, including case control studies, retrospective cohort studies, retrospective studies, clinical trials studies, observational studies, prospective studies, randomized controlled trials, randomized clinical trials, systematic reviews, meta-analysis, and case reports.

**INDEXING/ABSTRACTING**

The WJCC is now indexed in Science Citation Index Expanded (also known as SciSearch®), Journal Citation Reports/Science Edition, Scopus, PubMed, and PubMed Central. The 2021 Edition of Journal Citation Reports® cites the 2020 impact factor (IF) for WJCC as 1.337; IF without journal self cites: 1.301; 5-year IF: 1.742; Journal Citation Indicator: 0.33; Ranking: 119 among 169 journals in medicine, general and internal; and Quartile category: Q3. The WJCC's CiteScore for 2020 is 0.8 and Scopus CiteScore rank 2020: General Medicine is 493/793.

**RESPONSIBLE EDITORS FOR THIS ISSUE**

Production Editor: Jia-Hui Li; Production Department Director: Yu-Jie Ma; Editorial Office Director: Jin-Lei Wang.

**NAME OF JOURNAL**

*World Journal of Clinical Cases*

**ISSN**

ISSN 2307-8960 (online)

**LAUNCH DATE**

April 16, 2013

**FREQUENCY**

Thrice Monthly

**EDITORS-IN-CHIEF**

Dennis A Bloomfield, Sandro Vento, Bao-Gan Peng

**EDITORIAL BOARD MEMBERS**

<https://www.wjnet.com/2307-8960/editorialboard.htm>

**PUBLICATION DATE**

November 16, 2021

**COPYRIGHT**

© 2021 Baishideng Publishing Group Inc

**INSTRUCTIONS TO AUTHORS**

<https://www.wjnet.com/bpg/gerinfo/204>

**GUIDELINES FOR ETHICS DOCUMENTS**

<https://www.wjnet.com/bpg/GerInfo/287>

**GUIDELINES FOR NON-NATIVE SPEAKERS OF ENGLISH**

<https://www.wjnet.com/bpg/gerinfo/240>

**PUBLICATION ETHICS**

<https://www.wjnet.com/bpg/GerInfo/288>

**PUBLICATION MISCONDUCT**

<https://www.wjnet.com/bpg/gerinfo/208>

**ARTICLE PROCESSING CHARGE**

<https://www.wjnet.com/bpg/gerinfo/242>

**STEPS FOR SUBMITTING MANUSCRIPTS**

<https://www.wjnet.com/bpg/GerInfo/239>

**ONLINE SUBMISSION**

<https://www.f6publishing.com>





## Extensive abdominal lymphangiomatosis involving the small bowel mesentery: A case report

Ayman S Alhasan, Tareef S Daqqaq

**ORCID number:** Ayman S Alhasan 0000-0001-8879-4017; Tareef S Daqqaq 0000-0002-1479-0897.

**Author contributions:** Alhasan AS reviewed the literature, performed the radiological interpretation, and wrote the manuscript; Daqqaq TS prepared the figures and contributed to manuscript drafting; All authors read and approved the final manuscript.

**Informed consent statement:** A written consent for publication was obtained from the patient for all potentially identifiable clinical data and accompanying images.

**Conflict-of-interest statement:** The authors declare that they have no competing interests.

**CARE Checklist (2016) statement:** The authors have read the CARE Checklist (2016), and the manuscript was prepared and revised according to the CARE Checklist (2016).

**Country/Territory of origin:** Saudi Arabia

**Specialty type:** Medicine, research and experimental

**Peer-review report's scientific quality classification**

Grade A (Excellent): 0

Grade B (Very good): 0

**Ayman S Alhasan, Tareef S Daqqaq**, Department of Radiology and Medical Imaging, College of Medicine Taibah University, Madinah 42353, Saudi Arabia

**Corresponding author:** Ayman S Alhasan, MD, Assistant Professor, Department of Radiology and Medical Imaging, College of Medicine Taibah University, Universities Road, Madinah 42353, Saudi Arabia. [ahasan@taibahu.edu.sa](mailto:ahasan@taibahu.edu.sa)

### Abstract

#### BACKGROUND

Abdominal lymphangiomatosis is a rare benign condition accounting for less than 1% of all the cases of lymphangiomatosis. Management usually involves radical surgical excision; however, depending upon the extent of involvement, patient condition, and absence of complications, conservative management can be also considered.

#### CASE SUMMARY

We present the case of a 32-year-old male who presented with short onset abdominal pain and melena. Physical examination findings were within normal limits, except for left lower abdominal tenderness. Upper gastrointestinal endoscopy was within normal limits. Abdominal and pelvic ultrasound and computed tomography (CT) scan revealed numerous, variably-sized cystic lesions within the abdominal cavity, exclusively and extensively affecting the small bowel mesentery with sparing of the retroperitoneum. The diagnosis was confirmed by CT and cytological examination. Radical surgical excision was technically impossible in this patient because of the extensive involvement of the mesentery; therefore, the patient was managed conservatively.

#### CONCLUSION

Extensive and exclusive small bowel mesentery involvement in abdominal lymphangiomatosis is rare. Imaging modalities play an important role in establishing the diagnosis and conservative management can be considered when surgery is technically impossible.

**Key Words:** Abdominal lymphangiomatosis; Mesentery; Melena; Computed tomography scan; Case report

©The Author(s) 2021. Published by Baishideng Publishing Group Inc. All rights reserved.

Grade C (Good): C, C

Grade D (Fair): 0

Grade E (Poor): 0

**Open-Access:** This article is an open-access article that was selected by an in-house editor and fully peer-reviewed by external reviewers. It is distributed in accordance with the Creative Commons Attribution NonCommercial (CC BY-NC 4.0) license, which permits others to distribute, remix, adapt, build upon this work non-commercially, and license their derivative works on different terms, provided the original work is properly cited and the use is non-commercial. See: <http://creativecommons.org/licenses/by-nc/4.0/>

**Received:** June 26, 2021**Peer-review started:** June 26, 2021**First decision:** July 14, 2021**Revised:** July 16, 2021**Accepted:** July 29, 2021**Article in press:** July 29, 2021**Published online:** November 16, 2021**P-Reviewer:** Wang XJ, Yi XL**S-Editor:** Yan JP**L-Editor:** Filipodia**P-Editor:** Wang LYT

**Core Tip:** Abdominal lymphangiomas are rare, accounting for less than 1% of all cases of lymphangiomas. The retroperitoneum is the typical site affected in abdominal lymphangiomas. Other than the retroperitoneum, the mesentery and omentum can also be affected. Here, we report a case of extensive mesenteric lymphangiomas without retroperitoneal involvement. Surgical excision was technically impossible in our case due to the extensive and exclusive involvement of the small bowel mesentery and the patient was managed conservatively.

**Citation:** Alhasan AS, Daqqaq TS. Extensive abdominal lymphangiomas involving the small bowel mesentery: A case report. *World J Clin Cases* 2021; 9(32): 9990-9996

**URL:** <https://www.wjgnet.com/2307-8960/full/v9/i32/9990.htm>

**DOI:** <https://dx.doi.org/10.12998/wjcc.v9.i32.9990>

## INTRODUCTION

Lymphangiomas are a rare benign condition that affects the lymphatic system[1,2]. Usually, younger children are affected by this condition; however, in rare cases, adults can also be diagnosed with lymphangiomas. The exact etiology of lymphangiomas has not been fully established; however, since children are more commonly affected, it is postulated that lymphangiomas could be a congenital disease[3]. In some cases, certain secondary underlying conditions, such as a history of abdominal trauma, surgery, radiation, or underlying obstruction of the lymphatic ducts owing to inflammation or infection, can precipitate lymphangiomas[4]. Lymphangiomas can occur anywhere in the body except for the brain, as it lacks the lymphatic system [5]. Approximately 95% of lesions occur in the neck and axillary regions, whereas the remaining 5% can arise elsewhere[6]. Herein, we report a rare case of extensive cystic lymphangiomas exclusively involving the small bowel mesentery without involvement of the retroperitoneum in a 32-year-old male. We also highlight the importance of imaging modalities and present a review of literature on this entity.

## CASE PRESENTATION

### Chief complaints

A male patient aged 32 years presented with mild dull diffuse abdominal pain and two episodes of melena.

### History of present illness

The symptoms started 1 wk prior to presentation, with recurrent abdominal pain and two episodes of melena.

### History of past illness

The patient had no significant prior medical or surgical history.

### Personal and family history

The patient had no family history that was related to the present illness.

### Physical examination

General examination findings were within normal limits. Vital signs were also normal. Abdominal examination revealed mild to moderate abdominal distension with mild left lower quadrant tenderness.

### Laboratory examinations

Complete blood count and coagulation profile were within normal limits. The serum creatinine level was 0.91 mg/dL, liver and cholestasis parameters were unremarkable, and albumin level was 4.1 g/dL.



### Imaging examinations

Abdominal radiography did not show air-fluid levels or free air. Abdominal ultrasound reported the presence of multiple anechoic cystic lesions within the abdominal cavity. Some of the cystic lesions at the left lower quadrant showed low level internal echoes. An abdominal computed tomography (CT) scan revealed numerous confluent cystic lesions of variable size showing fluid density 0-10 Hounsfield units (HU) with no enhancing walls (Figure 1). The lesions were extensive, involving the small bowel mesentery and encasing the mesenteric vessels. The largest lesions were seen peripherally, while the smaller lesions were more central in location. The largest lesion measured approximately 4.6 cm at its longest axis. No enhancement was seen within these lesions on post-contrast CT images. The jejunal loops were displaced superiorly and to the left side, while the ileal loops were displaced inferiorly and towards the right side. Despite the mass effect on the small bowel loops, there were no signs of intestinal or colonic obstruction. A few small, round calcifications were present within these lesions (Figure 2). No cystic lesions were seen within the mesocolon, retroperitoneum, gastro-hepatic, peri-gastric, or peri-splenic spaces. No lung, mediastinal, liver, kidney or bone lesions were seen. At the left lower quadrant of the abdomen, some of the lesions showed intra-cystic hemorrhage with a spontaneous density of 53 HU. (Figure 3).

### Further diagnostic work-up

Upper gastrointestinal (GI) endoscopy was performed and revealed no significant abnormality. Ultrasound-guided fine needle aspiration obtained from one of the large cystic lesions was performed with no subsequent adverse events. Gross examination showed clear fluid. Cytology revealed few mature lymphocytes and was negative for chyle. The culture was also negative. Flow cytometry showed few B and T lymphocytes.

---

## FINAL DIAGNOSIS

The final diagnosis of the present case was extensive and exclusive mesenteric cystic lymphangiomatosis.

---

## TREATMENT

The patient received symptomatic treatment with 1 g of oral paracetamol three times per day for 1 wk. Radical surgical excision was technically impossible in our case due to the extensive involvement of the small bowel mesentery.

---

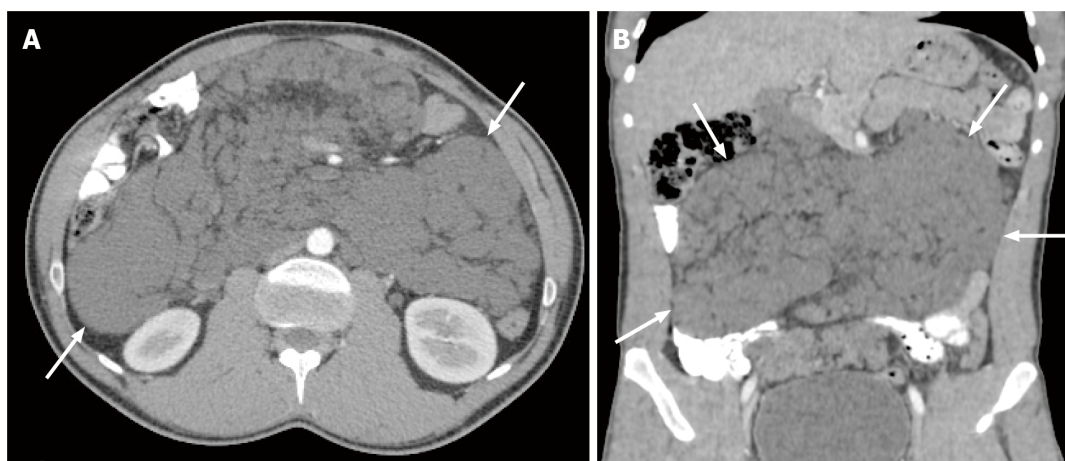
## OUTCOME AND FOLLOW-UP

The patient reported no pain after 1 wk of using oral paracetamol three times per day and was asymptomatic during short-term follow-up.

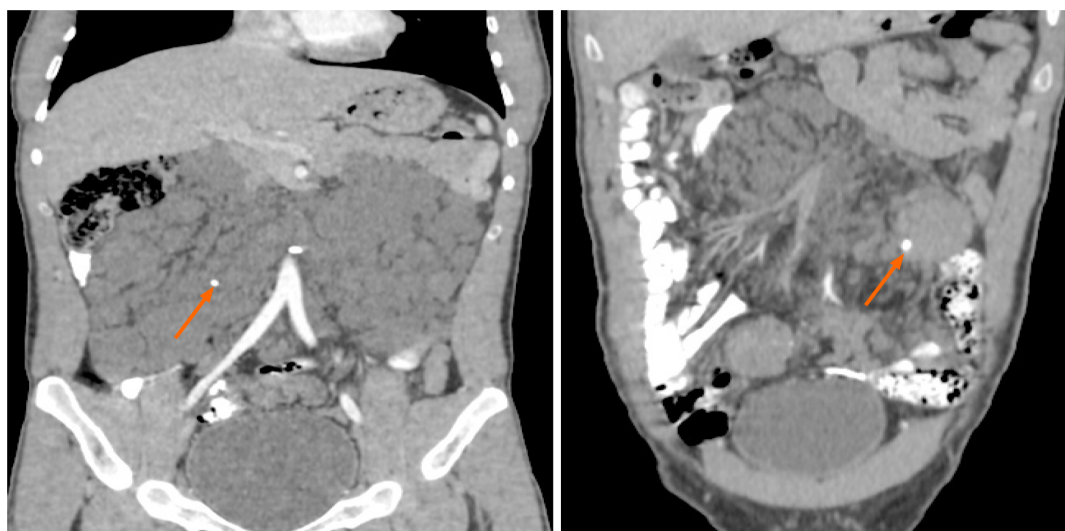
---

## DISCUSSION

Lymphangiomatosis is a rare benign disease characterized by proliferative lymphatic malformations. The lesions are composed of spaces lined with endothelium and encompassed connective tissue stroma composed of lymphatic tissue, smooth muscle, and round cells[1]. In most cases, the disease is diagnosed during the initial 2 years of life and the disease is rarely diagnosed after reaching adulthood[1,3]. The disease is not familial and does not depend on patient gender[2]. Abdominal lymphangiomatosis is very rare, representing less than 1% of all lymphangiomatosis cases. The retroperitoneum is the typical site affected in abdominal lymphangiomatosis. Other than the retroperitoneum, the mesentery and omentum can also be affected[7]. In our case, the patient had extensive involvement of the small bowel mesentery with no involvement of the retroperitoneum.



**Figure 1** Computed tomography image of confluent peritoneal cystic lesions. A: Post-contrast axial; B: Coronal computed tomography scan reveals numerous confluent peritoneal cystic lesions (white arrows) of variable sizes extensively involving the small bowel mesentery and responsible for peripheral displacement of the small bowel loops. No retro-peritoneal lesions are seen.

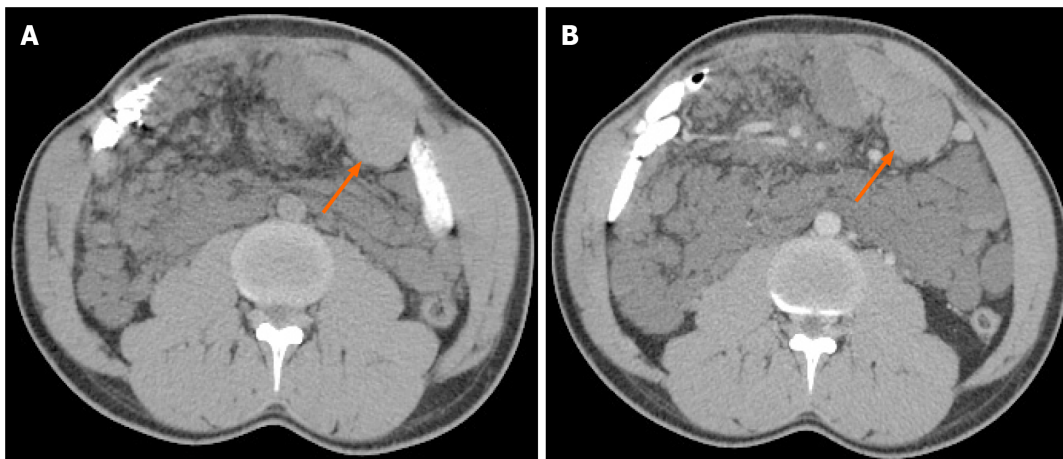


**Figure 2** Post-contrast-enhanced coronal computed tomography scan revealed two small calcifications (orange arrows) within some of the lesions.

There are no specific signs or symptoms for abdominal lymphangiomatosis. Also, there are no specific laboratory diagnostic tests to confirm the disease. Although nonspecific palpable abdominal mass, pain, or abdominal distensions could be presenting features, different patients might present with different sets of symptoms and signs. In most cases, the lesions are usually fluid-filled sacs, and incidental diagnosis is made after imaging study of the abdomen, such as ultrasound or CT. Some of the patients might present with acute abdomen, GI bleeding in the form of melena or hematemesis, intestinal obstruction, or even bowel perforation in severe cases[8,9]. Rarely, life-threatening complications might arise, such as rupture, torsion of the cyst, volvulus, or severe GI bleeding leading to shock[9].

Literature search revealed only a few cases of abdominal lymphangiomatosis in adult patients presenting with GI bleeding[1,10,11]. Our case described a male patient aged 32 years, without any significant prior medical or surgical history, with complaints of mild, dull, diffuse abdominal pain, and two episodes of melena for 1 wk. An existing hypothesis suggests that trauma can precipitate GI bleeding, due to hemorrhage in these cystic lymphatic lesions. The bleeding in these cystic lymphatic lesions can result in the development of an abnormal venolymphatic communication or hemangioma within the lesion[7,12].

Radiological investigations play an important role in the diagnosis of abdominal lymphangiomatosis. Although plain abdominal X-ray cannot diagnose abdominal lymphangiomatosis, it can be useful in the diagnosis of complications, such as



**Figure 3 Computed tomography image of intra-cystic hemorrhage.** A: Non-enhanced axial computed tomography scan of the abdomen shows hemorrhage within one of the cystic lesions (orange arrow) located at the left lower quadrant with a spontaneous density of 53 Hounsfield units; B: Portal-venous phase axial contrast-enhanced image at the same level shows no internal enhancement within the lesion after administration of intravenous contrast.

intestinal obstruction or displacement of bowel loops owing to the mass effect of the cystic lesions. Ultrasonography typically demonstrates purely anechoic cystic lesions or lesions with low level internal echoes if complicated by internal bleeding or infection. CT can provide additional details, such as size, specific anatomical location, extent of organs affected, and presence or absence of complications (*i.e.* hemorrhage or infection), and allows differentiation from other pathologies, such as complicated ascites. CT scans usually reveal uni- or multi-locular low density cysts with no perceptible wall, as in our case. The lesions usually contain fluid or chyle with a density ranging from  $-10$  HU to  $0$  HU. If internal bleeding occurs, density might increase, as demonstrated in our case. In some rare cases, calcification might also be present, as also shown in our case[13]. Magnetic resonance imaging is another important diagnostic tool. Cystic lesions typically have low signal intensity on T1-weighted imaging and high signal intensity on T2-weighted imaging. Cysts containing high chyle might present with high signal intensity on T1-weighted images and moderate signal intensity on T2 weighted images[14].

Although typical radiological findings, in combination with cytological examination might be sufficient to establish a diagnosis, histopathological and/or immunohistochemical examinations could be helpful. The cell lining of the cystic lesions in abdominal lymphangiomas are immunologically reactive to cytokeratin and does not show positive reaction for factor VIII. The most reliable method of demonstrating the endothelium in lymphangiomas is positive staining with CD31 and Prox1[7,15].

Radical excision of the abdominal cystic lesions is considered an ideal treatment option by some authors, even if diagnosed incidentally in asymptomatic patients due to the risk of complications, such as intestinal obstructions[9]. In this case, radical surgical excision was technically impossible due to the extensive involvement of the mesentery. Regarding radical excision of the cystic lesions, some authors, such as Kochman *et al*[16], have reported that radical surgical excision should be avoided, especially in asymptomatic patients without any complications. Other authors have suggested other treatment options, such as marsupialization, percutaneous drainage of the cystic lesions, intra-cystic injection of biological response modifiers and sclerotherapy agents[17,18].

Abdominal lymphangiomas is quite rare and the evidence regarding the ideal choice of treatment is meager. The treatment options should take in consideration individual patient status, such as symptoms, number, size and location of the lesions, presence of complications, and risk of future complications. Our patient was managed symptomatically, as radical surgical excision was not feasible because of extensive involvement of the mesentery. In addition, there were no signs of intestinal obstruction or other complications. The patient reported a good response to self-prescribed oral paracetamol to control the pain. Paracetamol has been traditionally considered a safer alternative to non-steroidal anti-inflammatory drugs. As a result, the treating physician advised the patient to continue with the recommended dose of paracetamol for 1 wk. The patient did not receive any other treatment. The patient's melena and abdominal pain subsided eventually, and no further treatment was offered as the patient became asymptomatic. Among the few cases of abdominal

lymphangiomas reported in the literature, abdominal pain, anemia, protein-losing enteropathy, and GI bleeding were the most common presenting symptoms. However, one patient presented with symptoms of intestinal (ileal) perforation. Chan *et al* [12] presented a case of lymphangiomas involving both the mesentery and retroperitoneum in a male patient aged 51 years with melena, whom they managed conservatively. Surgical laparotomy was subsequently performed to obtain tissue for histopathologic examination.

## CONCLUSION

In conclusion, extensive and exclusive small bowel mesentery involvement in abdominal lymphangiomas is rare. Imaging modalities, especially CT scans, play an important role in the diagnosis. Conservative management can be considered when surgery is technically impossible.

## REFERENCES

- 1 **Lin RY**, Zou H, Chen TZ, Wu W, Wang JH, Chen XL, Han QX. Abdominal lymphangiomas in a 38-year-old female: case report and literature review. *World J Gastroenterol* 2014; **20**: 8320-8324 [PMID: 25009412 DOI: 10.3748/wjg.v20.i25.8320]
- 2 **Alqahtani A**, Nguyen LT, Flageole H, Shaw K, Laberge JM. 25 years' experience with lymphangiomas in children. *J Pediatr Surg* 1999; **34**: 1164-1168 [PMID: 10442614 DOI: 10.1016/s0022-3468(99)90590-0]
- 3 **Hanagiri T**, Baba M, Shimabukuro T, Hashimoto M, Takemoto H, Inoue A, Sugitani A, Shirakusa T. Lymphangioma in the small intestine: report of a case and review of the Japanese literature. *Surg Today* 1992; **22**: 363-367 [PMID: 1392347 DOI: 10.1007/bf00308747]
- 4 **Suthiwartnarueput W**, Kiatipunsodsai S, Kwankua A, Chaumrattanakul U. Lymphangioma of the small bowel mesentery: a case report and review of the literature. *World J Gastroenterol* 2012; **18**: 6328-6332 [PMID: 23180956 DOI: 10.3748/wjg.v18.i43.6328]
- 5 **Stopinski J**, Stephan S, Staib I. [Intra-abdominal cystic lymphangioma and mesenteric cysts as a cause of abdominal discomfort]. *Langenbecks Arch Chir* 1994; **379**: 182-187 [PMID: 8052061 DOI: 10.1007/bf00680116]
- 6 **Roisman I**, Manny J, Fields S, Shiloni E. Intra-abdominal lymphangioma. *Br J Surg* 1989; **76**: 485-489 [PMID: 2660949 DOI: 10.1002/bjs.1800760519]
- 7 **Apra G**, Guida F, Canfora A, Ferronetti A, Giugliano A, Ciciriello MB, Savanelli A, Amato B. Mesenteric cystic lymphangioma in adult: a case series and review of the literature. *BMC Surg* 2013; **13**: A4 [DOI: 10.1186/1471-2482-13-S1-A4]
- 8 **Giuliani A**, Romano L, Coletti G, Walid A, Fatayer M, Calvisi G, Maffione F, Muolo C, Vicentini V, Schietroma M, Carlei F. Lymphangiomas of the ileum with perforation: A case report and review of the literature. *Ann Med Surg (Lond)* 2019; **41**: 6-10 [PMID: 30992989 DOI: 10.1016/j.amsu.2019.03.010]
- 9 **Jang JH**, Lee SL, Ku YM, An CH, Chang ED. Small bowel volvulus induced by mesenteric lymphangioma in an adult: a case report. *Korean J Radiol* 2009; **10**: 319-322 [PMID: 19412523 DOI: 10.3348/kjr.2009.10.3.319]
- 10 **Amadori G**, Micciolo R, Poletti A. A case of intra-abdominal multiple lymphangiomas in an adult in whom the immunological evaluation supported the diagnosis. *Eur J Gastroenterol Hepatol* 1999; **11**: 347-351 [PMID: 10333211 DOI: 10.1097/00042737-199903000-00022]
- 11 **Takami A**, Nakao S, Sugimori N, Ishida F, Yamazaki M, Nakatsumi Y, Saito M, Otake S, Nakamura S, Matsuda T. Management of disseminated intra-abdominal lymphangiomas with protein-losing enteropathy and intestinal bleeding. *South Med J* 1995; **88**: 1156-1158 [PMID: 7481991 DOI: 10.1097/00007611-199511000-00016]
- 12 **Chan WYS**, Kwan KEL, Teo LT. A rare case of retroperitoneal and mesenteric lymphangiomas. *Radiol Case Rep* 2020; **15**: 11-14 [PMID: 31762861 DOI: 10.1016/j.radcr.2019.09.039]
- 13 **Cuttillo DP**, Swayne LC, Cucco J, Dougan H. CT and MR imaging in cystic abdominal lymphangiomas. *J Comput Assist Tomogr* 1989; **13**: 534-536 [PMID: 2656785 DOI: 10.1097/00004728-198905000-00038]
- 14 **Rajiah P**, Sinha R, Cuevas C, Dubinsky TJ, Bush WH Jr, Kolokythas O. Imaging of uncommon retroperitoneal masses. *Radiographics* 2011; **31**: 949-976 [PMID: 21768233 DOI: 10.1148/rg.314095132]
- 15 **Hornick JL**, Fletcher CD. Intraabdominal cystic lymphangiomas obscured by marked superimposed reactive changes: clinicopathological analysis of a series. *Hum Pathol* 2005; **36**: 426-432 [PMID: 15892005 DOI: 10.1016/j.humpath.2005.02.007]
- 16 **Kochman ML**, Wiersema MJ, Hawes RH, Canal D, Wiersema L. Preoperative diagnosis of cystic lymphangioma of the colon by endoscopic ultrasound. *Gastrointest Endosc* 1997; **45**: 204-206 [PMID: 9041015 DOI: 10.1016/s0016-5107(97)70253-0]

- 17 **Grunewald TGP**, Damke L, Maschan M, Petrova U, Surianinova O, Esipenko A, Kononov D, Behrends U, Schiessl J, Wörtler K, Burdach S, von Luetichau I. First report of effective and feasible treatment of multifocal lymphangiomatosis (Gorham-Stout) with bevacizumab in a child. *Ann Oncol* 2010; **21**: 1733-1734 [PMID: [20605931](#) DOI: [10.1093/annonc/mdq331](#)]
- 18 **Rostom AY**. Treatment of thoracic lymphangiomatosis. *Arch Dis Child* 2000; **83**: 138-139 [PMID: [10906021](#) DOI: [10.1136/adc.83.2.138](#)]



Published by **Baishideng Publishing Group Inc**  
7041 Koll Center Parkway, Suite 160, Pleasanton, CA 94566, USA

**Telephone:** +1-925-3991568

**E-mail:** [bpgoffice@wjgnet.com](mailto:bpgoffice@wjgnet.com)

**Help Desk:** <https://www.f6publishing.com/helpdesk>

<https://www.wjgnet.com>

