

World Journal of *Clinical Cases*

World J Clin Cases 2021 December 6; 9(34): 10392-10745



Contents

Thrice Monthly Volume 9 Number 34 December 6, 2021

OPINION REVIEW

- 10392** Regulating monocyte infiltration and differentiation: Providing new therapies for colorectal cancer patients with COVID-19

Bai L, Yang W, Qian L, Cui JW

REVIEW

- 10400** Role of circular RNAs in gastrointestinal tumors and drug resistance

Xi SJ, Cai WQ, Wang QQ, Peng XC

MINIREVIEWS

- 10418** Liver injury associated with acute pancreatitis: The current status of clinical evaluation and involved mechanisms

Liu W, Du JJ, Li ZH, Zhang XY, Zuo HD

- 10430** Association between celiac disease and vitiligo: A review of the literature

Zhang JZ, Abudoureyimu D, Wang M, Yu SR, Kang XJ

- 10438** Role of immune escape in different digestive tumours

Du XZ, Wen B, Liu L, Wei YT, Zhao K

ORIGINAL ARTICLE

Basic Study

- 10451** Magnolol protects against acute gastrointestinal injury in sepsis by down-regulating regulated on activation, normal T-cell expressed and secreted

Mao SH, Feng DD, Wang X, Zhi YH, Lei S, Xing X, Jiang RL, Wu JN

Case Control Study

- 10464** Effect of Nephritis Rehabilitation Tablets combined with tacrolimus in treatment of idiopathic membranous nephropathy

Ly W, Wang MR, Zhang CZ, Sun XX, Yan ZZ, Hu XM, Wang TT

Retrospective Cohort Study

- 10472** Lamb's tripe extract and vitamin B₁₂ capsule plus celecoxib reverses intestinal metaplasia and atrophy: A retrospective cohort study

Wu SR, Liu J, Zhang LF, Wang N, Zhang LY, Wu Q, Liu JY, Shi YQ

- 10484** Clinical features and survival of patients with multiple primary malignancies

Wang XK, Zhou MH

Retrospective Study

- 10494** Thoracoscopic segmentectomy and lobectomy assisted by three-dimensional computed-tomography bronchography and angiography for the treatment of primary lung cancer
Wu YJ, Shi QT, Zhang Y, Wang YL
- 10507** Endoscopic ultrasound fine needle aspiration *vs* fine needle biopsy in solid lesions: A multi-center analysis
Moura DTH, McCarty TR, Jirapinyo P, Ribeiro IB, Farias GFA, Madruga-Neto AC, Ryou M, Thompson CC
- 10518** Resection of bilateral occipital lobe lesions during a single operation as a treatment for bilateral occipital lobe epilepsy
Lyu YE, Xu XF, Dai S, Feng M, Shen SP, Zhang GZ, Ju HY, Wang Y, Dong XB, Xu B
- 10530** Improving rehabilitation and quality of life after percutaneous transhepatic cholangiography drainage with a rapid rehabilitation model
Xia LL, Su T, Li Y, Mao JF, Zhang QH, Liu YY
- 10540** Combined lumbar muscle block and perioperative comprehensive patient-controlled intravenous analgesia with butorphanol in gynecological endoscopic surgery
Zhu RY, Xiang SQ, Chen DR
- 10549** Teicoplanin combined with conventional vancomycin therapy for the treatment of pulmonary methicillin-resistant *Staphylococcus aureus* and *Staphylococcus epidermidis* infections
Wu W, Liu M, Geng JJ, Wang M
- 10557** Application of narrative nursing in the families of children with biliary atresia: A retrospective study
Zhang LH, Meng HY, Wang R, Zhang YC, Sun J

Observational Study

- 10566** Comparative study for predictability of type 1 gastric variceal rebleeding after endoscopic variceal ligation: High-frequency intraluminal ultrasound study
Kim JH, Choe WH, Lee SY, Kwon SY, Sung IK, Park HS
- 10576** Effects of WeChat platform-based health management on health and self-management effectiveness of patients with severe chronic heart failure
Wang ZR, Zhou JW, Liu XP, Cai GJ, Zhang QH, Mao JF
- 10585** Early cardiopulmonary resuscitation on serum levels of myeloperoxidase, soluble ST2, and hypersensitive C-reactive protein in acute myocardial infarction patients
Hou M, Ren YP, Wang R, Lu LX

Prospective Study

- 10595** Remimazolam benzenesulfonate anesthesia effectiveness in cardiac surgery patients under general anesthesia
Tang F, Yi JM, Gong HY, Lu ZY, Chen J, Fang B, Chen C, Liu ZY

Randomized Clinical Trial

- 10604** Effects of lower body positive pressure treadmill on functional improvement in knee osteoarthritis: A randomized clinical trial study
Chen HX, Zhan YX, Ou HN, You YY, Li WY, Jiang SS, Zheng MF, Zhang LZ, Chen K, Chen QX

SYSTEMATIC REVIEWS

- 10616** Effects of hypoxia on bone metabolism and anemia in patients with chronic kidney disease
Kan C, Lu X, Zhang R

META-ANALYSIS

- 10626** Intracuff alkalinized lidocaine to prevent postoperative airway complications: A meta-analysis
Chen ZX, Shi Z, Wang B, Zhang Y

CASE REPORT

- 10638** Rarely fast progressive memory loss diagnosed as Creutzfeldt-Jakob disease: A case report
Xu YW, Wang JQ, Zhang W, Xu SC, Li YX
- 10645** Diagnosis, fetal risk and treatment of pemphigoid gestationis in pregnancy: A case report
Jiao HN, Ruan YP, Liu Y, Pan M, Zhong HP
- 10652** Histology transformation-mediated pathological atypism in small-cell lung cancer within the presence of chemotherapy: A case report
Ju Q, Wu YT, Zhang Y, Yang WH, Zhao CL, Zhang J
- 10659** Reversible congestive heart failure associated with hypocalcemia: A case report
Wang C, Dou LW, Wang TB, Guo Y
- 10666** Excimer laser coronary atherectomy for a severe calcified coronary ostium lesion: A case report
Hou FJ, Ma XT, Zhou YJ, Guan J
- 10671** Comprehensive management of malocclusion in maxillary fibrous dysplasia: A case report
Kaur H, Mohanty S, Kochhar GK, Iqbal S, Verma A, Bhasin R, Kochhar AS
- 10681** Intravascular papillary endothelial hyperplasia as a rare cause of cervicothoracic spinal cord compression: A case report
Gu HL, Zheng XQ, Zhan SQ, Chang YB
- 10689** Proximal true lumen collapse in a chronic type B aortic dissection patient: A case report
Zhang L, Guan WK, Wu HP, Li X, Lv KP, Zeng CL, Song HH, Ye QL
- 10696** Tigecycline sclerotherapy for recurrent pseudotumor in aseptic lymphocyte-dominant vasculitis-associated lesion after metal-on-metal total hip arthroplasty: A case report
Lin IH, Tsai CH

- 10702** Acute myocardial infarction induced by eosinophilic granulomatosis with polyangiitis: A case report
Jiang XD, Guo S, Zhang WM
- 10708** Aggressive natural killer cell leukemia with skin manifestation associated with hemophagocytic lymphohistiocytosis: A case report
Peng XH, Zhang LS, Li LJ, Guo XJ, Liu Y
- 10715** Chronic lymphocytic leukemia/small lymphocytic lymphoma complicated with skin Langerhans cell sarcoma: A case report
Li SY, Wang Y, Wang LH
- 10723** Severe mediastinitis and pericarditis after endobronchial ultrasound-guided transbronchial needle aspiration: A case report
Koh JS, Kim YJ, Kang DH, Lee JE, Lee SI
- 10728** Obturator hernia - a rare etiology of lateral thigh pain: A case report
Kim JY, Chang MC
- 10733** Tracheal tube misplacement in the thoracic cavity: A case report
Li KX, Luo YT, Zhou L, Huang JP, Liang P
- 10738** Peri-implant keratinized gingiva augmentation using xenogeneic collagen matrix and platelet-rich fibrin: A case report
Han CY, Wang DZ, Bai JF, Zhao LL, Song WZ

ABOUT COVER

Editorial Board Member of *World Journal of Clinical Cases*, Gagan Mathur, MBBS, MD, Associate Professor, Director, Staff Physician, Department of Pathology, Saint Luke's Health System, Kansas City, MO 64112, United States. gmathur@saint-lukes.org

AIMS AND SCOPE

The primary aim of *World Journal of Clinical Cases* (WJCC, *World J Clin Cases*) is to provide scholars and readers from various fields of clinical medicine with a platform to publish high-quality clinical research articles and communicate their research findings online.

WJCC mainly publishes articles reporting research results and findings obtained in the field of clinical medicine and covering a wide range of topics, including case control studies, retrospective cohort studies, retrospective studies, clinical trials studies, observational studies, prospective studies, randomized controlled trials, randomized clinical trials, systematic reviews, meta-analysis, and case reports.

INDEXING/ABSTRACTING

The WJCC is now indexed in Science Citation Index Expanded (also known as SciSearch®), Journal Citation Reports/Science Edition, Scopus, PubMed, and PubMed Central. The 2021 Edition of Journal Citation Reports® cites the 2020 impact factor (IF) for WJCC as 1.337; IF without journal self cites: 1.301; 5-year IF: 1.742; Journal Citation Indicator: 0.33; Ranking: 119 among 169 journals in medicine, general and internal; and Quartile category: Q3. The WJCC's CiteScore for 2020 is 0.8 and Scopus CiteScore rank 2020: General Medicine is 493/793.

RESPONSIBLE EDITORS FOR THIS ISSUE

Production Editor: Yan-Xia Xing; Production Department Director: Yun-Jie Ma; Editorial Office Director: Jin-Lei Wang.

NAME OF JOURNAL

World Journal of Clinical Cases

ISSN

ISSN 2307-8960 (online)

LAUNCH DATE

April 16, 2013

FREQUENCY

Thrice Monthly

EDITORS-IN-CHIEF

Bao-Gan Peng, Sandro Vento, Dennis A Bloomfield

EDITORIAL BOARD MEMBERS

<https://www.wjnet.com/2307-8960/editorialboard.htm>

PUBLICATION DATE

December 6, 2021

COPYRIGHT

© 2021 Baishideng Publishing Group Inc

INSTRUCTIONS TO AUTHORS

<https://www.wjnet.com/bpg/gerinfo/204>

GUIDELINES FOR ETHICS DOCUMENTS

<https://www.wjnet.com/bpg/GerInfo/287>

GUIDELINES FOR NON-NATIVE SPEAKERS OF ENGLISH

<https://www.wjnet.com/bpg/gerinfo/240>

PUBLICATION ETHICS

<https://www.wjnet.com/bpg/GerInfo/288>

PUBLICATION MISCONDUCT

<https://www.wjnet.com/bpg/gerinfo/208>

ARTICLE PROCESSING CHARGE

<https://www.wjnet.com/bpg/gerinfo/242>

STEPS FOR SUBMITTING MANUSCRIPTS

<https://www.wjnet.com/bpg/GerInfo/239>

ONLINE SUBMISSION

<https://www.f6publishing.com>

Retrospective Cohort Study

Lamb's tripe extract and vitamin B₁₂ capsule plus celecoxib reverses intestinal metaplasia and atrophy: A retrospective cohort study

Si-Ran Wu, Jie Liu, Li-Feng Zhang, Na Wang, Lu-Yao Zhang, Qiong Wu, Jun-Ye Liu, Yong-Quan Shi

ORCID number: Si-Ran Wu 0000-0002-4378-0794; Jie Liu 0000-0002-3869-0858; Li-Feng Zhang 0000-0001-5001-1400; Na Wang 0000-0003-0789-2681; Lu-Yao Zhang 0000-0001-9408-9496; Qiong Wu 0000-0002-3968-509X; Jun-Ye Liu 0000-0003-3616-7817; Yong-Quan Shi 0000-0001-9515-7577.

Author contributions: Wu SR, Liu J, Shi YQ, Wu Q, and Liu JY designed the research; Wu SR, Liu J, Zhang LF, and Zhang LY made up the methodology; Liu J, Zhang LF, Zhang LY, and Wang N performed the research; Wu SR, Liu J, Zhang LY, and Wu Q managed the data; Liu J, Wu Q, Liu JY, and Wang N acquired the funding; Wu SR and Liu J finished the original draft; Shi YQ, Liu JY, and Wu Q reviewed and edited the paper.

Institutional review board

statement: This study was performed in accordance with the ethical principles for medical research as outlined in the Declaration of Helsinki. The study was approved by the institutional research ethics committee of the First Affiliated Hospital, the Air Force Medical University (KY20212048-C-1).

Informed consent statement:

According to the approval of the institutional research ethics

Si-Ran Wu, Jie Liu, Li-Feng Zhang, Na Wang, Lu-Yao Zhang, Yong-Quan Shi, State Key Laboratory of Cancer Biology, National Clinical Research Center for Digestive Diseases, Xijing Hospital, Air Force Military Medical University, Xi'an 710032, Shaanxi Province, China

Qiong Wu, Department of Clinical Nutrition, Xijing Hospital, Air Force Military Medical University, Xi'an 710032, Shaanxi Province, China

Jun-Ye Liu, Department of Radiation Protective Medicine, Air Force Military Medical University, Xi'an 710032, Shaanxi Province, China

Corresponding author: Yong-Quan Shi, MD, Chief Physician, Doctor, State Key Laboratory of Cancer Biology, National Clinical Research Center for Digestive Diseases, Xijing Hospital, Air Force Military Medical University, No. 127 Changle West Road, Xincheng District, Xi'an 710032, Shaanxi Province, China. shiyquan@fmmu.edu.cn

Abstract**BACKGROUND**

Chronic atrophic gastritis (AG) with intestinal metaplasia (IM) significantly increases the risk of gastric cancer. Some medicines have showed definite therapeutic effects in AG and IM regression.

AIM

To validate the efficacy of Lamb's tripe extract and vitamin B₁₂ capsule (LTEVB₁₂) initial therapy and celecoxib rescue therapy for IM and AG.

METHODS

A total of 255 patients were included to receive LTEVB₁₂ initial therapy (2 capsules each time, three times daily for 6 mo) in hospital in this study. The patients with failure of IM regression continued to receive celecoxib rescue therapy (200 mg, once daily for 6 mo). After each therapy finished, the patients underwent endoscopy and biopsy examination. The regression efficiency was assessed by the operative link on gastritis assessment (OLGA) and the operative link on the gastric intestinal metaplasia assessment (OLGIM) staging system. Logistic regression analysis was applied to identify factors associated with the curative effect.

RESULTS

For LTEVB₁₂ initial therapy, the reversal rates of IM and AG were 52.95% and

committee of the First Affiliated Hospital, the Air Force Medical University, this retrospective cohort study could be applied with exception to the requirement of informed consent forms or documents.

Conflict-of-interest statement: The authors declare that they have no conflict of interest to disclose.

Data sharing statement: No additional data are available.

STROBE statement: The authors have read the STROBE Statement – checklist of items, and the manuscript was prepared and revised according to the STROBE Statement – checklist of items.

Supported by Shaanxi Foundation for Innovation Team of Science and Technology, No. 2018TD-003; and Project from State Key Laboratory of Cancer Biology, No. 2019CBSKL2019ZZ07.

Country/Territory of origin: China

Specialty type: Medicine, research and experimental

Provenance and peer review: Unsolicited article; Externally peer reviewed.

Peer-review report's scientific quality classification

Grade A (Excellent): 0
Grade B (Very good): B
Grade C (Good): 0
Grade D (Fair): 0
Grade E (Poor): 0

Open-Access: This article is an open-access article that was selected by an in-house editor and fully peer-reviewed by external reviewers. It is distributed in accordance with the Creative Commons Attribution NonCommercial (CC BY-NC 4.0) license, which permits others to distribute, remix, adapt, build upon this work non-commercially, and license their derivative works on different terms, provided the original work is properly cited and the use is non-commercial. See: <http://creativecommons.org/licenses/by-nc/4.0/>

48.24%, respectively. Analogously, for celecoxib rescue therapy, the effective rates for IM and AG were 56.25% and 51.56%, respectively. The IM regression rate of complete therapy was up to 85.03%. In different OLGA and OLGIM stages of IM patients, therapeutic efficiency showed a significant difference in each group ($P < 0.05$). For both therapies, patients with high stages (III or IV) of both the OLGA and OLGIM evaluation systems showed a higher IM or AG regression rate than those with low stages (I or II). Among patients with high stages (OLGIM III and IV), the IM regression rate was above 70% for each therapy. Eating habits, fresh vegetable intake, and high-salt diet were identified as independent factors for the IM reversal effect of LTEVB₁₂ therapy, especially high-salt diet (odds ratio = 1.852, $P < 0.05$).

CONCLUSION

Monotherapy could reverse IM and AG. LTEVB₁₂ initial therapy and celecoxib rescue therapy significantly increase the regression effect. IM may not be the point of no return among gastric precancerous lesions.

Key Words: Atrophy gastritis; Intestinal metaplasia; Celecoxib; Stomach neoplasms; Operative link on the gastric intestinal metaplasia assessment; Operative link on the gastritis assessment

©The Author(s) 2021. Published by Baishideng Publishing Group Inc. All rights reserved.

Core Tip: First, we used the operative link on the gastric intestinal metaplasia (IM) assessment and the operative link on the gastritis assessment staging systems to assess IM and atrophic gastritis regression of individual lesions. Monotherapy with either Lamb's tripe extract and vitamin B₁₂ capsule or celecoxib could reverse IM and AG. Additionally, the results proved that the integrative therapy combining Chinese and Western medicine had better regression effects. Last but not least, the results counter the argument that IM may not be the point of no return about gastric mucosal lesions.

Citation: Wu SR, Liu J, Zhang LF, Wang N, Zhang LY, Wu Q, Liu JY, Shi YQ. Lamb's tripe extract and vitamin B₁₂ capsule plus celecoxib reverses intestinal metaplasia and atrophy: A retrospective cohort study. *World J Clin Cases* 2021; 9(34): 10472-10483

URL: <https://www.wjgnet.com/2307-8960/full/v9/i34/10472.htm>

DOI: <https://dx.doi.org/10.12998/wjcc.v9.i34.10472>

INTRODUCTION

Gastric cancer (GC), one of the most common malignant tumors, has a high incidence around the world[1]. In China, GC ranks second in both the morbidity and mortality of malignant tumors. According to previous reports in 2015, approximately 498000 Chinese people died from GC per year[2]. The Correa model revealed a successive stepwise development of premalignant gastric lesions, which resulted in GC, especially for the intestinal type[3]. From decades of research, intestinal metaplasia (IM) and severe atrophic gastritis (AG) have proved to form the backdrop of dysplasia and intestinal-type gastric adenocarcinoma, so that they were considered high risk factors for GC occurrence[4,5]. Even in the low GC risk population cohort, IM and AG obtained 6.2 and 4.5 hazard ratios, respectively, compared with the normal group[6]. The view of the point of no return among gastric precancerous lesions was revealed at the end of the last century[7]. There were some meta-analyses supporting this view. They suggested that *Helicobacter pylori* (*H. pylori*) eradication did not reverse IM but did have an effect on chronic AG[8-10]. However, there was still some evidence that did not support this conclusion. Some studies supported that *H. pylori* eradication actually could reverse the IM in the long-term follow-up, which has made the debate about the point of no return among gastric precancerous lesions persisting[11-13].

There are still some studies that found the IM reversal effect of medicine. In recent years, there have also been many reports related to drugs, including Western medicine and traditional Chinese medicine, that could reverse IM. Lamb's tripe extract and

Received: March 27, 2021**Peer-review started:** March 27, 2021**First decision:** August 18, 2021**Revised:** August 31, 2021**Accepted:** October 24, 2021**Article in press:** October 24, 2021**Published online:** December 6, 2021**P-Reviewer:** Wakatsuki T**S-Editor:** Fan JR**L-Editor:** Wang TQ**P-Editor:** Fan JR

vitamin B₁₂ capsule (LTEVB₁₂) is the combination of the lamb sheep's fourth tripe extracted at low temperature, vitamin B₁₂ and excipients. The extract of lamb's fourth tripe contains many active substances, such as renin, pepsin, mucin, and bifidus factor. It has been proven to promote the growth and propagation of bifidobacteria *in vitro* [14]. Recently, many studies have shown that both the application of LTEVB₁₂ alone or in combination with other medication could reverse IM and AG [15,16]. Moreover, our recent study found that the use of LTEVB₁₂ alone for 6 mo and 12 mo reversed IM. Among all related studies, the IM regression rate of LTEVB₁₂ alone was reported to be up to 55.71% [16].

Cyclooxygenase-2 (COX-2), an enzyme that acts as a catalyst in the transformation of arachidonic acid into prostaglandins, has been found to participate in *H. pylori*-associated gastric carcinogenesis [17]. COX-2 is overexpressed in gastric carcinoma and premalignant lesions [18,19]. A selective COX-2 inhibitor, celecoxib, can observably decrease the risk of colon, lung, breast, and prostate cancers [20]. Many studies have shown that both long-term and short-term applications of celecoxib can reverse IM and AG and even other gastric premalignant lesions [21-25]. However, these studies reported that the reversal rate of IM was approximately 40%.

On the basis of such evidence, monotherapy with either LTEVB₁₂ or celecoxib did not show an ideal efficiency with regard to IM regression. We conducted a retrospective cohort study to assess whether LTEVB₁₂ initial therapy and celecoxib rescue therapy can prevent progression or enhance the regression of IM and AG.

MATERIALS AND METHODS

Patients and study design

From October 2016 to July 2019, 345 patients diagnosed with IM with or without low-grade intraepithelial neoplasia (LGIN) by upper gastrointestinal endoscopy and histopathological biopsy were enrolled and followed at the Department of Gastroenterology, Xijing Hospital, Air Force Military Medical University. The inclusion criteria were: (1) Patients aged from 18 to 75 years old; (2) IM patients with or without LGIN diagnosed by upper gastrointestinal endoscopy and histopathological biopsy; and (3) Patients without *H. pylori* infection confirmed by ¹³C-urea breath test (UBT) or patients with *H. pylori* infection who completed the bismuth-containing quadruple program and had confirmed successful eradication by ¹³C-UBT. The exclusion criteria were: (1) Previously diagnosed malignant tumor; (2) History of stomach surgery; (3) Breast-feeding or pregnancy; (4) Hypothyroidism, adrenal insufficiency, systemic lupus erythematosus, ankylosing spondylitis, and other endocrine diseases or autoimmune diseases; (5) Severe mental illness; (6) Refusal of drug treatment; (7) Diagnosis of GC or high grade intraepithelial neoplasia (HGIN) by upper gastrointestinal endoscopy and pathological examination; and (8) Severe liver and kidney dysfunction. The general situation, eating habits, behavioral characteristics (smoking and drinking), disease history, medication history, and other data of the patients were collected at the inception of the study. When the therapy was accomplished, they underwent upper gastrointestinal endoscopy and histopathological biopsy. This study was performed in accordance with the ethical principles for medical research as outlined in the Declaration of Helsinki. The study was approved by the institutional research ethics committee of the First Affiliated Hospital, the Air Force Medical University (KY20212048-C-1).

The participants received LTEVB₁₂ initial treatment (2 capsules each time, three times daily; GMP, the Xinjiang Uygur Autonomous Region, China) for 6 mo at first. Some participants with IM regression failure in initial therapy could choose to continue the next rescue therapy or not. The patients deciding to accept it received celecoxib rescue therapy (200 mg, once daily; Pfizer, New York, NY, United States) for 6 mo. This study is a retrospective cohort study. We determined whether the patients needed to accept celecoxib rescue therapy depending on the change of the operative link on the gastric intestinal metaplasia assessment (OLGIM) stage score before and after treatment. The study size was decided by comparing with similar studies.

Endoscopy and histological assessment

Participants with a prior diagnosis of IM and dysplasia accepted upper gastrointestinal endoscopy surveillance with a standard video endoscope (Olympus GIF-Q160, Tokyo, Japan). Comprehensive biopsy samples for histological examination were obtained from five standardized sites: Two from the antrum, two from the corpus (one from the lesser curvature and one from the greater curvature), and one

from the angulus. In the case of endoscopically visible lesions, additional targeted biopsy samples were obtained.

Three pathologists blinded to the patient clinical information independently reviewed the histology of the collected samples. The grades of IM and AG were classified according to the updated Sydney system, which scored as 0 (absent), 1 (mild), 2 (moderate), or 3 (marked). Dysplasia was assessed based on the revised Vienna classification[26,27]. Of antrum and angulus biopsy samples, the severer one was on behalf of the distal antrum mucosa score. The same method applied to corpus greater and lesser curvature biopsy samples for the corpus mucosa score. According to the standardized sites, the AG, IM, and inflammation stages in all five biopsy specimens were evaluated on the basis of the operative link on gastritis assessment (OLGA) staging system[28] and the OLGIM staging system[29]. Combining the antrum and corpus scores for AG, IM, and inflammation resulted in OLGA and OLGIM staging scores (range: 0-4, respectively). For an inconsistent diagnosis, the final decision was depended on the majority diagnosis: At least two of three pathologists agreed.

End points and statistical analysis

The hypothesis tested in this study was that LTEVB₁₂ initial treatment and celecoxib rescue therapy could promote the reversal of IM and AG. The main observation indexes were OLGIM and OLGA stage changes. To evaluate the effects of the therapies, each subject was assigned a stage score before the therapy (A) and at the end point (B) according to OLGIM and OLGA stages. We choose to use the result of B-A to verdict the development status of gastric mucosal lesions. If B-A was > 1, = 0, and < 0, the subject was considered as progression, no-change, and regression, respectively. Regression was deemed to be effective; the others were clarified to be ineffective.

Data were analyzed with SPSS 26.0 software. Continuous variables are described as medians and interquartile ranges. Count variables are described as numbers and percentages. Comparison of the effective rate between different therapies and different OLGA and OLGIM stages was evaluated by the chi-square test or Fisher exact method. Comparison of the proportion among different OLGA and OLGIM stages before and after treatment was evaluated by rank sum test. The influence of the various factors on the efficacy was computed by univariate and multivariate logistic regression analyses with *P* values, odd ratios (ORs), and 95% confidence interval (CIs).

RESULTS

Subject characteristics and related histology before treatment

There were 338 IM patients consecutively enrolled in this study during a total follow-up period of 34 mo (median, 15 mo). Eighty-three patients (20 who did not complete the treatment and 63 who refused endoscopic follow-up) in the LTEVB₁₂ initial therapy group and 56 (17 who did not complete the treatment and 39 who refused endoscopic follow-up) in the celecoxib rescue therapy group dropped out of the study (Figure 1). A total of 255 patients finished LTEVB₁₂ initial treatment. For 120 patients, treatment was viewed as ineffective (IM regression failure). Finally, 64 patients completed rescue therapy, 28 of whom were invalid (Figure 1). For the patients receiving LTEVB₁₂ and celecoxib therapy, the demographic parameters, pretreatment histological features, and baseline data are shown in the supplementary materials (Supplementary Table 1). Before LTEVB₁₂ initial treatment, the OLGIM stages in 255 patients from I to IV were 64, 110, 62, and 19, respectively, and the OLGA stages from 0 to IV were 23, 14, 102, 81, and 35, respectively. Twenty-one had LGIN at baseline. Before celecoxib rescue therapy, the OLGIM stages from I to IV in 64 patients were 6, 32, 16, and 10, and the OLGA stages from 0 to IV were 1, 0, 20, 23, and 20, respectively. One had LGIN.

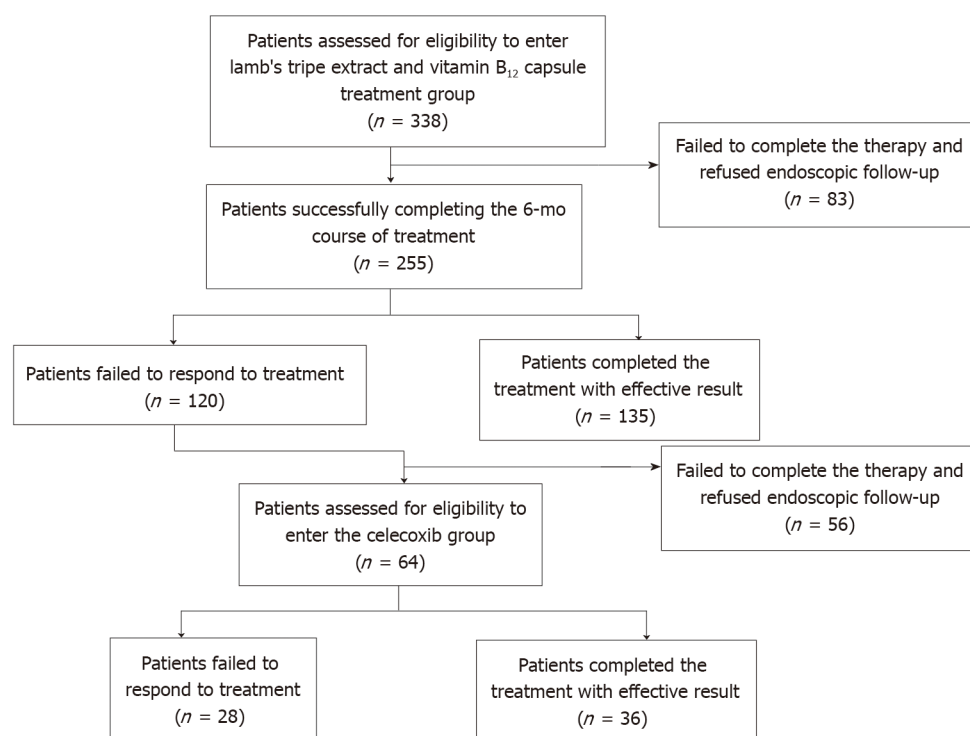
Intention-to-treat and per-protocol analysis of IM and AG regression following the two therapies

There were 255 cases in the LTEVB₁₂ initial therapy group and 64 cases in the celecoxib rescue therapy group that were enrolled for per-protocol (PP) analysis. The rates of IM and AG regression at 6 mo according to intention-to-treat (ITT) or PP analysis are shown in Table 1. The results of comparing the same patients before and after the therapies by OLGA and OLGIM stages were significantly different (for the two therapies and both stages, *P* < 0.01). For the LTEVB₁₂ initial therapy group, about half

Table 1 Intestinal metaplasia and atrophic gastritis regression based on intention-to-treat and per-protocol analyses

Group	IM regression (%)		AG regression (%)		IM or AG regression (%)	
	ITT analysis	PP analysis	ITT analysis	PP analysis	ITT analysis	PP analysis
LTEVB ₁₂ initial therapy	39.94	52.95	36.39	48.24	53.55	70.98
Celecoxib rescue therapy	30.00	56.25	27.50	51.56	39.17	78.33
Complete therapy	50.59	85.93	-	-	-	-

AG: Atrophic gastritis; IM: Intestinal metaplasia; LTEVB₁₂: Lamb's tripe extract and vitamin B₁₂ capsule; ITT: Intention-to-treat; PP: Per-protocol.

**Figure 1 Schematic flowchart showing patient numbers at different study stages.**

of the patients (52.95%) in the PP analysis showed IM regression after 6 mo of initial LTEVB₁₂ therapy. Forty-eight percent of patients showed an effect with regard to AG regression. In addition, 19 out of 21 patients with LGIN had lesions that disappeared. For 6-mo celecoxib rescue therapy, in 64 patients, the regression rate of IM was up to 56.25%. Approximately 51.56% of patients had AG regression. The lesion of the only LGIN patient disappeared. For complete therapy, 85.93% of participants in the PP analysis had IM regression. Efficiency did not differ between the two monotherapies ($P > 0.05$) but showed a significant difference when comparing either monotherapy to complete therapy ($P < 0.05$).

Changes in OLGA and OLGIM stages before and after treatment and therapeutic efficiency among different OLGA and OLGIM stages

Figure 2 shows the proportions of patients who had IM and achieved improvement of IM after 6 mo of LTEVB₁₂ and celecoxib therapy. For LTEVB₁₂, 11.76% (30/255) and 16.08% (41/255) of patients had complete disappearance of IM and AG, respectively. A total of 41.18% (105/255) and 31.16% (82/255) of patients were found to have decreased OLGIM and OLGA stages, respectively. Similarly, the rates of complete IM and AG disappearance were 6.25% (4/64) and 14.06% (9/64), respectively, following celecoxib rescue therapy. Fifty percent (32/64) and 37.5% (24/64) of patients were found to have decreased OLGIM and OLGA stages, respectively.

Depending on the OLGA and OLGIM stages, the proportions of different stages showed significant differences before and after therapies (for the two therapies and

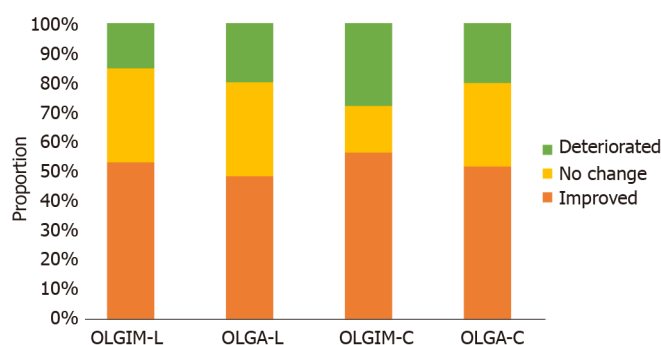


Figure 2 Proportions of intestinal metaplasia and atrophic gastritis changes after Lamb's tripe extract and vitamin B₁₂ capsule initial therapy and celecoxib rescue therapy. L: Lamb's tripe extract and vitamin B₁₂ capsule initial therapy; C: Celecoxib rescue therapy; OLGA: Operative link on gastritis assessment; OLGIM: Operative link on the gastric intestinal metaplasia assessment.

both stages, $P < 0.01$). **Figure 3** shows the different OLGA and OLGIM stages changing after each therapy. The proportion of high stages was decreased by therapies. The proportion of low stages, by contrast, obviously increased. In OLGIM stages III and IV, which were viewed as a high risk for GC, the IM regression rates were all above 70% for each therapy. LTEVB₁₂ initial therapy reversed IM in 89.47% of OLGIM stage IV patients. For high-risk OLGA stages III and IV patients, the AG regression rate ranged from 50% to 100%.

In different OLGA and OLGIM stages of IM patients, therapeutic efficiency showed a significant difference in each group (**Table 2**). For LTEVB₁₂ therapy, patients with OLGIM or OLGA stage IV disease had higher IM and AG regression rates than those with stages I and II disease (IM: 89.5% *vs* 17.2% and 57.3%; AG: 100% *vs* 33.3% and 40.6%; $P < 0.05$). For celecoxib therapy, both IM and AG regression rates showed significant differences between high stages (III and IV) and stage II (IM: 71.6% and 71.4% *vs* 31.4%; AG: 76.2%, 50% *vs* 30%; $P < 0.05$). In summary, each therapy had more efficiency for patients with high OLGA or OLGIM stages.

Analysis of factors associated with curative effect

The influencing factors of two therapies were assessed by univariate and multivariate logistic regression analyses. Many factors were included in the analysis, such as sex, age, body mass index, family history of GC, smoking and alcohol status, disease history, medication history, and eating habits. The results of univariate logistic regression analysis are shown in the supplementary materials (**Supplementary Tables 2 and 3**). After univariate logistic regression analysis, as shown in **Table 3**, some factors were included in the multivariate analysis according to the inclusion criteria ($P < 0.10$). Eating habits, fresh vegetable intake, and high-salt diet were viewed as independent factors for the IM reversal effect of LTEVB₁₂ therapy, especially high-salt diet. Nearly twice as many patients with a high-salt diet as those without a high-salt diet benefited from LTEVB₁₂ therapy in IM regression (OR = 1.852, 95%CI: 1.044-3.285). For AG regression, patients with low education levels (OR = 0.480, 95%CI: 0.255-0.903) may benefit more from LTEVB₁₂ therapy than patients with high education levels ($P < 0.05$). For celecoxib therapy, income level (≥ 5000 yuan/mo) was the independent influencing factor for the IM regression, which suggested that celecoxib therapy for IM regression may be more effective in patients with high income levels ($P < 0.10$). In addition, for male patients with LTEVB₁₂ therapy, the inflammation score (score > 2) before therapy (OR = 0.448, 95%CI: 0.223-0.898) at baseline and fresh fruit intake (OR = 2.784, 95%CI: 1.131-6.852) were associated with the effect ($P < 0.05$).

DISCUSSION

Through this study, we found that both LTEVB₁₂ and celecoxib monotherapies could reverse IM and AG, and the addition of celecoxib rescue therapy to LTEVB₁₂ initial therapy further increased the regression rate of IM. After LTEVB₁₂ initial therapy and celecoxib rescue therapy, the regression rate of IM depending on the OLGIM stage was up to 85.93%. These results suggested that this complete therapy could be applied in the clinical setting to reverse precancerous lesions, especially IM.

Table 2 Intestinal metaplasia and atrophic gastritis regression rates of different operative link on gastritis assessment and operative link on gastric intestinal metaplasia assessment stages for each therapy group

Group	IM regression (%)					AG regression (%)				
	I stage	II stage	III stage	IV stage	P value	I stage	II stage	III stage	IV stage	P value
LTEVB ₁₂	17.19	57.27 ^a	70.97 ^a	89.47 ^{a,b}	< 0.001	33.33	40.63	66.67	100.00 ^{c,d}	< 0.05
Celecoxib	57.14	31.37	71.60 ^e	71.43 ^e	< 0.001	-	30.00	50.00	76.20 ^f	< 0.05

^aP < 0.05 *vs* control (IM regression of stage I in LTEVB₁₂ group).^bP < 0.05 *vs* control (IM regression of stage II in LTEVB₁₂ group).^cP < 0.05 *vs* control (AG regression of stage I in LTEVB₁₂ group).^dP < 0.05 *vs* control (AG regression of stage II in LTEVB₁₂ group).^eP < 0.05 *vs* control (IM regression of stage II in celecoxib group).^fP < 0.05 *vs* control (IM regression of stage II in celecoxib group).AG: Atrophic gastritis; IM: Intestinal metaplasia; ITT: Intention-to-treat; LTEVB₁₂: Lamb's tripe extract and vitamin B₁₂ capsule; OLGA: Operative link on gastritis assessment; OLGIM: Operative link on the gastric intestinal metaplasia assessment.**Table 3 Factors associated with regression of intestinal metaplasia and atrophic gastritis (multivariate analysis)**

Regression effect	Factor	LTEVB ₁₂			Celecoxib		
		OR	95%CI	P value	OR	95%CI	P value
IM	Fresh vegetable intake (> 100 g/d)	0.497	0.224-1.105	0.087	-	-	-
	High salt diet	1.852	1.044-3.285	0.035	-	-	-
	Tea intake (> 100g/d)	-	-	-	2.295	0.736-7.158	0.152
	Education level (≥ senior high school)	-	-	-	1.672	0.495-5.643	0.408
	Income level (≥ 5000 yuan/mo)	-	-	-	3.097	0.902-10.638	0.073
AG	Education level (≥ senior high school)	0.480	0.255-0.903	0.023	-	-	-
	Tea intake (> 100g/d)	0.678	0.388-1.185	0.173	-	-	-
	Profession (ref: Farmer)			0.169			-
	Officer	0.784	0.313-1.965	0.603	-	-	-
	Medic	-	-	-	-	-	-
	Teacher	1.897	0.620-5.804	0.262	-	-	-
	Merchant	1.028	0.361-2.933	0.958	-	-	-
	Technical staff	3.305	1.275-8.565	0.014	-	-	-
	Retired	1.878	0.791-4.458	0.153	-	-	-
	Unemployed	1.570	0.612-4.027	0.348	-	-	-
	Blood type (ref: A)			-			0.123
	B	-	-	-	2.021	0.240-17.033	0.518
	O	-	-	-	0.322	0.064-1.617	0.169
	AB	-	-	-	0.118	0.010-1.460	0.096
	Unknown	-	-	-	0.389	0.128-1.182	0.096

AG: Atrophic gastritis; CI: Confidence interval; IM: Intestinal metaplasia; ITT: Intention-to-treat; LTEVB₁₂: Lamb Tripe Extract and Vitamin B₁₂ Capsule; OR: Odds ratio; PP: Per-protocol.

LTEVB₁₂ is a kind of traditional Chinese medicine extract. Several studies have shown that it has an effect on IM and AG[15,16]. In addition, it was effective for clinical symptoms such as abdominal distension and lack of appetite, with an effective rate up to 91%. In contrast with studies that evaluated IM regression after 6 mo or 12

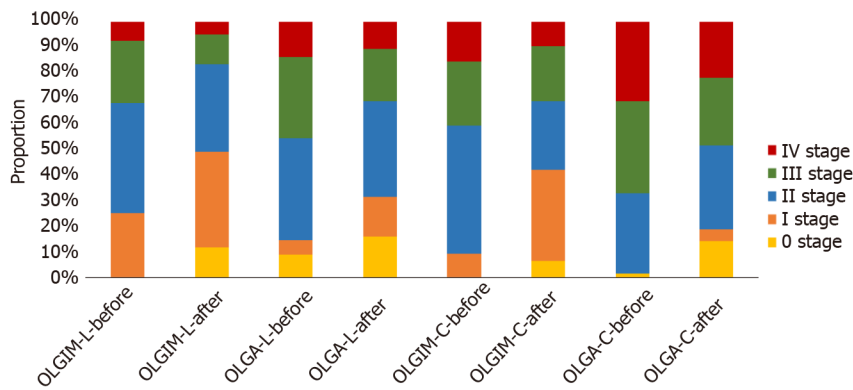


Figure 3 Changes of the different operative link on gastritis assessment and operative link on gastric intestinal metaplasia assessment stages after each therapy. L: Lamb's tripe extract and vitamin B₁₂ capsule initial therapy; C: Celecoxib rescue therapy; OLGA: Operative link on gastritis assessment; OLGIM: Operative link on the gastric intestinal metaplasia assessment.

mo of LTEVB₁₂ treatment, the effective rates were 56.25% *vs* 55.71% and 32.9% and 41.8%, respectively. In other studies, few adverse effect or toxic side effects was found during the treatments[14-16]. The participants in our research did not show severe adverse effect and toxic side effects. Some studies have indicated that the application of aspirin or other non-steroidal anti-inflammatory drugs could restrain the development of GC[30,31]. Several studies have reported the effect of celecoxib on IM regression. COX-2 was suggested to cause *H. pylori*-related gastric lesions though various mechanisms. Overexpression of COX-2 and the prostaglandin cascade induced by *H. pylori*-induced inflammation during carcinogenesis could lead to cell proliferation, mutagenesis, mitogenesis, and inhibition of apoptosis. As a COX-2 inhibitor, celecoxib could restrain the processes as mentioned above so that it may inhibit the development of GC[17,20]. Moreover, nuclear factor kappa B activation, which acts as a major mediator of *H. pylori*-related inflammation, was reported to be inhibited by celecoxib[32,33]. Wong *et al*[25] reported that the combination of anti-*H. pylori* therapy and celecoxib did not show better effects than anti-*H. pylori* therapy alone. However, two studies found that after eradication therapy (1 year and 3 years apart), celecoxib still had an effect on IM and AG regression[21,22]. This might contribute to the persistent existence of the tumor microenvironment even after *H. pylori* eradication[34, 35]. In contrast with other studies that evaluated IM regression after 12 mo or 2 mo of celecoxib treatment, the rate was 56.25% *vs* 42% and 51.3% and 28.6%, respectively. It was also significantly different even when compared with the nondrug group (16.1% and 20.0%)[21-23].

The complete therapy used traditional Chinese medicine extract and Western medicine in turn, which could combine the advantage of both sides. In Taipei consensus on integrative traditional Chinese and Western medicine, Western medicine was deemed to play a part in the disease diagnosis and therapy, yet was still not perfect with deficiency. Traditional Chinese medicine had complementary and alternative effect which is indispensable[36]. A meta-analysis indicated that traditional Chinese medicine is more effective than current routine pharmacotherapy in clinical symptom relief, *H. pylori* eradication, and efficacy under endoscopy[37]. Thus, LTEVB₁₂ initial therapy and celecoxib rescue therapy actually enhance the regression rate of gastric mucosal lesions with few adverse effects and toxic side effects.

Generally, the effective rate of each monotherapy for IM in our study was better or at least not inferior to that in other studies. Following the complete therapy, the IM regression rate was up to 85.93%, obviously improving the efficacy of IM regression. In addition, in contrast to previous studies, we had a larger sample in this study. Moreover, in our study, we chose the OLGIM and OLGA stages to assess the effect of IM and AG regression. Some studies chose other methods, such as the mean IM score (MIM), to assess the IM and AG regression effects[24]. MIM was the sum of all IM scores from all samples divided by the number of tissues, which led to the assessment of the effect of regression by lesions, not patients. Compared with other evaluation methodologies of histological examination, OLGA and OLGIM stages exhibited superior capability to assess the individuals. OLGA and OLGIM stages combines the location and degree of gastric mucosal atrophy and IM, which could better reflect the severity of gastric mucosal lesions. What's more, the OLGA and OLGIM stages have been applied to evaluate the risk of GC in the clinic, which could be much more

persuasive[38,39]. In each monotherapy in this study, high GC risk patients with OLGIM or OLGA stages III and IV disease had good effects compared with low-risk patients with low stage disease. Kang *et al*[40] conducted a 3-year follow-up study in Korea and found that the severe grade of IM was associated with the improvement of IM in the body (OR = 5.14; $P < 0.05$). This result may be attributed to some reasons. Patients with high OLGIM or OLGA stage usually had more serious inflammation, which may show better efficacy when receiving the therapy particularly the celecoxib therapy. Besides, the patients with advanced OLGIM stage would preferably follow the doctor's advice than other patients and complete the whole course of treatment. Many factors associated with efficacy were included in our study for analysis. The results of logistic regression analysis showed that eating habits are an independent factor for the IM reversal effect of LTEVB₁₂ therapy, which suggested that patients should change unhealthy eating habits while receiving treatment. At the end of the follow-up, four patients were diagnosed with HGIN and recommended to undergo digestive endoscopy surgery. Thus, the efficacy of complete therapy on such advanced lesions may be limited. A drawback of the study was that we did not obtain complete data for clinical symptoms, so we could not evaluate the effect. However, many studies have reported that celecoxib treatment did not increase adverse reactions or affect renal function[22]. This study was conducted in a single center, the sample size was limited, and the follow-up was only applied when 6 mo of therapy was finished, so the conclusion needs to be verified by a long-term follow-up prospective study.

Based on our findings, it is inappropriate to regard IM as the point of no return of gastric mucosal lesions. Correa *et al*[41] reported in 1990 that in the long-term follow-up, IM could reverse spontaneously in a few patients (0.044/person-year). Hwang *et al* [42] suggested that in the 10-year follow-up, eradication therapy of *H. pylori* could reverse 60% of IM lesions. Although some meta-analyses have shown that IM cannot be reversed after *H. pylori* eradication, there were still some clinical studies with long-term follow-up showed that IM could be reversed after *H. pylori* eradication. Correa *et al*[43] reported that eradication therapy could reverse not only the degree of AG, but also the IM in a randomized controlled trial. Leung *et al*[44] demonstrated that *H. pylori* eradication could inhibit the development of IM based on a randomized controlled trial with a 5-year follow-up. Kong *et al*[11] conducted a meta-analysis with the inclusion criteria using the Sydney system or the updated Sydney system. The result showed that *H. pylori* eradication was significantly related to improvement in IM in the antrum. Kodama *et al*[12] conducted a prospective 10-year follow-up of patients with IM after *H. pylori* eradication. Biopsy specimens were taken from five points of the stomach, as recommended by the updated Sydney system. IM scores of the lesser curvature of the corpus decreased gradually in the whole observation period and showed a significant decline after 6-year follow-up. These studies showed the importance of standardized methods of biopsy depending on OLGIM stage and long-term follow-up. Besides, Western and Chinese traditional medicines have a great effect on IM regression. In addition to LTEVB₁₂ and celecoxib mentioned in this study, our group recently also found that resveratrol could reduce IM through the PI3K/AKT/p-FoxO4 signaling pathway and had a potential reversing effect on those IM lesions especially caused by bile acid reflux[45]. Vitamins and other traditional Chinese medicines, such as Moluodan, have also been reported to have reversal effects on gastric precancerous lesions[46,47]. In general, IM should not be viewed as a point of no return of gastric mucosal lesions. The reversal effect of medicine is important for the prevention of GC and is beneficial for reducing the heavy burden of endoscopic follow-up of IM in China.

CONCLUSION

LTEVB₁₂ initial therapy and celecoxib rescue therapy can effectively decrease the OLGA and OLGIM stages of IM patients to reduce the risk of GC. This therapy with integrative Chinese and western medicine may have good clinical application value in the prevention of GC. Moreover, this finding supports the insight that IM is not the point of no return among gastric precancerous lesions.

ARTICLE HIGHLIGHTS

Research background

A large number of intestinal metaplasia (IM) patients need to be effectively treated, which can successfully reduce the risk of gastric cancer (GC). Some medicines have showed the potential to reverse the IM lesion. It would help doctors in clinical practice and refute the concept that IM could not be reversed.

Research motivation

Lamb's tripe extract and vitamin B₁₂ capsule (LTEVB₁₂) and celecoxib have been proved to reverse IM in past studies. But the IM regression effect of LTEVB₁₂ and celecoxib still have to be evaluated thoroughly by operative link on gastritis assessment (OLGA) and operative link on the gastric intestinal metaplasia assessment (OLGIM) stages. What's more, the combination of these two kinds of drugs may enhance the effect of IM regression.

Research objectives

This study aimed to validate the efficacy of LTEVB₁₂ initial therapy and celecoxib rescue therapy on IM.

Research methods

This study was a retrospective cohort study. A total of 255 patients were included to receive LTEVB₁₂ initial therapy in this study. The patients with failure of IM regression continued to celecoxib receive rescue therapy. After each therapy finished, patients underwent endoscopy and biopsy examination. OLGA and OLGIM stages were applied to evaluate the reversal of atrophic gastritis (AG) and IM.

Research results

For LTEVB₁₂ initial therapy, the reversal rates of IM and AG were 52.95% and 48.24%, respectively. For celecoxib rescue therapy, the effective rates for IM and AG were 56.25% and 51.56%, respectively. The IM regression rate of complete therapy was up to 85.03% ($P < 0.05$). For both therapies, patients with high stages (III or IV) of both OLGA and OLGIM evaluation systems showed a higher IM or AG regression rate than those patients with low stages (I or II). Among high stage (OLGIM III and IV) patients, the IM regression rate was above 70% for each therapy.

Research conclusions

Each monotherapy could effectively reverse IM and AG. The LTEVB₁₂ initial therapy and celecoxib rescue therapy, significantly increased the regression effect, which showed strong potential to reduce the risk of GC. IM may be not the point of no return among gastric precancerous lesions.

Research perspectives

LTEVB₁₂ initial therapy and celecoxib rescue therapy can achieve better effect on IM regression compared with either monotherapy. IM could be reversed by clinical intervention.

REFERENCES

- 1 Ferlay J, Colombet M, Soerjomataram I, Mathers C, Parkin DM, Piñeros M, Znaor A, Bray F. Estimating the global cancer incidence and mortality in 2018: GLOBOCAN sources and methods. *Int J Cancer* 2019; **144**: 1941-1953 [PMID: 30350310 DOI: 10.1002/ijc.31937]
- 2 Chen W, Zheng R, Baade PD, Zhang S, Zeng H, Bray F, Jemal A, Yu XQ, He J. Cancer statistics in China, 2015. *CA Cancer J Clin* 2016; **66**: 115-132 [PMID: 26808342 DOI: 10.3322/caac.21338]
- 3 Correa P. Human gastric carcinogenesis: a multistep and multifactorial process--First American Cancer Society Award Lecture on Cancer Epidemiology and Prevention. *Cancer Res* 1992; **52**: 6735-6740 [PMID: 1458460]
- 4 Dinis-Ribeiro M, Areia M, de Vries AC, Marcos-Pinto R, Monteiro-Soares M, O'Connor A, Pereira C, Pimentel-Nunes P, Correia R, Ensari A, Dumonceau JM, Machado JC, Macedo G, Malfertheiner P, Matysiak-Budnik T, Megraud F, Miki K, O'Morain C, Peek RM, Ponchon T, Ristimäki A, Rembacken B, Carneiro F, Kuipers EJ; European Society of Gastrointestinal Endoscopy; European Helicobacter Study Group; European Society of Pathology; Sociedade Portuguesa de Endoscopia Digestiva. Management of precancerous conditions and lesions in the stomach (MAPS): guideline

- from the European Society of Gastrointestinal Endoscopy (ESGE), European Helicobacter Study Group (EHSG), European Society of Pathology (ESP), and the Sociedade Portuguesa de Endoscopia Digestiva (SPED). *Endoscopy* 2012; **44**: 74-94 [PMID: 22198778 DOI: 10.1055/s-0031-1291491]
- 5 **Pimentel-Nunes P**, Libânio D, Marcos-Pinto R, Areia M, Leja M, Esposito G, Garrido M, Kikuste I, Megraud F, Matsiyak-Budnik T, Annibale B, Dumonceau JM, Barros R, Fléjou JF, Carneiro F, van Hooft JE, Kuipers EJ, Dinis-Ribeiro M. Management of epithelial precancerous conditions and lesions in the stomach (MAPS II): European Society of Gastrointestinal Endoscopy (ESGE), European Helicobacter and Microbiota Study Group (EHMSG), European Society of Pathology (ESP), and Sociedade Portuguesa de Endoscopia Digestiva (SPED) guideline update 2019. *Endoscopy* 2019; **51**: 365-388 [PMID: 30841008 DOI: 10.1055/a-0859-1883]
 - 6 **Song H**, Ekheden IG, Zheng Z, Ericsson J, Nyrén O, Ye W. Incidence of gastric cancer among patients with gastric precancerous lesions: observational cohort study in a low risk Western population. *BMJ* 2015; **351**: h3867 [DOI: 10.1136/bmj.h3867]
 - 7 **Wright NA**. Gastric carcinogenesis: when is the point of no return? CA: Springer, 1998
 - 8 **Rokkas T**, Pistiolos D, Sechopoulos P, Robotis I, Margantinis G. The long-term impact of Helicobacter pylori eradication on gastric histology: a systematic review and meta-analysis. *Helicobacter* 2007; **12** Suppl 2: 32-38 [PMID: 17991174 DOI: 10.1111/j.1523-5378.2007.00563.x]
 - 9 **Wang J**, Xu L, Shi R, Huang X, Li SW, Huang Z, Zhang G. Gastric atrophy and intestinal metaplasia before and after Helicobacter pylori eradication: a meta-analysis. *Digestion* 2011; **83**: 253-260 [PMID: 21282951 DOI: 10.1159/000280318]
 - 10 **Chen HN**, Wang Z, Li X, Zhou ZG. Helicobacter pylori eradication cannot reduce the risk of gastric cancer in patients with intestinal metaplasia and dysplasia: evidence from a meta-analysis. *Gastric Cancer* 2016; **19**: 166-175 [PMID: 25609452 DOI: 10.1007/s10120-015-0462-7]
 - 11 **Kong YJ**, Yi HG, Dai JC, Wei MX. Histological changes of gastric mucosa after Helicobacter pylori eradication: a systematic review and meta-analysis. *World J Gastroenterol* 2014; **20**: 5903-5911 [PMID: 24914352 DOI: 10.3748/wjg.v20.i19.5903]
 - 12 **Kodama M**, Murakami K, Okimoto T, Sato R, Uchida M, Abe T, Shiota S, Nakagawa Y, Mizukami K, Fujioka T. Ten-year prospective follow-up of histological changes at five points on the gastric mucosa as recommended by the updated Sydney system after Helicobacter pylori eradication. *J Gastroenterol* 2012; **47**: 394-403 [PMID: 22138891 DOI: 10.1007/s00535-011-0504-9]
 - 13 **Kodama M**, Murakami K, Okimoto T, Abe T, Nakagawa Y, Mizukami K, Uchida M, Inoue K, Fujioka T. Helicobacter pylori eradication improves gastric atrophy and intestinal metaplasia in long-term observation. *Digestion* 2012; **85**: 126-130 [PMID: 22269293 DOI: 10.1159/000334684]
 - 14 **Wang SR**, Zhang HW, Zhang KY. Biological activity of bifidus factor in the extracts from animal gastric mucosa. *Zhongguo Yaojixue Zazhi* 1994; **15**: 41-43 [DOI: 10.3736/jcim20040109]
 - 15 **Gou X**, Liu L, Wang Q, Chen L, Dou DC. Treatment of chronic atrophic gastritis in middle aged and senile patients by gastropylor complex capsules combined with folic acid. *Xinan Guofangjun Yixue Zazhi* 2013; **23**: 40-42 [DOI: 10.11569/wcjd.v25.i23.2139]
 - 16 **He H**, Liu F, Li FF, Re YL, Chen WG. Clinical effect of gastropylor complex capsules in treatment of chronic atrophic gastritis with intestinal metaplasia. *Zhonghua Weichangganbingxue Zazhi* 2015; **24**: 1116-1118 [DOI: 10.3736/jcim20080218]
 - 17 **Saukkonen K**, Rintahaka J, Sivula A, Buskens CJ, Van Rees BP, Rio MC, Haglund C, Van Lanschot JJ, Offerhaus GJ, Ristimäki A. Cyclooxygenase-2 and gastric carcinogenesis. *APMIS* 2003; **111**: 915-925 [PMID: 14616542 DOI: 10.1034/j.1600-0463.2003.1111001.x]
 - 18 **Liu F**, Pan K, Zhang X, Zhang Y, Zhang L, Ma J, Dong C, Shen L, Li J, Deng D, Lin D, You W. Genetic variants in cyclooxygenase-2: Expression and risk of gastric cancer and its precursors in a Chinese population. *Gastroenterology* 2006; **130**: 1975-1984 [PMID: 16762620 DOI: 10.1053/j.gastro.2006.03.021]
 - 19 **Sung JJ**, Leung WK, Go MY, To KF, Cheng AS, Ng EK, Chan FK. Cyclooxygenase-2 expression in Helicobacter pylori-associated premalignant and malignant gastric lesions. *Am J Pathol* 2000; **157**: 729-735 [PMID: 10980112 DOI: 10.1016/S0002-9440(10)64586-5]
 - 20 **Harris RE**. Cyclooxygenase-2 (cox-2) blockade in the chemoprevention of cancers of the colon, breast, prostate, and lung. *Inflammopharmacology* 2009; **17**: 55-67 [PMID: 19340409 DOI: 10.1007/s10787-009-8049-8]
 - 21 **Hung KH**, Yang HB, Cheng HC, Wu JJ, Sheu BS. Short-term celecoxib to regress long-term persistent gastric intestinal metaplasia after Helicobacter pylori eradication. *J Gastroenterol Hepatol* 2010; **25**: 48-53 [PMID: 19793174 DOI: 10.1111/j.1440-1746.2009.05974.x]
 - 22 **Sheu BS**, Tsai YC, Wu CT, Chang WL, Cheng HC, Yang HB. Long-term celecoxib can prevent the progression of persistent gastric intestinal metaplasia After H. pylori eradication. *Helicobacter* 2013; **18**: 117-123 [PMID: 23067366 DOI: 10.1111/hel.12013]
 - 23 **Yang HB**, Cheng HC, Sheu BS, Hung KH, Liou MF, Wu JJ. Chronic celecoxib users more often show regression of gastric intestinal metaplasia after Helicobacter pylori eradication. *Aliment Pharmacol Ther* 2007; **25**: 455-461 [PMID: 17270001 DOI: 10.1111/j.1365-2036.2006.03224.x]
 - 24 **Zhang LJ**, Wang SY, Huo XH, Zhu ZL, Chu JK, Ma JC, Cui DS, Gu P, Zhao ZR, Wang MW, Yu J. Anti-Helicobacter pylori therapy followed by celecoxib on progression of gastric precancerous lesions. *World J Gastroenterol* 2009; **15**: 2731-2738 [PMID: 19522023 DOI: 10.3748/wjg.15.2731]
 - 25 **Wong BC**, Zhang L, Ma JL, Pan KF, Li JY, Shen L, Liu WD, Feng GS, Zhang XD, Li J, Lu AP, Xia HH, Lam S, You WC. Effects of selective COX-2 inhibitor and Helicobacter pylori eradication on precancerous gastric lesions. *Gut* 2012; **61**: 812-818 [PMID: 21917649 DOI: 10.1136/gut.2011.241111]

- 10.1136/gutjnl-2011-300154]
- 26 **Dixon MF**, Genta RM, Yardley JH, Correa P. Classification and grading of gastritis. The updated Sydney System. International Workshop on the Histopathology of Gastritis, Houston 1994. *Am J Surg Pathol* 1996; **20**: 1161-1181 [PMID: 8827022 DOI: 10.1097/00000478-199610000-00001]
 - 27 **Dixon MF**. Gastrointestinal epithelial neoplasia: Vienna revisited. *Gut* 2002; **51**: 130-131 [PMID: 12077106 DOI: 10.1136/gut.51.1.130]
 - 28 **Rugge M**, Genta RM. Staging and grading of chronic gastritis. *Hum Pathol* 2005; **36**: 228-233 [PMID: 15791566 DOI: 10.1016/j.humpath.2004.12.008]
 - 29 **Capelle LG**, de Vries AC, Haringsma J, Ter Borg F, de Vries RA, Bruno MJ, van Dekken H, Meijer J, van Grieken NC, Kuipers EJ. The staging of gastritis with the OLGA system by using intestinal metaplasia as an accurate alternative for atrophic gastritis. *Gastrointest Endosc* 2010; **71**: 1150-1158 [PMID: 20381801 DOI: 10.1016/j.gie.2009.12.029]
 - 30 **Yang P**, Zhou Y, Chen B, Wan HW, Jia GQ, Bai HL, Wu XT. Aspirin use and the risk of gastric cancer: a meta-analysis. *Dig Dis Sci* 2010; **55**: 1533-1539 [PMID: 19672710 DOI: 10.1007/s10620-009-0915-0]
 - 31 **Futagami S**, Suzuki K, Hiratsuka T, Shindo T, Hamamoto T, Ueki N, Kusunoki M, Miyake K, Gudis K, Tsukui T, Sakamoto C. Chemopreventive effect of celecoxib in gastric cancer. *Inflammopharmacology* 2007; **15**: 1-4 [PMID: 17323186 DOI: 10.1007/s10787-006-1541-5]
 - 32 **Fu SL**, Wu YL, Zhang YP, Qiao MM, Chen Y. Anti-cancer effects of COX-2 inhibitors and their correlation with angiogenesis and invasion in gastric cancer. *World J Gastroenterol* 2004; **10**: 1971-1974 [PMID: 15222049 DOI: 10.3748/wjg.v10.i13.1971]
 - 33 **Nam KT**, Hahm KB, Oh SY, Yeo M, Han SU, Ahn B, Kim YB, Kang JS, Jang DD, Yang KH, Kim DY. The selective cyclooxygenase-2 inhibitor nimesulide prevents *Helicobacter pylori*-associated gastric cancer development in a mouse model. *Clin Cancer Res* 2004; **10**: 8105-8113 [PMID: 15585646 DOI: 10.1158/1078-0432.CCR-04-0896]
 - 34 **Shiotani A**, Cen P, Graham DY. Eradication of gastric cancer is now both possible and practical. *Semin Cancer Biol* 2013; **23**: 492-501 [PMID: 23876852 DOI: 10.1016/j.semcancer.2013.07.004]
 - 35 **Graham DY**. *Helicobacter pylori* update: gastric cancer, reliable therapy, and possible benefits. *Gastroenterology* 2015; **148**: 719-31.e3 [PMID: 25655557 DOI: 10.1053/j.gastro.2015.01.040]
 - 36 **Lue HC**, Su YC, Lin SJ, Huang YC, Chang YH, Lin IH, Yang SP. Taipei consensus on integrative traditional Chinese and Western Medicine. *J Formos Med Assoc* 2021; **120**: 34-47 [PMID: 32151487 DOI: 10.1016/j.jfma.2020.02.005]
 - 37 **Chen X**, Dai YK, Zhang YZ, Liu FB, Lan SY, Wang SS, Hu L, Li PW. Efficacy of traditional Chinese Medicine for gastric precancerous lesion: A meta-analysis of randomized controlled trials. *Complement Ther Clin Pract* 2020; **38**: 101075 [PMID: 31783342 DOI: 10.1016/j.ctcp.2019.101075]
 - 38 **Malfertheiner P**, Megraud F, O'Morain CA, Gisbert JP, Kuipers EJ, Axon AT, Bazzoli F, Gasbarrini A, Atherton J, Graham DY, Hunt R, Moayyedi P, Rokkas T, Rugge M, Selgrad M, Suerbaum S, Sugano K, El-Omar EM; European *Helicobacter* and Microbiota Study Group and Consensus panel. Management of *Helicobacter pylori* infection-the Maastricht V/Florence Consensus Report. *Gut* 2017; **66**: 6-30 [PMID: 27707777 DOI: 10.1136/gutjnl-2016-312288]
 - 39 **Yue H**, Shan L, Bin L. The significance of OLGA and OLGIM staging systems in the risk assessment of gastric cancer: a systematic review and meta-analysis. *Gastric Cancer* 2018; **21**: 579-587 [PMID: 29460004 DOI: 10.1007/s10120-018-0812-3]
 - 40 **Kang JM**, Kim N, Shin CM, Lee HS, Lee DH, Jung HC, Song IS. Predictive factors for improvement of atrophic gastritis and intestinal metaplasia after *Helicobacter pylori* eradication: a three-year follow-up study in Korea. *Helicobacter* 2012; **17**: 86-95 [DOI: 10.1111/j.1523-5378.2011.00918.x]
 - 41 **Correa P**, Haenszel W, Cuello C, Zavala D, Fontham E, Zarama G, Tannenbaum S, Collazos T, Ruiz B. Gastric precancerous process in a high risk population: cohort follow-up. *Cancer Res* 1990; **50**: 4737-4740 [PMID: 2369748]
 - 42 **Hwang YJ**, Kim N, Lee HS, Lee JB, Choi YJ, Yoon H, Shin CM, Park YS, Lee DH. Reversibility of atrophic gastritis and intestinal metaplasia after *Helicobacter pylori* eradication - a prospective study for up to 10 years. *Aliment Pharmacol Ther* 2018; **47**: 380-390 [PMID: 29193217 DOI: 10.1111/apt.14424]
 - 43 **Satoh K**, Kimura K, Takimoto T, Kihira K. A follow-up study of atrophic gastritis and intestinal metaplasia after eradication of *Helicobacter pylori*. *Helicobacter* 1998; **3**: 236-240 [PMID: 9844064]
 - 44 **Leung WK**, Lin SR, Ching JY, To KF, Ng EK, Chan FK, Lau JY, Sung JJ. Factors predicting progression of gastric intestinal metaplasia: results of a randomised trial on *Helicobacter pylori* eradication. *Gut* 2004; **53**: 1244-1249 [DOI: 10.1136/gut.2003.034629]
 - 45 **Lu W**, Ni Z, Jiang S, Tong M, Zhang J, Zhao J, Feng C, Jia Q, Wang J, Yao T, Ning H, Shi Y. Resveratrol inhibits bile acid-induced gastric intestinal metaplasia via the PI3K/AKT/p-FoxO4 signalling pathway. *Phytother Res* 2021; **35**: 1495-1507 [PMID: 33103284 DOI: 10.1002/ptr.6915]
 - 46 **Correa P**, Fontham ET, Bravo JC, Bravo LE, Ruiz B, Zarama G, Realpe JL, Malcom GT, Li D, Johnson WD, Mera R. Chemoprevention of gastric dysplasia: randomized trial of antioxidant supplements and anti-*helicobacter pylori* therapy. *J Natl Cancer Inst* 2000; **92**: 1881-1888 [PMID: 11106679 DOI: 10.1093/jnci/92.23.1881]
 - 47 **Tang XD**, Zhou LY, Zhang ST, Xu YQ, Cui QC, Li L, Lu JJ, Li P, Lu F, Wang FY, Wang P, Bian LQ, Bian ZX. Randomized double-blind clinical trial of Moluodan () for the treatment of chronic atrophic gastritis with dysplasia. *Chin J Integr Med* 2016; **22**: 9-18 [PMID: 26424292 DOI: 10.1007/s11655-015-2114-5]



Published by **Baishideng Publishing Group Inc**
7041 Koll Center Parkway, Suite 160, Pleasanton, CA 94566, USA

Telephone: +1-925-3991568

E-mail: bpgoffice@wjgnet.com

Help Desk: <https://www.f6publishing.com/helpdesk>

<https://www.wjgnet.com>

