

World Journal of *Clinical Cases*

World J Clin Cases 2021 December 6; 9(34): 10392-10745



Contents

Thrice Monthly Volume 9 Number 34 December 6, 2021

OPINION REVIEW

- 10392** Regulating monocyte infiltration and differentiation: Providing new therapies for colorectal cancer patients with COVID-19

Bai L, Yang W, Qian L, Cui JW

REVIEW

- 10400** Role of circular RNAs in gastrointestinal tumors and drug resistance

Xi SJ, Cai WQ, Wang QQ, Peng XC

MINIREVIEWS

- 10418** Liver injury associated with acute pancreatitis: The current status of clinical evaluation and involved mechanisms

Liu W, Du JJ, Li ZH, Zhang XY, Zuo HD

- 10430** Association between celiac disease and vitiligo: A review of the literature

Zhang JZ, Abudoureyimu D, Wang M, Yu SR, Kang XJ

- 10438** Role of immune escape in different digestive tumours

Du XZ, Wen B, Liu L, Wei YT, Zhao K

ORIGINAL ARTICLE

Basic Study

- 10451** Magnolol protects against acute gastrointestinal injury in sepsis by down-regulating regulated on activation, normal T-cell expressed and secreted

Mao SH, Feng DD, Wang X, Zhi YH, Lei S, Xing X, Jiang RL, Wu JN

Case Control Study

- 10464** Effect of Nephritis Rehabilitation Tablets combined with tacrolimus in treatment of idiopathic membranous nephropathy

Ly W, Wang MR, Zhang CZ, Sun XX, Yan ZZ, Hu XM, Wang TT

Retrospective Cohort Study

- 10472** Lamb's tripe extract and vitamin B₁₂ capsule plus celecoxib reverses intestinal metaplasia and atrophy: A retrospective cohort study

Wu SR, Liu J, Zhang LF, Wang N, Zhang LY, Wu Q, Liu JY, Shi YQ

- 10484** Clinical features and survival of patients with multiple primary malignancies

Wang XK, Zhou MH

Retrospective Study

- 10494** Thoracoscopic segmentectomy and lobectomy assisted by three-dimensional computed-tomography bronchography and angiography for the treatment of primary lung cancer
Wu YJ, Shi QT, Zhang Y, Wang YL
- 10507** Endoscopic ultrasound fine needle aspiration *vs* fine needle biopsy in solid lesions: A multi-center analysis
Moura DTH, McCarty TR, Jirapinyo P, Ribeiro IB, Farias GFA, Madruga-Neto AC, Ryou M, Thompson CC
- 10518** Resection of bilateral occipital lobe lesions during a single operation as a treatment for bilateral occipital lobe epilepsy
Lyu YE, Xu XF, Dai S, Feng M, Shen SP, Zhang GZ, Ju HY, Wang Y, Dong XB, Xu B
- 10530** Improving rehabilitation and quality of life after percutaneous transhepatic cholangiography drainage with a rapid rehabilitation model
Xia LL, Su T, Li Y, Mao JF, Zhang QH, Liu YY
- 10540** Combined lumbar muscle block and perioperative comprehensive patient-controlled intravenous analgesia with butorphanol in gynecological endoscopic surgery
Zhu RY, Xiang SQ, Chen DR
- 10549** Teicoplanin combined with conventional vancomycin therapy for the treatment of pulmonary methicillin-resistant *Staphylococcus aureus* and *Staphylococcus epidermidis* infections
Wu W, Liu M, Geng JJ, Wang M
- 10557** Application of narrative nursing in the families of children with biliary atresia: A retrospective study
Zhang LH, Meng HY, Wang R, Zhang YC, Sun J

Observational Study

- 10566** Comparative study for predictability of type 1 gastric variceal rebleeding after endoscopic variceal ligation: High-frequency intraluminal ultrasound study
Kim JH, Choe WH, Lee SY, Kwon SY, Sung IK, Park HS
- 10576** Effects of WeChat platform-based health management on health and self-management effectiveness of patients with severe chronic heart failure
Wang ZR, Zhou JW, Liu XP, Cai GJ, Zhang QH, Mao JF
- 10585** Early cardiopulmonary resuscitation on serum levels of myeloperoxidase, soluble ST2, and hypersensitive C-reactive protein in acute myocardial infarction patients
Hou M, Ren YP, Wang R, Lu LX

Prospective Study

- 10595** Remimazolam benzenesulfonate anesthesia effectiveness in cardiac surgery patients under general anesthesia
Tang F, Yi JM, Gong HY, Lu ZY, Chen J, Fang B, Chen C, Liu ZY

Randomized Clinical Trial

- 10604** Effects of lower body positive pressure treadmill on functional improvement in knee osteoarthritis: A randomized clinical trial study
Chen HX, Zhan YX, Ou HN, You YY, Li WY, Jiang SS, Zheng MF, Zhang LZ, Chen K, Chen QX

SYSTEMATIC REVIEWS

- 10616** Effects of hypoxia on bone metabolism and anemia in patients with chronic kidney disease
Kan C, Lu X, Zhang R

META-ANALYSIS

- 10626** Intracuff alkalinized lidocaine to prevent postoperative airway complications: A meta-analysis
Chen ZX, Shi Z, Wang B, Zhang Y

CASE REPORT

- 10638** Rarely fast progressive memory loss diagnosed as Creutzfeldt-Jakob disease: A case report
Xu YW, Wang JQ, Zhang W, Xu SC, Li YX
- 10645** Diagnosis, fetal risk and treatment of pemphigoid gestationis in pregnancy: A case report
Jiao HN, Ruan YP, Liu Y, Pan M, Zhong HP
- 10652** Histology transformation-mediated pathological atypism in small-cell lung cancer within the presence of chemotherapy: A case report
Ju Q, Wu YT, Zhang Y, Yang WH, Zhao CL, Zhang J
- 10659** Reversible congestive heart failure associated with hypocalcemia: A case report
Wang C, Dou LW, Wang TB, Guo Y
- 10666** Excimer laser coronary atherectomy for a severe calcified coronary ostium lesion: A case report
Hou FJ, Ma XT, Zhou YJ, Guan J
- 10671** Comprehensive management of malocclusion in maxillary fibrous dysplasia: A case report
Kaur H, Mohanty S, Kochhar GK, Iqbal S, Verma A, Bhasin R, Kochhar AS
- 10681** Intravascular papillary endothelial hyperplasia as a rare cause of cervicothoracic spinal cord compression: A case report
Gu HL, Zheng XQ, Zhan SQ, Chang YB
- 10689** Proximal true lumen collapse in a chronic type B aortic dissection patient: A case report
Zhang L, Guan WK, Wu HP, Li X, Lv KP, Zeng CL, Song HH, Ye QL
- 10696** Tigecycline sclerotherapy for recurrent pseudotumor in aseptic lymphocyte-dominant vasculitis-associated lesion after metal-on-metal total hip arthroplasty: A case report
Lin IH, Tsai CH

- 10702** Acute myocardial infarction induced by eosinophilic granulomatosis with polyangiitis: A case report
Jiang XD, Guo S, Zhang WM
- 10708** Aggressive natural killer cell leukemia with skin manifestation associated with hemophagocytic lymphohistiocytosis: A case report
Peng XH, Zhang LS, Li LJ, Guo XJ, Liu Y
- 10715** Chronic lymphocytic leukemia/small lymphocytic lymphoma complicated with skin Langerhans cell sarcoma: A case report
Li SY, Wang Y, Wang LH
- 10723** Severe mediastinitis and pericarditis after endobronchial ultrasound-guided transbronchial needle aspiration: A case report
Koh JS, Kim YJ, Kang DH, Lee JE, Lee SI
- 10728** Obturator hernia - a rare etiology of lateral thigh pain: A case report
Kim JY, Chang MC
- 10733** Tracheal tube misplacement in the thoracic cavity: A case report
Li KX, Luo YT, Zhou L, Huang JP, Liang P
- 10738** Peri-implant keratinized gingiva augmentation using xenogeneic collagen matrix and platelet-rich fibrin: A case report
Han CY, Wang DZ, Bai JF, Zhao LL, Song WZ

ABOUT COVER

Editorial Board Member of *World Journal of Clinical Cases*, Gagan Mathur, MBBS, MD, Associate Professor, Director, Staff Physician, Department of Pathology, Saint Luke's Health System, Kansas City, MO 64112, United States. gmathur@saint-lukes.org

AIMS AND SCOPE

The primary aim of *World Journal of Clinical Cases* (WJCC, *World J Clin Cases*) is to provide scholars and readers from various fields of clinical medicine with a platform to publish high-quality clinical research articles and communicate their research findings online.

WJCC mainly publishes articles reporting research results and findings obtained in the field of clinical medicine and covering a wide range of topics, including case control studies, retrospective cohort studies, retrospective studies, clinical trials studies, observational studies, prospective studies, randomized controlled trials, randomized clinical trials, systematic reviews, meta-analysis, and case reports.

INDEXING/ABSTRACTING

The WJCC is now indexed in Science Citation Index Expanded (also known as SciSearch®), Journal Citation Reports/Science Edition, Scopus, PubMed, and PubMed Central. The 2021 Edition of Journal Citation Reports® cites the 2020 impact factor (IF) for WJCC as 1.337; IF without journal self cites: 1.301; 5-year IF: 1.742; Journal Citation Indicator: 0.33; Ranking: 119 among 169 journals in medicine, general and internal; and Quartile category: Q3. The WJCC's CiteScore for 2020 is 0.8 and Scopus CiteScore rank 2020: General Medicine is 493/793.

RESPONSIBLE EDITORS FOR THIS ISSUE

Production Editor: Yan-Xia Xing; Production Department Director: Yun-Jie Ma; Editorial Office Director: Jin-Lei Wang.

NAME OF JOURNAL

World Journal of Clinical Cases

ISSN

ISSN 2307-8960 (online)

LAUNCH DATE

April 16, 2013

FREQUENCY

Thrice Monthly

EDITORS-IN-CHIEF

Dennis A Bloomfield, Sandro Vento, Bao-Gan Peng

EDITORIAL BOARD MEMBERS

<https://www.wjgnet.com/2307-8960/editorialboard.htm>

PUBLICATION DATE

December 6, 2021

COPYRIGHT

© 2021 Baishideng Publishing Group Inc

INSTRUCTIONS TO AUTHORS

<https://www.wjgnet.com/bpg/gerinfo/204>

GUIDELINES FOR ETHICS DOCUMENTS

<https://www.wjgnet.com/bpg/GerInfo/287>

GUIDELINES FOR NON-NATIVE SPEAKERS OF ENGLISH

<https://www.wjgnet.com/bpg/gerinfo/240>

PUBLICATION ETHICS

<https://www.wjgnet.com/bpg/GerInfo/288>

PUBLICATION MISCONDUCT

<https://www.wjgnet.com/bpg/gerinfo/208>

ARTICLE PROCESSING CHARGE

<https://www.wjgnet.com/bpg/gerinfo/242>

STEPS FOR SUBMITTING MANUSCRIPTS

<https://www.wjgnet.com/bpg/GerInfo/239>

ONLINE SUBMISSION

<https://www.f6publishing.com>



Excimer laser coronary atherectomy for a severe calcified coronary ostium lesion: A case report

Fang-Jie Hou, Xiao-Teng Ma, Yu-Jie Zhou, Jun Guan

ORCID number: Fang-Jie Hou 0000-0002-4859-9804; Xiao-Teng Ma 0000-0003-4806-6458; Yu-Jie Zhou 0000-0002-9545-1984; Jun Guan 0000-0001-9642-1595.

Author contributions: Hou FJ followed up the patient and was a major contributor to manuscript writing; Guan J, Zhou YJ and Ma XT analyzed the patient data and angiography data; all authors read and approved the final manuscript.

Informed consent statement: Informed written consent was obtained from the patient for publication of this report and any accompanying images.

Conflict-of-interest statement: The authors declare that they have no conflict of interest.

CARE Checklist (2016) statement: The authors have read the CARE Checklist(2016), and the manuscript was prepared and revised according to the CARE Checklist (2016).

Country/Territory of origin: China

Specialty type: Medicine, research and experimental

Provenance and peer review: Unsolicited article; Externally peer reviewed.

Peer-review report's scientific

Fang-Jie Hou, Jun Guan, Department of Cardiology, Qingdao Municipal Hospital, Qingdao 266000, Shandong Province, China

Fang-Jie Hou, Xiao-Teng Ma, Yu-Jie Zhou, Department of Cardiology, Beijing Anzhen Hospital, Capital Medical University, Beijing 100029, China

Corresponding author: Jun Guan, MD, Dean, Doctor, Professor, Department of Cardiology, Qingdao Municipal Hospital, No. 1 Jiaozhou Road, Qingdao 266000, Shandong Province, China. guanjunsly@163.com

Abstract

BACKGROUND

Percutaneous coronary intervention can be challenging for ostial coronary artery lesions due to calcium burden and elastic fiber content. Excimer laser coronary atherectomy (ELCA) is a less common treatment for severe calcified coronary ostium lesions.

CASE SUMMARY

An 81-year-old male presented to the Cardiology Department of Qingdao Municipal Hospital with a 1-year history of chest pain. Coronary angiography showed severe calcific stenosis (approximately 90%) in the right coronary artery ostium. The right coronary artery ostium was unable to be advanced using a 2.5 mm × 12.0 mm balloon (NC Sprinter, Medtronic, United States) or dilated using a 2.0 mm × 12.0 mm balloon (Sprinter, Medtronic, United States). The patient underwent successful ELCA and balloon dilation of the calcified coronary ostium lesion.

CONCLUSION

ELCA appears to be a safe and effective treatment for the management of severe calcified coronary ostium lesions.

Key Words: Excimer laser coronary atherectomy; Coronary ostium lesion; Coronary calcified lesion; Intravascular ultrasound; Case report

©The Author(s) 2021. Published by Baishideng Publishing Group Inc. All rights reserved.

quality classification

Grade A (Excellent): 0
 Grade B (Very good): 0
 Grade C (Good): C
 Grade D (Fair): 0
 Grade E (Poor): 0

Open-Access: This article is an open-access article that was selected by an in-house editor and fully peer-reviewed by external reviewers. It is distributed in accordance with the Creative Commons Attribution NonCommercial (CC BY-NC 4.0) license, which permits others to distribute, remix, adapt, build upon this work non-commercially, and license their derivative works on different terms, provided the original work is properly cited and the use is non-commercial. See: <http://creativecommons.org/licenses/by-nc/4.0/>

Received: April 6, 2021

Peer-review started: April 6, 2021

First decision: July 5, 2021

Revised: July 12, 2021

Accepted: October 25, 2021

Article in press: October 25, 2021

Published online: December 6, 2021

P-Reviewer: Matsuo Y

S-Editor: Fan JR

L-Editor: A

P-Editor: Fan JR



Core Tip: In the presented case, coronary angiography showed severe calcific stenosis (approximately 90%) in the right coronary artery ostium. A 2.5 mm × 12.0 mm balloon was unable to be advanced into the lesion, while a 2.0 mm × 12.0 mm balloon could not be inflated in the right ostium. Intravascular ultrasonography revealed severe calcifications. The patient underwent an excimer laser coronary atherectomy (ELCA) and balloon dilation, and remained asymptomatic during the 12-mo follow-up. This is the first case report of the successful use of ELCA and small balloon dilatation in treating a severely calcified cardiac ostium lesion.

Citation: Hou FJ, Ma XT, Zhou YJ, Guan J. Excimer laser coronary atherectomy for a severe calcified coronary ostium lesion: A case report. *World J Clin Cases* 2021; 9(34): 10666-10670

URL: <https://www.wjgnet.com/2307-8960/full/v9/i34/10666.htm>

DOI: <https://dx.doi.org/10.12998/wjcc.v9.i34.10666>

INTRODUCTION

Excimer laser coronary atherectomy (ELCA) has emerged as a key procedure that can modify coronary plaques. ELCA achieves its therapeutic efficacy primarily through its photochemical, photothermal, and photomechanical actions. It was reported by Phillips that there were approximately 50000 ELCA catheters used during the period of 2010–2019[1]. However, reports on the use of ELCA in treating heavily calcified coronary lesions are scarce.

CASE PRESENTATION

Chief complaints

An 81-year-old male presented to the Cardiology Department of Qingdao Municipal Hospital with a 1-year history of chest pain.

History of present illness

Coronary angiography (CAG) carried out in a separate center three months earlier noted severe calcific stenosis (approximately 90%) in the right coronary artery (RCA) ostium, 90% stenosis in the proximal left circumflex artery, and 90% stenosis in the proximal left anterior descending artery. The patient declined coronary artery bypass grafting. Stent insertion was then performed in each of the occluded arteries. However, the RCA ostium was unable to be advanced using a 2.5 mm × 12.0 mm balloon (NC Sprinter, Medtronic, United States) or dilated using a 2.0 mm × 12.0 mm balloon (Sprinter, Medtronic, United States). The patient still had persistent angina pectoris despite the insertion of two stents.

History of past illness

The patient had hypertension for more than 30 years, diabetes mellitus for over 7 years, and had no history of smoking.

Personal and family history

The patient had no personal or family history.

Physical examination

No positive signs were found during the physical examination.

Laboratory examinations

No abnormalities were found during laboratory examinations.

Imaging examinations

Percutaneous coronary intervention was performed for the RCA ostium lesion after informed consent was obtained from the patient. The radial artery was cannulated using a 6-Fr SAL1.0 guiding catheter (Medtronic, United States). The distal RCA was

then cannulated with a Balance Middle Weight Universal II guidewire (Abbott, United States). Intravascular ultrasonography (IVUS; Boston Scientific, United States) was performed and identified severe calcifications (Figure 1A-D).

FINAL DIAGNOSIS

CAG and IVUS revealed severe calcific stenosis in the RCA ostium.

TREATMENT

A 0.9 mm eccentric catheter (Spectranetics, United States) was used to initiate ELCA at 45/60, 60/80, and 80/80 (fluence/Hz) in sequence. This initially resulted in no progress. A 1.5 mm × 15.0 mm balloon (Sprinter, Medtronic, United States) was adopted to dilate the lesion at 10–12 atm. At 45/60 (fluence/Hz), the catheter was slowly passed through the lesion (Figure 1E). The laser catheter was inserted at a speed of less than 0.5–1.0 mm/s using a “saline flush” technique. Normal saline was flushed into the guiding catheter and manifold before laser treatment, and a 5–10 mL bolus of saline was injected prior to each train of laser pulses through the guiding catheter. Continuous saline flushing at a rate of 1–2 mL/s was performed during laser treatment[2,3]. The lesion was then successfully dilated using a 2.5 mm × 12 mm balloon (NC Sprinter, Medtronic, United States). One 3.50 mm × 18.00 mm stent (Xience Xpediton; Abbott) was placed at 12 atm (Figure 1F). The stent was deployed at 14–20 atm to perform post-dilation with a 3.5 mm × 12.0 mm balloon. Stent placements were evaluated with CAG, and the final IVUS findings demonstrated no obvious dissection, malposition, or under expansion (Figure 1G-J).

OUTCOME AND FOLLOW-UP

The patient was healthy and asymptomatic after operation during hospitalization and remained asymptomatic during the 1, 3, 6, and 12-mo follow-up visits.

DISCUSSION

Coronary artery ostial lesions are barriers to the percutaneous coronary interventions, especially in the presence of severe calcifications. In most cases, severe coronary artery calcifications cannot be crossed or expanded with balloons despite the successful advancement of the guidewire distal to the lesion. ELCA and rotational atherectomy are the two treatments that are effective in managing severe coronary artery calcifications. The risk of no reflow is very low because most of the particles produced by ELCA are less than 10 µm in diameter, which can easily be filtered by the reticuloendothelial system[4]. The dissection of ostium lesions is likely to cause more serious consequences. The use of 308 nm pulsed ultraviolet light reduces the risk of vessel perforation and dissection, given its shallow penetration depth. Most standard 0.014-inch guidewires are compatible with ELCA. Lesions that are unable to be cannulated or expanded may benefit from the use of a 0.9 mm X-80 catheter with a maximum fluence (energy) of 80 mJ/mm² and repetition rate of 80 Hz, both of which are attainable using a 10 s on and 5 s off laser cycle[1]. Calcified lesions are amenable to treatment with a 0.9 mm excimer laser catheter bringing increased density of energy while conserving the production of heat, which results in a smaller ablated area. The laser catheter pushing speed should be less than 0.5–1.0 mm/s to avoid production of large particles.

Currently, ELCA is commonly used in highly complex lesions, including saphenous vein grafts, calcifications, tortuosity (moderate/severe), in-stent restenosis, and bifurcations, and carries the dual benefit of low rates of major adverse cardiovascular complications and high technical and procedural success rates[5,6]. We present the first case of a severe calcified ostium lesion treated with ELCA and balloon dilatation. During the ELCA procedure, if the catheter cannot pass through the lesion smoothly, balloon dilatation can be used to change the plaque morphology and achieve better results. Although ELCA may not be the first choice for severe calcified coronary

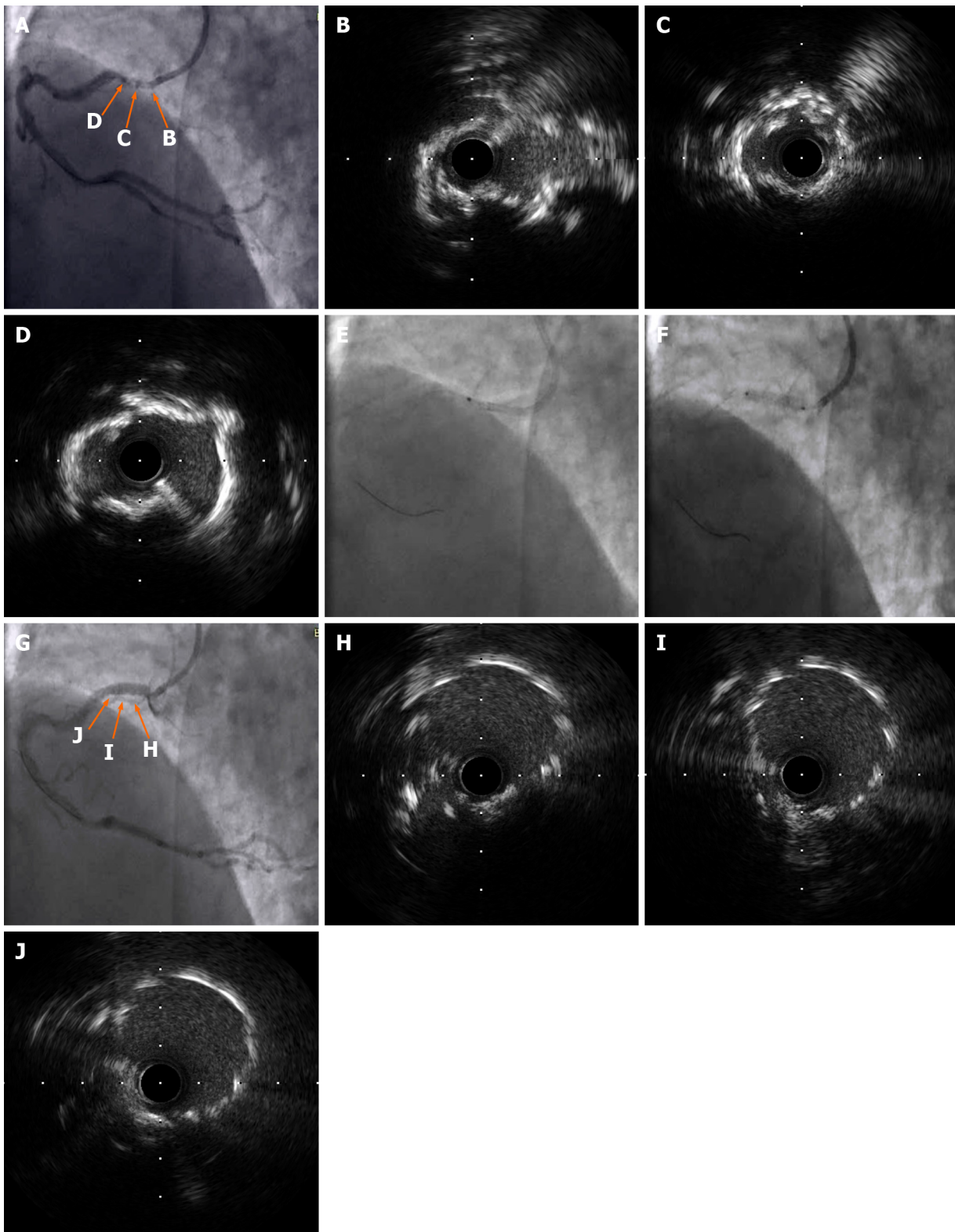


Figure 1 Intravascular ultrasonography findings. A–D: Intravascular ultrasonography (IVUS) was performed after the laser catheter passed through the lesion and severe calcifications were noted; E and F: The laser catheter was slowly passed through the lesion and the stent was placed at 12 atm; G–J: The final IVUS findings showed no apparent dissection, malapposition, or underexpansion.

ostium lesions as compared to rotational atherectomy, it may be used as an alternative in the following cases: Thrombus, severe tortuosity, bifurcation, ostial coronary artery dissection, the failure of a Rotawire to pass through the target lesion, and severe heart failure. We successfully treated a severe calcified coronary ostium lesion by ELCA and small balloon dilatation. Nevertheless, further studies are needed to evaluate the efficacy and safety of ELCA *vs* rotational atherectomy.

CONCLUSION

Alternative use of ELCA and small balloon dilatation appears to be a safe and effective means of managing severely calcified coronary ostium lesions.

REFERENCES

- 1 **Tsutsui RS**, Sammour Y, Kalra A, Reed G, Krishnaswamy A, Ellis S, Nair R, Khatri J, Kapadia S, Puri R. Excimer Laser Atherectomy in Percutaneous Coronary Intervention: A Contemporary Review. *Cardiovasc Revasc Med* 2021; **25**: 75-85 [PMID: [33158754](#) DOI: [10.1016/j.carrev.2020.10.016](#)]
- 2 **Shavadia JS**, Vo MN, Bainey KR. Challenges With Severe Coronary Artery Calcification in Percutaneous Coronary Intervention: A Narrative Review of Therapeutic Options. *Can J Cardiol* 2018; **34**: 1564-1572 [PMID: [30527144](#) DOI: [10.1016/j.cjca.2018.07.482](#)]
- 3 **Shibui T**, Tsuchiyama T, Masuda S, Nagamine S. Excimer laser coronary atherectomy prior to paclitaxel-coated balloon angioplasty for de novo coronary artery lesions. *Lasers Med Sci* 2021; **36**: 111-117 [PMID: [32304003](#) DOI: [10.1007/s10103-020-03019-w](#)]
- 4 **Rawlins J**, Din JN, Talwar S, O'Kane P. Coronary Intervention with the Excimer Laser: Review of the Technology and Outcome Data. *Interv Cardiol* 2016; **11**: 27-32 [PMID: [29588701](#) DOI: [10.15420/icr.2016;2:2](#)]
- 5 **Karacsonyi J**, Armstrong EJ, Truong HTD, Tsuda R, Kokkinidis DG, Martinez-Parachini JR, Alame AJ, Danek BA, Karatasakis A, Roesle M, Khalili H, Ungi I, Banerjee S, Brilakis ES, Rangan BV. Contemporary Use of Laser During Percutaneous Coronary Interventions: Insights from the Laser Veterans Affairs (LAVA) Multicenter Registry. *J Invasive Cardiol* 2018; **30**: 195-201 [PMID: [29543185](#)]
- 6 **Ojeda S**, Azzalini L, Suárez de Lezo J, Johal GS, González R, Barman N, Hidalgo F, Bellera N, Dangas G, Jurado-Román A, Kini A, Romero M, Moreno R, Garcia Del Blanco B, Mehran R, Sharma SK, Pan M. Excimer laser coronary atherectomy for uncrossable coronary lesions. A multicenter registry. *Catheter Cardiovasc Interv* 2020 [PMID: [33232583](#) DOI: [10.1002/ccd.29392](#)]



Published by **Baishideng Publishing Group Inc**
7041 Koll Center Parkway, Suite 160, Pleasanton, CA 94566, USA

Telephone: +1-925-3991568

E-mail: bpgoffice@wjgnet.com

Help Desk: <https://www.f6publishing.com/helpdesk>

<https://www.wjgnet.com>

