

World Journal of *Clinical Cases*

World J Clin Cases 2021 December 6; 9(34): 10392-10745



Contents

Thrice Monthly Volume 9 Number 34 December 6, 2021

OPINION REVIEW

- 10392** Regulating monocyte infiltration and differentiation: Providing new therapies for colorectal cancer patients with COVID-19

Bai L, Yang W, Qian L, Cui JW

REVIEW

- 10400** Role of circular RNAs in gastrointestinal tumors and drug resistance

Xi SJ, Cai WQ, Wang QQ, Peng XC

MINIREVIEWS

- 10418** Liver injury associated with acute pancreatitis: The current status of clinical evaluation and involved mechanisms

Liu W, Du JJ, Li ZH, Zhang XY, Zuo HD

- 10430** Association between celiac disease and vitiligo: A review of the literature

Zhang JZ, Abudoureyimu D, Wang M, Yu SR, Kang XJ

- 10438** Role of immune escape in different digestive tumours

Du XZ, Wen B, Liu L, Wei YT, Zhao K

ORIGINAL ARTICLE

Basic Study

- 10451** Magnolol protects against acute gastrointestinal injury in sepsis by down-regulating regulated on activation, normal T-cell expressed and secreted

Mao SH, Feng DD, Wang X, Zhi YH, Lei S, Xing X, Jiang RL, Wu JN

Case Control Study

- 10464** Effect of Nephritis Rehabilitation Tablets combined with tacrolimus in treatment of idiopathic membranous nephropathy

Ly W, Wang MR, Zhang CZ, Sun XX, Yan ZZ, Hu XM, Wang TT

Retrospective Cohort Study

- 10472** Lamb's tripe extract and vitamin B₁₂ capsule plus celecoxib reverses intestinal metaplasia and atrophy: A retrospective cohort study

Wu SR, Liu J, Zhang LF, Wang N, Zhang LY, Wu Q, Liu JY, Shi YQ

- 10484** Clinical features and survival of patients with multiple primary malignancies

Wang XK, Zhou MH

Retrospective Study

- 10494** Thoracoscopic segmentectomy and lobectomy assisted by three-dimensional computed-tomography bronchography and angiography for the treatment of primary lung cancer
Wu YJ, Shi QT, Zhang Y, Wang YL
- 10507** Endoscopic ultrasound fine needle aspiration *vs* fine needle biopsy in solid lesions: A multi-center analysis
Moura DTH, McCarty TR, Jirapinyo P, Ribeiro IB, Farias GFA, Madruga-Neto AC, Ryou M, Thompson CC
- 10518** Resection of bilateral occipital lobe lesions during a single operation as a treatment for bilateral occipital lobe epilepsy
Lyu YE, Xu XF, Dai S, Feng M, Shen SP, Zhang GZ, Ju HY, Wang Y, Dong XB, Xu B
- 10530** Improving rehabilitation and quality of life after percutaneous transhepatic cholangiography drainage with a rapid rehabilitation model
Xia LL, Su T, Li Y, Mao JF, Zhang QH, Liu YY
- 10540** Combined lumbar muscle block and perioperative comprehensive patient-controlled intravenous analgesia with butorphanol in gynecological endoscopic surgery
Zhu RY, Xiang SQ, Chen DR
- 10549** Teicoplanin combined with conventional vancomycin therapy for the treatment of pulmonary methicillin-resistant *Staphylococcus aureus* and *Staphylococcus epidermidis* infections
Wu W, Liu M, Geng JJ, Wang M
- 10557** Application of narrative nursing in the families of children with biliary atresia: A retrospective study
Zhang LH, Meng HY, Wang R, Zhang YC, Sun J

Observational Study

- 10566** Comparative study for predictability of type 1 gastric variceal rebleeding after endoscopic variceal ligation: High-frequency intraluminal ultrasound study
Kim JH, Choe WH, Lee SY, Kwon SY, Sung IK, Park HS
- 10576** Effects of WeChat platform-based health management on health and self-management effectiveness of patients with severe chronic heart failure
Wang ZR, Zhou JW, Liu XP, Cai GJ, Zhang QH, Mao JF
- 10585** Early cardiopulmonary resuscitation on serum levels of myeloperoxidase, soluble ST2, and hypersensitive C-reactive protein in acute myocardial infarction patients
Hou M, Ren YP, Wang R, Lu LX

Prospective Study

- 10595** Remimazolam benzenesulfonate anesthesia effectiveness in cardiac surgery patients under general anesthesia
Tang F, Yi JM, Gong HY, Lu ZY, Chen J, Fang B, Chen C, Liu ZY

Randomized Clinical Trial

- 10604** Effects of lower body positive pressure treadmill on functional improvement in knee osteoarthritis: A randomized clinical trial study
Chen HX, Zhan YX, Ou HN, You YY, Li WY, Jiang SS, Zheng MF, Zhang LZ, Chen K, Chen QX

SYSTEMATIC REVIEWS

- 10616** Effects of hypoxia on bone metabolism and anemia in patients with chronic kidney disease
Kan C, Lu X, Zhang R

META-ANALYSIS

- 10626** Intracuff alkalinized lidocaine to prevent postoperative airway complications: A meta-analysis
Chen ZX, Shi Z, Wang B, Zhang Y

CASE REPORT

- 10638** Rarely fast progressive memory loss diagnosed as Creutzfeldt-Jakob disease: A case report
Xu YW, Wang JQ, Zhang W, Xu SC, Li YX
- 10645** Diagnosis, fetal risk and treatment of pemphigoid gestationis in pregnancy: A case report
Jiao HN, Ruan YP, Liu Y, Pan M, Zhong HP
- 10652** Histology transformation-mediated pathological atypism in small-cell lung cancer within the presence of chemotherapy: A case report
Ju Q, Wu YT, Zhang Y, Yang WH, Zhao CL, Zhang J
- 10659** Reversible congestive heart failure associated with hypocalcemia: A case report
Wang C, Dou LW, Wang TB, Guo Y
- 10666** Excimer laser coronary atherectomy for a severe calcified coronary ostium lesion: A case report
Hou FJ, Ma XT, Zhou YJ, Guan J
- 10671** Comprehensive management of malocclusion in maxillary fibrous dysplasia: A case report
Kaur H, Mohanty S, Kochhar GK, Iqbal S, Verma A, Bhasin R, Kochhar AS
- 10681** Intravascular papillary endothelial hyperplasia as a rare cause of cervicothoracic spinal cord compression: A case report
Gu HL, Zheng XQ, Zhan SQ, Chang YB
- 10689** Proximal true lumen collapse in a chronic type B aortic dissection patient: A case report
Zhang L, Guan WK, Wu HP, Li X, Lv KP, Zeng CL, Song HH, Ye QL
- 10696** Tigecycline sclerotherapy for recurrent pseudotumor in aseptic lymphocyte-dominant vasculitis-associated lesion after metal-on-metal total hip arthroplasty: A case report
Lin IH, Tsai CH

- 10702** Acute myocardial infarction induced by eosinophilic granulomatosis with polyangiitis: A case report
Jiang XD, Guo S, Zhang WM
- 10708** Aggressive natural killer cell leukemia with skin manifestation associated with hemophagocytic lymphohistiocytosis: A case report
Peng XH, Zhang LS, Li LJ, Guo XJ, Liu Y
- 10715** Chronic lymphocytic leukemia/small lymphocytic lymphoma complicated with skin Langerhans cell sarcoma: A case report
Li SY, Wang Y, Wang LH
- 10723** Severe mediastinitis and pericarditis after endobronchial ultrasound-guided transbronchial needle aspiration: A case report
Koh JS, Kim YJ, Kang DH, Lee JE, Lee SI
- 10728** Obturator hernia - a rare etiology of lateral thigh pain: A case report
Kim JY, Chang MC
- 10733** Tracheal tube misplacement in the thoracic cavity: A case report
Li KX, Luo YT, Zhou L, Huang JP, Liang P
- 10738** Peri-implant keratinized gingiva augmentation using xenogeneic collagen matrix and platelet-rich fibrin: A case report
Han CY, Wang DZ, Bai JF, Zhao LL, Song WZ

ABOUT COVER

Editorial Board Member of *World Journal of Clinical Cases*, Gagan Mathur, MBBS, MD, Associate Professor, Director, Staff Physician, Department of Pathology, Saint Luke's Health System, Kansas City, MO 64112, United States. gmathur@saint-lukes.org

AIMS AND SCOPE

The primary aim of *World Journal of Clinical Cases* (WJCC, *World J Clin Cases*) is to provide scholars and readers from various fields of clinical medicine with a platform to publish high-quality clinical research articles and communicate their research findings online.

WJCC mainly publishes articles reporting research results and findings obtained in the field of clinical medicine and covering a wide range of topics, including case control studies, retrospective cohort studies, retrospective studies, clinical trials studies, observational studies, prospective studies, randomized controlled trials, randomized clinical trials, systematic reviews, meta-analysis, and case reports.

INDEXING/ABSTRACTING

The WJCC is now indexed in Science Citation Index Expanded (also known as SciSearch®), Journal Citation Reports/Science Edition, Scopus, PubMed, and PubMed Central. The 2021 Edition of Journal Citation Reports® cites the 2020 impact factor (IF) for WJCC as 1.337; IF without journal self cites: 1.301; 5-year IF: 1.742; Journal Citation Indicator: 0.33; Ranking: 119 among 169 journals in medicine, general and internal; and Quartile category: Q3. The WJCC's CiteScore for 2020 is 0.8 and Scopus CiteScore rank 2020: General Medicine is 493/793.

RESPONSIBLE EDITORS FOR THIS ISSUE

Production Editor: Yan-Xia Xing, Production Department Director: Yun-Jie Ma, Editorial Office Director: Jin-Lei Wang.

NAME OF JOURNAL

World Journal of Clinical Cases

ISSN

ISSN 2307-8960 (online)

LAUNCH DATE

April 16, 2013

FREQUENCY

Thrice Monthly

EDITORS-IN-CHIEF

Dennis A Bloomfield, Sandro Vento, Bao-Gan Peng

EDITORIAL BOARD MEMBERS

<https://www.wjgnet.com/2307-8960/editorialboard.htm>

PUBLICATION DATE

December 6, 2021

COPYRIGHT

© 2021 Baishideng Publishing Group Inc

INSTRUCTIONS TO AUTHORS

<https://www.wjgnet.com/bpg/gerinfo/204>

GUIDELINES FOR ETHICS DOCUMENTS

<https://www.wjgnet.com/bpg/GerInfo/287>

GUIDELINES FOR NON-NATIVE SPEAKERS OF ENGLISH

<https://www.wjgnet.com/bpg/gerinfo/240>

PUBLICATION ETHICS

<https://www.wjgnet.com/bpg/GerInfo/288>

PUBLICATION MISCONDUCT

<https://www.wjgnet.com/bpg/gerinfo/208>

ARTICLE PROCESSING CHARGE

<https://www.wjgnet.com/bpg/gerinfo/242>

STEPS FOR SUBMITTING MANUSCRIPTS

<https://www.wjgnet.com/bpg/GerInfo/239>

ONLINE SUBMISSION

<https://www.f6publishing.com>



Comprehensive management of malocclusion in maxillary fibrous dysplasia: A case report

Harneet Kaur, Sujata Mohanty, Gulsheen Kaur Kochhar, Shahid Iqbal, Anjali Verma, Ritasha Bhasin, Anuraj Singh Kochhar

ORCID number: Harneet Kaur 0000-0002-9107-363X; Sujata Mohanty 0000-0002-1444-7191; Gulsheen Kaur Kochhar 0000-0001-5881-3512; Shahid Iqbal 0000-0001-8163-7326; Anjali Verma 0000-0002-7670-2418; Ritasha Bhasin 0000-0002-6198-7756; Anuraj Singh Kochhar 0000-0001-6611-6143.

Author contributions: Kaur H and Mohanty S contributed equally to this work; Kaur H, Kochhar GK and Iqbal S were involved in the writing of the manuscript; Kaur H and Verma A were involved in providing photographs and case followups; Bhasin R and Kochhar AS in proofreading and copyediting; all authors have read and approve the final manuscript.

Informed consent statement: All study participants, or their legal guardian, provided informed written consent prior to study enrollment.

Conflict-of-interest statement: The authors deny any conflict of interest related to this study.

CARE Checklist (2016) statement: The authors have read the CARE Checklist (2016), and the manuscript was prepared and revised according to the CARE Checklist (2016).

Harneet Kaur, Department of Orthodontics and Dentofacial Orthopaedics, Faculty of Dentistry, Jamia Millia Islamia, Delhi 110025, Delhi, India

Sujata Mohanty, Anjali Verma, Department of Oral and Maxillofacial Surgery, Maulana Azad Institute of Dental Sciences, Delhi 110002, Delhi, India

Gulsheen Kaur Kochhar, Department of Pediatric and Preventive Dentistry, National Dental College and Hospital, Derabassi 140507, Punjab, India

Shahid Iqbal, Faculty of Dentistry, Jamia Millia Islamia, Delhi 110025, Delhi, India

Ritasha Bhasin, Faculty of Dentistry, University of Toronto, Toronto M5G1G6, Ontario, Canada

Anuraj Singh Kochhar, Department of Orthodontics and Dentofacial Orthopaedics, Faculty of Dentistry, University of Toronto, Toronto M5G0C1, Ontario, Canada

Corresponding author: Anuraj Singh Kochhar, MDS, DSATP Resident, Department of Orthodontics and Dentofacial Orthopaedics, Faculty of Dentistry, University of Toronto, 124 Edward st, Toronto M5G0C1, Ontario, Canada. anuraj_kochhar@yahoo.co.in

Abstract

BACKGROUND

Fibrous dysplasia (FD) is a developmental hamartomatous bone disease characterized by a blend of fibrous and osseous entities. Though rarely malignant, the tumor can vary from being small and asymptomatic, to a fairly large sized lesion, progressing gradually, compromising occlusion and facial esthetics. Treatment approach depends on the stage of skeletal maturity. It primarily involves surgical management for stabilizing the disease process. Post-surgical comprehensive dental treatment is necessary for restoring form and function of the jaws and teeth. This article describes comprehensive orthodontic management of severe malocclusion in a surgically operated case of FD maxilla.

CASE SUMMARY

A 19-year female presented with a chief complaint of excessive gingival display when smiling. Dental history included swelling of gums around the upper right front teeth, diagnosed at the age of 15 as FD of the right anterior maxillary segment and treated with surgical recontouring of the dysplastic bone. The

Country/Territory of origin: India**Specialty type:** Oncology**Provenance and peer review:**

Invited article; Externally peer reviewed.

Peer-review report's scientific quality classification

Grade A (Excellent): 0

Grade B (Very good): 0

Grade C (Good): C

Grade D (Fair): 0

Grade E (Poor): 0

Open-Access: This article is an open-access article that was selected by an in-house editor and fully peer-reviewed by external reviewers. It is distributed in accordance with the Creative Commons Attribution NonCommercial (CC BY-NC 4.0) license, which permits others to distribute, remix, adapt, build upon this work non-commercially, and license their derivative works on different terms, provided the original work is properly cited and the use is non-commercial. See: <http://creativecommons.org/licenses/by-nc/4.0/>

Received: April 6, 2021**Peer-review started:** April 6, 2021**First decision:** July 6, 2021**Revised:** July 14, 2021**Accepted:** October 20, 2021**Article in press:** October 20, 2021**Published online:** December 6, 2021**P-Reviewer:** Kaku M**S-Editor:** Gao CC**L-Editor:** A**P-Editor:** Gao CC

clinical and radiological examinations showed adequate post-surgical healing. The surgically treated dysplastic area presented with right canting of the maxillary anterior occlusal plane. The maxillary teeth were torqued palatally, with the root of the right maxillary canine exposed clinically. We discuss sequential management of the associated malocclusion with comprehensive fixed orthodontics, along with special precautions taken to prevent reactivation of the quiescent and healed lesion.

CONCLUSION

The adequate healing of fibro-dysplastic bone post-surgery must be allowed before initiating orthodontic tooth movement in the dysplastic bone. Periodic follow-ups are needed to monitor stability of occlusion and any relapse of the lesion.

Key Words: Craniofacial fibrous dysplasia; Malocclusion; Orthodontic tooth movement; Jaw surgery; Case report

©The Author(s) 2021. Published by Baishideng Publishing Group Inc. All rights reserved.

Core Tip: This article discusses comprehensive management of severe malocclusion in a surgically treated case of maxillary fibrous dysplasia. Adequate healing of the fibro-dysplastic bone post-surgery must be allowed before initiating orthodontic tooth movement. Orthodontic treatment in such patients should mainly focus on improving function and esthetics. Special precautions must be taken to prevent reactivation/relapse of the quiescent/healed lesion, including sequential orthodontic tooth movement, lighter forces, and avoidance of direct orthodontic forces to the latent bone. Periodic follow-ups are necessary to monitor long-term stability of occlusion and any progression of the lesion.

Citation: Kaur H, Mohanty S, Kochhar GK, Iqbal S, Verma A, Bhasin R, Kochhar AS. Comprehensive management of malocclusion in maxillary fibrous dysplasia: A case report. *World J Clin Cases* 2021; 9(34): 10671-10680

URL: <https://www.wjgnet.com/2307-8960/full/v9/i34/10671.htm>

DOI: <https://dx.doi.org/10.12998/wjcc.v9.i34.10671>

INTRODUCTION

Fibrous dysplasia (FD) is a rare slow-growing disorder of the bone characterized histologically by excessive cellular fibrous connective tissue interspersed with irregular bony trabeculae[1,2]. Lichtenstein and Jaffe first identified and named this pathological bone deformity in 1938. The etiology is still unclear, although certain studies highlight mutations in the alpha-subunit of the stimulatory G protein encoded by the gene GNAS[3]. This rare clinical entity presents in three forms- monostotic, polyostotic, and polyostotic with endocrinopathies with hyperpigmentation (café-au-lait macules) known as McCune Albright syndrome[4]. Generalized FD involving the face and skull and appearing prominently in the middle third of the face is known as "Leontiasis ossea"[5]. Monostotic forms are less severe, most commonly involving the zygomatic-maxillary complex. In monostotic forms involving the jaw, the symptoms may vary depending on the location, resulting in malocclusions, asymmetry, facial deformity, nasal obstruction, visual changes, pain and/or paresthesia. Either crowding or spacing may be seen, because teeth positions can change following the contours of the bony deformity. Polyostotic FD presents as multiple lesions involving adjacent bone. Skeletal deformities in the extremities may be seen, due to repeated fractures in the affected bone[4]. The most common dental anomalies associated with FD include tooth rotation, oligodontia, displacement, enamel hypoplasia, enamel hypomineralization, taurodontism, retained deciduous teeth and attrition[6]. The differential diagnosis for FD includes ossifying fibroma, hyperparathyroidism, chronic osteomyelitis, Paget's disease, osteosarcoma and various other bony lesions. These entities should be excluded by taking a detailed history, evaluating the pattern of growth of

the lesion, clinical examination, radiographs and histological analysis[6-8].

Management of FD depends upon the severity and rate of progression of the lesion. There are no accepted medical treatments for curing or stopping the progression of the disease. Bisphosphonates may be used for pain management, although they have shown no significant effect on disease progression[9]. Monoclonal antibodies to the receptor activator of nuclear factor kappa-B ligand and interleukin-6 have also been explored as a medical treatment for FD, resulting in reduction in bone pain, tumor growth, and bone turnover markers[10,11]. Most FD lesions require surgical management, mostly involving a conservative recontouring of the dysplastic bone to restore the normal bone shape. However, the need for re-surgery is high with this type of conservative surgical treatment. Reconstruction may be necessary for larger lesions [12]. The correction of concomitant malocclusion is also necessary, with the main focus on improving function and esthetics.

A thorough search revealed little mention of fibrous dysplasia in the orthodontic literature, and it is probably rarely seen in the typical orthodontic practice. There is limited information regarding protocols and precautions for orthodontic management of such lesions[13]. The case report follows and adheres to the CARE guidelines[14]. In the present article, we shall describe sequential dental and orthodontic management of malocclusion in a case of surgically treated FD of the maxilla.

CASE PRESENTATION

Chief complaints

A 19-year-old Indian female presented with a chief complaint of excessive display of gums when smiling.

History of present illness

Dental history included a hard, non-tender swelling of gums around the upper right canine-premolar teeth, first noted at 15 years of age. Orthopantomogram (OPG) X-ray revealed a mixed radiolucent/radiopaque lesion with ground-glass appearance, blending into the adjacent normal bone. There was loss of lamina dura of the associated teeth. Biopsy revealed trabeculae of mature bone with osteocytes in lacunae and rimmed by osteoid. The connective tissue was cellular and vascular, suggestive of a hamartomatous fibro-osseous lesion. The case was thus diagnosed as FD of the maxillary right anterior segment (Figure 1).

History of past illness

There was no significant medical, family and psychosocial history.

Personal and family history

There was no special personal and family history.

Imaging examinations

OPG X-ray revealed that the bone around the right maxillary canine-premolar teeth was less dense than in other areas, yet the bone pattern was regular. These findings suggested normal healing post-surgical resection. The lateral cephalometric analysis confirmed the aforementioned clinical diagnosis-Class II skeletal pattern, retrognathic mandible, retroclined maxillary anterior teeth and a normal growth pattern (Figure 2).

Extra-oral examination

The patient presented with symmetrical mesoprosopic face, competent lips, everted upper lip on right side, mild class II skeletal pattern with retrusive mandible and deep mentolabial sulcus. On smiling, inadequate display of incisor teeth with excessive gingival display on the right side was noted (Figure 2). Photographic analysis revealed canting of the inter-commissural line with respect to the inter-pupillary line, indicating an altered lip posture secondary to dysplasia and its surgical treatment (Figures 2 and 3A). Also, the photographs revealed no tooth display in the affected quadrant when smiling (Figure 3C).

Intra-oral examination

Intra-oral examination showed that the bony alveolus in the right maxillary canine-premolar region was markedly enlarged. The crowns of anterior maxillary teeth in this area were torqued lingually, with the root of the right maxillary canine (tooth #13)

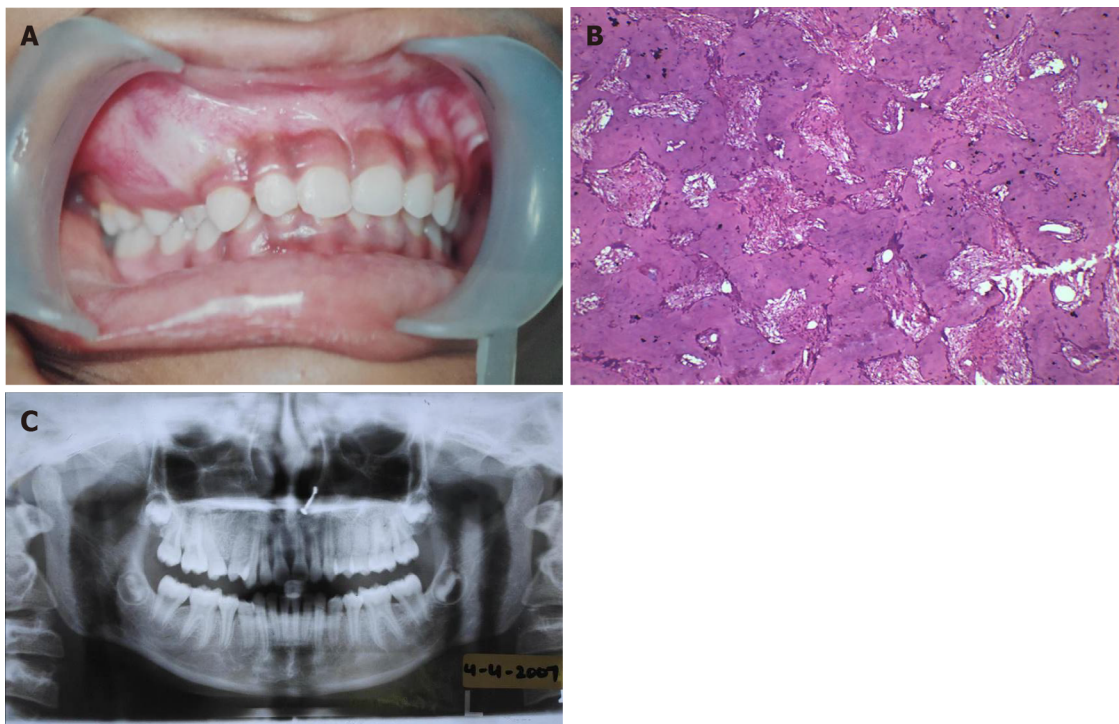


Figure 1 Pre-surgical treatment (April 2009). A: Intra-oral photograph; B: Immuno-histopathology slide; C: Orthopantomogram X-ray.

being exposed clinically. The maxillary anterior occlusal plane was canted towards the right side, resulting in asymmetric anterior arch form. Mandibular teeth were well aligned and upright on basal bone. Both left and right buccal segments had Class I occlusion.

MULTIDISCIPLINARY EXPERT CONSULTATION

In the first phase of treatment, surgical recontouring of the dysplastic area was performed was done by the oral surgeons. Four years after surgery, when the lesion was resolved and adequate bone healing was achieved, the case was referred for second phase treatment involving correction of the residual malocclusion and restoration of smile esthetics.

This phase involved a comprehensive orthodontic treatment and was commenced after thorough clinical and radiographic examination.

FINAL DIAGNOSIS

FD of the maxillary right anterior segment.

TREATMENT

Treatment plan

The treatment objectives included endodontic management of the clinically exposed root apex of right maxillary canine #13 (Federation Dentaire Internationale notation), followed by orthodontic correction of the following- the palatal root torque of teeth in the right maxillary anterior segment; the cant of the maxillary anterior occlusal plane towards the right side; the excessive gingival display on the right side; and the excess overbite. The radiographic findings suggested adequate healing of the lesion four years after surgery, therefore we decided to initiate tooth movement of the displaced teeth.

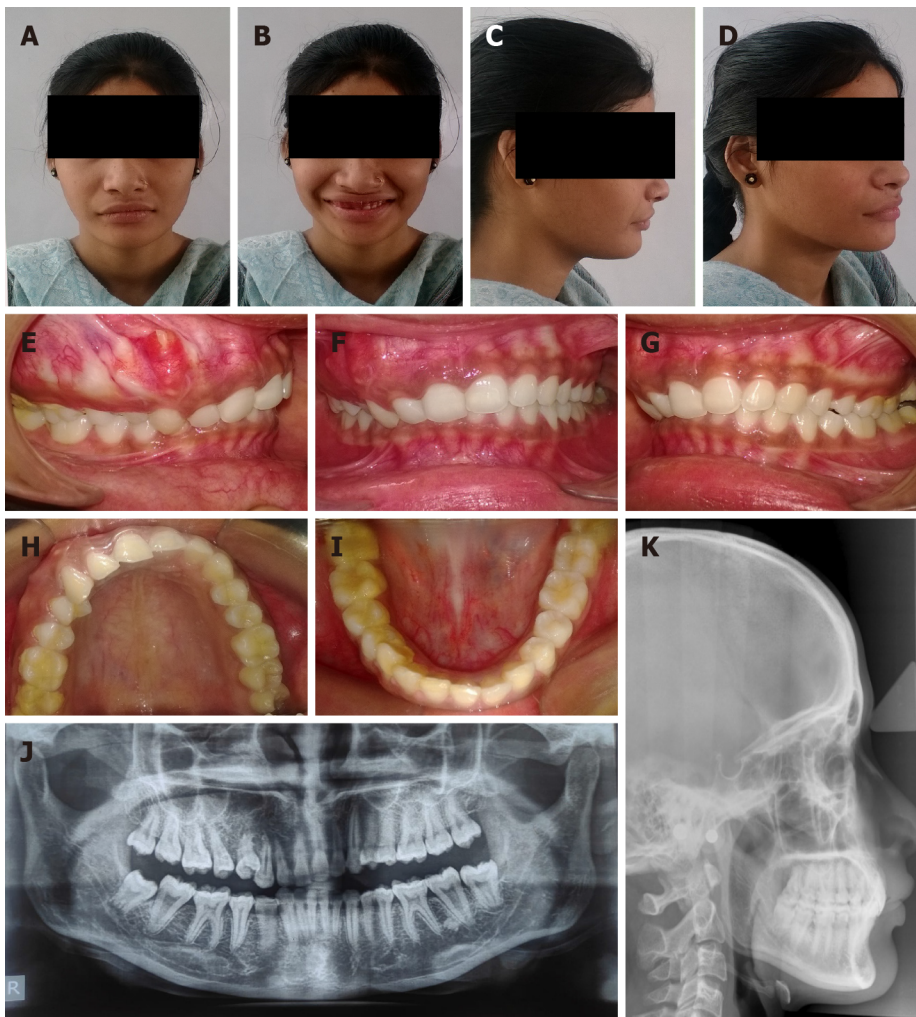

Figure 2 Post-surgical/pre-treatment photographs (October 2013). A: Extra-oral frontal view; B: Extra-oral frontal with smile view; C: Extra-oral right profile view; D: Extra-oral right three-quarter view; E: Intra-oral right buccal view; F: Intra-oral front view; G: Intra-oral left buccal view; H: Intra-oral maxillary occlusal view; I: Intra-oral mandibular occlusal view; J: Orthopantomogram X-ray; K: Lateral cephalogram.

Therapeutic intervention

The treatment commenced with non-surgical endodontic treatment of the right maxillary canine #13, followed by apicoectomy of the clinically exposed root apex. Three months later, after confirming adequate healing, the orthodontic treatment was started using .022X.028" slot, conventional straight-wire mechanics. (Figure 4). Following alignment of the maxillary arch, .019X.025" stainless steel wire was placed with anterior differential palatal root torque (Figure 4A). Additional trans-palatal arch allowed cross-arch stabilization. After desired up righting of teeth was achieved, the remaining mandibular arch was bonded for alignment along with an asymmetric anterior intrusion in the upper arch using a unilateral intrusion arch made from .018" A.J. Wilcock archwire (Figure 4B). Then, a separate canine intrusion spring (again made from .018" A.J. Wilcock archwire) and continued asymmetric anterior intrusion were used to further correct the occlusal cant and anterior deep bite (Figure 4C). After adequate bite opening and levelling of the occlusal cant, post-intrusion finishing and detailing was done using .019X.025" stainless steel wire with artistic positioning bends (Figure 4D). OPG X-rays were taken periodically throughout the active tooth movement phase to monitor for any changes in bone morphology. The case was debonded after 41 mo of active treatment (Figure 5). A maxillary Essix retainer and mandibular bonded lingual retainer were placed to maintain the achieved dental corrections.

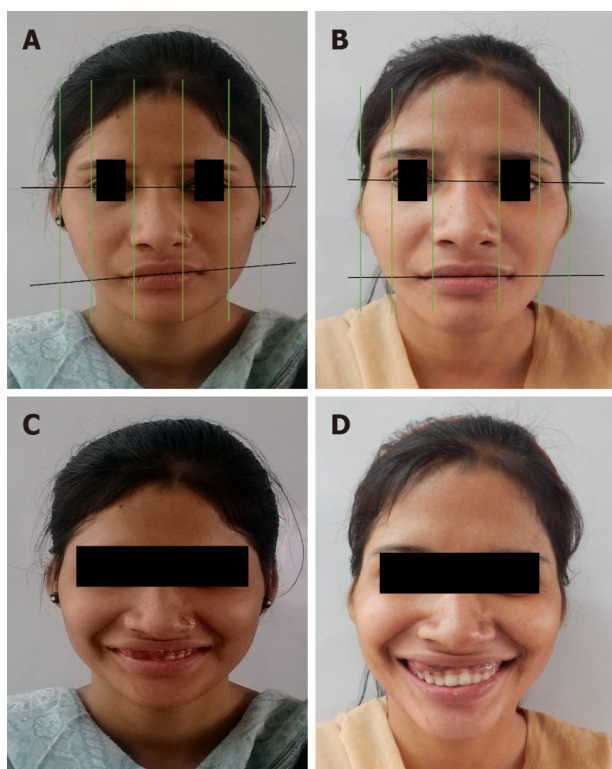

Figure 3 Photographic analysis and pre and post orthodontic treatment comparison. A and B: Comparison of frontal photographs portray the change in inter-commissural cant resulting from the correction of occlusal cant; C and D: Comparison of smile photographs depict the improvement of smile esthetics resulting from the intrusion of teeth on the affected side.

OUTCOME AND FOLLOW-UP

Periodic follow-ups were done every 6-mo for monitoring the stability of occlusion and any progression of the lesion. At the 3-year follow up, the patient's occlusion was stable and treatment results were well maintained without any signs and/or symptoms of an active lesion, despite discontinuing the maxillary retainer after two years (Figure 6).

DISCUSSION

FD is a type of bone disorder mostly involving craniofacial bones. Lesions are twice as common in the posterior maxilla as compared to the mandible[15]. Maxillary FD is associated with metabolic dysfunction and disordered bone architecture, which in turn affects tooth development and eruption.

The most common dental anomalies associated with FD include tooth rotation, oligodontia, displacement, enamel hypoplasia, enamel hypomineralization, impacted teeth and/or severe malocclusion[16]. The patient in the current report presented for esthetic reasons with excessive gingival display and malocclusion following surgically corrected/recontoured FD of the right maxilla in the canine-premolar area. The lesion resulted in crowding, rotations and displacement of teeth in the same quadrant, along with excessive palatal crown torque/buccal root torque of teeth, exposed root of the right maxillary canine tooth #13 and a canted occlusion plane. Deposition of dysplastic bone caused expansion of the buccal cortical plate, and surgical recontouring of the lesion caused exposure of the maxillary right canine root apex. It was treated by root canal treatment and apicoectomy. Our ultimate goal was to correct malocclusion by movement of teeth in the affected area.

FD in the craniofacial skeleton and related structures results in significant dysmorphic features like facial asymmetry and deformity. In the present case, characteristic features of FD were apparent on pre-surgical panoramic radiographs, described as a mixed radiolucent/radiopaque lesion with ground glass appearance[1-4]. Few articles have reported adequate healing of fibro-dysplastic bone following orthognathic surgery[17,18]. There is also very limited information regarding

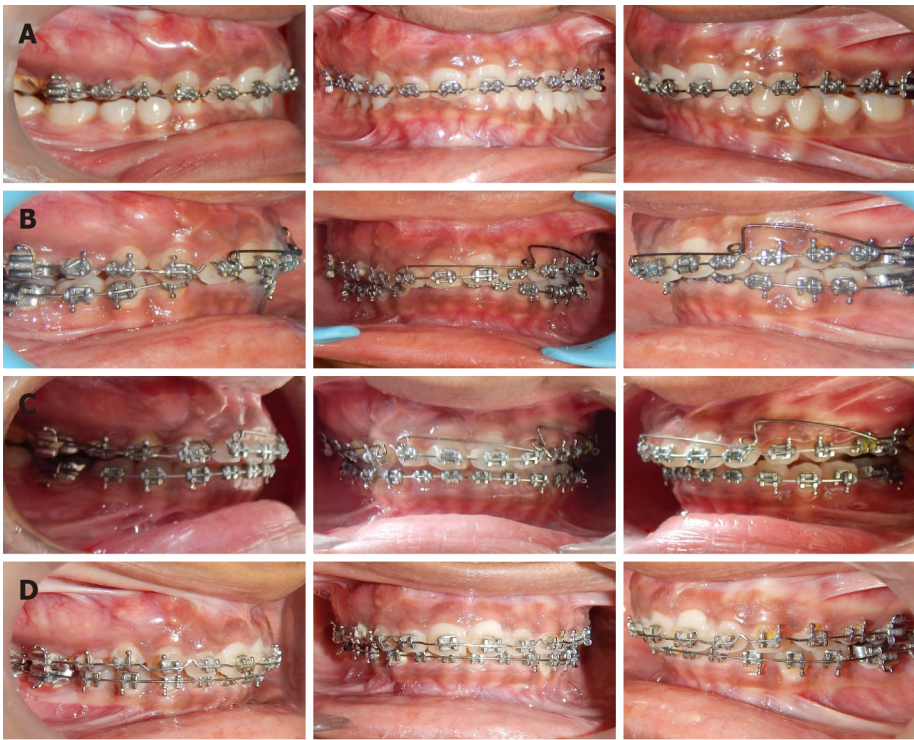

Figure 4 Treatment progress and orthodontic mechanics applied (timeline: Dec 2013-May 2017). A: Torquing wire with anterior differential palatal root torque; B: Lower arch bonding. Upper arch asymmetric anterior intrusion using unilateral Intrusion arch (.018" AJW); C: Separate canine intrusion arch (.018" AJW) and continued asymmetric anterior intrusion; D: Post-intrusion finishing and detailing.

orthodontic tooth movement in dysplastic bone, and the long-term prognosis of such treatment. A case report describing orthodontic repositioning of an impacted cuspid in fibro-dysplastic maxillary bone of a 12-year-old girl suggests a normal response of dysplastic bone to orthodontic forces[19]. Lee *et al*[3] and Akintoye *et al*[20] suggest delaying orthodontic therapy until after the age of skeletal maturity, based on the individual patient's needs and findings from an initial orthodontic evaluation. The advantage of such delay is that FD disease activity tends to decrease after skeletal maturity, which is reflected in a decline in bone turnover markers, a decrease in the number of mutated skeletal stem/progenitor cells, and a tendency of FD histology to improve over time[21]. Orthodontic treatment for the patient in the current report was initiated after completion of the pubertal growth spurt. Furthermore, four years post-surgery, there were no signs and/or symptoms of an active lesion. The OPG X-ray revealed less osseous density but predominantly regular woven bone in the area of the lesion, indicative of successful healing.

A position correlation between increase in c-fos gene and FD was described by Marie *et al*[22]. Increase in c-fos gene has been related to post-traumatic FD in a couple of case reports[23,24]. Therefore, to avoid the risk of transforming a quiescent lesion into an aggressively growing lesion, we planned to proceed with sequential orthodontic tooth movement, using light forces, without applying any direct forces to the bone (through micro-implants) and to monitor the lesion periodically. There were no signs of reactivation of the FD lesion during the active orthodontic treatment period of 41 mo, as evident on post-operative photographs and radiographs (Figure 5), which may be attributed to the following special precautions taken in this case: Delaying orthodontic treatment until adequate healing of the surgically treated bone was confirmed, as well as skeletal maturity was attained[21]; Sequential orthodontic mechanics: Initial torquing and up righting of the teeth was followed by segmental intrusion of anterior teeth to correct the cant of the occlusal plane; Use of light forces: To correct the anterior cant of the occlusal plane, a unilateral cantilever intrusion arch was used for unilateral intrusion of the right maxillary incisors. The forces were kept light, below 20gms, and 0.018" A.J Wilcock wire was used instead of conventional 0.017X0.25" TMA wires. Additionally, we did a separate intrusion for the right maxillary canine; Avoid direct forces to the healed bone: We avoided using micro-implants for supported intrusion, to prevent any immediate trigger for reactivation of the lesion.

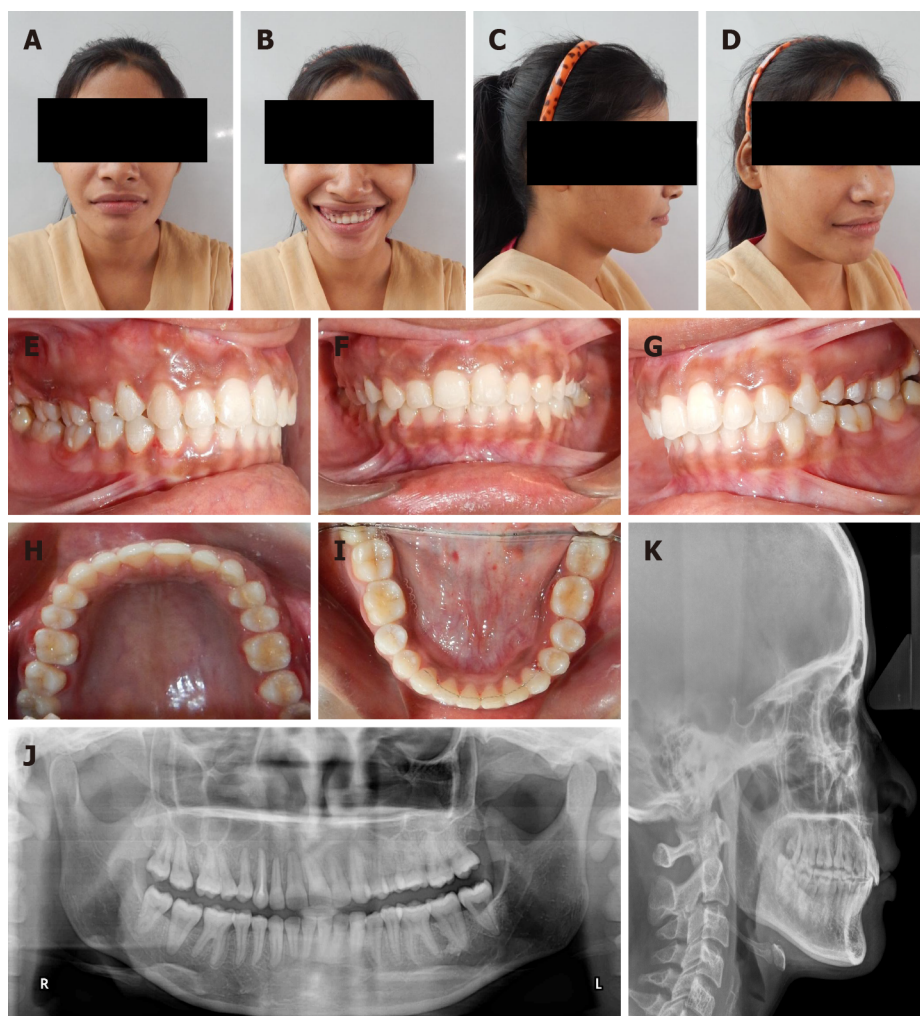


Figure 5 Post-orthodontic treatment photographs (June 2017). A: Extra-oral frontal view; B: Extra-oral frontal with smile view; C: Extra-oral right profile view; D: Extra-oral right three-quarter view; E: Intra-oral right buccal view; F: Intra-oral front view; G: Intra-oral left buccal view; H: Intra-oral maxillary occlusal view; I: Intra-oral mandibular occlusal view; J: Orthopantomogram X-ray; K: Lateral cephalogram.

The total duration of active treatment was 41 mo. This is in accordance with previous studies showing that orthodontic treatment duration is increased in FD cases [3,20]. Using light forces over longer duration also minimizes the possibility of relapse after orthodontic treatment. There is limited data on long-term outcomes of orthodontic treatment and the effectiveness of retention in FD cases [3,13]. Therefore, we proposed long-term retention in the present case. Maxillary Essix retainer and mandibular bonded lingual retainer were given to maintain the achieved dental corrections. Periodic follow-ups were done every 6-mo. The 3-year follow-up records showed relatively stable occlusion and minimal relapse, despite discontinuing the maxillary retainer after two years. However, the authors believe that results from this case report may not be applicable to all patients with FD and further characterization of orthodontic management should be decided by more precise, prospective clinical studies.

CONCLUSION

In this report, FD of the maxilla was successfully treated with surgical recontouring and orthodontic treatment. The goal of orthodontic treatment in FD affecting the maxillary region is to focus on improving function and esthetics, while avoiding reactivation of the quiescent/healed lesion. Adequate healing of fibro-dysplastic bone post-surgery must be allowed before commencement of orthodontic tooth movement, as inferred from a good outcome in this case. Special precautions must be taken, such as sequential orthodontic tooth movement, use of lighter forces and avoidance of direct orthodontic forces to the latent bone. Periodic follow-ups are necessary to

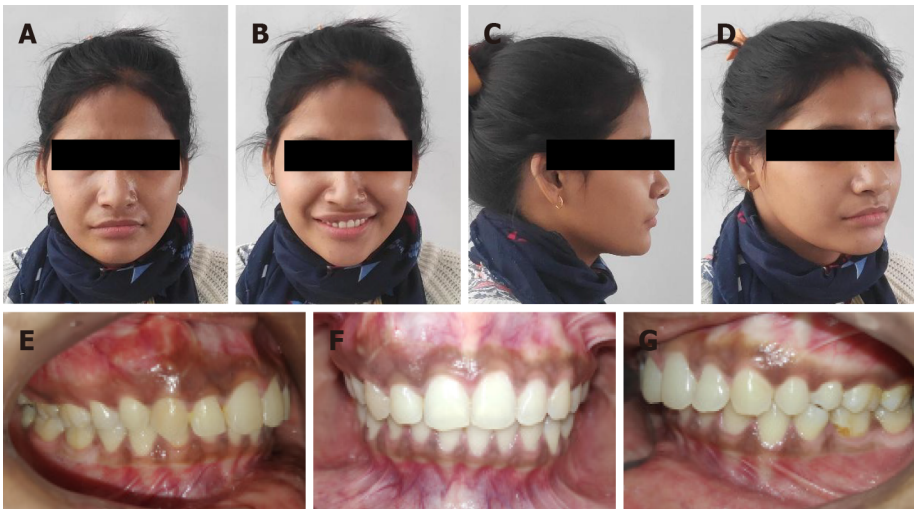

Figure 6 Three years post-retention pics (December 2020). A: Extra-oral frontal view; B: Extra-oral frontal with smile view; C: Extra-oral right profile view; D: Extra-oral right three-quarter view; E: Intra-oral right buccal view; F: Intra-oral front view; G: Intra-oral left buccal view.

monitor the stability of occlusion and any relapse of the lesion.

ACKNOWLEDGEMENTS

We acknowledge the patient and her parents for providing us with consent to perform the treatment, being cooperative throughout the treatment and follow-ups, and giving us permission to submit and publish the records for this article. We also acknowledge Dr. Verma P (DDS, MS, FAGD, Diplomate, American Board of Endodontics) for the prompt professional guidance and expertise to polish the manuscript further.

REFERENCES

- 1 **Costanzi MA**, Velasco e Cruz AA. Envolvimento orbitário difuso por dysplasia fibrosa na síndrome de McCune Albright: Relato de caso. *Arq Bras Oftalmol* 2007; **70**: 1021-1023
- 2 **Neville BW**, Damm DD, Allen CW, Bouquot JR. *Patologia Oral & Maxilofacial*. 2nd ed. Rio de Janeiro: Guanabara Koogan, 2004
- 3 **Lee JS**, FitzGibbon EJ, Chen YR, Kim HJ, Lustig LR, Akintoye SO, Collins MT, Kaban LB. Clinical guidelines for the management of craniofacial fibrous dysplasia. *Orphanet J Rare Dis* 2012; **7** Suppl 1: S2 [PMID: 22640797 DOI: 10.1186/1750-1172-7-S1-S2]
- 4 **MacDonald-Jankowski D**. Fibrous dysplasia: a systematic review. *Dentomaxillofac Radiol* 2009; **38**: 196-215 [PMID: 19372108 DOI: 10.1259/dmfr/16645318]
- 5 **Mansilla-Lory J**, Amezcua-Guerra LM, Vargas-Rodríguez A, Fernández-Tapia S, Lebreiro I, Resnick D, Martínez-Lavín M, Villanueva M, Gaytan E, Pineda C. Leontiasis ossea: a paleopathologic case report. *J Clin Rheumatol* 2007; **13**: 269-272 [PMID: 17921795 DOI: 10.1097/RHU.0b013e318156dd1a]
- 6 **Akintoye SO**, Boyce AM, Collins MT. Dental perspectives in fibrous dysplasia and McCune-Albright syndrome. *Oral Surg Oral Med Oral Pathol Oral Radiol* 2013; **116**: e149-e155 [PMID: 23953425 DOI: 10.1016/j.oooo.2013.05.023]
- 7 **Burke AB**, Collins MT, Boyce AM. Fibrous dysplasia of bone: craniofacial and dental implications. *Oral Dis* 2017; **23**: 697-708 [PMID: 27493082 DOI: 10.1111/odi.12563]
- 8 **Unal Erzurumlu Z**, Celenk P, Bulut E, Baris YS. CT Imaging of Craniofacial Fibrous Dysplasia. *Case Rep Dent* 2015; **2015**: 134123 [PMID: 26339510 DOI: 10.1155/2015/134123]
- 9 **Plotkin H**, Rauch F, Zeitlin L, Munns C, Travers R, Glorieux FH. Effect of pamidronate treatment in children with polyostotic fibrous dysplasia of bone. *J Clin Endocrinol Metab* 2003; **88**: 4569-4575 [PMID: 14557424 DOI: 10.1210/jc.2003-030050]
- 10 **Boyce AM**, Chong WH, Yao J, Gafni RI, Kelly MH, Chamberlain CE, Bassim C, Cherman N, Ellsworth M, Kasa-Vubu JZ, Farley FA, Molinolo AA, Bhattacharyya N, Collins MT. Denosumab treatment for fibrous dysplasia. *J Bone Miner Res* 2012; **27**: 1462-1470 [PMID: 22431375 DOI: 10.1002/jbmr.1603]
- 11 **de Boysson H**, Johnson A, Hablani N, Hajlaoui W, Auzary C, Geffray L. Tocilizumab in the treatment of a polyostotic variant of fibrous dysplasia of bone. *Rheumatology (Oxford)* 2015; **54**:

- 1747-1749 [PMID: [26070936](#) DOI: [10.1093/rheumatology/kev221](#)]
- 12 **Zeng HF**, Lu JJ, Teng L, Jin XL, Xu JJ, Zhang C, Xu MB, Xie F, Tian T, Xu R, Wu HH. Surgical treatment of craniomaxillofacial fibrous dysplasia: functionally or aesthetically? *J Craniofac Surg* 2013; **24**: 758-762 [PMID: [23714874](#) DOI: [10.1097/SCS.0b013e3182869674](#)]
- 13 **Subramani K**, Lee V, Krisko A, Huja S. Orthodontic treatment of patient with maxillofacial fibrous dysplasia: A case report. *J Clin Exp Dent* 2019; **11**: e296-e302 [PMID: [31001403](#) DOI: [10.4317/jced.55584](#)]
- 14 **Riley DS**, Barber MS, Kienle GS, Aronson JK, von Schoen-Angerer T, Tugwell P, Kiene H, Helfand M, Altman DG, Sox H, Werthmann PG, Moher D, Rison RA, Shamseer L, Koch CA, Sun GH, Hanaway P, Sudak NL, Kaszkin-Bettag M, Carpenter JE, Gagnier JJ. CARE guidelines for case reports: explanation and elaboration document. *J Clin Epidemiol* 2017; **89**: 218-235 [PMID: [28529185](#) DOI: [10.1016/j.jclinepi.2017.04.026](#)]
- 15 **Menon S**, Venkatswamy S, Ramu V, Banu K, Ehtai S, Kashyap VM. Craniofacial fibrous dysplasia: Surgery and literature review. *Ann Maxillofac Surg* 2013; **3**: 66-71 [PMID: [23662263](#) DOI: [10.4103/2231-0746.110088](#)]
- 16 **Catena DL**, Glick GL. Monostotic fibrous dysplasia with dental anomalies. Report of a case. *Oral Surg Oral Med Oral Pathol* 1971; **32**: 136-140 [PMID: [5281546](#) DOI: [10.1016/0030-4220\(71\)90259-3](#)]
- 17 **Samman N**, Piette E, Cheung LK, Tideman H. Feasibility of osteotomies in fibrous dysplasia of the jaws. *Int J Oral Maxillofac Surg* 1991; **20**: 353-356 [PMID: [1770240](#) DOI: [10.1016/s0901-5027\(05\)80264-4](#)]
- 18 **Yeow VK**, Chen YR. Orthognathic surgery in craniomaxillofacial fibrous dysplasia. *J Craniofac Surg* 1999; **10**: 155-159 [PMID: [10388417](#) DOI: [10.1097/00001665-199903000-00012](#)]
- 19 **Colella G**, Itró A, Perillo L, Cannavale R. Orthodontic movement of impacted cuspid in fibrodysplastic bone: a case report. *Bone* 2010; **46**: 248-250 [PMID: [19716453](#) DOI: [10.1016/j.bone.2009.08.049](#)]
- 20 **Akintoye SO**, Lee JS, Feimster T, Booher S, Brahim J, Kingman A, Riminucci M, Robey PG, Collins MT. Dental characteristics of fibrous dysplasia and McCune-Albright syndrome. *Oral Surg Oral Med Oral Pathol Oral Radiol Endod* 2003; **96**: 275-282 [PMID: [12973283](#) DOI: [10.1016/s1079-2104\(03\)00225-7](#)]
- 21 **Davies ML**, Macpherson P. Fibrous dysplasia of the skull: disease activity in relation to age. *Br J Radiol* 1991; **64**: 576-579 [PMID: [1873656](#) DOI: [10.1259/0007-1285-64-763-576](#)]
- 22 **Marie PJ**, de Pollak C, Chanson P, Lomri A. Increased proliferation of osteoblastic cells expressing the activating Gs alpha mutation in monostotic and polyostotic fibrous dysplasia. *Am J Pathol* 1997; **150**: 1059-1069 [PMID: [9060842](#)]
- 23 **Tomiyama A**, Aoki K, Nakayama H, Izukura H, Kimura H, Harashina J, Ito K, Hayashi M, Saito N, Sakurai T, Oharaseki T, Terada H, Iwabuchi S. Posttraumatic cranial cystic fibrous dysplasia. *Case Rep Med* 2011; **2011**: 680401 [PMID: [21876700](#) DOI: [10.1155/2011/680401](#)]
- 24 **Umerani MS**, Bakhshi SK, Abbas A, Sharif S, Arshad S. Post-traumatic fibrous dysplasia of the parietal bone: A rare entity. *Asian J Neurosurg* 2017; **12**: 547-550 [PMID: [28761541](#) DOI: [10.4103/1793-5482.148800](#)]



Published by **Baishideng Publishing Group Inc**
7041 Koll Center Parkway, Suite 160, Pleasanton, CA 94566, USA

Telephone: +1-925-3991568

E-mail: bpgoffice@wjgnet.com

Help Desk: <https://www.f6publishing.com/helpdesk>

<https://www.wjgnet.com>

