

World Journal of *Clinical Cases*

World J Clin Cases 2021 December 16; 9(35): 10746-11121



Contents

Thrice Monthly Volume 9 Number 35 December 16, 2021

REVIEW

- 10746 Management of acute kidney injury in gastrointestinal tumor: An overview

Su YQ, Yu YY, Shen B, Yang F, Nie YX

- 10765 Application of vascular endothelial cells in stem cell medicine

Liang QQ, Liu L

MINIREVIEWS

- 10781 Application of traditional Chinese medicine in treatment of *Helicobacter pylori* infection

Li RJ, Dai YY, Qin C, Huang GR, Qin YC, Huang YY, Huang ZS, Luo XK, Huang YQ

ORIGINAL ARTICLE

Case Control Study

- 10792 Impact of cytomegalovirus infection on biliary disease after liver transplantation - maybe an essential factor

Liu JY, Zhang JR, Sun LY, Zhu ZJ, Wei L, Qu W, Zeng ZG, Liu Y, Zhao XY

- 10805 Blood tests for prediction of deep endometriosis: A case-control study

Chen ZY, Zhang LF, Zhang YQ, Zhou Y, Li XY, Huang XF

Retrospective Cohort Study

- 10816 Association between neutrophil-to-lymphocyte ratio and major postoperative complications after carotid endarterectomy: A retrospective cohort study

Yu Y, Cui WH, Cheng C, Lu Y, Zhang Q, Han RQ

- 10828 Application of MAGnetic resonance imaging compilation in acute ischemic stroke

Wang Q, Wang G, Sun Q, Sun DH

Retrospective Study

- 10838 Ninety-four thousand-case retrospective study on antibacterial drug resistance of *Helicobacter pylori*

Zhang Y, Meng F, Jin J, Wang J, Gu BB, Peng JB, Ye LP

- 10850 Adjacent segment disease following Dynesys stabilization for lumbar disorders: A case series of mid- and long-term follow-ups

Chen KJ, Lai CY, Chiu LT, Huang WS, Hsiao PH, Chang CC, Lin CJ, Lo YS, Chen YJ, Chen HT

- 10861 Identification of independent risk factors for intraoperative gastroesophageal reflux in adult patients undergoing general anesthesia

Zhao X, Li ST, Chen LH, Liu K, Lian M, Wang HJ, Fang YJ

- 10871** Value of the controlling nutritional status score and psoas muscle thickness per height in predicting prognosis in liver transplantation

Dai X, Gao B, Zhang XX, Li J, Jiang WT

- 10884** Development of a lipid metabolism-related gene model to predict prognosis in patients with pancreatic cancer

Xu H, Sun J, Zhou L, Du QC, Zhu HY, Chen Y, Wang XY

- 10899** Serum magnesium level as a predictor of acute kidney injury in patients with acute pancreatitis

Yu XQ, Deng HB, Liu Y, Qu C, Duan ZH, Tong ZH, Liu YX, Li WQ

- 10909** Pedicle complex tissue flap transfer for reconstruction of duplicated thumbs with unequal size

Wang DH, Zhang GP, Wang ZT, Wang M, Han QY, Liu FX

- 10919** Minimally invasive surgery *vs* laparotomy in patients with colon cancer residing in high-altitude areas

Suo Lang DJ, Ci Ren YZ, Bian Ba ZX

Observational Study

- 10927** Surgery for chronic pancreatitis in Finland is rare but seems to produce good long-term results

Parhiala M, Sand J, Laukkanen J

- 10937** Association of overtime work and obesity with needle stick and sharp injuries in medical practice

Chen YH, Yeh CJ, Jong GP

- 10948** Serum gastrin-17 concentration for prediction of upper gastrointestinal tract bleeding risk among peptic ulcer patients

Wang JX, Cao YP, Su P, He W, Li XP, Zhu YM

- 10956** Predictive risk scales for development of pressure ulcers in pediatric patients admitted to general ward and intensive care unit

Luo WJ, Zhou XZ, Lei JY, Xu Y, Huang RH

META-ANALYSIS

- 10969** Clinical significance of signet ring cells in surgical esophageal and esophagogastric junction adenocarcinoma: A systematic review and meta-analysis

Wang YF, Xu SY, Wang Y, Che GW, Ma HT

- 10979** Percutaneous biliary stent combined with brachytherapy using ¹²⁵I seeds for treatment of unresectable malignant obstructive jaundice: A meta-analysis

Chen WY, Kong CL, Meng MM, Chen WQ, Zheng LY, Mao JT, Fang SJ, Chen L, Shu GF, Yang Y, Weng QY, Chen MJ, Xu M, Ji JS

CASE REPORT

- 10994** Prenatal ultrasonographic findings in Klippel-Trenaunay syndrome: A case report

Pang HQ, Gao QQ

- 10999** Immunoglobulin G4-related lymph node disease with an orbital mass mimicking Castleman disease: A case report
Hao FY, Yang FX, Bian HY, Zhao X
- 11007** Treatment for subtrochanteric fracture and subsequent nonunion in an adult patient with osteopetrosis: A case report and review of the literature
Yang H, Shao GX, Du ZW, Li ZW
- 11016** Early surgical intervention in culture-negative endocarditis of the aortic valve complicated by abscess in an infant: A case report
Yang YF, Si FF, Chen TT, Fan LX, Lu YH, Jin M
- 11024** Severe absence of intra-orbital fat in a patient with orbital venous malformation: A case report
Yang LD, Xu SQ, Wang YF, Jia RB
- 11029** Pulmonary Langerhans cell histiocytosis and multiple system involvement: A case report
Luo L, Li YX
- 11036** Complete androgen insensitivity syndrome caused by the c.2678C>T mutation in the androgen receptor gene: A case report
Wang KN, Chen QQ, Zhu YL, Wang CL
- 11043** Ultrasound guiding the rapid diagnosis and treatment of perioperative pneumothorax: A case report
Zhang G, Huang XY, Zhang L
- 11050** Chronic colchicine poisoning with neuromyopathy, gastric ulcers and myelosuppression in a gout patient: A case report
Li MM, Teng J, Wang Y
- 11056** Treatment of a giant low-grade appendiceal mucinous neoplasm: A case report
Xu R, Yang ZL
- 11061** Thoracoscopic resection of a large lower esophageal schwannoma: A case report and review of the literature
Wang TY, Wang BL, Wang FR, Jing MY, Zhang LD, Zhang DK
- 11071** Signet ring cell carcinoma hidden beneath large pedunculated colorectal polyp: A case report
Yan JN, Shao YF, Ye GL, Ding Y
- 11078** Double-mutant invasive mucinous adenocarcinoma of the lung in a 32-year-old male patient: A case report
Wang T
- 11085** Acute myocarditis presenting as accelerated junctional rhythm in Graves' disease: A case report
Li MM, Liu WS, Shan RC, Teng J, Wang Y
- 11095** Lingual nerve injury caused by laryngeal mask airway during percutaneous nephrolithotomy: A case report
Wang ZY, Liu WZ, Wang FQ, Chen YZ, Huang T, Yuan HS, Cheng Y

- 11102** Ventricular fibrillation and sudden cardiac arrest in apical hypertrophic cardiomyopathy: Two case reports
Park YM, Jang AY, Chung WJ, Han SH, Semsarian C, Choi IS
- 11108** *Rhizopus microsporus* lung infection in an immunocompetent patient successfully treated with amphotericin B: A case report
Chen L, Su Y, Xiong XZ
- 11115** Spermatocytic tumor: A rare case report
Hao ML, Li CH

ABOUT COVER

Editorial Board Member of *World Journal of Clinical Cases*, Luca Morelli, FACS, FASCRS, MD, Associate Professor, Division of General Surgery, Department of Translational Research and of New Surgical and Medical Technologies, University of Pisa, Pisa 56124, Italy. luca.morelli@unipi.it

AIMS AND SCOPE

The primary aim of *World Journal of Clinical Cases* (WJCC, *World J Clin Cases*) is to provide scholars and readers from various fields of clinical medicine with a platform to publish high-quality clinical research articles and communicate their research findings online.

WJCC mainly publishes articles reporting research results and findings obtained in the field of clinical medicine and covering a wide range of topics, including case control studies, retrospective cohort studies, retrospective studies, clinical trials studies, observational studies, prospective studies, randomized controlled trials, randomized clinical trials, systematic reviews, meta-analysis, and case reports.

INDEXING/ABSTRACTING

The WJCC is now indexed in Science Citation Index Expanded (also known as SciSearch®), Journal Citation Reports/Science Edition, Scopus, PubMed, and PubMed Central. The 2021 Edition of Journal Citation Reports® cites the 2020 impact factor (IF) for WJCC as 1.337; IF without journal self cites: 1.301; 5-year IF: 1.742; Journal Citation Indicator: 0.33; Ranking: 119 among 169 journals in medicine, general and internal; and Quartile category: Q3. The WJCC's CiteScore for 2020 is 0.8 and Scopus CiteScore rank 2020: General Medicine is 493/793.

RESPONSIBLE EDITORS FOR THIS ISSUE

Production Editor: Jia-Hui Li; Production Department Director: Xiang Li; Editorial Office Director: Jin-Lei Wang.

NAME OF JOURNAL

World Journal of Clinical Cases

ISSN

ISSN 2307-8960 (online)

LAUNCH DATE

April 16, 2013

FREQUENCY

Thrice Monthly

EDITORS-IN-CHIEF

Dennis A Bloomfield, Sandro Vento, Bao-Gan Peng

EDITORIAL BOARD MEMBERS

<https://www.wjgnet.com/2307-8960/editorialboard.htm>

PUBLICATION DATE

December 16, 2021

COPYRIGHT

© 2021 Baishideng Publishing Group Inc

INSTRUCTIONS TO AUTHORS

<https://www.wjgnet.com/bpg/gerinfo/204>

GUIDELINES FOR ETHICS DOCUMENTS

<https://www.wjgnet.com/bpg/GerInfo/287>

GUIDELINES FOR NON-NATIVE SPEAKERS OF ENGLISH

<https://www.wjgnet.com/bpg/gerinfo/240>

PUBLICATION ETHICS

<https://www.wjgnet.com/bpg/GerInfo/288>

PUBLICATION MISCONDUCT

<https://www.wjgnet.com/bpg/gerinfo/208>

ARTICLE PROCESSING CHARGE

<https://www.wjgnet.com/bpg/gerinfo/242>

STEPS FOR SUBMITTING MANUSCRIPTS

<https://www.wjgnet.com/bpg/GerInfo/239>

ONLINE SUBMISSION

<https://www.f6publishing.com>



Retrospective Study

Pedicle complex tissue flap transfer for reconstruction of duplicated thumbs with unequal size

De-Hua Wang, Gui-Ping Zhang, Zeng-Tao Wang, Meng Wang, Qin-Yi Han, Fan-Xiao Liu

ORCID number: De-Hua Wang 0000-0002-1303-8564; Gui-Ping Zhang 0000-0002-0005-4602; Zeng-Tao Wang 0000-0002-3279-893X; Meng Wang 0000-0001-6933-6408; Qin-Yi Han 0000-0002-3222-5883; Fan-Xiao Liu 0000-0002-1412-849X.

Author contributions: Liu FX, Wang DH, and Han QY designed the research study; Wang DH, Zhang GP, Wang ZT, Wang M, Han Q, and Liu FX performed the research; Liu FX and Han QY analyzed the data; Wang DH, Zhang GP, Wang ZT, Wang M, Han QY, and Liu FX wrote the manuscript; Liu FX and Han QY contributed equally in the planning, construction, and writing of the manuscript.

Institutional review board statement: The study was reviewed and approved by the Biomedical Ethic Committee of Shandong Provincial Hospital (Approval No. 2021-018).

Informed consent statement: Written consent was obtained from the patients' parents for the purpose of publication of case details and images.

Conflict-of-interest statement: The authors declare no potential conflicts of interest with respect to the research, authorship, and/or

De-Hua Wang, Zeng-Tao Wang, Meng Wang, Department of Hand and Foot, Shandong Provincial Hospital Affiliated to Shandong First Medical University, Jinan 250021, Shandong Province, China

Gui-Ping Zhang, Department of Anesthesiology, The Affiliated Hospital of Shandong University of Traditional Chinese Medicine, Jinan 250000, Shandong Province, China

Qin-Yi Han, Department of Hand and Foot, Shandong Provincial Hospital Affiliated to Shandong University, Jinan 250021, Shandong Province, China

Fan-Xiao Liu, Department of Orthopaedics, Shandong Provincial Hospital Affiliated to Shandong First Medical University, Jinan 250021, Shandong Province, China

Corresponding author: Qin-Yi Han, MD, Doctor, Department of Hand and Foot, Shandong Provincial Hospital Affiliated to Shandong University, No. 324 Qingwuwei, Jinan 250021, Shandong Province, China. hanqinyi@126.com

Abstract

BACKGROUND

Thumb polydactyly is one of the most common congenital hand deformities, and the Bilhaut-Cloquet procedure or a modified one is often used. However, controversy remains over the rare instances in which both thumbs are not of similar length or far apart in distance.

AIM

To evaluate the clinical outcomes of pedicle complex tissue flap transfer in the treatment of duplicated thumbs with unequal size.

METHODS

From January 2014 to December 2020, 15 patients underwent duplicated thumb reconstruction by pedicle complex tissue flap transfer at our hand surgery center. The technique was used when it was necessary to combine different tissues from both severed and preserved thumbs that were not of similar length or far apart in distance. Subjective parents' evaluations and functional outcomes (ALURRA and TATA criteria) were obtained. The alignment deviation, instability, range of motion (percent of opposite thumb) of the interphalangeal and metacarpophalangeal joints, and the aesthetic aspects, including circumference, length, nail size, and nail deformity, were used to assess the clinical outcomes.

publication of this article.

Data sharing statement: No additional data are available.

Supported by the China Scholarship Council, No. 201808080126 (to Liu FX).

Country/Territory of origin: China

Specialty type: Orthopedics

Provenance and peer review: Unsolicited article; Externally peer reviewed.

Peer-review model: Single blind

Peer-review report's scientific quality classification

Grade A (Excellent): 0
Grade B (Very good): 0
Grade C (Good): C
Grade D (Fair): 0
Grade E (Poor): 0

Open-Access: This article is an open-access article that was selected by an in-house editor and fully peer-reviewed by external reviewers. It is distributed in accordance with the Creative Commons Attribution NonCommercial (CC BY-NC 4.0) license, which permits others to distribute, remix, adapt, build upon this work non-commercially, and license their derivative works on different terms, provided the original work is properly cited and the use is non-commercial. See: <http://creativecommons.org/licenses/by-nc/4.0/>

Received: July 11, 2021

Peer-review started: July 11, 2021

First decision: August 18, 2021

Revised: August 22, 2021

Accepted: October 27, 2021

Article in press: October 27, 2021

Published online: December 16, 2021

P-Reviewer: Abulsoud MI

S-Editor: Yan JP

L-Editor: Wang TQ

P-Editor: Yan JP



RESULTS

The average age of patients at the time of surgery was 13 mo, and the mean final follow-up occurred at 42 mo. An appropriate volume with a stable joint and good appearance was obtained in 14 reconstructed thumbs. An unstable interphalangeal joint occurred in one thumb. The flexion-extension arc at the metacarpophalangeal joint was good, while that at the interphalangeal joint was poor. Most of the parents were satisfied with the cosmetic and functional results of the reconstructed thumbs. The mean ALURRA score was 21.8 (range: 20-24), and the Tada score was 6.9 (range: 5-8). Compared with the non-operated side, the length of the operated thumb was approximately 95%, the girth was 89%, and the nail width was 82.9%. The mean ranges of motion were 62.1% of that of the unaffected thumb in the interphalangeal joint and 78.3% in the metacarpophalangeal joint.

CONCLUSION

Harvesting a pedicle flap from a severed thumb is a safe and reliable procedure. Defects of the preserved thumb, such as the skin, nail, and bone, can be effectively restored using the complex tissue flap.

Key Words: Thumb duplication; Deformity; Pedicle flap; Pedicle

©The Author(s) 2021. Published by Baishideng Publishing Group Inc. All rights reserved.

Core Tip: We found that an appropriate volume with a stable joint and good appearance was obtained in 14 reconstructed thumbs. An unstable interphalangeal joint occurred in one thumb. The mean ALURRA score was 21.8 (range: 20-24), and the Tada score was 6.9 (range: 5-8). Compared with the non-operated side, the length of the operated thumb was approximately 95%, the girth was 89%, and the nail width was 82.9%. The mean ranges of motion were 62.1% of that of the unaffected thumb in the interphalangeal joint and 78.3% in the metacarpophalangeal joint. Therefore, harvesting a pedicle flap from a severed thumb is a safe and reliable procedure. Defects of the preserved thumb, such as the skin, nail, and bone, can be effectively restored using the complex tissue flap.

Citation: Wang DH, Zhang GP, Wang ZT, Wang M, Han QY, Liu FX. Pedicle complex tissue flap transfer for reconstruction of duplicated thumbs with unequal size. *World J Clin Cases* 2021; 9(35): 10909-10918

URL: <https://www.wjgnet.com/2307-8960/full/v9/i35/10909.htm>

DOI: <https://dx.doi.org/10.12998/wjcc.v9.i35.10909>

INTRODUCTION

Thumb polydactyly is the most prevalent duplication in Caucasian and Asian populations, occurring in approximately 0.8 to 1.4 per 1000 births[1-4], impacting not only the appearance of the affected hand but also the function of thumb flexion and extension and grasping and pinching movements[5-7]. To better restore the function of the thumb, reconstruction surgery for thumb deformities should be performed early in the first year of life[8], which could help children to obtain a thumb similar to normal thumb anatomy with less growth impairment and to reconstruct thumb function during their growth and development.

The surgical strategy should be formulated according to the specific thumb deformity because thumb deformities are different for various children. There are many clinical diagnostic classifications of complex thumb deformity. At present, the Wassel classification is the most commonly used, which divides complex thumb deformity into seven types based on its type and grade of phalangeal division[9]. Currently, for a clear distinction between primary and redundant thumbs, a surgical strategy including resection of the redundant finger and reconstruction of the main thumb is generally adopted when the primary thumb is well developed. The Bilhaut-Cloquet procedure and its modified operation are often used to reconstruct symmetrical or essentially symmetrical thumb polydactyly with the same size as the

supernumerary finger[7,10]. However, reconstruction of thumb polydactyly correction is often associated with several problems, such as a slender and short reserved thumb, unstable joints, nail lateral deviation deformity, and a narrow skin defect in the first web space, which is a challenge for clinicians.

Thumb polydactyly is one of the most common congenital hand deformities; surgery for most conditions usually involves removal of the more hypoplastic thumb and reconstruction of the better thumb. When neither thumb is obviously dominant in all aspects or when a combination of the two thumbs is a better choice, the Bilhaut-Cloquet procedure or a modified one can be used. There are rare instances in which both thumbs are not of similar length or far apart in distance, in which case the Bilhaut-Cloquet procedure or a modified procedure is difficult to implement. In such cases, a useful procedure is to transfer a complex tissue flap on a neurovascular pedicle raised from the severed thumb to overcome the defect in length or distance.

Therefore, the purpose of this article is to deliver our experience on this kind of reconstruction and to report the follow-up outcomes in our series of patients.

MATERIALS AND METHODS

Choice of study participants

This retrospective study included patients who underwent duplicated thumb reconstruction by pedicle complex tissue flap transfer at the Shandong Provincial Hospital Affiliated to Shandong First Medical University from January 2014 to December 2020. The technique was used when it was necessary to combine different tissues from both severed and preserved thumbs that were not of similar length or far apart in distance. The patients had at least one of the following symptoms: There was a skin defect in the preserved thumb (Figure 1A); neither thumb was obviously dominant in all aspects, and there was a difference in length between the two thumbs that were intended to be combined together (Figure 1B); and there was a distance in space between the two thumbs that also had different defects, such as short and slender bulks, unstable joints, and nail deformities (Figure 1C).

Operation process

Detailed clinical assessments and radiological examinations are essential for hand surgeons to design an ideal reconstruction plan for duplicated thumbs. The clinical assessment addresses the soft tissue bulk and shape, the integrity of the nail folds, and the stability and the range and motion (ROM) in both interphalangeal joints (IPJs) and metacarpophalangeal joints (MCPJs). An X-ray of the opposite thumb is beneficial, especially when accompanied by the findings of the clinical examination to obtain as accurate information as possible. Ultrasound may assist in the assessment of neurovascular conditions of the thumbs but is not employed routinely.

The surgery was performed under general anesthesia and tourniquet control. Generally, the procedures are divided into three steps. First, preoperative assessments must determine which digit will provide the best thumb with an essentially stable osteoarticular structure, especially an adequate carpometacarpal joint. Second, tense skin relaxation and first web space broadening, partial cutoff of the deformed nail, diverse transverse or longitudinal osteotomy of metacarpal or phalangeal bones, and K-wire internal fixation are performed on the chosen thumb (Figures 2-4). Then, the defects are evaluated in all aspects. Finally, pedicle complex tissue flaps, according to the defects in all aspects, are carefully designed and elevated from the abandoned thumb to reconstruct the chosen thumb. Clinical manifestations, operating methods, and follow-up results are discussed by way of typical case reports in the following report.

Postoperative treatment

Spasmolysis and blood circulation-promoting drugs were routinely applied after the operation, and the digit was bandaged with external brace fixation. Six weeks after surgery, the internal fixation K-wires and external fixation were removed. Rehabilitation activities were allowed, including active and passive functional exercises of the operated digit.

Efficacy evaluation

The survival of pedicled tissue flaps was observed after the operation. The length and diameter of the reconstructed thumb and the contralateral healthy thumb, the finger

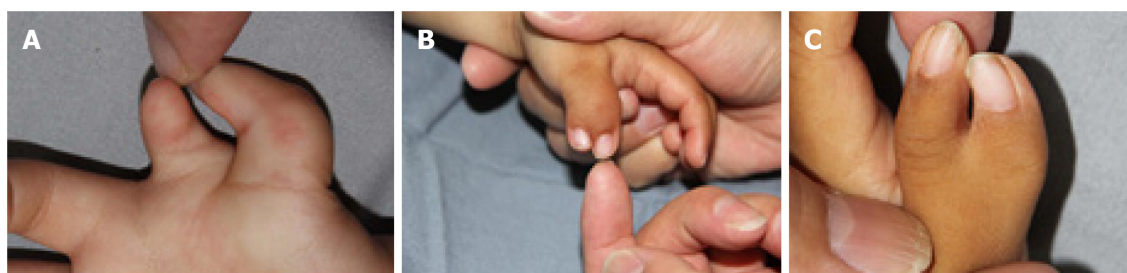

Figure 1 Three types of the included patients. A: Preservation of thumb body involving palmar skin defects of fingernails; B: Preservation of thumb body involving different lengths of fingernails; C: Preservation of thumb body narrow lateral deviation of fingernails.

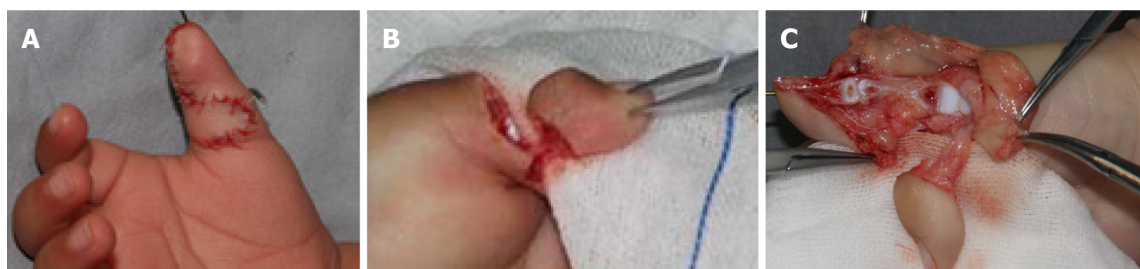

Figure 2 Surgical procedure of transfer flap. A: The excision of finger and flap was designed and transferred locally; B: The excision of nail flap was designed and transferred locally; C: The excision of composite tissue flap was designed and transferred locally.

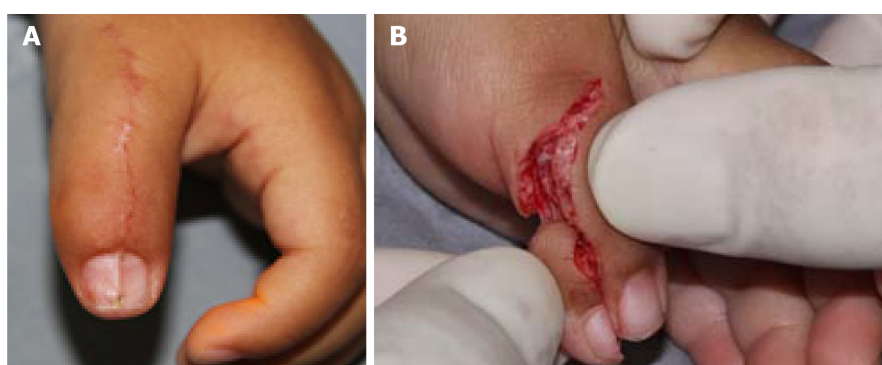


Figure 3 Operation process. A: Longitudinal ridge after nail fusion; B: The nail flap was pushed far away to maintain the length of the finger.

strength line, the stability and mobility of the MCPJ and IPJ, and the appearance of the nail were observed and recorded. These objective indexes were evaluated by the Horri Tata score system (Table 1) and the ALURRA score system[11] (Table 2). Meanwhile, the satisfaction of the parents of the children with the reconstruction of thumb appearance (aesthetic) and function was recorded.

Statistical analysis

All patients with thumb duplication were treated by pedicle complex tissue flap transfer. Sex distribution, weight, types of duplicated thumb, and nail deformity information were provided. Parametric data, including age, follow-up, range of motion and alignment deviation of the IPJ and MCPJ, aesthetic aspects including circumference, length, nail size, and nail deformities, ALURRA score, and Tata score are described as the mean \pm SD.

RESULTS

Patient demographics

In total, 15 patients involving eight males and seven females, were included in this

Table 1 TATA criteria of postoperative evaluation

Score	2	1	0
Range of motion ¹	> 70%	50%-70%	< 50%
Instability	-	No instability	Instability
Deformity	< 10°	10°-20°	> 20°
Cosmetic	Acceptable	Moderate deformity	Substantial deformity

¹Compared with the opposite side.

Results over or equal to 5 were categorized as good, 3 and 4 as fair, and less than 3 as poor.

Table 2 ALURRA criteria

Criteria	Score		
	2	1	0
Alignment	< 10°	10°-20°	> 20°
IP joint deviation (radial/ulnar)			
MP joint deviation (radial/ulnar)	< 10°	10°-20°	> 20°
Ulnar instability			
IP joint	< 5°	5°-15°	> 15°
MCP joint	< 20°	20°-40°	> 40°
Radial instability			
IP joint	< 5°	5°-15°	> 15°
MCP joint	< 20°	20°-40°	> 40°
Range of motion			
IP joint	> 70°	50°-70°	< 50°
MCP joint (% of opposite thumb)	> 70°	50°-70°	< 50°
Aesthetical aspects			
Circumference (% of opposite thumb)	75-100	50-75	< 50
Length	75-100	50-75	< 50
Nail size	75-100	50-75	< 50
Nail deformities	None	Small ridge	Severe deformation

A total score above 20 is categorized as good, between 13 and 20 as moderate, and less than 13 as poor. IP: Interphalangeal; MCP: Metacarpophalangeal.

study, with an average age at surgery of 13 mo (range: 10 mo to 2 years old). All 15 patients were followed from 20 to 60 mo, with a mean of 42 mo (Table 3). Due to the absence of cooperation, outcomes were measured using appearance, parent satisfaction, and ROM.

Efficacy evaluation

All pedicle complex tissue flaps survived well after the operation with no arterio-venous crises. The reconstructed thumbs in 14 patients obtained a good longitudinal axis, with appropriate length and girth matching the healthy contralateral thumbs. The reconstructed thumb girth of one child was larger than the contralateral thumb, which was further improved upon treatment by plastic surgery during the surgery for removing the internal fixation. The appearance of the nail was good, though there were various degrees of ridging of the nail after operation of the two halves in some patients (Figure 3). All the MCPJs and IPJs except for one joint of one thumb remained stable after the primary surgery. One case required revision due to IPJ radial collateral instability. The active and passive mobility levels of the MCPJs were good, the

Table 3 Demographic data of the included patients

Case	Sex	Term birth	Age (mo)	Weight (kg)	Wassel type	Follow-up	ALURRA criteria												Score	TATA criteria				Score
							Alignment (deviation)		Instability				ROM ¹		Aesthetical aspects ¹					ROM ¹	Instability	Deformity	Cometic	
							IPJ	MCPJ	IPJ (ulnar)	MCPJ (radial)	IPJ	MCPJ	Circumference	Length	Nail size	Nail deformities								
1	M	Yes	12	10	III	60	< 5	0	< 5	15	< 5	10	45	90	90	92	85	None	22	65	Yes	< 10°	Ac	6
2	F	No	13	10.5	IV	20	< 5	5	< 5	10	< 5	15	60	75	120	89	95	None	22	65	Yes	< 10°	Ac	6
3	F	Yes	11	9.5	IV	50	< 5	5	< 5	10	25	15	60	70	90	95	88	None	20	65	No	< 10°	Ac	5
4	M	No	12	10	V	34	< 5	5	< 5	12	< 5	10	65	75	74	80	70	None	21	70	Yes	< 10°	Ac	6
5	M	Yes	10	9	V	22	< 5	5	< 5	10	< 5	5	60	75	130	78	90	Small ridge	21	68	Yes	< 10°	Md	5
6	F	Yes	17	12	IV	46	< 5	6	< 5	10	< 5	10	75	85	80	75	80	None	24	80	Yes	< 10°	Ac	7
7	M	Yes	13	11	IV	49	< 5	4	< 5	14	< 5	8	80	78	85	80	74	None	23	80	Yes	< 10°	Ac	7
8	M	No	11	9	V	43	< 5	0	< 5	13	< 5	10	55	77	86	82	97	Small ridge	21	65	Yes	< 10°	Ac	6
9	M	Yes	24	15	V	53	< 5	0	< 5	10	< 5	5	75	85	118	85	94	None	23	80	Yes	< 10°	Ac	7
10	F	No	12	10.5	VI	56	< 5	8	< 5	10	< 5	15	55	60	80	86	72	None	20	55	Yes	< 10°	Ac	6
11	F	Yes	11	9	V	52	< 5	3	< 5	12	< 5	10	65	85	78	90	96	Small ridge	22	75	Yes	< 10°	Md	6
12	M	No	13	11	VI	46	< 5	4	< 5	15	< 5	10	50	70	79	78	81	None	23	60	Yes	< 10°	Ac	6
13	F	Yes	14	11	V	28	< 5	5	< 5	15	< 5	13	72	75	90	79	90	Small ridge	23	70	Yes	< 10°	Md	5
14	M	Yes	12	12	VI	27	< 5	6	< 5	15	< 5	8	55	80	79	84	70	None	21	66	Yes	< 10°	Ac	6
15	F	Yes	10	10	III	44	< 5	3	< 5	10	< 5	10	60	95	82	70	68	None	21	70	Yes	< 10°	Ac	6

	5														
mean	13	10.6	42	3.9	12.1	10.3	62.1	78.3	90.7	82.9	83.3	21.8	68.9	6	
SD	3.4	1.5	12.3	2.3	2.1	3.1	9.6	8.5	16.8	6.5	10.1	1.2	7.1	0.6	

¹Shows the % of opposite thumb.

ROM: Range and motion; MCPJ: Metacarpophalangeal joints; IPJ: Interphalangeal joints; Ac: Acceptable; Md: Moderate deformity.

mobility of the interphalangeal joints was diminished, and the active mobility was significantly diminished. Compared with the non-operated side, the length of the operated thumb was approximately 82.9%, the girth was 90.7%, and the nail width was 83.3%. The mean ROMs were 62.1% of the unaffected thumb in the IPJ and 78.3% in the MCPJ. MCPJ malalignment showed statistically significant negative correlations with the Tada, and ALURRA scores. Most of the parents were satisfied with the cosmetic and functional results of the reconstructed thumb. The mean ALURRA score was 21.8 (range: 20-24), and the Tada score was 6.9 (range: 5-8).

DISCUSSION

The basic goals of reconstruction surgery for thumb duplication are to obtain good appearance and function[12,13]. There are many important factors to be considered in the process of reconstruction surgery, including good finger line, sufficient circumference and length of finger, stable metacarpophalangeal and interphalangeal joints, adequate blood circulation, and keen sense function[14,15]. In the case of the poor development of the preserved thumb or even the poor development of both thumbs, it is necessary to cut a part of the tissue structure from the resected thumb to make up for the defects of the preserved thumb.

The Bilhaut-Cloquet procedure and its modified operation provided a sound solution to these situations involving symmetrical or essentially symmetrical compound thumbs, slender little finger bodies, joint deflection and instability, lateral deviation of the nail, and skin defects[16-19]. If the distance between the two thumbs is far or if they are different in length, BC and its modified operation have difficulty achieving good thumb results. Therefore, according to the condition of retaining the tissue defect of the thumb, a tissue flap pedicled with the neurovascular bundle of the finger can be designed and cut from the resected finger for long-distance transfer, which can effectively solve the above problems. Our study included 15 cases with a long distance between or different lengths of the two thumbs. We used the above method for surgical treatment, and good clinical outcomes were achieved during the follow-up.

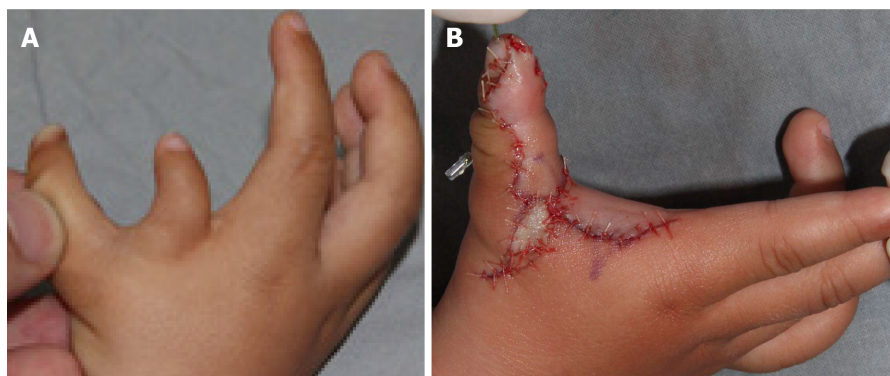

Figure 4 The design of the first web space. A: The narrow of the first web space and the thin and small finger were preserved before operation; B: The finger body was reconstructed by flap transfer and the first web space was enlarged.

When the two thumbs had different lengths (Figure 1B), we usually used the shorter thumb with pedicle extension and then combined it with the other thumb to keep the thumb length as long as possible (Figure 3B). The case presented in this study demonstrated that the pedicle can effectively extend to the distal end up to 1 cm, which is enough to compensate for the difference in length between the two thumbs. The skin defect of the proximal pedicle caused by the extension of the thumb to the distal end can be effectively covered by local skin.

When the distance between the two thumbs was relatively far, especially when combined with a narrow mouth in the thumb web (Figure 4A), a tissue flap pedicled with the digital nerve and vascular bundle for a longer distance transfer was used to achieve the combination of the two thumbs (Figure 4B). To achieve the distant transfer of pedicled tissue flaps, the vascular pedicle often needs to be free to the proximal end to reach the level of the metacarpal base. If the tissue mass is large, it can be transferred with a piece of dorsal reflux vein. A transverse design should be avoided in the incision at the thumb web to prevent contracture scarring.

In the process of bone joint splicing, especially the IPJ, epiphyseal plate butt joint and joint face joint connections were often contradictory. To preserve the growth potential of the phalanges, the epiphyseal plate butt joint had priority in handling and subsequently repairing the surface of the joint. In the follow-up cases, although the active and passive ranges of motion of the interphalangeal joint decreased, the joint was stable with a good holding function.

Nail splicing is an important step in the process of correcting compound thumb deformities. Tien *et al* [20] and Wang *et al* [21] performed an in-depth follow-up investigation and formulated the evaluation criteria in detail. To achieve enough width and good radians of regenerated nails and to prevent the occurrence of longitudinal ridges in the middle of nails, longitudinal oblique osteotomy of the distal phalanx can achieve a good arc fit of the nail bed. If the original nail is too narrow, we usually butt sutures after removing the nail and peeling off the nail bed from the upper part of the phalanx on the basis of the abovementioned treatment. In the follow-up, the regenerated nails achieved a good appearance. In conclusion, distal transfer of pedicled composite tissue flaps from thumb resection can effectively compensate for a variety of tissue defects of the thumb to achieve good therapeutic effects.

CONCLUSION

Harvesting a pedicle flap from the severed thumb is a safe and reliable procedure. Defects of the preserved thumb, such as the skin, nail, and bone, can be effectively restored with the complex tissue flap.

ARTICLE HIGHLIGHTS

Research background

Thumb polydactyly is one of the most common congenital hand deformities, and the Bilhaut-Cloquet procedure or a modified one is often used. However, controversy

remains over the rare instances in which both thumbs are not of similar length or far apart in distance.

Research motivation

Bilhaut-Cloquet procedure or a modified one is often used for thumb polydactyly. However, controversy remains over the rare instances in which both thumbs are not of similar length or far apart in distance.

Research objectives

To evaluate the clinical outcomes of pedicle complex tissue flap transfer in the treatment of duplicated thumbs with unequal size.

Research methods

We performed a cross-sectional study of patients who underwent duplicated thumb reconstruction by pedicle complex tissue flap transfer from January 2014 to December 2020.

Research results

An appropriate volume with a stable joint and good appearance was obtained in 14 reconstructed thumbs. The mean ALURRA score was 21.8 (range: 20-24), and the Tada score was 6.9 (range: 5-8). Compared with the non-operated side, the length of the operated thumb was approximately 95%, the girth was 89%, and the nail width was 82.9%. The mean ranges of motion were 62.1% of that of the unaffected thumb in the interphalangeal joint and 78.3% in the metacarpophalangeal joint.

Research conclusions

Harvesting a pedicle flap from a severed thumb is a safe and reliable procedure. Defects of the preserved thumb, such as the skin, nail, and bone, can be effectively restored using the complex tissue flap.

Research perspectives

Pedicle complex tissue flap transfer should be the initial management strategy for patients with duplicated thumbs with unequal size. In the future, more controlled studies with multicenter samples will be needed to confirm this finding.

REFERENCES

- 1 Van Wyhe RD, Trost JG, Koshy JC, Pederson WC. The Duplicated Thumb: A Review. *Semin Plast Surg* 2016; **30**: 181-188 [PMID: 27895541 DOI: 10.1055/s-0036-1593736]
- 2 Comer GC, Potter M, Ladd AL. Polydactyly of the Hand. *J Am Acad Orthop Surg* 2018; **26**: 75-82 [PMID: 29309292 DOI: 10.5435/JAAOS-D-16-00139]
- 3 Thomas BP, Pallapati S. Congenital thumb differences- current concepts. *J Clin Orthop Trauma* 2020; **11**: 580-589 [PMID: 32684694 DOI: 10.1016/j.jcot.2020.06.018]
- 4 Dobyns JH, Lipscomb PR, Cooney WP. Management of thumb duplication. *Clin Orthop Relat Res* 1985; **26**: 44 [PMID: 2983920 DOI: 10.1097/00003086-198505000-00004]
- 5 Ogino T, Ishii S, Takahata S, Kato H. Long-term results of surgical treatment of thumb polydactyly. *J Hand Surg Am* 1996; **21**: 478-486 [PMID: 8724483 DOI: 10.1016/S0363-5023(96)80366-2]
- 6 Yeung CM, Choi AKY, Tong JWS, Fok W, Chan YF, Chow YY. Long-Term Results of Surgically Treated Radial Polydactyly - An Outcome Correlation Study. *J Hand Surg Asian Pac Vol* 2019; **24**: 264-269 [PMID: 31438788 DOI: 10.1142/S2424835519500322]
- 7 Chang CF, Chen IC, Tsai YC, Lai CS, Chen YW, Lu CT, Yen JH. Transposition of Duplicated Thumb for Reconstruction of Asymmetric Radial Polydactyly. *Ann Plast Surg* 2019; **82**: S13-S17 [PMID: 30461458 DOI: 10.1097/SAP.0000000000001722]
- 8 Tada K, Yonenobu K, Tsuyuguchi Y, Kawai H, Egawa T. Duplication of the thumb. A retrospective review of two hundred and thirty-seven cases. *J Bone Joint Surg Am* 1983; **65**: 584-598 [PMID: 6853563 DOI: 10.2106/00004623-198365050-00002]
- 9 Wassel HD. The results of surgery for polydactyly of the thumb. A review. *Clin Orthop Relat Res* 1969; **64**: 175-193 [PMID: 4894526 DOI: 10.1103/PhysRev.76.1538.2]
- 10 Hu CH, Thompson ER, Agel J, Bauer AS, Moeller AT, Novotny SA, Van Heest AE, Bohn DC; CoULD Registry Study Group. A Comparative Analysis of 150 Thumb Polydactyly Cases from the CoULD Registry Using the Wassel-Flatt, Rotterdam, and Chung Classifications. *J Hand Surg Am* 2021; **46**: 17-26 [PMID: 32873448 DOI: 10.1016/j.jhsa.2020.06.009]
- 11 Lim YB, Seul JH, Nam HJ, Woo SH. Extended Indications of Bilhaut-Cloquet Procedure for Type III and IV of Duplicated Thumb. *J Korean Soc Plast Reconstr Surg* 2011; **38**: 821-828

- 12 **Tonkin MA.** Thumb duplication: concepts and techniques. *Clin Orthop Surg* 2012; **4**: 1-17 [PMID: 22379552 DOI: 10.4055/cios.2012.4.1.1]
- 13 **Cabrera González M,** Pérez López LM, Martínez Soto G, Gutiérrez de la Iglesia D. Prognostic value of age and Wassel classification in the reconstruction of thumb duplication. *J Child Orthop* 2013; **7**: 551-557 [PMID: 24432120 DOI: 10.1007/s11832-013-0534-3]
- 14 **Tonkin MA,** Bulstrode NW. The Bilhaut-Cloquet procedure for Wassel types III, IV and VII thumb duplication. *J Hand Surg Eur Vol* 2007; **32**: 684-693 [PMID: 17993432 DOI: 10.1016/J.JHSE.2007.05.021]
- 15 **Al-Qattan MM,** Kattan AE, Al-Lazzam A, Gelidan AG. A Modified Bilhaut-Cloquet Procedure for Zigzag Thumb Polydactyly Types III and IV. *Plast Reconstr Surg Glob Open* 2017; **5**: e1589 [PMID: 29632769 DOI: 10.1097/GOX.0000000000001589]
- 16 **Baek GH,** Gong HS, Chung MS, Oh JH, Lee YH, Lee SK. Modified Bilhaut-Cloquet procedure for Wassel type-II and III polydactyly of the thumb. *J Bone Joint Surg Am* 2007; **89**: 534-541 [PMID: 17332102 DOI: 10.2106/JBJS.F.00812]
- 17 **Baek GH,** Gong HS, Chung MS, Oh JH, Lee YH, Lee SK. Modified Bilhaut-Cloquet procedure for Wassel type-II and III polydactyly of the thumb. Surgical technique. *J Bone Joint Surg Am* 2008; **90** Suppl 2 Pt 1: 74-86 [PMID: 18310688 DOI: 10.2106/JBJS.G.01104]
- 18 **Dautel G,** Perrin P. Use of an Axial Flap to Increase the Girth of Wassel IV Thumb Reconstructions. *J Hand Surg Am* 2015; **40**: 1327-1332 [PMID: 25892712 DOI: 10.1016/j.jhsa.2015.02.032]
- 19 **Abid A,** Accadbled F, Knorr G, Darodes P, Cahuzac JP, Sales de Gauzy J. Type IV-D thumb duplication: A new reconstruction method. *Orthop Traumatol Surg Res* 2010; **96**: 521-524 [PMID: 20594929 DOI: 10.1016/j.otsr.2010.01.013]
- 20 **Tien YC,** Chih TT, Wang TL, Fu YC, Chen JC. Soft tissue reconstruction for type IV-D duplicated thumb: a new surgical technique. *J Pediatr Orthop* 2007; **27**: 462-466 [PMID: 17513971 DOI: 10.1097/01.bpb.0000271315.80374.68]
- 21 **Wang AY,** Gao WY, Wu LM, Li ZJ, Chen XL, Li XY. Nail Fusion Plasty: Nail Cosmetic Results and Assessment Criteria of Nail Reconstruction. *Ann Plast Surg* 2015; **75**: 290-294 [PMID: 25003436 DOI: 10.1097/SAP.0000000000000212]



Published by **Baishideng Publishing Group Inc**
7041 Koll Center Parkway, Suite 160, Pleasanton, CA 94566, USA

Telephone: +1-925-3991568

E-mail: bpgoffice@wjgnet.com

Help Desk: <https://www.f6publishing.com/helpdesk>

<https://www.wjgnet.com>

