

# World Journal of *Clinical Cases*

*World J Clin Cases* 2021 December 26; 9(36): 11122-11508



## Contents

Weekly Volume 9 Number 36 December 26, 2021

## REVIEW

- 11122** Diet and microbiome in the beginning of the sequence of gut inflammation  
*Ceballos D, Hernández-Camba A, Ramos L*

## MINIREVIEWS

- 11148** Stem cell therapy: A promising treatment for COVID-19  
*Zheng ZX*

## ORIGINAL ARTICLE

## Case Control Study

- 11156** Association between serum Sestrin2 level and diabetic peripheral neuropathy in type 2 diabetic patients  
*Mao EW, Cheng XB, Li WC, Kan CX, Huang N, Wang HS, Hou NN, Sun XD*
- 11165** Plasma brain natriuretic peptide, platelet parameters, and cardiopulmonary function in chronic obstructive pulmonary disease  
*Guo HJ, Jiang F, Chen C, Shi JY, Zhao YW*

## Retrospective Cohort Study

- 11173** Analysis of the incidence and influencing factors of hyponatremia before <sup>131</sup>I treatment of differentiated thyroid carcinoma  
*Cao JJ, Yun CH, Xiao J, Liu Y, Wei W, Zhang W*

## Retrospective Study

- 11183** Cognitive magnetic resonance imaging-ultrasound fusion transperineal targeted biopsy combined with randomized biopsy in detection of prostate cancer  
*Pang C, Wang M, Hou HM, Liu JY, Zhang ZP, Wang X, Zhang YQ, Li CM, Zhang W, Wang JY, Liu M*
- 11193** Nomogram based on inflammation-related markers for predicting survival of patients undergoing hepatectomy for hepatocellular carcinoma  
*Pu T, Li ZH, Jiang D, Chen JM, Guo Q, Cai M, Chen ZX, Xie K, Zhao YJ, Liu FB*
- 11208** Association of frailty with in-hospital outcomes in elderly patients with heart failure  
*Kang YP, Chen LY, Zhu JJ, Liu WX, Ma CS*
- 11220** COVID-19 pandemic and exacerbation of ulcerative colitis  
*Suda T, Takahashi M, Katayama Y, Tamano M*
- 11228** Surgical perspectives of symptomatic omphalomesenteric duct remnants: Differences between infancy and beyond  
*Kang A, Kim SH, Cho YH, Kim HY*

- 11237** Clustering cases of *Chlamydia psittaci* pneumonia mimicking COVID-19 pneumonia

*Zhao W, He L, Xie XZ, Liao X, Tong DJ, Wu SJ, Liu J*

- 11248** Sodium nitroprusside injection immediately before balloon inflation during percutaneous coronary intervention

*Yu Y, Yang BP*

- 11255** Machine learning approach to predict acute kidney injury after liver surgery

*Dong JF, Xue Q, Chen T, Zhao YY, Fu H, Guo WY, Ji JS*

- 11265** Application effect for a care bundle in optimizing nursing of patients with severe craniocerebral injury

*Gao Y, Liao LP, Chen P, Wang K, Huang C, Chen Y, Mou SY*

### Clinical Trials Study

- 11276** Influence of pontic design of anterior fixed dental prosthesis on speech: A clinical case study

*Wan J, Cai H, Wang T, Chen JY*

### Observational Study

- 11285** Real-world data on the infliximab biosimilar CT-P13 (Remsima®) in inflammatory bowel disease

*Huguet JM, Cortés X, Bosca-Watts MM, Aguas M, Maroto N, Martí L, Amorós C, Paredes JM*

- 11300** Correlation of periodontal inflamed surface area with glycemic status in controlled and uncontrolled type 2 diabetes mellitus

*Anil K, Vadakkekuttikal RJ, Radhakrishnan C, Parambath FC*

- 11311** Audiological characteristics and exploratory treatment of a rare condition of acute-otitis-media-associated sudden sensorineural hearing loss

*Cao X, Yi HJ*

- 11320** Yield of testing for micronutrient deficiencies associated with pancreatic exocrine insufficiency in a clinical setting: An observational study

*Jalal M, Campbell JA, Tesfaye S, Al-Mukhtar A, Hopper AD*

### Prospective Study

- 11330** Birthing ball on promoting cervical ripening and its influence on the labor process and the neonatal blood gas index

*Shen HC, Wang H, Sun B, Jiang LZ, Meng Q*

### CASE REPORT

- 11338** Mucormycosis – resurgence of a deadly opportunist during COVID-19 pandemic: Four case reports

*Upadhyay S, Bharara T, Khandait M, Chawdhry A, Sharma BB*

- 11346** Ductal breast carcinoma metastasized to the rectum: A case report and review of the literature

*Ban B, Zhang K, Li JN, Liu TJ, Shi J*

- 11355** De Garengeot hernia with avascular necrosis of the appendix: A case report  
*Yao MQ, Yi BH, Yang Y, Weng XQ, Fan JX, Jiang YP*
- 11362** Mature mediastinal bronchogenic cyst with left pericardial defect: A case report  
*Zhu X, Zhang L, Tang Z, Xing FB, Gao X, Chen WB*
- 11369** Difficulties in diagnosing anorectal melanoma: A case report and review of the literature  
*Apostu RC, Stefanescu E, Scurtu RR, Kacso G, Drasovean R*
- 11382** Solid pseudopapillary neoplasm of the pancreas in a young male with main pancreatic duct dilatation: A case report  
*Nakashima S, Sato Y, Imamura T, Hattori D, Tamura T, Koyama R, Sato J, Kobayashi Y, Hashimoto M*
- 11392** Acute myocardial infarction in a young man with ankylosing spondylitis: A case report  
*Wan ZH, Wang J, Zhao Q*
- 11400** Acute appendicitis complicated by mesenteric vein thrombosis: A case report  
*Yang F, Guo XC, Rao XL, Sun L, Xu L*
- 11406** Inguinal endometriosis: Ten case reports and review of literature  
*Li SH, Sun HZ, Li WH, Wang SZ*
- 11419** Dramatic response to immunotherapy in an epidermal growth factor receptor-mutant non-small cell lung cancer: A case report  
*Li D, Cheng C, Song WP, Ni PZ, Zhang WZ, Wu X*
- 11425** Three-dimensional inlay-guided endodontics applied in variant root canals: A case report and review of literature  
*Yan YQ, Wang HL, Liu Y, Zheng TJ, Tang YP, Liu R*
- 11437** Ectopic pregnancy implanted under the diaphragm: A rare case report  
*Wu QL, Wang XM, Tang D*
- 11443** Ear ischemia induced by endovascular therapy for arteriovenous fistula of the sigmoid sinus: A case report  
*Li W, Zhang SS, Gao XR, Li YX, Ge HJ*
- 11448** Giant schwannoma of thoracic vertebra: A case report  
*Zhou Y, Liu CZ, Zhang SY, Wang HY, Nath Varma S, Cao LQ, Hou TT, Li X, Yao BJ*
- 11457** Severe digital ischemia coexists with thrombocytopenia in malignancy-associated antiphospholipid syndrome: A case report and review of literature  
*Chen JL, Yu X, Luo R, Liu M*
- 11467** Rare spontaneous extensive annular intramural esophageal dissection with endoscopic treatment: A case report  
*Hu JW, Zhao Q, Hu CY, Wu J, Lv XY, Jin XH*

- 11475** Mucinous cystic neoplasm of the liver: A case report  
*Yu TY, Zhang JS, Chen K, Yu AJ*
- 11482** Retroperitoneal parasitic fetus: A case report  
*Xia B, Li DD, Wei HX, Zhang XX, Li RM, Chen J*
- 11487** De novo mutation loci and clinical analysis in a child with sodium taurocholate cotransport polypeptide deficiency: A case report  
*Liu HY, Li M, Li Q*
- 11495** Surgery for hepatocellular carcinoma with tumor thrombosis in inferior vena cava: A case report  
*Zhang ZY, Zhang EL, Zhang BX, Zhang W*

**LETTER TO THE EDITOR**

- 11504** Advantages and issues of concern regarding approaches to peripheral nerve block for total hip arthroplasty  
*Crisci M, Cuomo A, Forte CA, Bimonte S, Esposito G, Tracey MC, Cascella M*

**ABOUT COVER**

Editorial Board Member of *World Journal of Clinical Cases*, Moises Rodriguez-Gonzalez, MD, Adjunct Professor, Senior Researcher, Department of Pediatric Cardiology, Hospital Universitario Puerta del Mar, Cadiz 11009, Spain. doctormoisesrodriguez@gmail.com

**AIMS AND SCOPE**

The primary aim of *World Journal of Clinical Cases* (WJCC, *World J Clin Cases*) is to provide scholars and readers from various fields of clinical medicine with a platform to publish high-quality clinical research articles and communicate their research findings online.

WJCC mainly publishes articles reporting research results and findings obtained in the field of clinical medicine and covering a wide range of topics, including case control studies, retrospective cohort studies, retrospective studies, clinical trials studies, observational studies, prospective studies, randomized controlled trials, randomized clinical trials, systematic reviews, meta-analysis, and case reports.

**INDEXING/ABSTRACTING**

The WJCC is now indexed in Science Citation Index Expanded (also known as SciSearch®), Journal Citation Reports/Science Edition, Scopus, PubMed, and PubMed Central. The 2021 Edition of Journal Citation Reports® cites the 2020 impact factor (IF) for WJCC as 1.337; IF without journal self cites: 1.301; 5-year IF: 1.742; Journal Citation Indicator: 0.33; Ranking: 119 among 169 journals in medicine, general and internal; and Quartile category: Q3. The WJCC's CiteScore for 2020 is 0.8 and Scopus CiteScore rank 2020: General Medicine is 493/793.

**RESPONSIBLE EDITORS FOR THIS ISSUE**

Production Editor: Ji-Hong Lin; Production Department Director: Xu Guo; Editorial Office Director: Jin-Lei Wang.

**NAME OF JOURNAL**

*World Journal of Clinical Cases*

**ISSN**

ISSN 2307-8960 (online)

**LAUNCH DATE**

April 16, 2013

**FREQUENCY**

Weekly

**EDITORS-IN-CHIEF**

Bao-Gan Peng

**EDITORIAL BOARD MEMBERS**

<https://www.wjgnet.com/2307-8960/editorialboard.htm>

**PUBLICATION DATE**

December 26, 2021

**COPYRIGHT**

© 2022 Baishideng Publishing Group Inc

**INSTRUCTIONS TO AUTHORS**

<https://www.wjgnet.com/bpg/gerinfo/204>

**GUIDELINES FOR ETHICS DOCUMENTS**

<https://www.wjgnet.com/bpg/GerInfo/287>

**GUIDELINES FOR NON-NATIVE SPEAKERS OF ENGLISH**

<https://www.wjgnet.com/bpg/gerinfo/240>

**PUBLICATION ETHICS**

<https://www.wjgnet.com/bpg/GerInfo/288>

**PUBLICATION MISCONDUCT**

<https://www.wjgnet.com/bpg/gerinfo/208>

**ARTICLE PROCESSING CHARGE**

<https://www.wjgnet.com/bpg/gerinfo/242>

**STEPS FOR SUBMITTING MANUSCRIPTS**

<https://www.wjgnet.com/bpg/GerInfo/239>

**ONLINE SUBMISSION**

<https://www.f6publishing.com>



## De Garengeot hernia with avascular necrosis of the appendix: A case report

Min-Quan Yao, Bing-Hong Yi, Yong Yang, Xiao-Qi Weng, Jin-Xing Fan, Yu-Peng Jiang

**ORCID number:** Min-Quan Yao 0000-0001-8567-9021; Bing-Hong Yi 0000-0003-0498-7204; Yong Yang 0000-0002-7785-8182; Xiao-Qi Weng 0000-0001-5194-3883; Jin-Xing Fan 0000-0003-2003-7858; Yu-Peng Jiang 0000-0001-9250-3606.

**Author contributions:** Yao MQ and Yi BH wrote the manuscript; Yang Y and Weng XQ collected the information and images; Jiang YP and Fan JX reviewed the manuscript; all authors were involved in drafting the manuscript and revising it critically for important intellectual content, read and approved the final manuscript and take public responsibility for appropriate portions of the content and have agreed to be accountable for all aspects of the work.

**Informed consent statement:** Informed consent was obtained from the patient for publication of this report.

**Conflict-of-interest statement:** The authors declare no conflicts of interest.

**CARE Checklist (2016) statement:** The authors have read the CARE Checklist (2016), and the manuscript was prepared and revised according to the CARE Checklist (2016).

**Min-Quan Yao, Bing-Hong Yi, Yong Yang, Xiao-Qi Weng, Jin-Xing Fan, Yu-Peng Jiang,** Departments of Gastrointestinal Surgery, Tongxiang First People's Hospital, Jiaxing 314500, Zhejiang Province, China

**Corresponding author:** Yu-Peng Jiang, BSc, Surgeon, Departments of Gastrointestinal Surgery, Tongxiang First People's Hospital, No. 1918 Jiaochang East Road, Jiaxing 314500, Zhejiang Province, China. [13567321611@qq.com](mailto:13567321611@qq.com)

### Abstract

#### BACKGROUND

An incarcerated hernia is a common cause of acute abdominal pain. There are various types of incarcerated hernias, including incarcerated hernias of the appendix. These hernias are often complicated by appendiceal inflammation, necrosis, and suppuration, which affect the outcome of surgical repair. A De Garengeot hernia is a femoral hernia that contains the appendix. This type of hernia has a low incidence. When a De Garengeot hernia is clinically suspected, emergency surgical treatment should be performed as soon as possible.

#### CASE SUMMARY

A 59-year-old man was admitted to the hospital with a painful right inguinal mass that had suddenly developed 6 hours earlier. Physical examination revealed a 4 cm × 2 cm palpable mass in the right groin. The mass was hard and could not be reduced due to tenderness. It did not descend into the scrotum. B-ultrasound revealed an incarcerated hernia. During surgery, the hernia was found to contain the appendix, which exhibited distal avascular necrosis. A De Garengeot hernia was diagnosed according to the classification criteria of this type of inguinal hernia. Laparoscopic reduction of the incarcerated hernia, appendectomy, and small-incision femoral hernia repair were performed in the emergency department, and cefuroxime was administered as anti-infection therapy for 2 d postoperatively. After treatment, the patient had no abdominal pain or infection and was discharged on postoperative day 4. He had no recurrence of the inguinal hernia after 16 months of follow-up.

#### CONCLUSION

De Garengeot hernias have a low incidence and are difficult to diagnose. Laparoscopy is useful for their diagnosis and treatment.

**Key Words:** De Garengeot hernia; Incarcerated hernia; Avascular necrosis; Femoral hernia;

**Supported by** Zhejiang Provincial Medical Science Research Foundation, No. 2020ZH053 and No. 2021KY1133.

**Country/Territory of origin:** China

**Specialty type:** Surgery

**Provenance and peer review:** Unsolicited article; Externally peer reviewed.

**Peer-review model:** Single blind

**Peer-review report's scientific quality classification**

Grade A (Excellent): 0  
Grade B (Very good): B  
Grade C (Good): C, C, C  
Grade D (Fair): 0  
Grade E (Poor): 0

**Open-Access:** This article is an open-access article that was selected by an in-house editor and fully peer-reviewed by external reviewers. It is distributed in accordance with the Creative Commons Attribution NonCommercial (CC BY-NC 4.0) license, which permits others to distribute, remix, adapt, build upon this work non-commercially, and license their derivative works on different terms, provided the original work is properly cited and the use is non-commercial. See: <http://creativecommons.org/licenses/by-nc/4.0/>

**Received:** April 27, 2021

**Peer-review started:** April 27, 2021

**First decision:** June 5, 2021

**Revised:** June 6, 2021

**Accepted:** August 16, 2021

**Article in press:** August 16, 2021

**Published online:** December 26, 2021

**P-Reviewer:** Ferreira GSA, Strainiene S

**S-Editor:** Wu YXJ

**L-Editor:** Webster JR

**P-Editor:** Wang LYT



Laparoscopy; Case report

©The Author(s) 2021. Published by Baishideng Publishing Group Inc. All rights reserved.

**Core Tip:** Clinicians should be aware of the fact that a De Garegeot hernia has a low incidence and is difficult to diagnose in the early stages. When a De Garegeot hernia is clinically suspected, B-ultrasound or computed tomography and emergency surgical treatment should be performed as soon as possible. Laparoscopy is useful for the diagnosis and treatment of De Garegeot hernias and is thus worthy of clinical application.

**Citation:** Yao MQ, Yi BH, Yang Y, Weng XQ, Fan JX, Jiang YP. De Garegeot hernia with avascular necrosis of the appendix: A case report. *World J Clin Cases* 2021; 9(36): 11355-11361

**URL:** <https://www.wjgnet.com/2307-8960/full/v9/i36/11355.htm>

**DOI:** <https://dx.doi.org/10.12998/wjcc.v9.i36.11355>

## INTRODUCTION

Clinically, incarcerated hernias include an incarcerated hernia of part of the intestinal wall (Richter hernia), a small intestinal diverticulum-containing incarcerated hernia (Littre hernia), a retrograde loop incarcerated hernia (Maydl hernia), and an incarcerated hernia of the appendix[1]. A De Garegeot hernia contains the appendix, which is often complicated by inflammation, necrosis, and suppuration, affecting the outcome of surgical repair[2]. De Garegeot hernias have a low incidence that tends to be consistent with the incidence pattern of femoral hernias, and they are more common in older women[3]. We admitted a patient with an incarcerated hernia on December 10, 2019, who was diagnosed intraoperatively with a De Garegeot hernia and avascular necrosis of the appendix.

## CASE PRESENTATION

### Chief complaint

A 59-year-old man was admitted to hospital with a painful right groin mass that had suddenly developed 6 h earlier.

### History of present illness

The pain was located in the inguinal region, and the mass did not descend into the scrotum. The patient reported nausea and vomiting, but he had no fever, diarrhea, hemochezia, or associated dysuria.

### History of past illness

The patient had a 10-year history of hypertension that was controlled with valsartan at 40 mg once daily.

### Personal and family history

He had smoked approximately 10 cigarettes daily for 20 years and did not drink. The patient's family history was negative.

### Physical examination

On admission, the patient showed normal consciousness and had evidence of acute illness, a flat and soft abdomen, and mild tenderness in the right lower abdomen with no rebound pain. A hard 4 cm × 2 cm mass was palpable in the right groin, and it was unable to be reduced due to tenderness. The mass did not descend into the scrotum, and the skin in the groin area showed no obvious redness or swelling.



### Laboratory examinations

Examination after admission showed a white blood cell count of  $4.6 \times 10^9/L$  (75.4% neutrophils), red blood cell count of  $5.29 \times 10^{12}/L$ , platelet count of  $153.0 \times 10^9/L$ , and C-reactive protein concentration of 25.2 mg/L. The prothrombin time was 10.9 s, activated partial thromboplastin time was 32.5 s, and international normalized ratio was 1.01. The blood urea nitrogen concentration was 9.2 mmol/L, the serum creatinine concentration was 84  $\mu\text{mol}/L$ , and the alanine aminotransferase concentration was 39 U/L.

### Imaging examinations

Inguinal B-ultrasound showed involvement of the right inguinal canal with no obvious reduction after pressurization with probes. Color Doppler flow imaging indicated no change in blood flow, and scanning of the left groin area showed no obvious abnormalities (Figure 1).

## FINAL DIAGNOSIS

The appendix was herniated into the femoral ring, leading to a definitive diagnosis of a De Garengeot hernia.

## TREATMENT

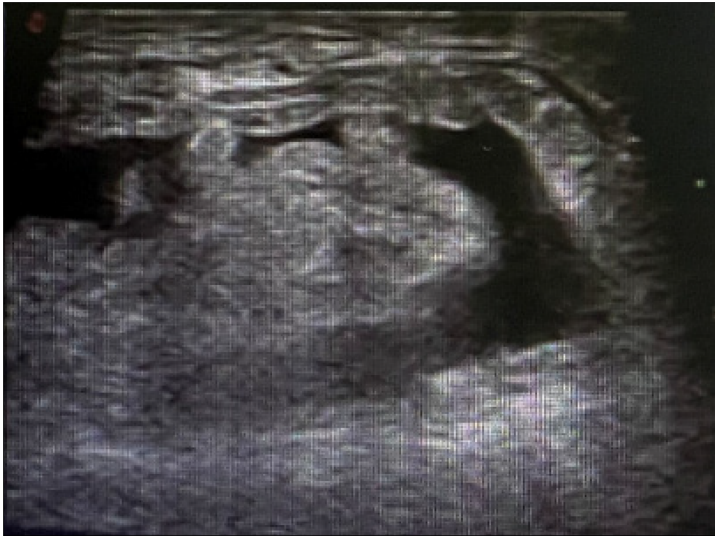A right-sided incarcerated hernia was considered, and laparoscopic exploration was performed under general anesthesia in the emergency department. During surgery, the appendix and its mesangium were found to be herniated into the femoral ring. The 3-cm most proximal segment of the appendix was in the abdominal cavity, and its color was normal (Figure 2). The proximal appendix was pulled and assisted manual reduction was attempted, but the hernia could not be reduced. The 2-cm section of peritoneum above the femoral ring was cut in an arc to detach the preperitoneal space and thus expose the iliopubic tract (Figure 3). After cutting part of the iliopubic tract using an electric hook to loosen the hernia ring and return the appendix, we found that the distal appendix and its mesangium were dark in color and demonstrated avascular necrosis (Figure 4). After reduction, the femoral ring was clear (Figure 5). The necrotic appendix was removed by laparoscopic surgery, and the roots were ligated using double silk sutures. Considering that patch placement after surgery had a high risk of serious complications such as patch infection, a small incision was made in the right groin to suture the internal oblique muscle and syndesmosis to the pectineal ligament. The right femoral hernia was then repaired using the McVay method. The postoperative pathology report showed that a large number of neutrophils had infiltrated the wall of the appendix and mesangial fat, and hemorrhagic necrosis was also observed in the mesangium (Figure 6).

## OUTCOME AND FOLLOW-UP

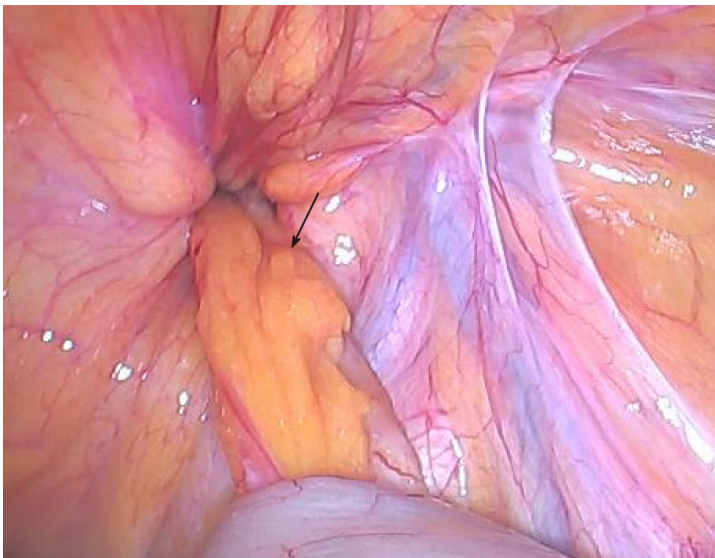
The surgical course was smooth, and cefuroxime was administered as anti-infection therapy for 2 d after surgery. The patient was discharged 4 d after surgery without complications such as wound infection. He had no recurrence of the inguinal hernia after 16 mo of follow-up.

## DISCUSSION

Incarcerated hernias of the groin and strangulated hernias require timely emergency surgery. Delays in diagnosis and surgery greatly increase the possibility of intestinal necrosis, which markedly increases the incidence of postoperative complications and mortality[4]. Amyand hernias have a low incidence, accounting for less than 1% of all inguinal hernias. Amyand hernias with complications, such as inflammation, perforation, or abscess formation, are even rarer, with an incidence of approximately 0.1%[5]. De Garengeot hernias are much rarer than Amyand hernias, with a reported incidence of 0.5% to 5.0% of all femoral hernias[6]. Due to the narrow femoral ring, a



**Figure 1 Inguinal B-ultrasound.** The right inguinal canal was involved, and there was no obvious reduction after pressurization with probes.

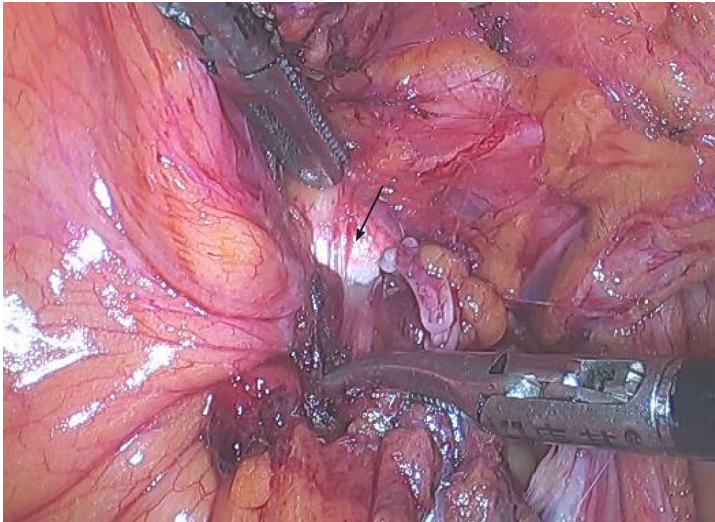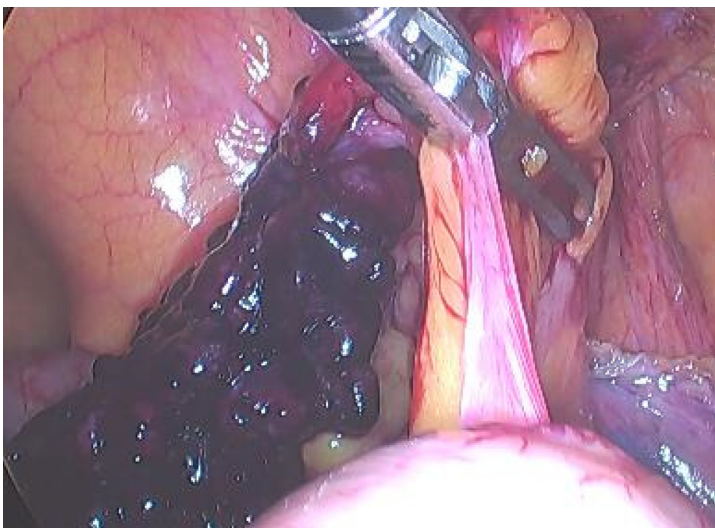


**Figure 2 Appendix and femoral ring.** The arrow shows the appendix. The appendix and its mesangium were herniated into the femoral ring without reduction, and the color of the proximal segment was normal.

De Garengeot hernia has a much higher risk of strangulation than an Amyand hernia [7]. De Garengeot hernias are difficult to diagnose before surgery; thus, they are easily misdiagnosed and may be missed clinically. The mechanism underlying the development of a De Garengeot hernia is compression of the neck of the hernia ring, which causes extraluminal obstruction. Muscle contraction or any other cause of a sudden increase in intra-abdominal pressure may cause compression of the appendix, and its blood supply may be subsequently interrupted or significantly reduced, leading to inflammation and bacterial overgrowth[8]. Whether appendectomy should be performed in patients with a healthy appendix and whether patch repair should be adopted after appendectomy remain controversial. Laparoscopic exploration enables visual observation of the abdominal cavity and hernia, and can be used to diagnose a De Garengeot hernia, assess the condition of the appendix, and choose the subsequent treatment regimen (appendectomy, femoral hernia repair, or transabdominal preperitoneal prosthetic and laparoscopic appendectomy)[9]. The choice of the most appropriate surgical method depends on whether the appendix is inflamed and, if so, the severity of inflammation (Table 1). If the appendix is not inflamed, laparoscopic patch repair is recommended. If appendicitis is observed but peritonitis is not, and if tissue conditions permit, laparoscopic appendectomy and patch repair can be performed[10]. When inflammation of the appendix is severe, patch repair may have

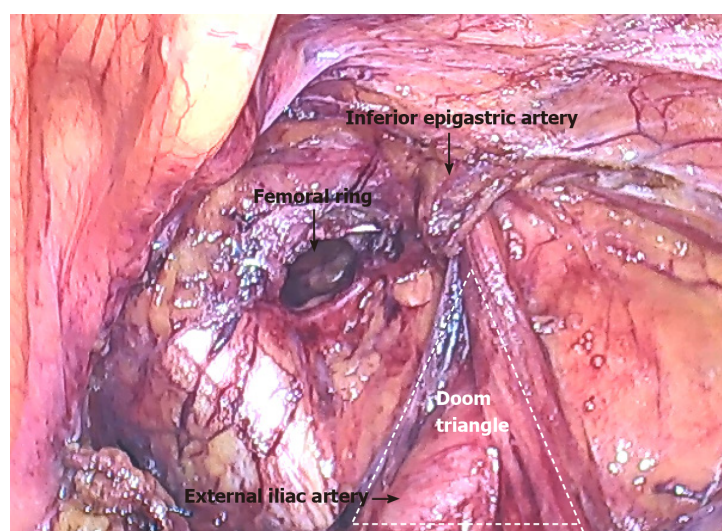
**Table 1 Surgical methods as determined by severity of appendiceal inflammation**

Appendiceal inflammation	Interventions
No inflammation	Return the appendix and perform laparoscopic patch repair
Non-severe inflammation	Laparoscopic appendectomy and patch repair
Severe inflammation with perforation or abscess formation	Laparoscopic appendectomy and mesh-free repair

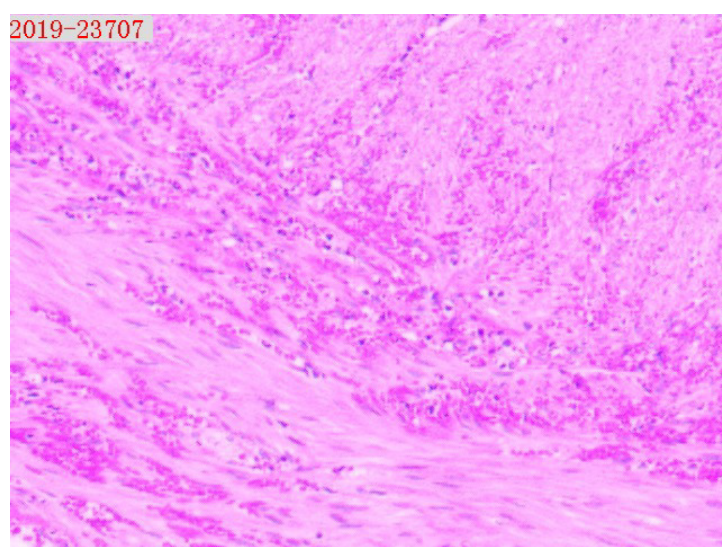
**Figure 3 Iliopubic tract.** The arrow shows the iliopubic tract. Part of the iliopubic tract was cut using an electric hook to return the appendix.**Figure 4 Distal segment of the appendix.** The distal segment of the appendix and its mesangium were dark in color with avascular necrosis and surface exudation.

an infection rate as high as 50%[11]; therefore, this form of repair is not recommended. Due to avascular necrosis of the appendix, patch repair may complicate infection. Thus, the patient in the present case underwent appendectomy and hernia repair using the conventional McVay method. The patient was discharged from the hospital 4 d after surgery. One week after surgery, he returned to hospital for suture removal, and no evidence of incisional infection was present.





**Figure 5 Femoral ring.** After reduction, the femoral ring could be observed. The partially severed iliopubic tract is shown.



**Figure 6 Pathological analysis of the appendix.** The postoperative pathology report showed that a large number of neutrophils had infiltrated the wall of the appendix and mesangial fat, and hemorrhagic necrosis was also observed in the mesangium. Magnification: 50 ×.

## CONCLUSION

Clinicians should be aware of the fact that De Garengeot hernias have a low incidence and are difficult to diagnose in the early stages. When a De Garengeot hernia is suspected, surgery should be performed as soon as possible. Laparoscopy is useful for the diagnosis and treatment of De Garengeot hernias and is therefore worthy of clinical application.

## REFERENCES

- 1 **China Hernia Society**, Guideline for diagnosis and treatment of adult groin hernia (2018 edition). Zhonghua Xiaohuawaike Zazhi 2018; 17: 645-648 [DOI: [10.3760/cma.j.issn.1673-9752.2018.07.001](https://doi.org/10.3760/cma.j.issn.1673-9752.2018.07.001)]
- 2 **Chen XP**, Wang JP, Zhao JZ. Surgery. Peking: People's Sanitary Publishing Pub, 2018: 371-374
- 3 **Granvall SA**. de Garengeot hernia: a unique surgical finding. *JAAPA* 2014; 27: 39-41 [PMID: 24758977 DOI: [10.1097/01.JAA.0000443968.31234.63](https://doi.org/10.1097/01.JAA.0000443968.31234.63)]
- 4 **Zhu L**, Tang WH, Tang JX. Emergency surgery of groin incarcerated hernia and strangulated hernia in adults. *Guoji Waikexue Zazhi* 2016; 43: 712-715 [DOI: [10.3760/cma.j.issn.1673-4203.2016.10.022](https://doi.org/10.3760/cma.j.issn.1673-4203.2016.10.022)]
- 5 **Michalinos A**, Moris D, Vernadakis S. Amyand's hernia: a review. *Am J Surg* 2014; 207: 989-995

- [PMID: 24280148 DOI: 10.1016/j.amjsurg.2013.07.043]
- 6 **Talini C**, Oliveira LO, Araújo AC, Netto FA, Westphalen AP. De Garengeot hernia: Case report and review. *Int J Surg Case Rep* 2015; **8C**: 35-37 [PMID: 25622240 DOI: 10.1016/j.ijscr.2014.12.042]
  - 7 **Sharma D**, Katsnelson J, Nwachuku E, Kolff J. The De Garengeot hernia: A case report of an unusual presentation of appendicitis. *Int J Surg Case Rep* 2020; **76**: 46-48 [PMID: 33010614 DOI: 10.1016/j.ijscr.2020.08.053]
  - 8 **Sharma H**, Jha PK, Shekhawat NS, Memon B, Memon MA. De Garengeot hernia: an analysis of our experience. *Hernia* 2007; **11**: 235-238 [PMID: 17340052 DOI: 10.1007/s10029-007-0208-5]
  - 9 **Shiuhara M**, Kato T, Kaneko Y, Yoshitoshi K, Ota T. de Garengeot hernia with appendicitis treated by two-way-approach surgery: a case report. *J Surg Case Rep* 2017; **2017**: rjx140 [PMID: 28775838 DOI: 10.1093/jscr/rjx140]
  - 10 **Dai WG**, Chen JH, Yu HL, Chen CQ. right-sided De Garengeot's hernia with gangrenous appendicitis: a case report. *Zhongguo Shiyong Waikexue* 2018; **38**: 1084-1085 [DOI: 10.19538/j.cjps.issn1005-2208.2018.09.30]
  - 11 **Holmes K**, Guinn JE. Amyand hernia repair with mesh and appendectomy. *Surg Case Rep* 2019; **5**: 42 [PMID: 30877403 DOI: 10.1186/s40792-019-0600-2]



Published by **Baishideng Publishing Group Inc**  
7041 Koll Center Parkway, Suite 160, Pleasanton, CA 94566, USA

**Telephone:** +1-925-3991568

**E-mail:** [bpgoffice@wjgnet.com](mailto:bpgoffice@wjgnet.com)

**Help Desk:** <https://www.f6publishing.com/helpdesk>

<https://www.wjgnet.com>

