

World Journal of *Clinical Cases*

World J Clin Cases 2021 February 26; 9(6): 1247-1498



Contents

Thrice Monthly Volume 9 Number 6 February 26, 2021

EDITORIAL

- 1247 Interactive platform for peer review: A proposal to improve the current peer review system
Emile SH

MINIREVIEWS

- 1251 Animal models of cathartic colon
Meng YY, Li QD, Feng Y, Liu J, Wang EK, Zhong L, Sun QL, Yuan JY

ORIGINAL ARTICLE

Case Control Study

- 1259 New indicators in evaluation of hemolysis, elevated liver enzymes, and low platelet syndrome: A case-control study
Kang SY, Wang Y, Zhou LP, Zhang H

Retrospective Study

- 1271 Analysis of hospitalization costs related to fall injuries in elderly patients
Su FY, Fu ML, Zhao QH, Huang HH, Luo D, Xiao MZ
- 1284 Effect of alprostadil in the treatment of intensive care unit patients with acute renal injury
Jia Y, Liu LL, Su JL, Meng XH, Wang WX, Tian C

Clinical Trials Study

- 1293 Etomidate *vs* propofol in coronary heart disease patients undergoing major noncardiac surgery: A randomized clinical trial
Dai ZL, Cai XT, Gao WL, Lin M, Lin J, Jiang YX, Jiang X

Observational Study

- 1304 Healthy individuals *vs* patients with bipolar or unipolar depression in gray matter volume
Zhang YN, Li H, Shen ZW, Xu C, Huang YJ, Wu RH
- 1318 Impact of metabolism-related mutations on the heart rate of gastric cancer patients after peritoneal lavage
Yuan Y, Yao S, Luo GH, Zhang XY

CASE REPORT

- 1329 Efficacy of afatinib in a patient with rare EGFR (G724S/R776H) mutations and amplification in lung adenocarcinoma: A case report
He SY, Lin QF, Chen J, Yu GP, Zhang JL, Shen D

- 1336** Esophageal superficial adenosquamous carcinoma resected by endoscopic submucosal dissection: A rare case report
Liu GY, Zhang JX, Rong L, Nian WD, Nian BX, Tian Y
- 1343** Do medullary thyroid carcinoma patients with high calcitonin require bilateral neck lymph node clearance? A case report
Gan FJ, Zhou T, Wu S, Xu MX, Sun SH
- 1353** Femoral epithelioid hemangioendothelioma detected with magnetic resonance imaging and positron emission tomography/computed tomography: A case report
Zhao HG, Zhang KW, Hou S, Dai YY, Xu SB
- 1359** Noninvasive tools based on immune biomarkers for the diagnosis of central nervous system graft-vs-host disease: Two case reports and a review of the literature
Lyu HR, He XY, Hao HJ, Lu WY, Jin X, Zhao YJ, Zhao MF
- 1367** Periodontally accelerated osteogenic orthodontics with platelet-rich fibrin in an adult patient with periodontal disease: A case report and review of literature
Xu M, Sun XY, Xu JG
- 1379** Subtalar joint pigmented villonodular synovitis misdiagnosed at the first visit: A case report
Zhao WQ, Zhao B, Li WS, Assan I
- 1386** Wilson disease — the impact of hyperimmunity on disease activity: A case report
Stremmel W, Longerich T, Liere R, Vacata V, van Helden J, Weiskirchen R
- 1394** Unexplained elevation of erythrocyte sedimentation rate in a patient recovering from COVID-19: A case report
Pu SL, Zhang XY, Liu DS, Ye BN, Li JQ
- 1402** Thoracic pyogenic infectious spondylitis presented as pneumothorax: A case report
Cho MK, Lee BJ, Chang JH, Kim YM
- 1408** Unilateral pulmonary hemorrhage caused by negative pressure pulmonary edema: A case report
Park HJ, Park SH, Woo UT, Cho SY, Jeon WJ, Shin WJ
- 1416** Osseous Rosai-Dorfman disease of tibia in children: A case report
Vithran DTA, Wang JZ, Xiang F, Wen J, Xiao S, Tang WZ, Chen Q
- 1424** Abdominopelvic leiomyoma with large ascites: A case report and review of the literature
Wang YW, Fan Q, Qian ZX, Wang JJ, Li YH, Wang YD
- 1433** Unusual presentation of granulomatosis with polyangiitis causing periaortitis and consequent subclavian steal syndrome: A case report
Cho U, Kim SK, Ko JM, Yoo J
- 1439** Postoperative discal pseudocyst and its similarities to discal cyst: A case report
Fu CF, Tian ZS, Yao LY, Yao JH, Jin YZ, Liu Y, Wang YY

- 1446** Treatment of oral lichen planus by surgical excision and acellular dermal matrix grafting: Eleven case reports and review of literature
Fu ZZ, Chen LQ, Xu YX, Yue J, Ding Q, Xiao WL
- 1455** Nonalcoholic fatty liver disease as a risk factor for cytomegalovirus hepatitis in an immunocompetent patient: A case report
Khiatah B, Nasrollah L, Covington S, Carlson D
- 1461** Early reoccurrence of traumatic posterior atlantoaxial dislocation without fracture: A case report
Sun YH, Wang L, Ren JT, Wang SX, Jiao ZD, Fang J
- 1469** Intrahepatic cholangiocarcinoma is more complex than we thought: A case report
Zeng JT, Zhang JF, Wang Y, Qing Z, Luo ZH, Zhang YL, Zhang Y, Luo XZ
- 1475** Congenital hepatic fibrosis in a young boy with congenital hypothyroidism: A case report
Xiao FF, Wang YZ, Dong F, Li XL, Zhang T
- 1483** Polidocanol sclerotherapy for multiple gastrointestinal hemangiomas: A case report
Yao H, Xie YX, Guo JY, Wu HC, Xie R, Shi GQ
- 1490** Gastrointestinal stromal tumor with multisegmental spinal metastases as first presentation: A case report and review of the literature
Kong Y, Ma XW, Zhang QQ, Zhao Y, Feng HL

ABOUT COVER

Editorial Board Member of *World Journal of Clinical Cases*, Dr. Quach is an Associate Professor of Gastroenterology at the University of Medicine and Pharmacy at Hochiminh City, Viet Nam, where he received his MD in 1997 and his PhD in 2011. Dr. Quach has published more than 100 reviews and original papers in local and international journals. He has received several awards, including Outstanding Presentation at the Biannual Scientific Congress of Vietnamese Nationwide Medical Schools, Medal of Creativeness from the Vietnamese Central Youth League, etc. Currently, he serves as a Vice President of the Vietnam Association of Gastroenterology and Secretary General of the Vietnam Federation for Digestive Endoscopy. (L-Editor: Filipodia)

AIMS AND SCOPE

The primary aim of *World Journal of Clinical Cases* (*WJCC*, *World J Clin Cases*) is to provide scholars and readers from various fields of clinical medicine with a platform to publish high-quality clinical research articles and communicate their research findings online.

WJCC mainly publishes articles reporting research results and findings obtained in the field of clinical medicine and covering a wide range of topics, including case control studies, retrospective cohort studies, retrospective studies, clinical trials studies, observational studies, prospective studies, randomized controlled trials, randomized clinical trials, systematic reviews, meta-analysis, and case reports.

INDEXING/ABSTRACTING

The *WJCC* is now indexed in Science Citation Index Expanded (also known as SciSearch®), Journal Citation Reports/Science Edition, Scopus, PubMed, and PubMed Central. The 2020 Edition of Journal Citation Reports® cites the 2019 impact factor (IF) for *WJCC* as 1.013; IF without journal self cites: 0.991; Ranking: 120 among 165 journals in medicine, general and internal; and Quartile category: Q3. The *WJCC*'s CiteScore for 2019 is 0.3 and Scopus CiteScore rank 2019: General Medicine is 394/529.

RESPONSIBLE EDITORS FOR THIS ISSUE

Production Editor: Ji-Hong Lin; Production Department Director: Xiang Li; Editorial Office Director: Jin-Lai Wang.

NAME OF JOURNAL

World Journal of Clinical Cases

ISSN

ISSN 2307-8960 (online)

LAUNCH DATE

April 16, 2013

FREQUENCY

Thrice Monthly

EDITORS-IN-CHIEF

Dennis A Bloomfield, Sandro Vento, Bao-Gan Peng

EDITORIAL BOARD MEMBERS

<https://www.wjgnet.com/2307-8960/editorialboard.htm>

PUBLICATION DATE

February 26, 2021

COPYRIGHT

© 2021 Baishideng Publishing Group Inc

INSTRUCTIONS TO AUTHORS

<https://www.wjgnet.com/bpg/gerinfo/204>

GUIDELINES FOR ETHICS DOCUMENTS

<https://www.wjgnet.com/bpg/GerInfo/287>

GUIDELINES FOR NON-NATIVE SPEAKERS OF ENGLISH

<https://www.wjgnet.com/bpg/gerinfo/240>

PUBLICATION ETHICS

<https://www.wjgnet.com/bpg/GerInfo/288>

PUBLICATION MISCONDUCT

<https://www.wjgnet.com/bpg/gerinfo/208>

ARTICLE PROCESSING CHARGE

<https://www.wjgnet.com/bpg/gerinfo/242>

STEPS FOR SUBMITTING MANUSCRIPTS

<https://www.wjgnet.com/bpg/GerInfo/239>

ONLINE SUBMISSION

<https://www.f6publishing.com>

Periodontally accelerated osteogenic orthodontics with platelet-rich fibrin in an adult patient with periodontal disease: A case report and review of literature

Min Xu, Xiao-Yu Sun, Jian-Guang Xu

ORCID number: Min Xu 0000-0002-0888-0482; Xiao-Yu Sun 0000-0001-8773-1242; Jian-Guang Xu 0000-0001-8773-1241.

Author contributions: Xu M analyzed and interpreted the imaging findings; Sun XY reviewed the literature and drafted the manuscript; Xu JG was the patient's dentist and was responsible for the revision of the manuscript; All authors issued final approval for the version to be submitted.

Supported by Natured Science Foundation of Anhui Province, No. 1908085MH255.

Informed consent statement: Informed written consent was obtained from the patient for publication of this report and any accompanying images.

Conflict-of-interest statement: The authors declare that they have no conflict of interest.

CARE Checklist (2016) statement: The authors have read the CARE Checklist (2016), and the manuscript was prepared and revised according to the CARE Checklist (2016).

Open-Access: This article is an

Min Xu, Xiao-Yu Sun, Stomatological Hospital and College, Anhui Medical University, Hefei 230032, Anhui Province, China

Jian-Guang Xu, Department of Orthodontics, Anhui Medical University, Hefei 230032, Anhui Province, China

Corresponding author: Jian-Guang Xu, MD, PhD, Associate Professor, Doctor, Department of Orthodontics, Anhui Medical University, No. 69, Meishan Road, Hefei 230032, Anhui Province, China. xujianguang@ahmu.edu.cn

Abstract

BACKGROUND

In the clinical scenario, adult patients with periodontal diseases and dental malformation, characterized by dental crowding in lower anterior teeth with the thin biotype, often require orthodontic treatment. This case report aimed to evaluate the clinical and radiographic outcomes of periodontally accelerated osteogenic orthodontics (PAOO) combined with autologous platelet-rich fibrin (PRF) in an adult patient with class I malocclusion along with dental crowding, a thin periodontal biotype, and buccal plate deficiency.

CASE SUMMARY

A 32-year-old female complaining of dental crowding and gingival bleeding was referred to the orthodontic clinic. The patient underwent periodontal risk assessment prior to orthodontic treatment. She was diagnosed with a high risk of gingival recession due to dental crowding, root prominence, loss of buccal plates, and a thin gingival tissue biotype. The treatment regimen included PAOO combined with autologous PRF for alveolar augmentation and interproximal enamel reduction for moderate dental crowding. Clinically, PAOO-assisted orthodontic tooth movement in this case showed enhanced periodontium remodeling. Radiographic outcomes also showed statistically significant improvements ($P < 0.01$) in the mandibular buccal alveolar bone.

CONCLUSION

This case report suggests the combination of autologous PRF with PAOO to enhance bone augmentation and long-term tissue support in adult orthodontic patients with periodontal disease.

open-access article that was selected by an in-house editor and fully peer-reviewed by external reviewers. It is distributed in accordance with the Creative Commons Attribution NonCommercial (CC BY-NC 4.0) license, which permits others to distribute, remix, adapt, build upon this work non-commercially, and license their derivative works on different terms, provided the original work is properly cited and the use is non-commercial. See: <http://creativecommons.org/licenses/by-nc/4.0/>

Manuscript source: Unsolicited manuscript

Specialty type: Medicine, research and experimental

Country/Territory of origin: China

Peer-review report's scientific quality classification

Grade A (Excellent): 0
Grade B (Very good): B
Grade C (Good): 0
Grade D (Fair): 0
Grade E (Poor): 0

Received: September 22, 2020

Peer-review started: September 22, 2020

First decision: December 3, 2020

Revised: December 15, 2020

Accepted: December 26, 2020

Article in press: December 26, 2020

Published online: February 26, 2021

P-Reviewer: Kannan S

S-Editor: Gao CC

L-Editor: Filipodia

P-Editor: Wang LYT



Key Words: Periodontally accelerated osteogenic orthodontics; Orthodontic tooth movement; Platelet-rich fibrin; Bone augmentation; Periodontal biotype; Case report

©The Author(s) 2021. Published by Baishideng Publishing Group Inc. All rights reserved.

Core Tip: Periodontally accelerated osteogenic orthodontics (PAOO) has been widely used in the treatment of patients with periodontal diseases and dental malformation. However, the combined therapy with autologous platelet-rich fibrin and PAOO in orthodontic practice has been rarely reported. The aim of this case report was to evaluate clinical and radiographic outcomes of PAOO combined with autologous platelet-rich fibrin in an adult patient with class I malocclusion with thin periodontal biotype and buccal plate deficiency in order to provide guidance for future clinical diagnosis and treatment.

Citation: Xu M, Sun XY, Xu JG. Periodontally accelerated osteogenic orthodontics with platelet-rich fibrin in an adult patient with periodontal disease: A case report and review of literature. *World J Clin Cases* 2021; 9(6): 1367-1378

URL: <https://www.wjgnet.com/2307-8960/full/v9/i6/1367.htm>

DOI: <https://dx.doi.org/10.12998/wjcc.v9.i6.1367>

INTRODUCTION

A large number of studies have documented in the clinical scenario that patients with dental crowding are often predisposed to thin labial plate thickness^[1]. Orthodontic tooth movement (OTM) in these patients is often challenged with potential side effects, such as decreased responsiveness to orthodontic force^[2,3], consequently prolonged treatment course, and root resorption thereupon, as well as aggravated bone and soft tissue loss along with tooth movement. Periodontally accelerated osteogenic orthodontics (PAOO)^[4] is a delicate conjugation combining clinical periodontal treatment and orthodontic movement, involving surgical decortication, bone grafting, and orthodontic force application and has the advantages of sustainable alveolar bone augmentation, stable periodontium improvements, accelerated tooth movement, and abridged treatment duration^[4,5].

Autologous platelet-rich fibrin (PRF) can be obtained from human sources (*e.g.*, from the blood samples of a patient *per se*)^[6], and it is capable of accelerating wound healing and promoting tissue regeneration^[7]. PRF has been widely applied in medical therapy and plastic surgery, particularly in oral and maxillofacial surgeries^[8,9] such as implantology, guided bone regeneration operations, and exodontia^[10]. Nonetheless, to our knowledge, the combined therapy with autologous PRF and PAOO in orthodontic practice has been rarely reported.

The aim of this case report was to evaluate the clinical and radiographic outcomes of PAOO combined with autologous PRF in an adult patient with class I malocclusion along with a thin periodontal biotype and buccal plate deficiency to provide guidance for future clinical diagnosis and treatment.

CASE PRESENTATION

Chief complaints

A healthy 32-year-old female presented to the Stomatological Hospital of Anhui Medical University for orthodontic treatment of tooth crowding and gingival bleeding.

History of present illness

Patient's tooth crowding started many years ago. However, the gingival bleeding started a few months ago and had gradually worsened recently.

History of past illness

The patient had a free previous dental history.

Personal and family history

The patient had a non-contributory personal and family history.

Physical examination

Periodontal examination revealed bleeding on probing percentage (BOP%) of 48.6%, bleeding index of 2-3, and probing depth exceeding 4 mm at some sites. Assessment of soft tissues revealed a thin gingival biotype and severe gingival recession (GR) in some teeth, such as #32 (Figure 1). Orthodontic examination revealed molar class I malocclusion with mild (the maxillary arch) and moderate (the mandibular arch) dental crowding.

Laboratory examinations

The patient's blood test results were all normal.

Imaging examinations

Radiographically, results from cone beam computed tomography (CBCT) demonstrated different levels of bony dehiscence in the mandibular anterior teeth.

FINAL DIAGNOSIS

The final diagnosis of the presented case is molar class I malocclusion with mild (the maxillary arch) and moderate (the mandibular arch) dental crowding (Figure 1). Radiographically, results from CBCT demonstrated different levels of bony dehiscence in the mandibular anterior teeth (Figure 2).

TREATMENT

The patient was diagnosed as having a high risk of GR in case of routine orthodontic treatment. Hence, the orthodontic regimen consisted of PAOO combined with autologous PRF (incorporated into the graft and as a coating membrane) and interproximal enamel reduction. The periodontal treatment scheme included initial therapy, professional mechanical tooth cleaning, and regular consultation. In addition, the patient was instructed to brush her teeth as appropriate. This interdisciplinary regimen was aimed at alignment of teeth, stabilization of occlusion, promotion of the microenvironment of soft and hard tissues, and relief of GR. All therapeutic procedures were performed with written informed consent from the patient.

At the end of initial periodontal therapy, orthodontic brackets (Damon Q, Ormco, Brea, CA, United States) were fixed, and interproximal enamel reduction was performed, followed by application of 0.013-Cu-Ni-Ti wires (Ormco) to activate tooth movement (Figure 3A). One week later, PAOO surgery was performed on the mandibular anterior labial side (Figure 3B-I). The patient was followed up at an interval of 2-3 wk, coupled with the placement of orthodontic arch wires of increasing sizes. The patient underwent professional mechanical tooth cleaning for a 3-mo duration to safeguard the health and stability of periodontal tissues during OTM.

PRF preparation

Blood samples were taken from the median cubital vein into two 10 mL glass-coated tubes without the addition of anti-coagulants, followed by immediate centrifugation at room temperature at 3000 rpm for 10 min. Thereafter, the clots were carefully isolated with scissors from precipitated red blood cells (Figure 3D). Clots from one tube were minced and incorporated into xenograft (Bio-Oss, Geistlich, Wolhusen, Switzerland) particles, whereas clots from the other tube were prepared as an absorbable membrane (Figure 3E and F). PRF was prepared at the onset of the PAOO surgery.

PAOO surgery

According to the protocol proposed by Murphy *et al*^[11], a full-thickness flap was performed under local anesthesia (Figure 3B). Given the insufficient thickness of the alveolar bone, cortical perforation was performed in the interradicular areas

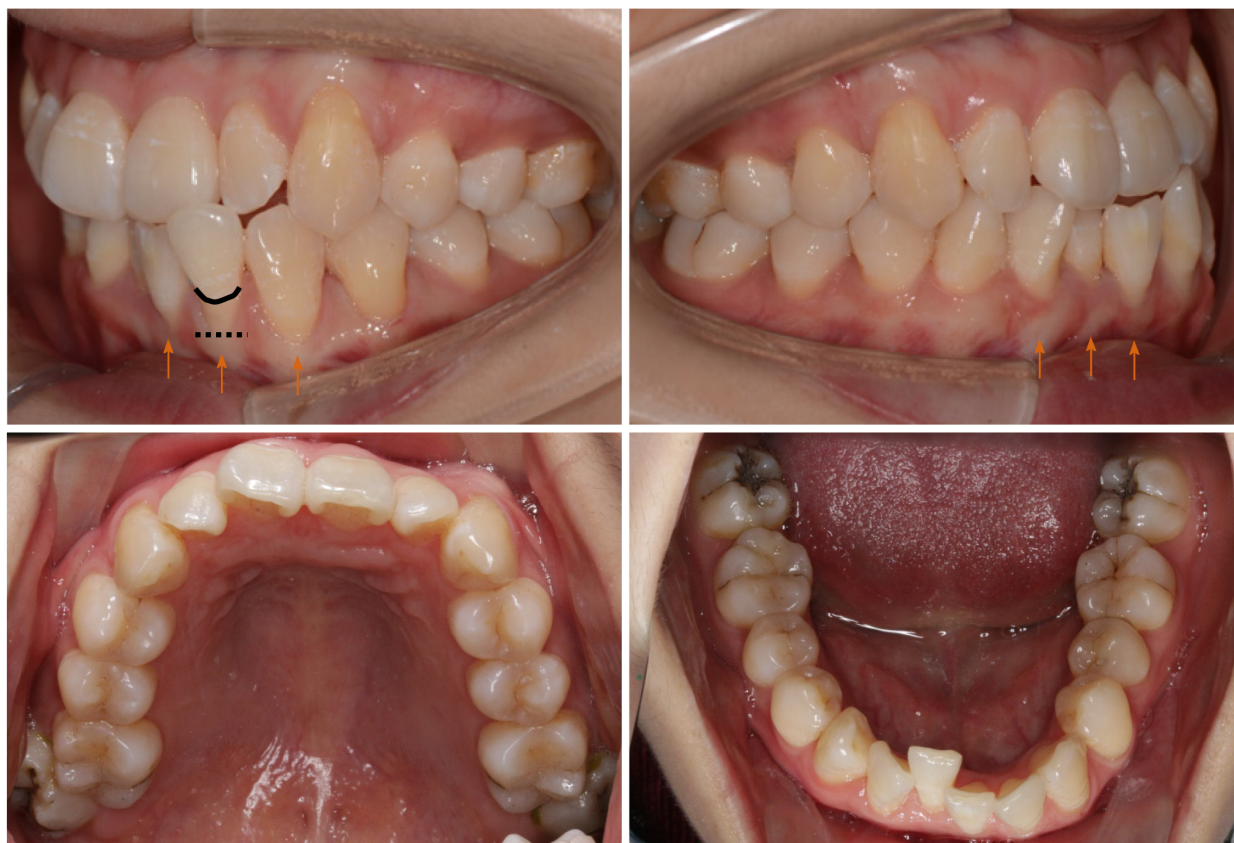


Figure 1 Pre-treatment intraoral photographs: Thin (more delicate, fragile) biotype and root surface exposure caused by apical displacement of the gingival margin past the enamel-cemental junction and prominent roots (orange arrow). Black line: Enamel-cemental junction at #32. Black dotted line: Gingival/soft tissue margin at #32.

(Figure 3C), followed by placement of bone xenografts (Bio-Oss, Geistlich) and autologous PRF mixture (Figure 3G) coated with a collagen membrane (Bio-Gide, Geistlich) together with self-prepared PRF membrane (Figure 3H). Then flaps were closed with an interrupted interdental suture and a single sling suture method (Figure 3I).

Statistics

The distance between the enamel-cemental junction to the top of the alveolar ridge (Figure 4) was measured in CBCT sagittal sections with Dolphin Software (Ver. 11.9 Premium; Oslo, Norway). The measurements were performed by a single examiner who was blind to the details of the study or the patient. The measurements were repeated by the same examiner 30 d later, with the average of the results to ensure accuracy and reliability. Both buccal and lingual distances were measured. Independent *t* test was used to compare the differences in bone height between pre-treatment and post-treatment profiles. A difference of $P < 0.05$ was considered statistically significant.

OUTCOME AND FOLLOW-UP

Subsequent to surgery, healing was clinically favorable, and crowded teeth were rapidly corrected within the first month. During the treatment, no evident reduction of soft tissues was observed or gingival bleeding was identified. With the treatment, the gingival margin of the mandibular anterior teeth was coronally displaced, the periodontal tissue was stabilized (Figure 5), and probing depth was ≤ 3 mm at all sites. Radiographic studies confirmed augmented alveolar bone (Figure 6) and significantly elevated height of the buccal bone ridge, particularly at #32 and #41 ($P < 0.05$) (Table 1). In addition, both soft tissue and hard tissue augmentation remained

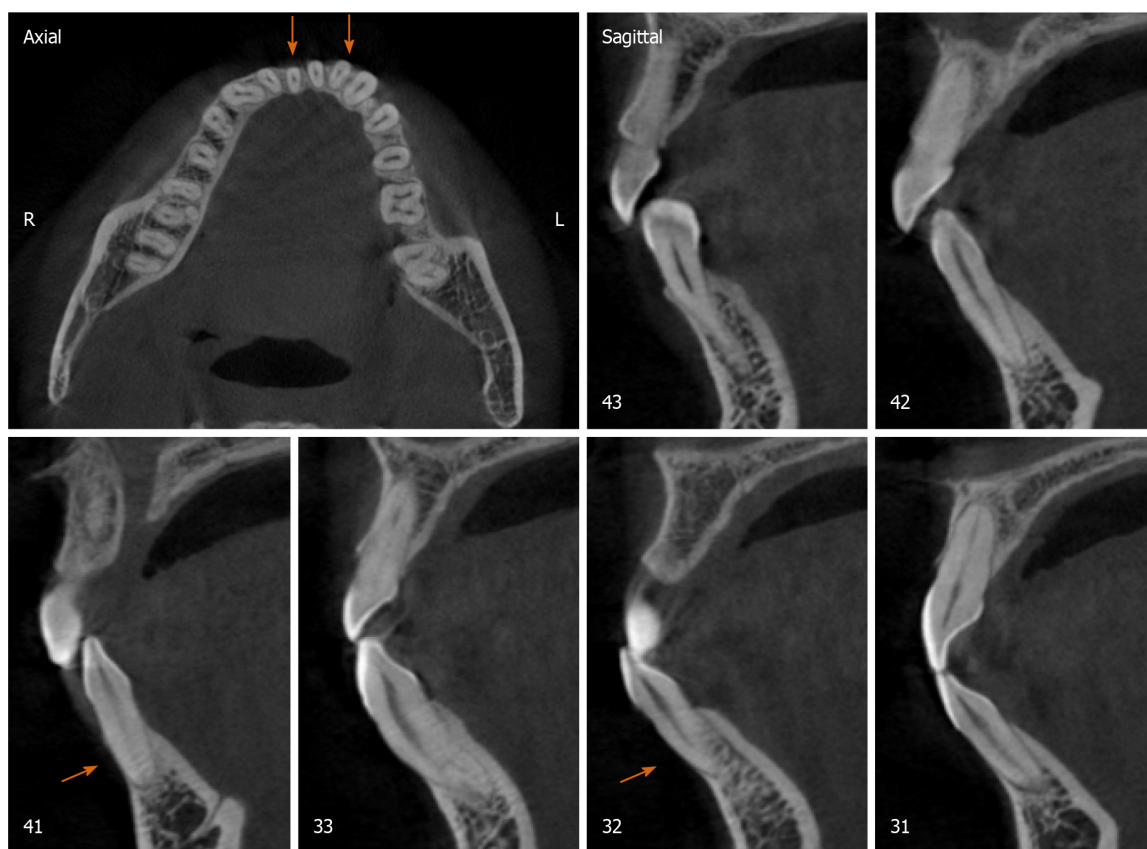
Table 1 Mean height of the alveolar bone crest in the mandibular anterior teeth

Mean height in mm	Tooth position											
	43		42		41		31		32		33	
	B	L	B	L	B ^d	L	B	L	B ^b	L ^b	B	L
Pre-(H1)	3.35	2.90	6.20	3.10	9.12	3.46	5.47	2.43	6.23	3.36	3.80	2.32
Post-(H2)	3.82	2.79	5.43	3.30	4.95	3.32	5.04	2.79	4.46	2.41	2.85	2.58
<i>P</i> value	0.1394	0.8128	0.6605	0.3310	< 0.0001	0.4763	0.1311	0.1383	0.0079	0.0024	0.0845	0.1116

^b*P* < 0.01.

^d*P* < 0.0001.

B: Buccal distance between buccal point of the enamel-cemental junction and buccal top point of the alveolar ridge in Figure 4; L: Lingual distance between lingual point of the enamel-cemental junction and buccal top point of the alveolar ridge in Figure 4.


Figure 2 Pre-treatment cone beam computed tomography images. Orange arrow: Buccal bone plate deficiency at #32 and #41.

stabilized at 6 mo after the treatment (figures not shown).

DISCUSSION

PAOO has been proven to broaden the scope of OTM and expand the indications of orthodontics^[12,13]. In this case, the alveolar ridges in some lower anterior teeth were significantly elevated, and the total treatment duration was abridged. These outcomes were supported by the findings of prior clinical case reports^[4,14-19] and animal studies^[20-22]. PAOO can be considered as an integrative surgery for achieving periodontal regeneration and dentoalveolar bone construction^[23], and it is capable of optimizing dentoalveolar relationships and creating an equilibrium between hard and

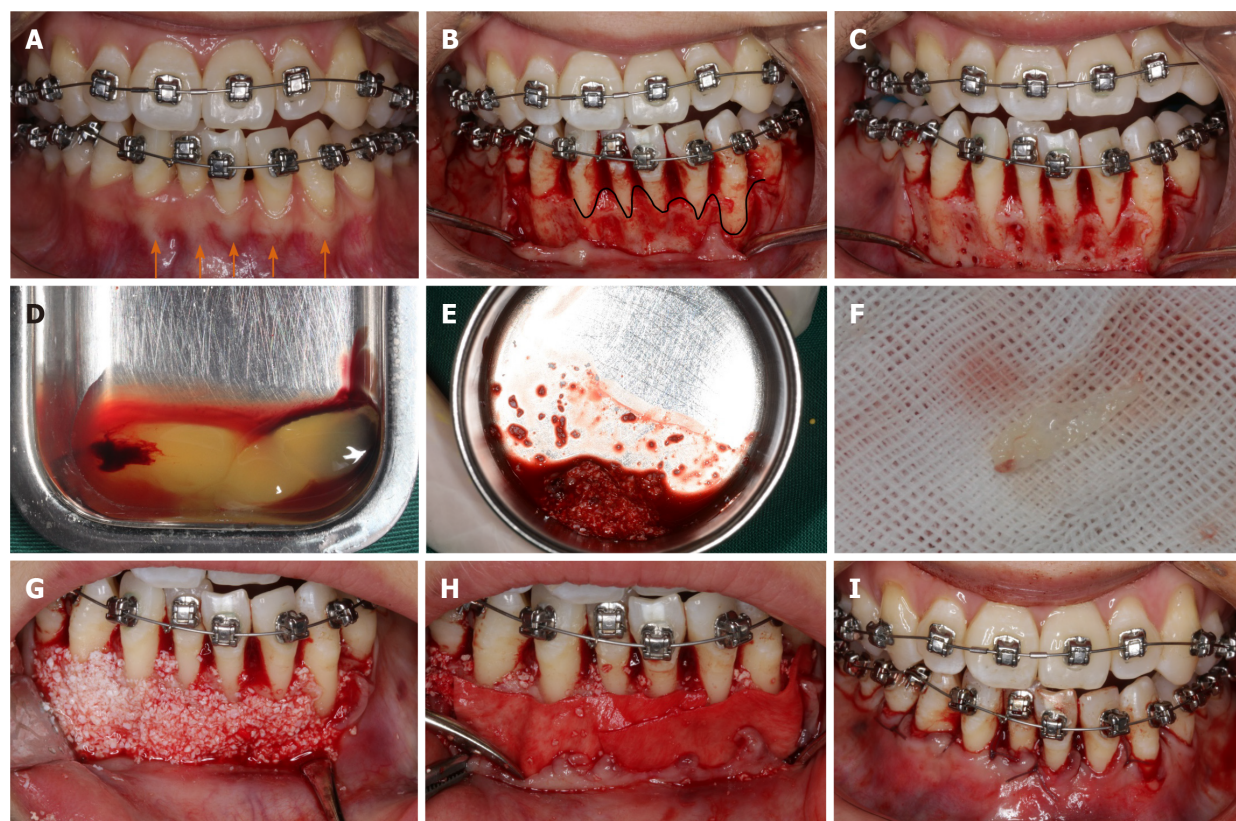


Figure 3 Periodontally accelerated osteogenic orthodontics surgery. A: Initial photograph with orthodontic appliances; B: Full-thickness envelope flap reflection; C: Cortical punching; D: Preparation of platelet-rich fibrin (PRF); E: Mixing up the Bio-Oss and PRF; F: Self-prepared PRF membrane; G: Placement of a bone graft; H: Coverage of Bio-Gide membrane and PRF membrane; I: Suture. Orange arrow: Prominent roots. Black curved line: Bone margin in the buccal plates.

soft surrounding tissues in patients with multiple dental malocclusions^[24-26], decompensation of mandibular incisors^[17-19], and different degrees of crowding^[15,16], with either fixed appliances or clear aligners.

The biological mechanism underpinning PAOO has been referred to as the regional acceleratory phenomenon (RAP)^[27,28], which is defined as accelerated bone remodeling and decreased regional bone density caused by noxious stimuli^[27] (e.g., surgery or fracture), whereby bone metabolism is two to 10 times faster than the normal healing process, attributable to the bursts of bone turnover and soft tissue reconstruction^[29]. “Regional” refers to osteopenia at the decortication site and the adjacent bone, and “acceleratory” refers to rapid bone metabolism. The role of RAP is to raise temporarily the biological bone response and systemically recruit growth factors at the decortication area^[30]. RAP is actually a transitional process that starts a few days after the trauma, peaks in the first month, and then gradually decreases till the fourth month^[31]. Thus, RAP could potentiate tissue reorganization and healing^[32], and it has a direct impact on the quality and quantity of OTM^[33,34]. In this case, correction of the crowded lower teeth was accomplished in the first month, or rather the most effective period of RAP (*i.e.* the rate of OTM might be two to three times higher with PAOO than with conventional orthodontic techniques)^[35]. Substantially less time in a fixed appliance means less conversion of cytotoxic plaque biofilms into local periodontal inducible stimuli and achievement of more intact periodontium.

As another key factor in PAOO, bone grafts are always contributory to the surgery. Brugnami *et al.*^[36] stated that when the tooth was moved outside the bony envelope, corticotomy with concomitant bone grafting technique could maintain the alveolar bone volume around the teeth, whereas corticotomy without concomitant bone grafting could not maintain the alveolar bone volume around the teeth. Bone grafting in PAOO actually abolished the traditional limitation of tooth movement by predictable malleability of the position of the dental root^[37]. There are many types of bone grafts, such as autograft, allograft, xenograft, and synthetic bone grafts. Bone grafts mainly feature in the combination of mechanical support and osteoconduction, embedded with another two crucial biological properties: Osteoinduction and

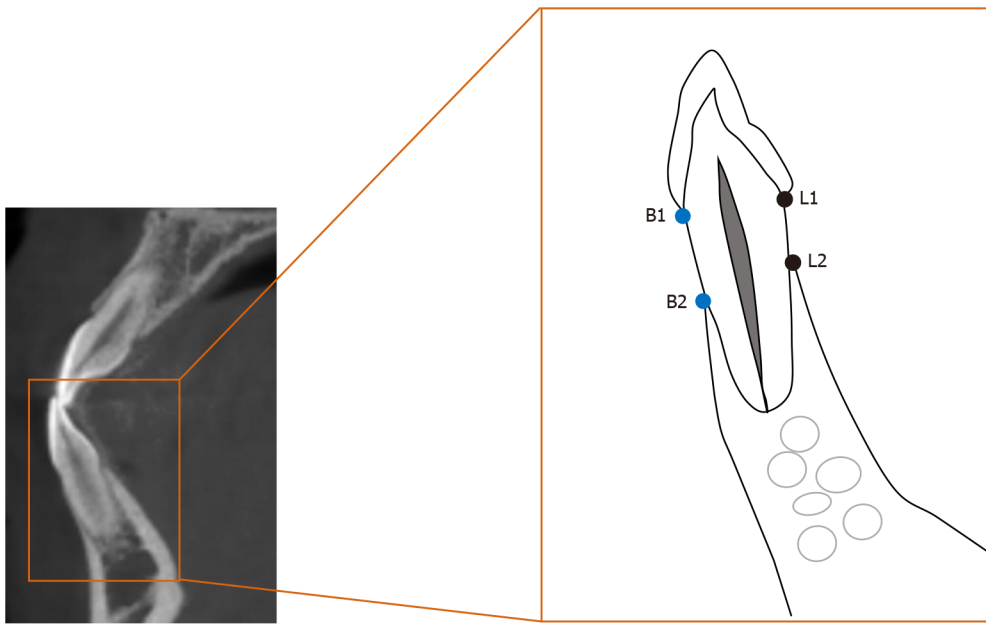


Figure 4 Diagram of a lower anterior tooth in the sagittal section of cone beam computed tomography images. Buccal height: The distance between B1 and B2. Lingual height: The distance between L1 and L2. B1: Buccal point of the enamel-cemental junction; B2: Buccal top point of the alveolar ridge; L1: Lingual point of the enamel-cemental junction; L2: Buccal top point of the alveolar ridge.

osteogenesis. Osteoconduction involves the attachment of osteoblasts and osteoprogenitor cells, and the subsequent migration and ingrowth of these cells within the three-dimensional architecture of the graft^[38]. Osteoinduction requires induction of the unspecialized, undifferentiated, and pluripotent cells in the development of the osteoprogenitor lineage, thereby further inducing osteogenesis^[39], or rather differentiation and subsequent formation of new bone tissues from donor cells derived from either the host or grafts^[40]. Generally, autogenous bone grafts are the gold standard. Nowzari *et al*^[24] first reported a combined application of PAOO with autogenous bone from the mandible in a 41-year-old man. Although this technique has crucial superiority in biocompatibility and viability of transferred osteogenic cells, the harvest is associated with unavoidable problems, such as secondary operation and quantity limitation. Alternatively, other biomaterials, such as allografts, xenografts, and synthetic bone substitutes, are also valuable options for bone regeneration.

In PAOO-assisted OTM, Bio-Oss is widely used as a bone graft. Bio-Oss is a substitute with high osteoconductivity derived from bovine origin. Bio-Oss acts as a scaffold to provide an interface for cells to attach, migrate, and proliferate. Yu *et al*^[18] and Ahn *et al*^[19] used Bio-Oss to correct labial alveolar defects and augment the regional bone. In theory, bone substitutes simultaneously employing osteoconduction, osteoinduction, and osteogenesis are more suitable for bone augmentation in PAOO. However, there is a paucity of literature with respect to the usage of other types of bone grafts, which encourages more research work to improve the properties of materials.

In this case, PRF was employed to enhance the regeneration of bone and soft tissues. PRF was labeled by Choukroun *et al*^[41] in 2000 as a “second-generation” platelet concentrate with the advantage of accumulated growth factors. Essentially, it is anteceded by platelet-rich plasma, which is a suspension rich in leukocytes and plasma components after centrifugation of fresh autologous whole blood. PRF plays a reliable role in optimizing wound healing, reducing pain and swelling^[41-44], promoting neovascularization and cell migration, and inducing angiogenesis^[45] in the alveolar preservation of an extraction socket, sinus lift, and various bone grafting procedures^[7]. When mixed with bone substitutes and covering the surface of bone wound, PRF increases graft survival, bone regeneration, and wound healing owing to the “sticky bone” consistency and release of autogenous growth factors^[10,46]. When shaped as a membrane coating the surface of bone grafts, PRF not only averts displacement and leakage of bone particulates^[47] but also serves as a porous scaffold. In addition, cell growth on PRF is reported to be significantly quicker than that on bovine collagen membrane (Bio-Gide, Geltish)^[48]. Shawky *et al*^[49] described a significant increase in new bone formation with the use of PRF plus autogenous bone graft in patients with maxillary clefts despite the modest contribution to bone density improvements

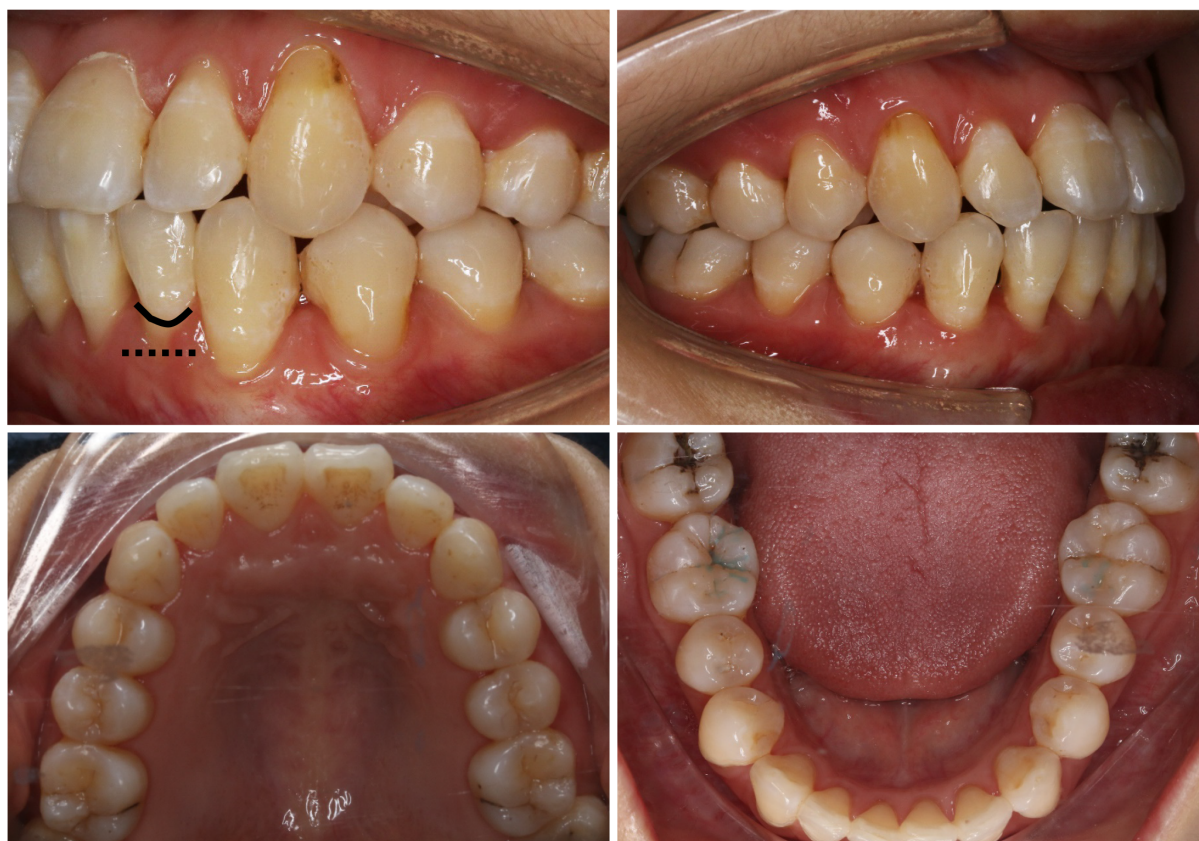

Figure 5 Post-treatment intraoral photographs: Improvements in the periodontium and reduction of gingival recession. Black line: Enamel-cemental junction at #32. Black dotted line: Gingival/soft tissue margin at #32.

compared with application of autogenous bone graft alone.

Despite the practical advantages of PRF, such as convenient preparation, enhancement of stability of grafting mixture, and protection against exposure, the clinical combination of PRF with PAOO in accelerated OTM has been rarely used. Only one cohort observational study^[42] applied PRF in PAOO surgery to observe the clinical effects on edema and pain. Notably, this case report was the first clinical presentation concerning the combined application of PRF with PAOO in an orthodontic patient with a thin biotype and labial plate deficiency. In this case, the combination of PRF with PAOO in the mandibular anterior region accelerated OTM and provided additional gain in the height of the gingival margin, which was similar to the findings presented by Wilcko *et al*^[50]. Although not measured precisely, the thickness of the gingiva was considered to have been enhanced by clinical experience on the labial side of the mandibular incisors, which is also in agreement with the research by Jing *et al*^[51]. PAOO improved soft tissue augmentation, which actually lays the periodontal foundation for successful orthodontics.

However, drawbacks are still inevitable. Extra cost and post-operative risks, such as possible bone loss, resorption of bone grafts, and susceptible infections, can be additional concerns in such patients. Moreover, a follow-up for 6 mo in this case is relatively short, and we are actually performing a large-scale observation and an increased length of follow-up period to evaluate the effectiveness and long-term stability of PAOO in adult orthodontic patients with a thin biotype and buccal plate deficiency.

At present, the main confounders of bone augmentation remain indefinite and uncertain. In this case, the effect of bone augmentation was negative in some dehiscence sites, such as #31; Thereby, approaches to ensure the effectiveness and certainty of bone augmentation in PAOO-assisted OTM bring novel prospects to clinicians. In summary, the first step rests on a meticulous examination of the gingival biotype and buccal bone thickness and proper case assessment prior to regimen implementation, and CBCT analysis is necessary. CBCT is capable of providing more clear and detailed images to show the relationship of target teeth with the adjacent anatomical structures and corresponding bone reconstruction, while ortho-

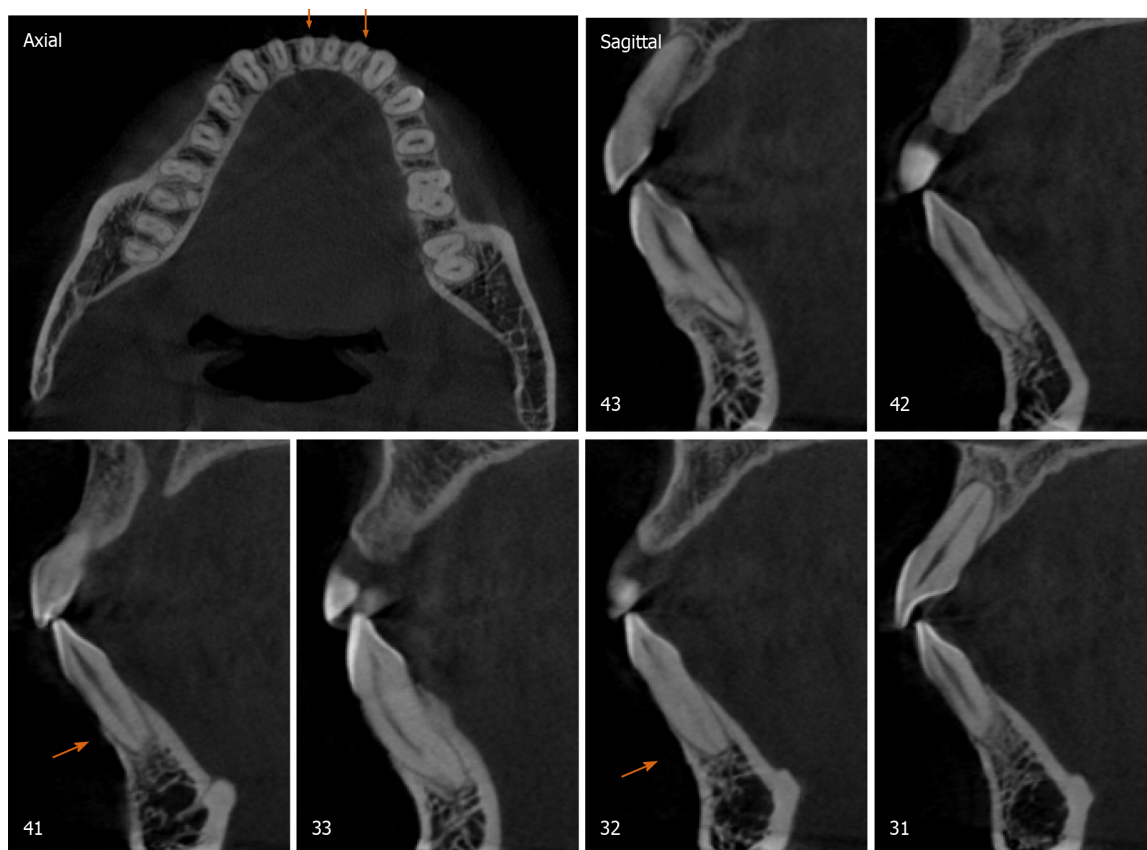


Figure 6 Post-treatment cone beam computed tomography images. Orange arrow: Bone augmentation at #32 and #41.

pantomogram could be beneficial in extensive measurements, including localization, angular, linear, and possible root resorption evaluation, especially in OTM of impacted maxillary canines. Second, standardized and unified clinical guidelines of PAOO surgery should be instituted. Third, prevention of bone substitutes from undergoing displacement and leakage should be emphasized. The last but the most important point, continuous and steady release of growth factors (such as PRF) should be encouraged to enhance bone formation. Despite the discrepancy in technical proficiency among the clinicians and idiosyncratic sensitivity in patients, PAOO combined with PRF is a promising treatment scheme to accelerate OTM and improve bone regeneration in adult patients with periodontal disease.

CONCLUSION

This case report demonstrated that the combination of autologous PRF with PAOO could reduce the therapeutic duration with rapid OTM plus augmented alveolar bone and soft tissues in adult patients with dental crowding, thin biotype, and buccal bone defects.

REFERENCES

- 1 **Kaya Y**, Alkan Ö, Keskin S. An evaluation of the gingival biotype and the width of keratinized gingiva in the mandibular anterior region of individuals with different dental malocclusion groups and levels of crowding. *Korean J Orthod* 2017; **47**: 176-185 [PMID: [28523244](#) DOI: [10.4041/kjod.2017.47.3.176](#)]
- 2 **Misawa Y**, Kageyama T, Moriyama K, Kurihara S, Yagasaki H, Deguchi T, Ozawa H, Sahara N. Effect of age on alveolar bone turnover adjacent to maxillary molar roots in male rats: A histomorphometric study. *Arch Oral Biol* 2007; **52**: 44-50 [PMID: [17125731](#) DOI: [10.1016/j.archoralbio.2006.06.012](#)]
- 3 **Schubert A**, Jäger F, Maltha JC, Bartzela TN. Age effect on orthodontic tooth movement rate and the composition of gingival crevicular fluid: A literature review. *J Orofac Orthop* 2020; **81**: 113-125

- [PMID: [31919542](#) DOI: [10.1007/s00056-019-00206-5](#)]
- 4 **Wilcko WM**, Wilcko T, Bouquot JE, Ferguson DJ. Rapid orthodontics with alveolar reshaping: two case reports of decrowding. *Int J Periodontics Restorative Dent* 2001; **21**: 9-19 [PMID: [11829041](#)]
 - 5 **Wilcko MT**, Wilcko WM, Bissada NF. An Evidence-Based Analysis of Periodontally Accelerated Orthodontic and Osteogenic Techniques: A Synthesis of Scientific Perspectives. *Semin Orthod* 2008; **14**: 305-316 [DOI: [10.1053/j.sodo.2008.07.007](#)]
 - 6 **Alves R**, Grimalt R. A Review of Platelet-Rich Plasma: History, Biology, Mechanism of Action, and Classification. *Skin Appendage Disord* 2018; **4**: 18-24 [PMID: [29457008](#) DOI: [10.1159/000477353](#)]
 - 7 **Agrawal AA**. Evolution, current status and advances in application of platelet concentrate in periodontics and implantology. *World J Clin Cases* 2017; **5**: 159-171 [PMID: [28560233](#) DOI: [10.12998/wjcc.v5.i5.159](#)]
 - 8 **Del Corso M**, Vervelle A, Simonpieri A, Jimbo R, Inchingolo F, Sammartino G, Dohan Ehrenfest DM. Current knowledge and perspectives for the use of platelet-rich plasma (PRP) and platelet-rich fibrin (PRF) in oral and maxillofacial surgery part 1: Periodontal and dentoalveolar surgery. *Curr Pharm Biotechnol* 2012; **13**: 1207-1230 [PMID: [21740371](#) DOI: [10.2174/138920112800624391](#)]
 - 9 **Simonpieri A**, Del Corso M, Vervelle A, Jimbo R, Inchingolo F, Sammartino G, Dohan Ehrenfest DM. Current knowledge and perspectives for the use of platelet-rich plasma (PRP) and platelet-rich fibrin (PRF) in oral and maxillofacial surgery part 2: Bone graft, implant and reconstructive surgery. *Curr Pharm Biotechnol* 2012; **13**: 1231-1256 [PMID: [21740370](#) DOI: [10.2174/138920112800624472](#)]
 - 10 **Fan Y**, Perez K, Dym H. Clinical Uses of Platelet-Rich Fibrin in Oral and Maxillofacial Surgery. *Dent Clin North Am* 2020; **64**: 291-303 [PMID: [32111269](#) DOI: [10.1016/j.cden.2019.12.012](#)]
 - 11 **Murphy KG**, Wilcko MT, Wilcko WM, Ferguson DJ. Periodontal accelerated osteogenic orthodontics: a description of the surgical technique. *J Oral Maxillofac Surg* 2009; **67**: 2160-2166 [PMID: [19761909](#) DOI: [10.1016/j.joms.2009.04.124](#)]
 - 12 **Sanivarapu S**, Addanki PK, Palaparty R, Adurty C. Periodontally accelerated osteogenic orthodontics: Novel perio-ortho interrelationship. *J Indian Soc Periodontol* 2018; **22**: 459-462 [PMID: [30210199](#) DOI: [10.4103/jisp.jisp_188_18](#)]
 - 13 **Vannala V**, Katta A, Reddy MS, Shetty SR, Shetty RM, Khazi SS. Periodontal Accelerated Osteogenic Orthodontics Technique for Rapid Orthodontic Tooth Movement: A Systematic Review. *J Pharm Bioallied Sci* 2019; **11**: S97-S106 [PMID: [31198320](#) DOI: [10.4103/JPBS.JPBS_298_18](#)]
 - 14 **Wilcko W**, Wilcko MT. Accelerating tooth movement: the case for corticotomy-induced orthodontics. *Am J Orthod Dentofacial Orthop* 2013; **144**: 4-12 [PMID: [23810038](#) DOI: [10.1016/j.ajodo.2013.04.009](#)]
 - 15 **Soltani L**, Loomer PM, Chaa EE. A Novel Approach in Periodontally Accelerated Osteogenic Orthodontics (PAOO): A Case Report. *Clin Adv Periodontics* 2019; **9**: 110-114 [PMID: [31490042](#) DOI: [10.1002/cap.10045](#)]
 - 16 **AlHammadi HA**, Wilcko MT, Ferguson DJ. Severe Mandibular Crowding Treated with Nonextraction Periodontally Accelerated Osteogenic Orthodontics. *Int J Periodontics Restorative Dent* 2019; **39**: e188-e194 [PMID: [31449579](#) DOI: [10.11607/prd.3926](#)]
 - 17 **Coscia G**, Coscia V, Peluso V, Addabbo F. Augmented corticotomy combined with accelerated orthodontic forces in class III orthognathic patients: morphologic aspects of the mandibular anterior ridge with cone-beam computed tomography. *J Oral Maxillofac Surg* 2013; **71**: 1760.e1-1760. e9 [PMID: [23773424](#) DOI: [10.1016/j.joms.2013.04.022](#)]
 - 18 **Yu H**, Jiao F, Wang B, Shen SG. Piezoelectric decortication applied in periodontally accelerated osteogenic orthodontics. *J Craniofac Surg* 2013; **24**: 1750-1752 [PMID: [24036771](#) DOI: [10.1097/SCS.0b013e3182902c5a](#)]
 - 19 **Ahn HW**, Seo DH, Kim SH, Park YG, Chung KR, Nelson G. Morphologic evaluation of dentoalveolar structures of mandibular anterior teeth during augmented corticotomy-assisted decompensation. *Am J Orthod Dentofacial Orthop* 2016; **150**: 659-669 [PMID: [27692424](#) DOI: [10.1016/j.ajodo.2016.03.027](#)]
 - 20 **Sebaoun JD**, Kantarci A, Turner JW, Carvalho RS, Van Dyke TE, Ferguson DJ. Modeling of trabecular bone and lamina dura following selective alveolar decortication in rats. *J Periodontol* 2008; **79**: 1679-1688 [PMID: [18771369](#) DOI: [10.1902/jop.2008.080024](#)]
 - 21 **Baloul SS**, Gerstenfeld LC, Morgan EF, Carvalho RS, Van Dyke TE, Kantarci A. Mechanism of action and morphologic changes in the alveolar bone in response to selective alveolar decortication-facilitated tooth movement. *Am J Orthod Dentofacial Orthop* 2011; **139**: S83-101 [PMID: [21435543](#) DOI: [10.1016/j.ajodo.2010.09.026](#)]
 - 22 **Kim YS**, Kim SJ, Yoon HJ, Lee PJ, Moon W, Park YG. Effect of piezopuncture on tooth movement and bone remodeling in dogs. *Am J Orthod Dentofacial Orthop* 2013; **144**: 23-31 [PMID: [23810042](#) DOI: [10.1016/j.ajodo.2013.01.022](#)]
 - 23 **Chin M**. Establishing and Maintaining Osseointegration Within the Functional Matrix. *Int J Periodontics Restorative Dent* 2016; **36**: 29-37 [PMID: [26697551](#) DOI: [10.11607/prd.2623](#)]
 - 24 **Nowzari H**, Yorita FK, Chang HC. Periodontally accelerated osteogenic orthodontics combined with autogenous bone grafting. *Compend Contin Educ Dent* 2008; **29**: 200-6; quiz 207, 218 [PMID: [18533317](#)]
 - 25 **Addanki P**, Gooty JR, Palaparthi R. Clinical and Radiographic Comparative Evaluation of Buccal and Palatal Corticotomy with Buccal Corticotomy in Periodontally Accelerated Osteogenic Orthodontics with Surgical Bur. *Contemp Clin Dent* 2017; **8**: 321-326 [PMID: [28839422](#) DOI: [10.43027/contemp-clin-dent.2017.8.321-326](#)]

- 0.4103/ccd.ccd.846_16]
- 26 **Singh S**, Jayan B. Comparative Evaluation of Periodontally Accelerated Osteogenic Orthodontics (PAOO) Versus Conventional Orthodontic Tooth Movement in Adult Patients with Bimaxillary Dentoalveolar Protrusion. *Int J Periodontics Restorative Dent* 2019; **39**: 571-577 [PMID: [31226197](#) DOI: [10.11607/prd.3771](#)]
- 27 **Frost HM**. The regional acceleratory phenomenon: a review. *Henry Ford Hosp Med J* 1983; **31**: 3-9 [PMID: [6345475](#)]
- 28 **Yaffe A**, Fine N, Binderman I. Regional accelerated phenomenon in the mandible following mucoperiosteal flap surgery. *J Periodontol* 1994; **65**: 79-83 [PMID: [8133418](#) DOI: [10.1902/jop.1994.65.1.79](#)]
- 29 **Frost HM**. The biology of fracture healing. An overview for clinicians. Part I. *Clin Orthop Relat Res* 1989: 283-293 [PMID: [2680202](#)]
- 30 **K S**, M S, D R, Gowd P. Wilkodontics - a novel synergy in time to save time. *J Clin Diagn Res* 2014; **8**: 322-325 [PMID: [24596806](#) DOI: [10.7860/JCDR/2014/7576.3978](#)]
- 31 **Fau V**, Diep D, Bader G, Brézulier D, Sorel O. [Effectiveness of selective alveolar decortication in accelerating orthodontic treatment: a systematic review]. *Orthod Fr* 2017; **88**: 165-178 [PMID: [28597837](#) DOI: [10.1051/orthodfr/2017005](#)]
- 32 **Shih MS**, Norrdin RW. Regional acceleration of remodeling during healing of bone defects in beagles of various ages. *Bone* 1985; **6**: 377-379 [PMID: [4096875](#) DOI: [10.1016/8756-3282\(85\)90336-9](#)]
- 33 **Verna C**, Dalstra M, Melsen B. The rate and the type of orthodontic tooth movement is influenced by bone turnover in a rat model. *Eur J Orthod* 2000; **22**: 343-352 [PMID: [11029824](#) DOI: [10.1093/ejo/22.4.343](#)]
- 34 **Midgett RJ**, Shaye R, Fruge JF Jr. The effect of altered bone metabolism on orthodontic tooth movement. *Am J Orthod* 1981; **80**: 256-262 [PMID: [6945049](#) DOI: [10.1016/0002-9416\(81\)90289-x](#)]
- 35 **Bell WH**, Finn RA, Buschang PH. Accelerated orthognathic surgery and increased orthodontic efficiency: a paradigm shift. *J Oral Maxillofac Surg* 2009; **67**: 2043-2044 [PMID: [19761897](#) DOI: [10.1016/j.joms.2009.07.005](#)]
- 36 **Brugnami F**, Caiazzo A, Mehra P. Can corticotomy (with or without bone grafting) expand the limits of safe orthodontic therapy? *J Oral Biol Craniofac Res* 2018; **8**: 1-6 [PMID: [29556455](#) DOI: [10.1016/j.jobcr.2017.11.001](#)]
- 37 **Williams MO**, Murphy NC. Beyond the Ligament: A Whole-Bone Periodontal View of Dentofacial Orthopedics and Falsification of Universal Alveolar Immutability. *Semin Orthod* 2008; **14**: 246-259 [DOI: [10.1053/j.sodo.2008.07.003](#)]
- 38 **Miron RJ**, Shuang Y, Bosshardt DD, Caballé-Serrano J, Chandad F, Zhang Y. Osteogenic gene array of osteoblasts cultured on a novel osteoinductive biphasic calcium phosphate bone grafting material. *Clin Oral Investig* 2017; **21**: 801-808 [PMID: [27105860](#) DOI: [10.1007/s00784-016-1825-0](#)]
- 39 **Baldwin P**, Li DJ, Auston DA, Mir HS, Yoon RS, Koval KJ. Autograft, Allograft, and Bone Graft Substitutes: Clinical Evidence and Indications for Use in the Setting of Orthopaedic Trauma Surgery. *J Orthop Trauma* 2019; **33**: 203-213 [PMID: [30633080](#) DOI: [10.1097/BOT.0000000000001420](#)]
- 40 **Laurencin C**, Khan Y, El-Amin SF. Bone graft substitutes. *Expert Rev Med Devices* 2006; **3**: 49-57 [PMID: [16359252](#) DOI: [10.1586/17434440.3.1.49](#)]
- 41 **Choukroun J**, Diss A, Simonpiéri A, Girard MO, Schoeffler C, Dohan SL, Dohan AJ, Mouhyi J, Dohan DM. Platelet-rich fibrin (PRF): a second-generation platelet concentrate. Part IV: clinical effects on tissue healing. *Oral Surg Oral Med Oral Pathol Oral Radiol Endod* 2006; **101**: e56-e60 [PMID: [16504852](#) DOI: [10.1016/j.tripleo.2005.07.011](#)]
- 42 **Munoz F**, Jiménez C, Espinoza D, Vervelle A, Beugnet J, Haidar Z. Use of leukocyte and platelet-rich fibrin (L-PRF) in periodontally accelerated osteogenic orthodontics (PAOO): Clinical effects on edema and pain. *J Clin Exp Dent* 2016; **8**: e119-e124 [PMID: [27034749](#) DOI: [10.4317/jced.52760](#)]
- 43 **Canellas JVDS**, Medeiros PJD, Figueredo CMDS, Fischer RG, Ritto FG. Platelet-rich fibrin in oral surgical procedures: a systematic review and meta-analysis. *Int J Oral Maxillofac Surg* 2019; **48**: 395-414 [PMID: [30072300](#) DOI: [10.1016/j.ijom.2018.07.007](#)]
- 44 **Albilila J DMD**, MSc, Herrera-Vizcaino C DDS, Weisleder H BSc, Choukroun J MD, Ghanaati S MD, DMD, PhD. Liquid platelet-rich fibrin injections as a treatment adjunct for painful temporomandibular joints: preliminary results. *Cranio* 2020; **38**: 292-304 [PMID: [30231809](#) DOI: [10.1080/08869634.2018.1516183](#)]
- 45 **Anitua E**, Tejero R, Zalduendo MM, Orive G. Plasma rich in growth factors promotes bone tissue regeneration by stimulating proliferation, migration, and autocrine secretion in primary human osteoblasts. *J Periodontol* 2013; **84**: 1180-1190 [PMID: [23088531](#) DOI: [10.1902/jop.2012.120292](#)]
- 46 **Dohan DM**, Choukroun J, Diss A, Dohan SL, Dohan AJ, Mouhyi J, Gogly B. Platelet-rich fibrin (PRF): a second-generation platelet concentrate. Part II: platelet-related biologic features. *Oral Surg Oral Med Oral Pathol Oral Radiol Endod* 2006; **101**: e45-e50 [PMID: [16504850](#) DOI: [10.1016/j.tripleo.2005.07.009](#)]
- 47 **Miron RJ**, Choukroun J. Platelet rich fibrin in regenerative dentistry: biological background and clinical indications. Hoboken (NJ): John Wiley and Sons, 2017
- 48 **Gassling V**, Hedderich J, Açil Y, Purcz N, Wiltfang J, Douglas T. Comparison of platelet rich fibrin and collagen as osteoblast-seeded scaffolds for bone tissue engineering applications. *Clin Oral Implants Res* 2013; **24**: 320-328 [PMID: [22092514](#) DOI: [10.1111/j.1600-0501.2011.02333.x](#)]
- 49 **Shawky H**, Seifeldin SA. Does Platelet-Rich Fibrin Enhance Bone Quality and Quantity of Alveolar Cleft Reconstruction? *Cleft Palate Craniofac J* 2016; **53**: 597-606 [PMID: [26451499](#) DOI:

- 10.1597/14-290]
- 50 **Wilcko MT**, Ferguson DJ, Makki L, Wilcko WM. Keratinized Gingiva Height Increases After Alveolar Corticotomy and Augmentation Bone Grafting. *J Periodontol* 2015; **86**: 1107-1115 [PMID: 26138808 DOI: 10.1902/jop.2015.150074]
- 51 **Jing WD**, Jiao J, Xu L, Hou JX, Li XT, Wang XX, Xu X, Mao MX. Periodontal soft- and hard-tissue changes after augmented corticotomy in Chinese adult patients with skeletal Angle Class III malocclusion: A non-randomized controlled trial. *J Periodontol* 2020; **91**: 1419-1428 [PMID: 32149391 DOI: 10.1002/JPER.19-0522]



Published by **Baishideng Publishing Group Inc**
7041 Koll Center Parkway, Suite 160, Pleasanton, CA 94566, USA

Telephone: +1-925-3991568

E-mail: bpgoffice@wjgnet.com

Help Desk: <https://www.f6publishing.com/helpdesk>

<https://www.wjgnet.com>

