

# World Journal of *Clinical Cases*

*World J Clin Cases* 2021 February 26; 9(6): 1247-1498



## Contents

Thrice Monthly Volume 9 Number 6 February 26, 2021

## EDITORIAL

- 1247 Interactive platform for peer review: A proposal to improve the current peer review system  
*Emile SH*

## MINIREVIEWS

- 1251 Animal models of cathartic colon  
*Meng YY, Li QD, Feng Y, Liu J, Wang EK, Zhong L, Sun QL, Yuan JY*

## ORIGINAL ARTICLE

## Case Control Study

- 1259 New indicators in evaluation of hemolysis, elevated liver enzymes, and low platelet syndrome: A case-control study  
*Kang SY, Wang Y, Zhou LP, Zhang H*

## Retrospective Study

- 1271 Analysis of hospitalization costs related to fall injuries in elderly patients  
*Su FY, Fu ML, Zhao QH, Huang HH, Luo D, Xiao MZ*
- 1284 Effect of alprostadil in the treatment of intensive care unit patients with acute renal injury  
*Jia Y, Liu LL, Su JL, Meng XH, Wang WX, Tian C*

## Clinical Trials Study

- 1293 Etomidate *vs* propofol in coronary heart disease patients undergoing major noncardiac surgery: A randomized clinical trial  
*Dai ZL, Cai XT, Gao WL, Lin M, Lin J, Jiang YX, Jiang X*

## Observational Study

- 1304 Healthy individuals *vs* patients with bipolar or unipolar depression in gray matter volume  
*Zhang YN, Li H, Shen ZW, Xu C, Huang YJ, Wu RH*
- 1318 Impact of metabolism-related mutations on the heart rate of gastric cancer patients after peritoneal lavage  
*Yuan Y, Yao S, Luo GH, Zhang XY*

## CASE REPORT

- 1329 Efficacy of afatinib in a patient with rare EGFR (G724S/R776H) mutations and amplification in lung adenocarcinoma: A case report  
*He SY, Lin QF, Chen J, Yu GP, Zhang JL, Shen D*

- 1336** Esophageal superficial adenosquamous carcinoma resected by endoscopic submucosal dissection: A rare case report  
*Liu GY, Zhang JX, Rong L, Nian WD, Nian BX, Tian Y*
- 1343** Do medullary thyroid carcinoma patients with high calcitonin require bilateral neck lymph node clearance? A case report  
*Gan FJ, Zhou T, Wu S, Xu MX, Sun SH*
- 1353** Femoral epithelioid hemangioendothelioma detected with magnetic resonance imaging and positron emission tomography/computed tomography: A case report  
*Zhao HG, Zhang KW, Hou S, Dai YY, Xu SB*
- 1359** Noninvasive tools based on immune biomarkers for the diagnosis of central nervous system graft-vs-host disease: Two case reports and a review of the literature  
*Lyu HR, He XY, Hao HJ, Lu WY, Jin X, Zhao YJ, Zhao MF*
- 1367** Periodontally accelerated osteogenic orthodontics with platelet-rich fibrin in an adult patient with periodontal disease: A case report and review of literature  
*Xu M, Sun XY, Xu JG*
- 1379** Subtalar joint pigmented villonodular synovitis misdiagnosed at the first visit: A case report  
*Zhao WQ, Zhao B, Li WS, Assan I*
- 1386** Wilson disease — the impact of hyperimmunity on disease activity: A case report  
*Stremmel W, Longerich T, Liere R, Vacata V, van Helden J, Weiskirchen R*
- 1394** Unexplained elevation of erythrocyte sedimentation rate in a patient recovering from COVID-19: A case report  
*Pu SL, Zhang XY, Liu DS, Ye BN, Li JQ*
- 1402** Thoracic pyogenic infectious spondylitis presented as pneumothorax: A case report  
*Cho MK, Lee BJ, Chang JH, Kim YM*
- 1408** Unilateral pulmonary hemorrhage caused by negative pressure pulmonary edema: A case report  
*Park HJ, Park SH, Woo UT, Cho SY, Jeon WJ, Shin WJ*
- 1416** Osseous Rosai-Dorfman disease of tibia in children: A case report  
*Vithran DTA, Wang JZ, Xiang F, Wen J, Xiao S, Tang WZ, Chen Q*
- 1424** Abdominopelvic leiomyoma with large ascites: A case report and review of the literature  
*Wang YW, Fan Q, Qian ZX, Wang JJ, Li YH, Wang YD*
- 1433** Unusual presentation of granulomatosis with polyangiitis causing periaortitis and consequent subclavian steal syndrome: A case report  
*Cho U, Kim SK, Ko JM, Yoo J*
- 1439** Postoperative discal pseudocyst and its similarities to discal cyst: A case report  
*Fu CF, Tian ZS, Yao LY, Yao JH, Jin YZ, Liu Y, Wang YY*

- 1446** Treatment of oral lichen planus by surgical excision and acellular dermal matrix grafting: Eleven case reports and review of literature  
*Fu ZZ, Chen LQ, Xu YX, Yue J, Ding Q, Xiao WL*
- 1455** Nonalcoholic fatty liver disease as a risk factor for cytomegalovirus hepatitis in an immunocompetent patient: A case report  
*Khiatah B, Nasrollah L, Covington S, Carlson D*
- 1461** Early reoccurrence of traumatic posterior atlantoaxial dislocation without fracture: A case report  
*Sun YH, Wang L, Ren JT, Wang SX, Jiao ZD, Fang J*
- 1469** Intrahepatic cholangiocarcinoma is more complex than we thought: A case report  
*Zeng JT, Zhang JF, Wang Y, Qing Z, Luo ZH, Zhang YL, Zhang Y, Luo XZ*
- 1475** Congenital hepatic fibrosis in a young boy with congenital hypothyroidism: A case report  
*Xiao FF, Wang YZ, Dong F, Li XL, Zhang T*
- 1483** Polidocanol sclerotherapy for multiple gastrointestinal hemangiomas: A case report  
*Yao H, Xie YX, Guo JY, Wu HC, Xie R, Shi GQ*
- 1490** Gastrointestinal stromal tumor with multisegmental spinal metastases as first presentation: A case report and review of the literature  
*Kong Y, Ma XW, Zhang QQ, Zhao Y, Feng HL*



**ABOUT COVER**

Editorial Board Member of *World Journal of Clinical Cases*, Dr. Quach is an Associate Professor of Gastroenterology at the University of Medicine and Pharmacy at Hochiminh City, Viet Nam, where he received his MD in 1997 and his PhD in 2011. Dr. Quach has published more than 100 reviews and original papers in local and international journals. He has received several awards, including Outstanding Presentation at the Biannual Scientific Congress of Vietnamese Nationwide Medical Schools, Medal of Creativeness from the Vietnamese Central Youth League, etc. Currently, he serves as a Vice President of the Vietnam Association of Gastroenterology and Secretary General of the Vietnam Federation for Digestive Endoscopy. (L-Editor: Filipodia)

**AIMS AND SCOPE**

The primary aim of *World Journal of Clinical Cases* (*WJCC*, *World J Clin Cases*) is to provide scholars and readers from various fields of clinical medicine with a platform to publish high-quality clinical research articles and communicate their research findings online.

*WJCC* mainly publishes articles reporting research results and findings obtained in the field of clinical medicine and covering a wide range of topics, including case control studies, retrospective cohort studies, retrospective studies, clinical trials studies, observational studies, prospective studies, randomized controlled trials, randomized clinical trials, systematic reviews, meta-analysis, and case reports.

**INDEXING/ABSTRACTING**

The *WJCC* is now indexed in Science Citation Index Expanded (also known as SciSearch®), Journal Citation Reports/Science Edition, Scopus, PubMed, and PubMed Central. The 2020 Edition of Journal Citation Reports® cites the 2019 impact factor (IF) for *WJCC* as 1.013; IF without journal self cites: 0.991; Ranking: 120 among 165 journals in medicine, general and internal; and Quartile category: Q3. The *WJCC*'s CiteScore for 2019 is 0.3 and Scopus CiteScore rank 2019: General Medicine is 394/529.

**RESPONSIBLE EDITORS FOR THIS ISSUE**

Production Editor: Ji-Hong Lin; Production Department Director: Xiang Li; Editorial Office Director: Jin-Lai Wang.

**NAME OF JOURNAL**

*World Journal of Clinical Cases*

**ISSN**

ISSN 2307-8960 (online)

**LAUNCH DATE**

April 16, 2013

**FREQUENCY**

Thrice Monthly

**EDITORS-IN-CHIEF**

Dennis A Bloomfield, Sandro Vento, Bao-Gan Peng

**EDITORIAL BOARD MEMBERS**

<https://www.wjgnet.com/2307-8960/editorialboard.htm>

**PUBLICATION DATE**

February 26, 2021

**COPYRIGHT**

© 2021 Baishideng Publishing Group Inc

**INSTRUCTIONS TO AUTHORS**

<https://www.wjgnet.com/bpg/gerinfo/204>

**GUIDELINES FOR ETHICS DOCUMENTS**

<https://www.wjgnet.com/bpg/GerInfo/287>

**GUIDELINES FOR NON-NATIVE SPEAKERS OF ENGLISH**

<https://www.wjgnet.com/bpg/gerinfo/240>

**PUBLICATION ETHICS**

<https://www.wjgnet.com/bpg/GerInfo/288>

**PUBLICATION MISCONDUCT**

<https://www.wjgnet.com/bpg/gerinfo/208>

**ARTICLE PROCESSING CHARGE**

<https://www.wjgnet.com/bpg/gerinfo/242>

**STEPS FOR SUBMITTING MANUSCRIPTS**

<https://www.wjgnet.com/bpg/GerInfo/239>

**ONLINE SUBMISSION**

<https://www.f6publishing.com>



## Abdominopelvic leiomyoma with large ascites: A case report and review of the literature

Yi-Wei Wang, Qiong Fan, Zhao-Xia Qian, Jin-Jin Wang, Yu-Hong Li, Yu-Dong Wang

**ORCID number:** Yi-Wei Wang 0000-0003-1314-1833; Qiong Fan 0000-0001-8702-7406; Zhao-Xia Qian 0000-0002-8311-9933; Jin-Jin Wang 0000-0002-4619-5005; Yu-Hong Li 0000-0003-0729-0824; Yu-Dong Wang 0000-0003-4251-4109.

**Author contributions:** Wang YW conceived the study, did literature search, and coordinated preparation of the manuscript for submission; Fan Q helped perform the analysis with constructive discussions; Fan Q, Qian ZX, and Wang JJ helped in literature search and in preparation of the manuscript; Li YH and Wang YD reviewed and edited the manuscript for final submission; all authors read and approved the manuscript.

**Supported by** Shanghai Municipal Key Clinical Specialty, No. Shslczdzk06302.

**Informed consent statement:** Informed consent was obtained from the patient for publication of this manuscript and any accompanying images.

**Conflict-of-interest statement:** The authors declare that they have no conflict of interest to report.

**CARE Checklist (2016) statement:** The authors have read the CARE Checklist (2016), and the

**Yi-Wei Wang, Qiong Fan, Yu-Hong Li, Yu-Dong Wang,** Department of Gynecological Oncology, International Peace Maternity & Child Health Hospital, Shanghai Jiaotong University, Shanghai 200000, China

**Zhao-Xia Qian,** Department of Radiology, International Peace Maternity & Child Health Hospital, Shanghai Jiaotong University, Shanghai 200000, China

**Jin-Jin Wang,** Department of Pathology, International Peace Maternity & Child Health Hospital, Shanghai Jiaotong University, Shanghai 200000, China

**Corresponding author:** Yu-Dong Wang, PhD, Professor, Department of Gynecological Oncology, International Peace Maternity & Child Health Hospital, Shanghai Jiaotong University, No. 145 Lane, Guangyuan Road, Xuhui District, Shanghai 200000, China. [wangyudong6688@126.com](mailto:wangyudong6688@126.com)

### Abstract

#### BACKGROUND

Leiomyoma of the uterus is relatively common, but uterine leiomyoma of the greater omentum is rare.

#### CASE SUMMARY

Here, we report the case of a 22-year-old woman who presented with a 3 mo history of progressive abdominal distension and a hypervascular abdominopelvic mass. Due to a high serum concentration of CA125, the preoperative diagnosis was unclear. During surgery, 5 L of ascites was removed. An 18.8 cm solid mass, which was pedunculated from the uterine fundus and exhibited complex adhesion to the greater omentum, was removed. The CA125 level was reduced postoperatively, and a pathologic study confirmed that the mass was a leiomyoma that originated in the uterus.

#### CONCLUSION

Uterine leiomyoma can share vessels with the greater omentum. This case highlights the difficulty of diagnosing pseudo-Meigs syndrome and the importance of imaging and laboratory examinations.

**Key Words:** Leiomyoma; Ascites; Greater omentum; Pseudo-Meigs syndrome; CA125; Case report

manuscript was prepared and revised according to the CARE Checklist (2016).

**Open-Access:** This article is an open-access article that was selected by an in-house editor and fully peer-reviewed by external reviewers. It is distributed in accordance with the Creative Commons Attribution NonCommercial (CC BY-NC 4.0) license, which permits others to distribute, remix, adapt, build upon this work non-commercially, and license their derivative works on different terms, provided the original work is properly cited and the use is non-commercial. See: <http://creativecommons.org/licenses/by-nc/4.0/>

**Manuscript source:** Unsolicited manuscript

**Specialty type:** Medicine, research and experimental

**Country/Territory of origin:** China

**Peer-review report's scientific quality classification**

Grade A (Excellent): 0  
Grade B (Very good): 0  
Grade C (Good): C, C  
Grade D (Fair): 0  
Grade E (Poor): 0

**Received:** October 13, 2020

**Peer-review started:** October 13, 2020

**First decision:** November 24, 2020

**Revised:** December 8, 2020

**Accepted:** December 23, 2020

**Article in press:** December 23, 2020

**Published online:** February 26, 2021

**P-Reviewer:** Vij M

**S-Editor:** Fan JR

**L-Editor:** Wang TQ

**P-Editor:** Li JH



©The Author(s) 2021. Published by Baishideng Publishing Group Inc. All rights reserved.

**Core Tip:** We report a case of uterine leiomyoma of the greater omentum with a high serum concentration of CA125 and pseudo-Meigs syndrome. It is rarely seen in this condition. Upon entering the abdomen, up to 5000 mL of yellow ascites was removed by suction. A large solid cystic neoplasm that measured almost 20 cm was found and diagnosed as leiomyoma pathologically later.

**Citation:** Wang YW, Fan Q, Qian ZX, Wang JJ, Li YH, Wang YD. Abdominopelvic leiomyoma with large ascites: A case report and review of the literature. *World J Clin Cases* 2021; 9(6): 1424-1432

**URL:** <https://www.wjgnet.com/2307-8960/full/v9/i6/1424.htm>

**DOI:** <https://dx.doi.org/10.12998/wjcc.v9.i6.1424>

## INTRODUCTION

Uterine leiomyomas are common benign smooth muscle tumors that affect up to 80% of women<sup>[1,2]</sup>. Common uterine leiomyomas principally result from the estrogen- and progesterone-dependent transformation of uterine smooth muscle<sup>[3]</sup>. Affected women may complain of bleeding, pain, pressure, or infertility, but few eventually develop uterine sarcoma<sup>[4,5]</sup>.

Meigs syndrome is a clinical triad whose pathology is limited to ovarian fibroma, fibrothecoma, Brenner tumor, and granulosa cell tumor<sup>[6,7]</sup> and is a syndrome characterized by ascites and hydrothorax. Pseudo-Meigs syndrome is defined as a disorder similar to Meigs syndrome, in which neoplasms of different histological types, including uterine leiomyomas, are present<sup>[8-10]</sup>. Uterine leiomyomas that present as pseudo-Meigs syndrome have already been described in the literature<sup>[11-14]</sup>. However, few cases of pseudo-Meigs syndrome in which a leiomyoma is implanted on the omentum have been reported<sup>[15]</sup>. In this study, we report a massive abdominopelvic leiomyoma with large ascites in a 22-year-old woman.

## CASE PRESENTATION

### Chief complaints

A 22-year-old woman presented to the outpatient unit with abdominal pain.

### History of present illness

The patient was not married and had never been pregnant. She reported no recent trauma, fall, or sexual intercourse. She reported a normal menstrual cycle with a menstrual period 18 d prior to her visit. The patient also reported a 3 mo history of increased abdominal circumference, which she considered a "pot belly".

A review of systems was notable for findings of abdominal pain and a lack of appetite, but the woman denied clinical indications of constipation, diarrhea, vaginal bleeding, nausea, emesis, or urinary urgency or frequency.

### Physical examination

The abdomen was gravid, soft, and firm. A rectovaginal examination revealed a movable mass at the front of the uterus.

### Laboratory examinations

The patient's laboratory test results are shown in [Table 1](#). Unexpectedly, the CA125 level was elevated to 569.5 U/mL.

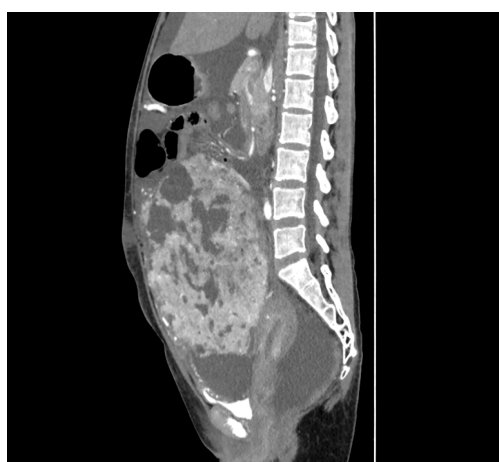
### Imaging examinations

Computed tomography (CT) of the pelvis was performed after administration of an intravenous contrast agent ([Figure 1](#)), and magnetic resonance imaging (MRI) (data not shown) revealed a large mass with a maximum cross-section of 18.8 cm × 13.5 cm.

**Table 1 Laboratory data**

Variable	Reference range, IPMCH <sup>1</sup>	1 d after admission	1 d after operation	1 d before discharge
Hematocrit (%)	33.5-45	38.8	25.8↓	25.7↓
Hemoglobin (g/L)	113-151	133	85↓	85↓
White cell count (10 <sup>9</sup> /L)	3.69-9.16	6.5	15.0↑	6.9
Platelet count (10 <sup>9</sup> /L)	101-320	337↑	188	500↑
Sodium (mmoL/L)	135-145	138	135	140
Potassium (mmoL/L)	3.5-5.5	4.37	4.15	4.75
Chloride (mmoL/L)	95-110	96	103	99
Creatinine (μmoL/L)	45-84	48	46	41
Albumin (g/L)	40-55	47.5	23.3↓	45.5
Alanine aminotransferase (U/L)	0-42	25	10	8
Aspartate transaminase (U/L)	0-42	32	17	17
Prothrombin time (sec)	11-14.5	13.0	14.7↑	14.1
International normalized ratio	0.95-1.125	1.00	1.17	1.11
Activated partial thromboplastin time (sec)	28-45	39.5	46.6↑	51.5↑
D-dimer (mg/L)	0-1.0	3.19↑	5.81↑	3.02↑
CEA (μg/L)	< 5.2	0.8	0.8	0.8
CA125 (U/mL)	< 35	569.5↑	192.3↑	162↑
CA199 (U/mL)	< 35	13.7	8.7	10.2
AFP (μg/L)	< 7.0	2.0	1.5	1.6
BMI	19-25	19.5	15.8	16.2

<sup>1</sup>Reference values are affected by many variables, including the patient population and the laboratory methods used. The ranges used at the International Peace Maternity and Child Health Hospital of China Welfare Institute, are for adults who are not pregnant and do not have medical conditions that could affect the results. They may therefore not be appropriate for all patients. IPMCH: International Peace Maternity and Child Health Hospital of China Welfare Institute; CEA: Carcinoembryonic antigen; AFP: Alpha fetal protein; BMI: Body mass index.

**Figure 1** Enhanced computed tomography of the abdomen/pelvis showing a large preperitoneal mass joined to the uterus.

Massive abdominal edema was also recorded. No evidence of swollen lymph nodes was found. Computed tomography angiography (CTA) revealed an abundant blood supply to the mass, which was provided by the uterine artery, superior mesenteric artery, and predominantly, by the gastroduodenal artery (Figure 2).

## FINAL DIAGNOSIS

The mass was determined to be a uterine-derived leiomyoma that had implanted on the omentum majus.

## TREATMENT

The patient underwent abdominal aortic balloon catheter placement in case of hemorrhage and later underwent exploratory laparotomy under combined spinal-epidural anesthesia. Upon entering the abdomen, up to 5000 mL of yellow ascites was removed by suction (Figure 3A). Ascitic fluid cytology revealed aggregated cells with inconspicuous atypia. A large solid cystic neoplasm that measured almost 20 cm was also found (Figure 3B). In addition, careful inspection after ligation of the omental vessels showed that the omental fat had vanished and that vessels from the greater omentum, which were shared with the mass, were engorged. Adhesions between the mass and the ileocecum, appendix, and descending colon were observed. The mass was found to be attached to the uterine fundus by a 3-cm-wide pedicle (Figure 3C). Resection of the mass and appendix was then performed (Figure 3D), and during surgery, the total blood loss was 1200 mL.

## OUTCOME AND FOLLOW-UP

The patient was transferred to recovery in a stable condition, and on postoperative day 8, she was discharged from the hospital.

A pathologic study of the specimen confirmed a diagnosis of leiomyoma. Hydropic degeneration, hyaline degeneration, and cystic degeneration were recorded. An immunohistochemical analysis showed that the leiomyoma cells were positive for progesterone receptor, estrogen receptor, h-caldesmon, and smooth muscle actin (Figure 4). The tissue was negative for CD10, CD117, HMB45, Dog-1, and Ki67. The mass was determined to be a uterine-derived leiomyoma that had implanted on the omentum majus.

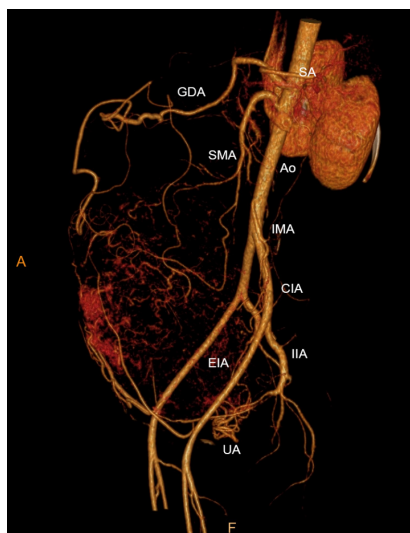
## DISCUSSION

The unique features of the presented case can be summarized as follows: A massive leiomyoma with the “digested” greater omentum and an elevated CA125 level accompanied by pseudo-Meigs syndrome. Uterine leiomyoma is the most common benign gynecological neoplasm<sup>[16]</sup>. However, elevated CA125 levels, a massive leiomyoma, and large ascites, which are collectively known as pseudo-Meigs syndrome, are rarely seen in this condition<sup>[11-14,17-20]</sup>. In addition, no agreement on the pathogenesis of this rare condition has been established.

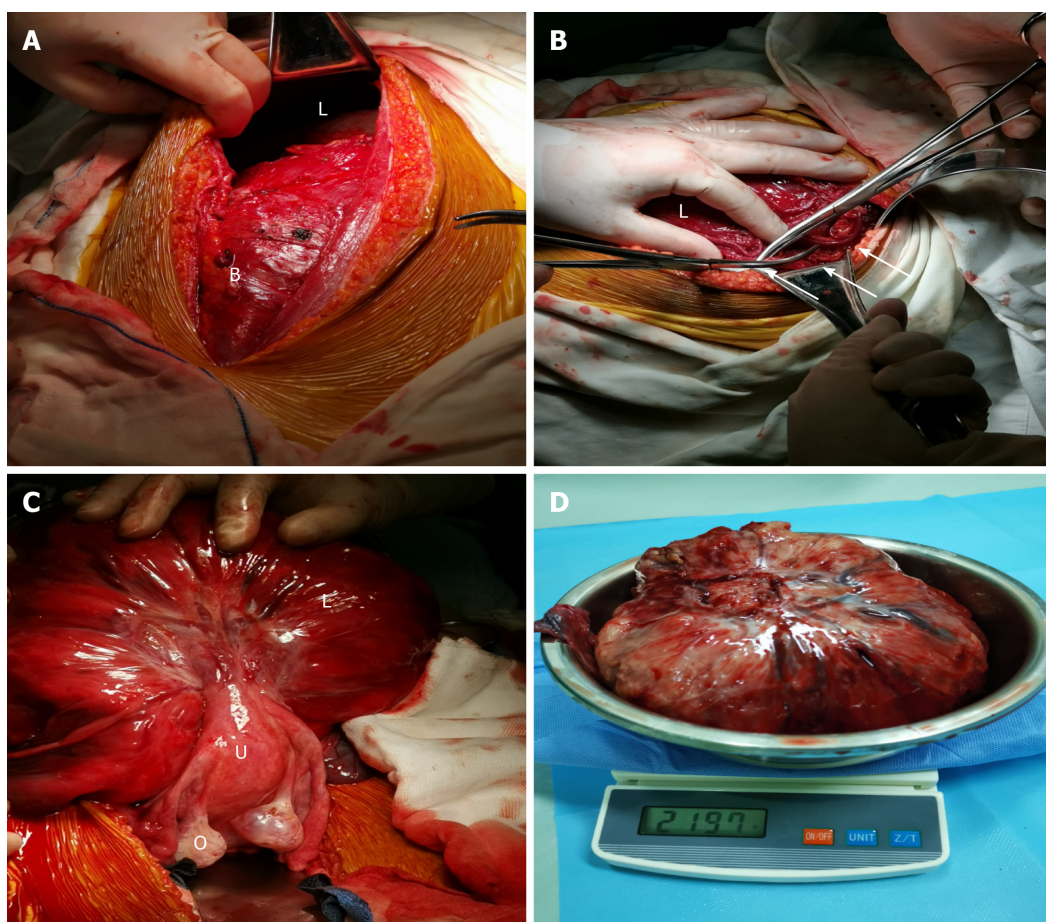
In this case, the increased abdominal circumference was considered to have resulted from pleural effusion and ascites. The pathogenesis of ascites in pseudo-Meigs syndrome is still not well defined<sup>[21]</sup>. According to several hypotheses, the release of inflammatory cytokines and growth factors may cause vascular permeability<sup>[22-24]</sup>. An imbalance among arterial flow, venous drainage, and direct pressure of the mass itself on lymphatic vessels may have caused the accumulation of nearly 5 L of ascites fluid in this case<sup>[25]</sup>.

Removal of the large leiomyoma could resolve the ascites, but it is difficult to perform a complete excision when a leiomyoma is broadly adhered to adjacent structures. Full preparation, including detailed information about the size of the mass and its properties, could help in the design of a better surgical strategy<sup>[26]</sup>. Specifically, various imaging techniques, including CT and MRI, were used in this case, and both modalities indicated an 18-cm mass with abdominal edema.





**Figure 2** Computed tomography angiography showing an abundant blood supply surrounding the mass. CIA: Common iliac artery; EIA: External iliac artery; GDA: Gastrooduodenal artery; IIA: Internal iliac artery; IMA: Inferior mesenteric artery; SA: Splenic artery; SMA: Superior mesenteric artery; UA: Uterine artery.



**Figure 3** Intraoperative findings. A: Bladder with a dense adhesion and the mass, which extended 3 cm below the umbilicus; B: Engorged vessels of the omentum majus that appeared along the surface of the mass; C: Lifted and turned mass showing a pedicle attached to the uterine fundus; D: Resected mass along with its pedicle stump.

CTA confirmed an abundant blood supply to the mass. During the surgery, distended blood vessels from the omentum (top), uterus (bottom), and colon (lateral) were observed and carefully ligated. Notably, the uterovesical peritoneal reflection was lifted, which was evidently due to the massive leiomyoma. Thus, preparations should have been made to reduce the risk of injury and to prevent uncontrolled bleeding or incomplete resection. Therefore, we performed abdominal aortic balloon catheter placement before surgery<sup>[27]</sup>.

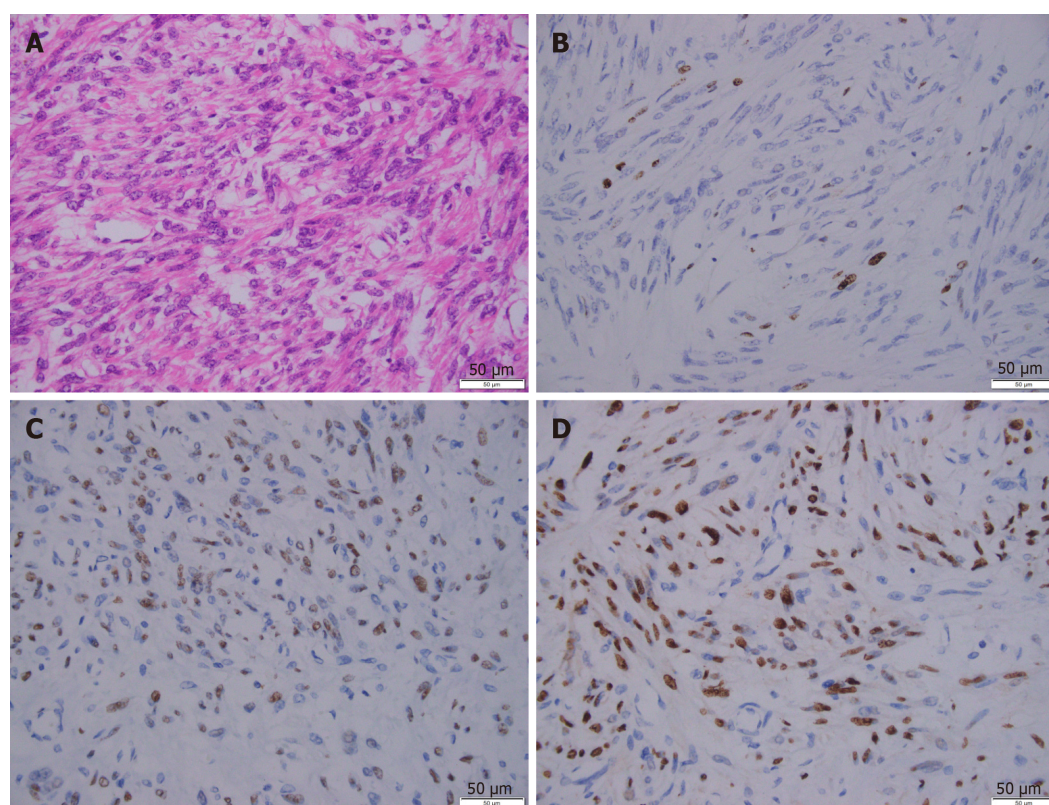
The elevated CA125 level is another complicating factor in this case. It is well known that as a high molecular weight glycoprotein, CA125 is expressed in a substantial proportion of ovarian cancers<sup>[28]</sup>. It has been reported that the serum CA125 levels range from 20 to over 1000 IU/mL in patients with leiomyomas<sup>[29-31]</sup>. Due to the significant overlap between malignancies and myomas, CA125 failed to provide a potential benefit for differential diagnosis<sup>[32]</sup>. The destruction of the peritoneum and severe adhesions of the omentum could explain why CA125 was overexpressed before surgery and reduced after surgery<sup>[33,34]</sup>.

A preoperative diagnosis of a pelvic mass with pseudo-Meigs syndrome remains very challenging, especially in cases such as the one presented in this study. In these cases, an accurate diagnosis may only be made after surgery. For oncological safety, patients with myomas may undergo hysterectomy or ovariectomy, which impairs reproductive function. On the contrary, an overly optimistic presumption of a benign leiomyoma may lead to the intra-abdominal spread of an unexpected sarcoma, which could result in poor survival. Therefore, it is always important to consider a broad differential diagnosis and employ the necessary scrutiny using imaging techniques. Uterine sarcomas are rare gynecological neoplasms, and some researchers believe that sarcomas originate from benign leiomyomas because they contain the same epithelial progenitor cells<sup>[35]</sup>. Currently, no diagnostic technique is available to accurately distinguish this neoplasm. A meta-analysis revealed that the expression of CA125, lactate dehydrogenase (LDH), and GDF-15 proteins is altered in sarcomas and that their serum levels are statistically higher<sup>[35]</sup>. In our case, the CA125 level was elevated. However, we interpreted this finding and believed that the higher level was due to the implantation of the leiomyoma on the omentum rather than as a cancer-related signal. Deficiency of LDH and GDF-15 levels was not assessed in our case. In addition, MRI may help in the preoperative distinction of sarcomas from benign leiomyomas<sup>[36]</sup>. In our case, MRI revealed no swollen lymph nodes. However, the abundant blood supply to the mass observed on CTA imaging still roused our suspicion of a malignancy. Adenomyosis is another differential diagnosis of leiomyoma. A recent study has shown that MRI and elevated CA125 levels are fairly accurate for the diagnosis of adenomyosis, with a high sensitivity and specificity<sup>[29]</sup>. A mean serum CA125 level of 19 U/mL has been established as the cutoff value. We speculated that this cutoff did not apply to our case because of the size of the mass and the tight adhesion. Preoperative MRI revealed a suspected abdominopelvic mass with large ascites, which did not support the diagnosis of adenomyosis.

## CONCLUSION

In conclusion, we have presented an unusual case of pseudo-Meigs syndrome with a uterine leiomyoma and an elevated CA125 level. CTA was used for the detection and ligation of the parasitic blood supply (in this case, mainly the blood vessels of the greater omentum). Surgeons should be aware of the malignant potential of this tumor and plan for the optimal surgical procedure, which would lead to a more appropriate treatment strategy.





**Figure 4 Representative immunohistochemical images of the leiomyoma.** A: H&E staining; B: Ki67 staining; C: Estrogen receptor staining; D: Progesterone receptor staining. Scale bar: 50 µm.

## REFERENCES

- 1 **Marsh EE**, Ekpo GE, Cardozo ER, Brocks M, Dune T, Cohen LS. Racial differences in fibroid prevalence and ultrasound findings in asymptomatic young women (18-30 years old): a pilot study. *Fertil Steril* 2013; **99**: 1951-1957 [PMID: [23498888](#) DOI: [10.1016/j.fertnstert.2013.02.017](#)]
- 2 **Babacan A**, Kizilaslan C, Gun I, Muhcu M, Mungen E, Atay V. CA 125 and other tumor markers in uterine leiomyomas and their association with lesion characteristics. *Int J Clin Exp Med* 2014; **7**: 1078-1083 [PMID: [24955185](#)]
- 3 **Commandeur AE**, Styer AK, Teixeira JM. Epidemiological and genetic clues for molecular mechanisms involved in uterine leiomyoma development and growth. *Hum Reprod Update* 2015; **21**: 593-615 [PMID: [26141720](#) DOI: [10.1093/humupd/dmv030](#)]
- 4 **Quade BJ**, Wang TY, Sornberger K, Dal Cin P, Mutter GL, Morton CC. Molecular pathogenesis of uterine smooth muscle tumors from transcriptional profiling. *Genes Chromosomes Cancer* 2004; **40**: 97-108 [PMID: [15101043](#) DOI: [10.1002/gcc.20018](#)]
- 5 **Skubitz KM**, Skubitz AP. Differential gene expression in leiomyosarcoma. *Cancer* 2003; **98**: 1029-1038 [PMID: [12942572](#) DOI: [10.1002/encr.11586](#)]
- 6 **Kawakubo N**, Okido M, Tanaka R, Mitsugi K, Fukuhara M, Aishima S, Kato M, Ichimiya H. Pseudo-Meigs' syndrome associated with breast cancer metastasis to both ovaries: Report of a case. *Surg Today* 2010; **40**: 1148-1151 [PMID: [21110158](#) DOI: [10.1007/s00595-009-4187-2](#)]
- 7 **Meigs JV**, Armstrong SH, Hamilton HH. A further contribution to the syndrome of fi broma of the ovary with fluid in the abdomen and chest: Meigs' syndrome. *Am J Obstet Gynecol* 1943; **46**: 19-37
- 8 **Schmitt R**, Weichert W, Schneider W, Luft FC, Kettritz R. Pseudo-pseudo Meigs' syndrome. *Lancet* 2005; **366**: 1672 [PMID: [16271650](#) DOI: [10.1016/S0140-6736\(05\)67666-0](#)]
- 9 **MEIGS JV**. Pelvic tumors other than fibromas of the ovary with ascites and hydrothorax. *Obstet Gynecol* 1954; **3**: 471-486 [PMID: [13154792](#)]
- 10 **Kyo K**, Maema A, Shirakawa M, Nakamura T, Koda K, Yokoyama H. Pseudo-Meigs' syndrome secondary to metachronous ovarian metastases from transverse colon cancer. *World J Gastroenterol* 2016; **22**: 4604-4609 [PMID: [27182170](#) DOI: [10.3748/wjg.v22.i18.4604](#)]
- 11 **Tsao KC**, Hong JH, Wu TL, Chang PY, Sun CF, Wu JT. Elevation of CA 19-9 and chromogranin A, in addition to CA 125, are detectable in benign tumors in leiomyomas and endometriosis. *J Clin Lab Anal* 2007; **21**: 193-196 [PMID: [17506483](#) DOI: [10.1002/jcla.20168](#)]
- 12 **Yaguchi A**, Ban K, Koshida Y, Fujikami Y, Ogura E, Terada A, Akagi K, Matsumoto H, Tobiume T, Okagaki A, Tatsumi K. Pseudo-Meigs Syndrome Caused by a Giant Uterine Leiomyoma with Cystic Degeneration: A Case Report. *J Nippon Med Sch* 2020; **87**: 80-86 [PMID: [31902853](#) DOI: [10.1272/jnms.JNMS.2020\\_87-205](#)]



- 13 **Dong R**, Jin C, Zhang Q, Yang X, Kong B. Cellular leiomyoma with necrosis and mucinous degeneration presenting as pseudo-Meigs' syndrome with elevated CA125. *Oncol Rep* 2015; **33**: 3033-3037 [PMID: [25891047](#) DOI: [10.3892/or.2015.3912](#)]
- 14 **Buckshee K**, Dhond AJ, Mittal S, Bose S. Pseudo-Meigs' syndrome secondary to broad ligament leiomyoma: a case report. *Asia Oceania J Obstet Gynaecol* 1990; **16**: 201-205 [PMID: [2088242](#) DOI: [10.1111/j.1447-0756.1990.tb00226.x](#)]
- 15 **Oguma T**, Yamasaki N, Nakanishi K, Kinoshita D, Mitsuhashi T, Nakagawa S. Pseudo-Meigs' syndrome associated with hydropic degenerating uterine leiomyoma: a case report. *J Obstet Gynaecol Res* 2014; **40**: 1137-1140 [PMID: [24612300](#) DOI: [10.1111/jog.12299](#)]
- 16 **Styer AK**, Rueda BR. The Epidemiology and Genetics of Uterine Leiomyoma. *Best Pract Res Clin Obstet Gynaecol* 2016; **34**: 3-12 [PMID: [26725703](#) DOI: [10.1016/j.bpobgyn.2015.11.018](#)]
- 17 **Kebapci M**, Aslan O, Kaya T, Yalcin OT, Ozalp S. Pedunculated uterine leiomyoma associated with pseudo-Meigs' syndrome and elevated CA-125 level: CT features. *Eur Radiol* 2002; **12** Suppl 3: S127-S129 [PMID: [12522621](#) DOI: [10.1007/s00330-002-1464-5](#)]
- 18 **Weinrach DM**, Wang KL, Keh P, Sambasiva Rao M. Pathologic quiz case: a 40-year-old woman with a large pelvic mass, ascites, massive right hydrothorax, and elevated CA 125. Uterine symplastic leiomyoma associated with pseudo-Meigs syndrome and elevated CA 125. *Arch Pathol Lab Med* 2004; **128**: 933-934 [PMID: [15270600](#) DOI: [10.1043/1543-2165\(2004\)128<933:PQCAWY>2.0.CO;2](#)]
- 19 **Ricci G**, Inglese S, Candiotto A, Maso G, Piccoli M, Alberico S, Guaschino S. Ascites in puerperium: a rare case of atypical pseudo-Meigs' syndrome complicating the puerperium. *Arch Gynecol Obstet* 2009; **280**: 1033-1037 [PMID: [19322576](#) DOI: [10.1007/s00404-009-1041-0](#)]
- 20 **Kurai M**, Shiozawa T, Noguchi H, Konishi I. Leiomyoma of the ovary presenting with Meigs' syndrome. *J Obstet Gynaecol Res* 2005; **31**: 257-262 [PMID: [15916664](#) DOI: [10.1111/j.1447-0756.2005.00285.x](#)]
- 21 **Yip HK**, Huang LW, Lin YH, Hwang JL. Massive ascites caused by a large pedunculated subserosal uterine leiomyoma that has feeding arteries from peripheral tissues and exhibits elevated CA125: a case report of atypical Pseudo-Meigs' syndrome. *J Obstet Gynaecol* 2014; **34**: 107 [PMID: [24359072](#) DOI: [10.3109/01443615.2013.832736](#)]
- 22 **Tajima Y**, Kameyama H, Yamada S, Yagi R, Nakano M, Nagahashi M, Shimada Y, Sakata J, Kobayashi T, Umezue H, Wakai T. Long-term survival in pseudo-Meigs' syndrome caused by ovarian metastases from colon cancer. *World J Surg Oncol* 2016; **14**: 286 [PMID: [27842595](#) DOI: [10.1186/s12957-016-1040-0](#)]
- 23 **Yin H**, Li XH, Xu HM, Lu YP. Pseudo-Meigs' syndrome secondary to bilateral ovarian endometrioid carcinomas. *Int J Gynaecol Obstet* 1999; **66**: 293-295 [PMID: [10580681](#) DOI: [10.1016/s0020-7292\(99\)00089-2](#)]
- 24 **Ishiko O**, Yoshida H, Sumi T, Hirai K, Ogita S. Vascular endothelial growth factor levels in pleural and peritoneal fluid in Meigs' syndrome. *Eur J Obstet Gynecol Reprod Biol* 2001; **98**: 129-130 [PMID: [11516814](#) DOI: [10.1016/s0301-2115\(01\)00290-1](#)]
- 25 **Migishima F**, Jobo T, Hata H, Sato R, Ikeda Y, Arai M, Kuramoto H. Uterine leiomyoma causing massive ascites and left pleural effusion with elevated CA 125: a case report. *J Obstet Gynaecol Res* 2000; **26**: 283-287 [PMID: [11049239](#) DOI: [10.1111/j.1447-0756.2000.tb01323.x](#)]
- 26 **Roques F**, Sanchez B, Bucher B, Larivière J. Role of pre-operative assessment in the surgical management of leiomyoma extended to the right heart chambers: a compendium of information from isolated reports. *Eur J Cardiothorac Surg* 2001; **19**: 522-524 [PMID: [11306327](#) DOI: [10.1016/s1010-7940\(01\)00604-2](#)]
- 27 **Kingdom JC**, Hobson SR, Murji A, Allen L, Windrim RC, Lockhart E, Collins SL, Soleymani Majd H, Alazzam M, Naaisa F, Shamshirsaz AA, Belfort MA, Fox KA. Minimizing surgical blood loss at cesarean hysterectomy for placenta previa with evidence of placenta increta or placenta percreta: the state of play in 2020. *Am J Obstet Gynecol* 2020; **223**: 322-329 [PMID: [32007492](#) DOI: [10.1016/j.ajog.2020.01.044](#)]
- 28 **He RH**, Yao WM, Wu LY, Mao YY. Highly elevated serum CA-125 levels in patients with non-malignant gynecological diseases. *Arch Gynecol Obstet* 2011; **283** Suppl 1: 107-110 [PMID: [21069368](#) DOI: [10.1007/s00404-010-1717-5](#)]
- 29 **Kil K**, Chung JE, Pak HJ, Jeung IC, Kim JH, Jo HH, Kim MR. Usefulness of CA125 in the differential diagnosis of uterine adenomyosis and myoma. *Eur J Obstet Gynecol Reprod Biol* 2015; **185**: 131-135 [PMID: [25577553](#) DOI: [10.1016/j.ejogrb.2014.12.008](#)]
- 30 **Çınar M**, Aksoy RT, Güzel Aİ, Tokmak A, Yenicesu O, Sarıkaya E, Evliyaoğlu Ö. The association between clinical parameters and uterine fibroid size in patients who underwent abdominal myomectomy. *J Exp Ther Oncol* 2016; **11**: 195-198 [PMID: [28471125](#)]
- 31 **Bast RC Jr**, Badgwell D, Lu Z, Marquez R, Rosen D, Liu J, Baggerly KA, Atkinson EN, Skates S, Zhang Z, Lokshin A, Menon U, Jacobs I, Lu K. New tumor markers: CA125 and beyond. *Int J Gynecol Cancer* 2005; **15** Suppl 3: 274-281 [PMID: [16343244](#) DOI: [10.1111/j.1525-1438.2005.00441.x](#)]
- 32 **Yilmaz N**, Sahin I, Kilic S, Ozgu E, Gungor T, Bilge U. Assessment of the predictivity of preoperative serum CA 125 in the differential diagnosis of uterine leiomyoma and uterine sarcoma in the Turkish female population. *Eur J Gynaecol Oncol* 2009; **30**: 412-414 [PMID: [19761133](#)]
- 33 **Tolman CJ**, Vaid T, Schreuder HW. Extremely elevated CA-125 in benign ovarian disease due to stretch of the peritoneum. *BMJ Case Rep* 2012; **2012** [PMID: [23188839](#) DOI: [10.1136/bmjcr-2012-000000](#)]

- 10.1136/bcr-2012-006664]
- 34 **Bottoni P**, Scatena R. The Role of CA 125 as Tumor Marker: Biochemical and Clinical Aspects. *Adv Exp Med Biol* 2015; **867**: 229-244 [PMID: 26530369 DOI: 10.1007/978-94-017-7215-0\_14]
- 35 **Zhang P**, Zhang C, Hao J, Sung CJ, Quddus MR, Steinhoff MM, Lawrence WD. Use of X-chromosome inactivation pattern to determine the clonal origins of uterine leiomyoma and leiomyosarcoma. *Hum Pathol* 2006; **37**: 1350-1356 [PMID: 16949924 DOI: 10.1016/j.humpath.2006.05.005]
- 36 **Kido A**, Togashi K, Koyama T, Yamaoka T, Fujiwara T, Fujii S. Diffusely enlarged uterus: evaluation with MR imaging. *Radiographics* 2003; **23**: 1423-1439 [PMID: 14615554 DOI: 10.1148/rg.236035033]



Published by **Baishideng Publishing Group Inc**  
7041 Koll Center Parkway, Suite 160, Pleasanton, CA 94566, USA

**Telephone:** +1-925-3991568

**E-mail:** [bpgoffice@wjgnet.com](mailto:bpgoffice@wjgnet.com)

**Help Desk:** <https://www.f6publishing.com/helpdesk>

<https://www.wjgnet.com>

