

# World Journal of *Clinical Cases*

*World J Clin Cases* 2021 February 26; 9(6): 1247-1498



## Contents

Thrice Monthly Volume 9 Number 6 February 26, 2021

## EDITORIAL

- 1247 Interactive platform for peer review: A proposal to improve the current peer review system  
*Emile SH*

## MINIREVIEWS

- 1251 Animal models of cathartic colon  
*Meng YY, Li QD, Feng Y, Liu J, Wang EK, Zhong L, Sun QL, Yuan JY*

## ORIGINAL ARTICLE

## Case Control Study

- 1259 New indicators in evaluation of hemolysis, elevated liver enzymes, and low platelet syndrome: A case-control study  
*Kang SY, Wang Y, Zhou LP, Zhang H*

## Retrospective Study

- 1271 Analysis of hospitalization costs related to fall injuries in elderly patients  
*Su FY, Fu ML, Zhao QH, Huang HH, Luo D, Xiao MZ*
- 1284 Effect of alprostadil in the treatment of intensive care unit patients with acute renal injury  
*Jia Y, Liu LL, Su JL, Meng XH, Wang WX, Tian C*

## Clinical Trials Study

- 1293 Etomidate *vs* propofol in coronary heart disease patients undergoing major noncardiac surgery: A randomized clinical trial  
*Dai ZL, Cai XT, Gao WL, Lin M, Lin J, Jiang YX, Jiang X*

## Observational Study

- 1304 Healthy individuals *vs* patients with bipolar or unipolar depression in gray matter volume  
*Zhang YN, Li H, Shen ZW, Xu C, Huang YJ, Wu RH*
- 1318 Impact of metabolism-related mutations on the heart rate of gastric cancer patients after peritoneal lavage  
*Yuan Y, Yao S, Luo GH, Zhang XY*

## CASE REPORT

- 1329 Efficacy of afatinib in a patient with rare EGFR (G724S/R776H) mutations and amplification in lung adenocarcinoma: A case report  
*He SY, Lin QF, Chen J, Yu GP, Zhang JL, Shen D*

- 1336** Esophageal superficial adenosquamous carcinoma resected by endoscopic submucosal dissection: A rare case report  
*Liu GY, Zhang JX, Rong L, Nian WD, Nian BX, Tian Y*
- 1343** Do medullary thyroid carcinoma patients with high calcitonin require bilateral neck lymph node clearance? A case report  
*Gan FJ, Zhou T, Wu S, Xu MX, Sun SH*
- 1353** Femoral epithelioid hemangioendothelioma detected with magnetic resonance imaging and positron emission tomography/computed tomography: A case report  
*Zhao HG, Zhang KW, Hou S, Dai YY, Xu SB*
- 1359** Noninvasive tools based on immune biomarkers for the diagnosis of central nervous system graft-vs-host disease: Two case reports and a review of the literature  
*Lyu HR, He XY, Hao HJ, Lu WY, Jin X, Zhao YJ, Zhao MF*
- 1367** Periodontally accelerated osteogenic orthodontics with platelet-rich fibrin in an adult patient with periodontal disease: A case report and review of literature  
*Xu M, Sun XY, Xu JG*
- 1379** Subtalar joint pigmented villonodular synovitis misdiagnosed at the first visit: A case report  
*Zhao WQ, Zhao B, Li WS, Assan I*
- 1386** Wilson disease — the impact of hyperimmunity on disease activity: A case report  
*Stremmel W, Longerich T, Liere R, Vacata V, van Helden J, Weiskirchen R*
- 1394** Unexplained elevation of erythrocyte sedimentation rate in a patient recovering from COVID-19: A case report  
*Pu SL, Zhang XY, Liu DS, Ye BN, Li JQ*
- 1402** Thoracic pyogenic infectious spondylitis presented as pneumothorax: A case report  
*Cho MK, Lee BJ, Chang JH, Kim YM*
- 1408** Unilateral pulmonary hemorrhage caused by negative pressure pulmonary edema: A case report  
*Park HJ, Park SH, Woo UT, Cho SY, Jeon WJ, Shin WJ*
- 1416** Osseous Rosai-Dorfman disease of tibia in children: A case report  
*Vithran DTA, Wang JZ, Xiang F, Wen J, Xiao S, Tang WZ, Chen Q*
- 1424** Abdominopelvic leiomyoma with large ascites: A case report and review of the literature  
*Wang YW, Fan Q, Qian ZX, Wang JJ, Li YH, Wang YD*
- 1433** Unusual presentation of granulomatosis with polyangiitis causing periaortitis and consequent subclavian steal syndrome: A case report  
*Cho U, Kim SK, Ko JM, Yoo J*
- 1439** Postoperative discal pseudocyst and its similarities to discal cyst: A case report  
*Fu CF, Tian ZS, Yao LY, Yao JH, Jin YZ, Liu Y, Wang YY*

- 1446** Treatment of oral lichen planus by surgical excision and acellular dermal matrix grafting: Eleven case reports and review of literature  
*Fu ZZ, Chen LQ, Xu YX, Yue J, Ding Q, Xiao WL*
- 1455** Nonalcoholic fatty liver disease as a risk factor for cytomegalovirus hepatitis in an immunocompetent patient: A case report  
*Khiatah B, Nasrollah L, Covington S, Carlson D*
- 1461** Early reoccurrence of traumatic posterior atlantoaxial dislocation without fracture: A case report  
*Sun YH, Wang L, Ren JT, Wang SX, Jiao ZD, Fang J*
- 1469** Intrahepatic cholangiocarcinoma is more complex than we thought: A case report  
*Zeng JT, Zhang JF, Wang Y, Qing Z, Luo ZH, Zhang YL, Zhang Y, Luo XZ*
- 1475** Congenital hepatic fibrosis in a young boy with congenital hypothyroidism: A case report  
*Xiao FF, Wang YZ, Dong F, Li XL, Zhang T*
- 1483** Polidocanol sclerotherapy for multiple gastrointestinal hemangiomas: A case report  
*Yao H, Xie YX, Guo JY, Wu HC, Xie R, Shi GQ*
- 1490** Gastrointestinal stromal tumor with multisegmental spinal metastases as first presentation: A case report and review of the literature  
*Kong Y, Ma XW, Zhang QQ, Zhao Y, Feng HL*

**ABOUT COVER**

Editorial Board Member of *World Journal of Clinical Cases*, Dr. Quach is an Associate Professor of Gastroenterology at the University of Medicine and Pharmacy at Hochiminh City, Viet Nam, where he received his MD in 1997 and his PhD in 2011. Dr. Quach has published more than 100 reviews and original papers in local and international journals. He has received several awards, including Outstanding Presentation at the Biannual Scientific Congress of Vietnamese Nationwide Medical Schools, Medal of Creativeness from the Vietnamese Central Youth League, etc. Currently, he serves as a Vice President of the Vietnam Association of Gastroenterology and Secretary General of the Vietnam Federation for Digestive Endoscopy. (L-Editor: Filipodia)

**AIMS AND SCOPE**

The primary aim of *World Journal of Clinical Cases* (*WJCC*, *World J Clin Cases*) is to provide scholars and readers from various fields of clinical medicine with a platform to publish high-quality clinical research articles and communicate their research findings online.

*WJCC* mainly publishes articles reporting research results and findings obtained in the field of clinical medicine and covering a wide range of topics, including case control studies, retrospective cohort studies, retrospective studies, clinical trials studies, observational studies, prospective studies, randomized controlled trials, randomized clinical trials, systematic reviews, meta-analysis, and case reports.

**INDEXING/ABSTRACTING**

The *WJCC* is now indexed in Science Citation Index Expanded (also known as SciSearch®), Journal Citation Reports/Science Edition, Scopus, PubMed, and PubMed Central. The 2020 Edition of Journal Citation Reports® cites the 2019 impact factor (IF) for *WJCC* as 1.013; IF without journal self cites: 0.991; Ranking: 120 among 165 journals in medicine, general and internal; and Quartile category: Q3. The *WJCC*'s CiteScore for 2019 is 0.3 and Scopus CiteScore rank 2019: General Medicine is 394/529.

**RESPONSIBLE EDITORS FOR THIS ISSUE**

Production Editor: Ji-Hong Lin; Production Department Director: Xiang Li; Editorial Office Director: Jin-Lai Wang.

**NAME OF JOURNAL**

*World Journal of Clinical Cases*

**ISSN**

ISSN 2307-8960 (online)

**LAUNCH DATE**

April 16, 2013

**FREQUENCY**

Thrice Monthly

**EDITORS-IN-CHIEF**

Dennis A Bloomfield, Sandro Vento, Bao-Gan Peng

**EDITORIAL BOARD MEMBERS**

<https://www.wjgnet.com/2307-8960/editorialboard.htm>

**PUBLICATION DATE**

February 26, 2021

**COPYRIGHT**

© 2021 Baishideng Publishing Group Inc

**INSTRUCTIONS TO AUTHORS**

<https://www.wjgnet.com/bpg/gerinfo/204>

**GUIDELINES FOR ETHICS DOCUMENTS**

<https://www.wjgnet.com/bpg/GerInfo/287>

**GUIDELINES FOR NON-NATIVE SPEAKERS OF ENGLISH**

<https://www.wjgnet.com/bpg/gerinfo/240>

**PUBLICATION ETHICS**

<https://www.wjgnet.com/bpg/GerInfo/288>

**PUBLICATION MISCONDUCT**

<https://www.wjgnet.com/bpg/gerinfo/208>

**ARTICLE PROCESSING CHARGE**

<https://www.wjgnet.com/bpg/gerinfo/242>

**STEPS FOR SUBMITTING MANUSCRIPTS**

<https://www.wjgnet.com/bpg/GerInfo/239>

**ONLINE SUBMISSION**

<https://www.f6publishing.com>



## Intrahepatic cholangiocarcinoma is more complex than we thought: A case report

Jian-Ting Zeng, Jie-Feng Zhang, Yu Wang, Zhou Qing, Zhen-Hua Luo, Yan-Lin Zhang, Yi Zhang, Xian-Zhang Luo

**ORCID number:** Jian-Ting Zeng 0000-0001-7010-4372; Jie-Feng Zhang 0000-0001-7010-3142; Yu Wang 0000-0002-2398-8336; Zhou Qing 0000-0002-0586-345X; Zhen-Hua Luo 0000-0002-0947-4910; Yan-Lin Zhang 0000-0001-6522-8274; Yi Zhang 0000-0002-1334-6719; Xian-Zhang Luo 0000-0002-5629-8163.

**Author contributions:** Zhang JF was the patient's surgeon; Qing Z and Luo ZH conducted research on the concept and design; Luo XZ and Zeng JT drafted the manuscript; Wang Y and Zhang YL critically revised the manuscript for important intellectual content; Zhang Y supervised the study; All authors approved the final manuscript.

**Informed consent statement:** Informed written consent was obtained from the patient for publication of this report and any accompanying images.

**Conflict-of-interest statement:** The authors declare that they have no conflict of interest.

**CARE Checklist (2016) statement:** The authors have read the CARE Checklist (2016), and the manuscript was prepared and revised according to the CARE Checklist (2016).

**Jian-Ting Zeng, Zhou Qing, Zhen-Hua Luo, Yan-Lin Zhang, Yi Zhang, Xian-Zhang Luo,** Key Laboratory for Biorheological Science and Technology of Ministry of Education, Chongqing University, Chongqing University Cancer Hospital, Chongqing 400030, China

**Jie-Feng Zhang, Yu Wang,** Chongqing Key Laboratory of Translational Research for Cancer Metastasis and Individualized Treatment, Chongqing University Cancer Hospital, Chongqing 400030, China

**Corresponding author:** Xian-Zhang Luo, MD, Doctor, Key Laboratory for Biorheological Science and Technology of Ministry of Education, Chongqing University, Chongqing University Cancer Hospital, No. 181 Hanyu Road, Shapingba District, Chongqing 400030, China. [heroluoxz@sina.com](mailto:heroluoxz@sina.com)

### Abstract

#### BACKGROUND

Brain metastasis from intrahepatic cholangiocarcinoma is rare. To the best of our knowledge, only a few cases have been reported. The biological behavior was complex, and treatment requires further investigation.

#### CASE SUMMARY

A 62-year-old woman complained of left limb weakness. Abdominal computed tomography showed a 5.0 cm × 5.6 cm lesion in the left lobe of the liver. Tumor markers were normal. Serological analysis indicated absence of hepatitis virus. Brain magnetic resonance imaging revealed a 1.0 cm × 1.3 cm mass in the right frontal lobe. Intrahepatic cholangiocarcinoma with brain metastasis was diagnosed by our liver cancer multidisciplinary team. After sufficient preparation, the patient underwent partial frontal lobotomy and left hemihepatectomy. Histopathological results confirmed that both the lesions were cholangiocarcinoma. Six cycles of gemcitabine combined with S1 were administered. During a 39 mo postoperative follow-up, no sign of local recurrence or distant metastasis was observed.

#### CONCLUSION

This case expands our knowledge concerning the complex and heterogeneous nature of tumor metastasis.

**Key Words:** Intrahepatic cholangiocarcinoma; Brain metastasis; Multidisciplinary team;

**Open-Access:** This article is an open-access article that was selected by an in-house editor and fully peer-reviewed by external reviewers. It is distributed in accordance with the Creative Commons Attribution NonCommercial (CC BY-NC 4.0) license, which permits others to distribute, remix, adapt, build upon this work non-commercially, and license their derivative works on different terms, provided the original work is properly cited and the use is non-commercial. See: <http://creativecommons.org/licenses/by-nc/4.0/>

**Manuscript source:** Unsolicited manuscript

**Specialty type:** Medicine, research and experimental

**Country/Territory of origin:** China

**Peer-review report's scientific quality classification**

Grade A (Excellent): 0  
Grade B (Very good): 0  
Grade C (Good): C, C, C, C  
Grade D (Fair): 0  
Grade E (Poor): 0

**Received:** November 9, 2020

**Peer-review started:** November 9, 2020

**First decision:** December 3, 2020

**Revised:** December 15, 2020

**Accepted:** January 6, 2021

**Article in press:** January 6, 2021

**Published online:** February 26, 2021

**P-Reviewer:** Giorgio A, Tajiri K, Tarazov PG

**S-Editor:** Fan JR

**L-Editor:** Filipodia

**P-Editor:** Liu JH



Synchronous brain metastasis; Case report

©The Author(s) 2021. Published by Baishideng Publishing Group Inc. All rights reserved.

**Core Tip:** Intrahepatic cholangiocarcinoma is the second most common type of primary liver cancer, but metastasis to the brain is rare. Because of the low prevalence, the treatment and biological behavior are still unclear and require further study. In this work, we report a 62-year-old patient with intrahepatic cholangiocarcinoma with brain metastasis. Operation-based comprehensive treatment was recommended by our liver cancer multidisciplinary group. There was no local recurrence or distant metastasis after 39 mo of postoperative follow-up. We propose that each cancer patient should be treated regardless of disease stage, and a multidisciplinary team is important.

**Citation:** Zeng JT, Zhang JF, Wang Y, Qing Z, Luo ZH, Zhang YL, Zhang Y, Luo XZ. Intrahepatic cholangiocarcinoma is more complex than we thought: A case report. *World J Clin Cases* 2021; 9(6): 1469-1474

**URL:** <https://www.wjgnet.com/2307-8960/full/v9/i6/1469.htm>

**DOI:** <https://dx.doi.org/10.12998/wjcc.v9.i6.1469>

## INTRODUCTION

Intrahepatic cholangiocarcinoma (ICC) is the second most common type of primary liver cancer. However, metastasis to the brain is rare, and no more than 40 cases have been described in the literature to date. Because of the low prevalence, the treatment and biological behavior are still unclear and require further study. Here, we report the first case of ICC with synchronous brain metastasis successfully managed by surgery-based comprehensive treatment.

## CASE PRESENTATION

### Chief complaints

A 62-year-old woman was referred to Chongqing Cancer hospital due to left limb weakness for 2 wk.

### History of present illness

Patient's symptoms started 2 wk ago and worsened in the first 48 h.

### Personal and family history

She denied a history of smoking and alcohol abuse.

### Physical examination

There was no positive sign on physical examination except for decreased muscle power in the left limb (left upper limb muscle power was level 3, and left lower limb muscle power was level 4).

### Laboratory examinations

Routine blood analysis and liver function were normal. Her  $\alpha$ -fetoprotein level was 1.3 ng/mL (range: 0-8.1 ng/mL), carcinoembryonic antigen was 1.27 ng/mL (range: 1.00-5.00 ng/mL), and carbohydrate antigen 19-9 was 10.76 U/mL (normal range: 0-30.90 U/mL).

### Imaging examinations

Chest computed tomography showed no abnormality. Contrast enhanced abdominal computed tomography showed a 5.0 cm  $\times$  5.6 cm lesion located in the left lateral lobe of the liver. The lesion had low density in unenhanced phase, slightly higher density during arterial phase and higher density enhanced in portal venous phase



(Figure 1A–C). Brain magnetic resonance imaging revealed a 1.3 cm × 1.0 cm mass in the right frontal lobe (Figure 1D–F), and the lesion had hyperintensity in T1 image and hypointensity in T2 image. There was an obvious edema zone around the lesion. No tumor was found by esophagogastroduodenoscopy and colonoscopy. Because the liver lesions had an unknown etiology, an 18G needle biopsy was performed. Histopathological results showed that the lesion had the feature of ICC.

## MULTIDISCIPLINARY EXPERT CONSULTATION

ICC with brain metastasis was diagnosed by our liver cancer multidisciplinary team (MDT), and surgery-based comprehensive treatment was recommended.

## FINAL DIAGNOSIS

Histopathological results showed that both the lesions from the brain (Figure 2A and 2B) and the liver (Figure 2C and D) were abundant in eosinophils with large vesicular nuclei and positive immunohistochemical staining for cytokeratin 8/18 and cytokeratin 19 and negative results for thyroid transcription factor-1. Cytokeratin 20 negative results are helpful for correct diagnosis. Diagnosis of ICC with brain metastasis was then made.

## TREATMENT

After sufficient preparation, the patient underwent partial frontal lobotomy, and left hemihepatectomy was performed 9 d later. Six cycles of chemotherapy with gemcitabine combined with S1 were administered.

## OUTCOME AND FOLLOW-UP

She recovered with an uneventful postoperative course. There was no local recurrence or distant metastasis after 39 mo of postoperative follow-up.

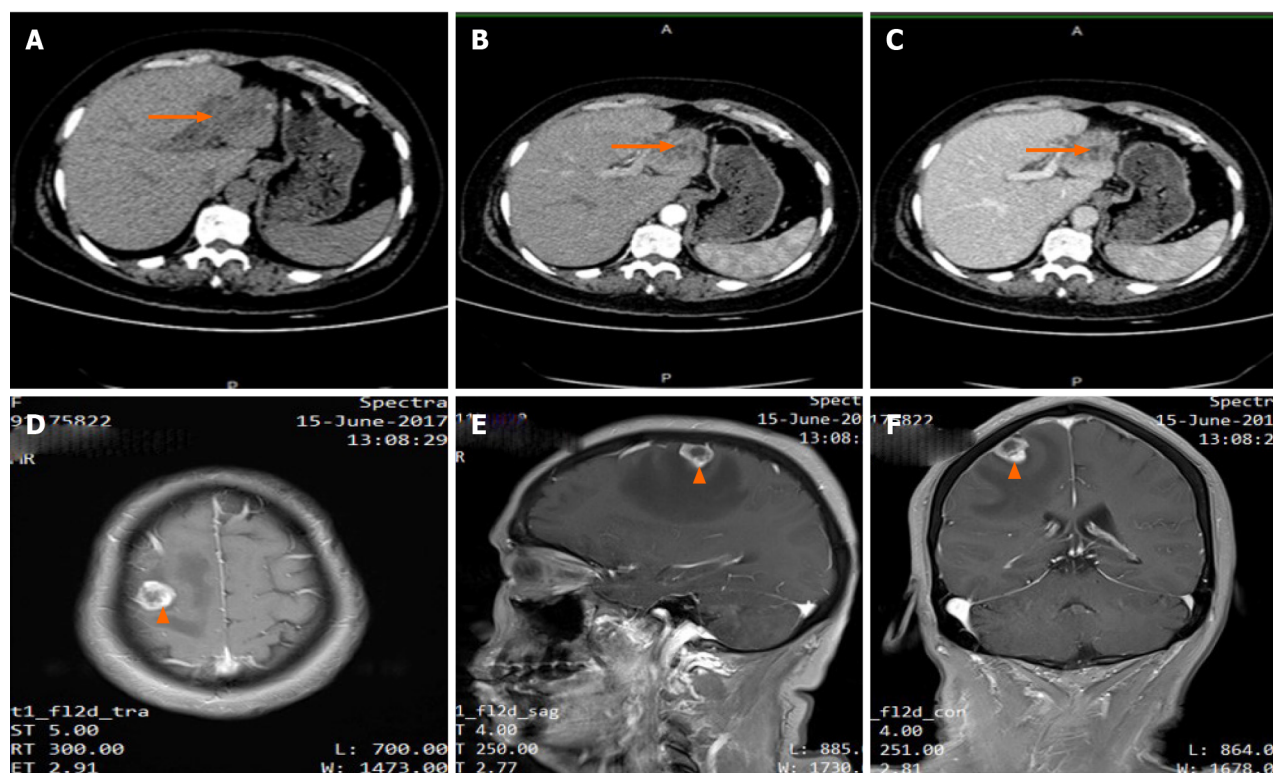
## DISCUSSION

ICC is the second most common type of primary liver cancer. The overall incidence of ICC has increased over the past few decades<sup>[1–3]</sup>; however, the survival rate at 5 yrs after diagnosis has not increased during this time<sup>[4]</sup>. Most patients have lost the opportunity for complete resection, which is deemed to be the most effective treatment. Moreover, recurrence is found in about 71% of patients undergoing curative resection. Meanwhile, extrahepatic metastases are seen in almost 40% of cases<sup>[5]</sup>. The most common sites for metastases are liver, lung and bone<sup>[6]</sup>.

Brain metastasis from ICC is rare, and no more than 40 cases have been described in the literature to date<sup>[7]</sup>. Metastatic lesions decrease survival time and quality of life<sup>[7–9]</sup>, although Yan *et al.*<sup>[6]</sup> reported that surgical resection for liver and lung metastases improved survival outcomes<sup>[6]</sup>. There is no standard therapy for brain metastasis due to the rareness of the disease. In the present case, the patient was admitted to the hospital due to compression symptoms caused by the metastatic lesion. ICC with brain metastasis was diagnosed after examination.

Surgery-based comprehensive treatment was recommended by our liver cancer MDT for the following reasons. First, there was an opportunity for complete resection of both the primary and metastatic lesions, and no lymph node metastasis was found, which is strongly associated with surgical prognosis<sup>[10]</sup>. Second, brain radiotherapy may exacerbate compression symptoms, and the primary liver lesion may progress during therapy. Third, chemotherapeutic drugs may not cross the blood–brain barrier; additionally, there are reports that resection of brain metastatic lesions from ICC did improve survival time<sup>[7]</sup>. However, there are no reports about simultaneously or staged resection of primary and synchronous metastatic lesions, and if staged, which lesion is resected first. We resected the metastatic lesion first because the compression





**Figure 1** Imaging results of the lesions (Liver: A-C; Brain: D-F). Abdominal computed tomography showed a mass in the left lobe of the liver (arrow). A: Low density lesions located in the left lateral lobe in unenhanced phase; B: Lesions washed-in and enhanced during hepatic arterial phase; C: Lesions enhanced in portal venous phase. Contrast-enhanced T1-weighted magnetic resonance imaging demonstrated a single brain metastasis in the right frontal lobe (arrow); D: Axial view; E: Sagittal view; F: Coronal view.

symptom was more serious, and simultaneous resection had a higher surgical risk.

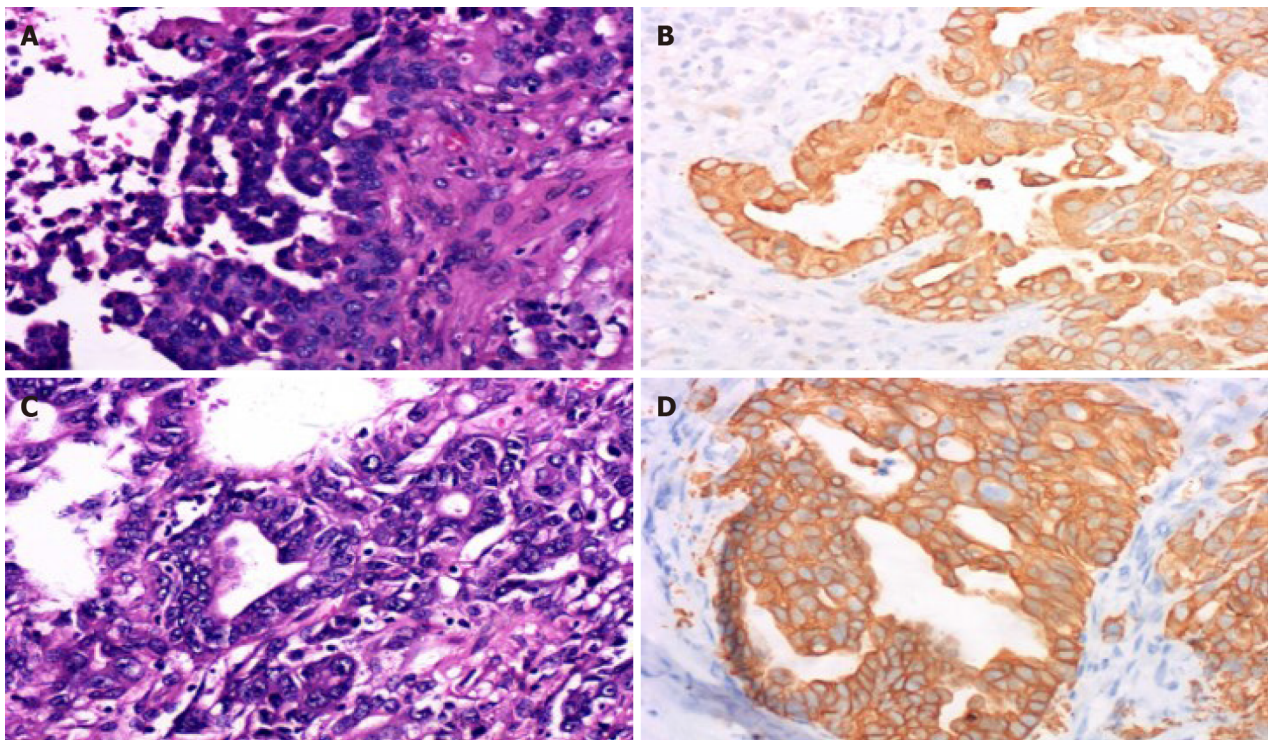
Our patient recovered well after both brain and liver surgery. Histopathological examination confirmed our preoperative diagnosis. Then combination chemotherapy with gemcitabine and S1 was given because the patient had distant metastasis. After comprehensive treatment, the patient achieved 39 mo disease-free survival.

Some unique characteristics should be noted in this case. First, to our knowledge this is the first report of complete resection of a liver lesion and synchronous brain metastatic lesion in ICC. Second, the patient was diagnosed with an advanced stage IV tumor. Surgery-based comprehensive treatment given by our MDT achieved long-term disease-free survival. We propose that each cancer patient should be treated regardless of disease stage, and an MDT is important. Third, there was no lymph node metastasis at the time of diagnosis. This observation reflects the complexity and heterogeneity of the disease. Due to the rare occurrence of the brain metastasis from ICC, an international sample library, which needs global cooperation of the relevant institutions, will help to unravel the complex pathogenesis using omics- and system-based methodologies and further clarify the underlying mechanism behind it.

However, the current results may be limited by the retrospective nature of this study, the mechanism of brain metastasis is unclear, and it is also unclear which patients will benefit from surgery. Thus, data on more cases should be continuously collected.

## CONCLUSION

This is believed to be the first report of ICC with synchronous brain metastasis successfully managed by surgery-based comprehensive treatment. Its unique characteristics associated with treatment and tumor development contribute to understanding the tumor.



**Figure 2 Pathological results of the lesions.** A: Hematoxylin and eosin-stained section of the brain lesion showing abundant eosinophils with large vesicular nuclei and clear cytoplasm ( $\times 400$ ); B: Immunohistochemical staining was positive for cytokeratin 19 ( $\times 400$ ) in the brain tumor cells, which indicated metastasis of intrahepatic cholangiocarcinoma; C and D: These findings of the liver lesions were similar to those of the intrahepatic cholangiocarcinoma pathological specimen obtained by hepatectomy ( $\times 400$ ).

## REFERENCES

- 1 **Patel T.** Worldwide trends in mortality from biliary tract malignancies. *BMC Cancer* 2002; **2**: 10 [PMID: [11991810](#) DOI: [10.1186/1471-2407-2-10](#)]
- 2 **Khan SA, Taylor-Robinson SD, Toledano MB, Beck A, Elliott P, Thomas HC.** Changing international trends in mortality rates for liver, biliary and pancreatic tumours. *J Hepatol* 2002; **37**: 806-813 [PMID: [12445422](#) DOI: [10.1016/s0168-8278\(02\)00297-0](#)]
- 3 **Antwi SO, Mousa OY, Patel T.** Racial, Ethnic, and Age Disparities in Incidence and Survival of Intrahepatic Cholangiocarcinoma in the United States; 1995-2014. *Ann Hepatol* 2018; **17**: 604-614 [PMID: [29893702](#) DOI: [10.5604/01.3001.0012.0929](#)]
- 4 **Farges O, Fuks D, Le Treut YP, Azoulay D, Laurent A, Bachellier P, Nuzzo G, Belghiti J, Pruvot FR, Regimbeau JM.** AJCC 7th edition of TNM staging accurately discriminates outcomes of patients with resectable intrahepatic cholangiocarcinoma: By the AFC-IHCC-2009 study group. *Cancer* 2011; **117**: 2170-2177 [PMID: [21523730](#) DOI: [10.1002/cncr.25712](#)]
- 5 **Spolverato G, Kim Y, Alexandrescu S, Marques HP, Lamelas J, Aldrighetti L, Clark Gamblin T, Maithel SK, Pulitano C, Bauer TW, Shen F, Poultides GA, Tran TB, Wallis Marsh J, Pawlik TM.** Management and Outcomes of Patients with Recurrent Intrahepatic Cholangiocarcinoma Following Previous Curative-Intent Surgical Resection. *Ann Surg Oncol* 2016; **23**: 235-243 [PMID: [26059651](#) DOI: [10.1245/s10434-015-4642-9](#)]
- 6 **Yan X, Wang P, Zhu Z, Ning Z, Xu L, Zhuang L, Sheng J, Meng Z.** Site-specific metastases of intrahepatic cholangiocarcinoma and its impact on survival: a population-based study. *Future Oncol* 2019; **15**: 2125-2137 [PMID: [31161810](#) DOI: [10.2217/fon-2018-0846](#)]
- 7 **Novegno F, Umana G, Granaroli P, Borri F, Orlandi A, Lunardi P.** Current management of central nervous system metastasis from cholangiocarcinoma: the neurosurgical perspective. Literature review. *Br J Neurosurg* 2020; **34**: 575-583 [PMID: [31304799](#) DOI: [10.1080/02688697.2019.1639614](#)]
- 8 **Chindaprasirt J, Sookprasert A, Sawanyawisuth K, Limpawattana P, Tiamkao S.** Brain metastases from cholangiocarcinoma: a first case series in Thailand. *Asian Pac J Cancer Prev* 2012; **13**: 1995-1997 [PMID: [22901160](#) DOI: [10.7314/apjcp.2012.13.5.1995](#)]
- 9 **Frega G, Garajová I, Palloni A, Barbera MA, Trossello Pastore M, Faccioli L, Spinardi L, De Lorenzo S, Cubelli M, Pantaleo MA, Biasco G, Brandi G.** Brain Metastases from Biliary Tract Cancer: A Monocentric Retrospective Analysis of 450 Patients. *Oncology* 2018; **94**: 7-11 [PMID: [29024931](#) DOI: [10.1159/000479929](#)]
- 10 **de Jong MC, Nathan H, Sotiropoulos GC, Paul A, Alexandrescu S, Marques H, Pulitano C, Barroso E, Clary BM, Aldrighetti L, Ferrone CR, Zhu AX, Bauer TW, Walters DM, Gamblin TC, Nguyen KT, Turley R, Popescu I, Hubert C, Meyer S, Schulick RD, Choti MA, Gigot JF, Mentha G, Pawlik**

TM. Intrahepatic cholangiocarcinoma: an international multi-institutional analysis of prognostic factors and lymph node assessment. *J Clin Oncol* 2011; **29**: 3140-3145 [PMID: [21730269](#) DOI: [10.1200/JCO.2011.35.6519](#)]



Published by **Baishideng Publishing Group Inc**  
7041 Koll Center Parkway, Suite 160, Pleasanton, CA 94566, USA

**Telephone:** +1-925-3991568

**E-mail:** [bpgoffice@wjgnet.com](mailto:bpgoffice@wjgnet.com)

**Help Desk:** <https://www.f6publishing.com/helpdesk>

<https://www.wjgnet.com>

