

World Journal of *Clinical Cases*

World J Clin Cases 2021 February 26; 9(6): 1247-1498



Contents

Thrice Monthly Volume 9 Number 6 February 26, 2021

EDITORIAL

- 1247 Interactive platform for peer review: A proposal to improve the current peer review system
Emile SH

MINIREVIEWS

- 1251 Animal models of cathartic colon
Meng YY, Li QD, Feng Y, Liu J, Wang EK, Zhong L, Sun QL, Yuan JY

ORIGINAL ARTICLE

Case Control Study

- 1259 New indicators in evaluation of hemolysis, elevated liver enzymes, and low platelet syndrome: A case-control study
Kang SY, Wang Y, Zhou LP, Zhang H

Retrospective Study

- 1271 Analysis of hospitalization costs related to fall injuries in elderly patients
Su FY, Fu ML, Zhao QH, Huang HH, Luo D, Xiao MZ
- 1284 Effect of alprostadil in the treatment of intensive care unit patients with acute renal injury
Jia Y, Liu LL, Su JL, Meng XH, Wang WX, Tian C

Clinical Trials Study

- 1293 Etomidate *vs* propofol in coronary heart disease patients undergoing major noncardiac surgery: A randomized clinical trial
Dai ZL, Cai XT, Gao WL, Lin M, Lin J, Jiang YX, Jiang X

Observational Study

- 1304 Healthy individuals *vs* patients with bipolar or unipolar depression in gray matter volume
Zhang YN, Li H, Shen ZW, Xu C, Huang YJ, Wu RH
- 1318 Impact of metabolism-related mutations on the heart rate of gastric cancer patients after peritoneal lavage
Yuan Y, Yao S, Luo GH, Zhang XY

CASE REPORT

- 1329 Efficacy of afatinib in a patient with rare EGFR (G724S/R776H) mutations and amplification in lung adenocarcinoma: A case report
He SY, Lin QF, Chen J, Yu GP, Zhang JL, Shen D

- 1336** Esophageal superficial adenosquamous carcinoma resected by endoscopic submucosal dissection: A rare case report
Liu GY, Zhang JX, Rong L, Nian WD, Nian BX, Tian Y
- 1343** Do medullary thyroid carcinoma patients with high calcitonin require bilateral neck lymph node clearance? A case report
Gan FJ, Zhou T, Wu S, Xu MX, Sun SH
- 1353** Femoral epithelioid hemangioendothelioma detected with magnetic resonance imaging and positron emission tomography/computed tomography: A case report
Zhao HG, Zhang KW, Hou S, Dai YY, Xu SB
- 1359** Noninvasive tools based on immune biomarkers for the diagnosis of central nervous system graft-vs-host disease: Two case reports and a review of the literature
Lyu HR, He XY, Hao HJ, Lu WY, Jin X, Zhao YJ, Zhao MF
- 1367** Periodontally accelerated osteogenic orthodontics with platelet-rich fibrin in an adult patient with periodontal disease: A case report and review of literature
Xu M, Sun XY, Xu JG
- 1379** Subtalar joint pigmented villonodular synovitis misdiagnosed at the first visit: A case report
Zhao WQ, Zhao B, Li WS, Assan I
- 1386** Wilson disease — the impact of hyperimmunity on disease activity: A case report
Stremmel W, Longerich T, Liere R, Vacata V, van Helden J, Weiskirchen R
- 1394** Unexplained elevation of erythrocyte sedimentation rate in a patient recovering from COVID-19: A case report
Pu SL, Zhang XY, Liu DS, Ye BN, Li JQ
- 1402** Thoracic pyogenic infectious spondylitis presented as pneumothorax: A case report
Cho MK, Lee BJ, Chang JH, Kim YM
- 1408** Unilateral pulmonary hemorrhage caused by negative pressure pulmonary edema: A case report
Park HJ, Park SH, Woo UT, Cho SY, Jeon WJ, Shin WJ
- 1416** Osseous Rosai-Dorfman disease of tibia in children: A case report
Vithran DTA, Wang JZ, Xiang F, Wen J, Xiao S, Tang WZ, Chen Q
- 1424** Abdominopelvic leiomyoma with large ascites: A case report and review of the literature
Wang YW, Fan Q, Qian ZX, Wang JJ, Li YH, Wang YD
- 1433** Unusual presentation of granulomatosis with polyangiitis causing periaortitis and consequent subclavian steal syndrome: A case report
Cho U, Kim SK, Ko JM, Yoo J
- 1439** Postoperative discal pseudocyst and its similarities to discal cyst: A case report
Fu CF, Tian ZS, Yao LY, Yao JH, Jin YZ, Liu Y, Wang YY

- 1446** Treatment of oral lichen planus by surgical excision and acellular dermal matrix grafting: Eleven case reports and review of literature
Fu ZZ, Chen LQ, Xu YX, Yue J, Ding Q, Xiao WL
- 1455** Nonalcoholic fatty liver disease as a risk factor for cytomegalovirus hepatitis in an immunocompetent patient: A case report
Khiatah B, Nasrollah L, Covington S, Carlson D
- 1461** Early reoccurrence of traumatic posterior atlantoaxial dislocation without fracture: A case report
Sun YH, Wang L, Ren JT, Wang SX, Jiao ZD, Fang J
- 1469** Intrahepatic cholangiocarcinoma is more complex than we thought: A case report
Zeng JT, Zhang JF, Wang Y, Qing Z, Luo ZH, Zhang YL, Zhang Y, Luo XZ
- 1475** Congenital hepatic fibrosis in a young boy with congenital hypothyroidism: A case report
Xiao FF, Wang YZ, Dong F, Li XL, Zhang T
- 1483** Polidocanol sclerotherapy for multiple gastrointestinal hemangiomas: A case report
Yao H, Xie YX, Guo JY, Wu HC, Xie R, Shi GQ
- 1490** Gastrointestinal stromal tumor with multisegmental spinal metastases as first presentation: A case report and review of the literature
Kong Y, Ma XW, Zhang QQ, Zhao Y, Feng HL

ABOUT COVER

Editorial Board Member of *World Journal of Clinical Cases*, Dr. Quach is an Associate Professor of Gastroenterology at the University of Medicine and Pharmacy at Hochiminh City, Viet Nam, where he received his MD in 1997 and his PhD in 2011. Dr. Quach has published more than 100 reviews and original papers in local and international journals. He has received several awards, including Outstanding Presentation at the Biannual Scientific Congress of Vietnamese Nationwide Medical Schools, Medal of Creativeness from the Vietnamese Central Youth League, etc. Currently, he serves as a Vice President of the Vietnam Association of Gastroenterology and Secretary General of the Vietnam Federation for Digestive Endoscopy. (L-Editor: Filipodia)

AIMS AND SCOPE

The primary aim of *World Journal of Clinical Cases* (*WJCC*, *World J Clin Cases*) is to provide scholars and readers from various fields of clinical medicine with a platform to publish high-quality clinical research articles and communicate their research findings online.

WJCC mainly publishes articles reporting research results and findings obtained in the field of clinical medicine and covering a wide range of topics, including case control studies, retrospective cohort studies, retrospective studies, clinical trials studies, observational studies, prospective studies, randomized controlled trials, randomized clinical trials, systematic reviews, meta-analysis, and case reports.

INDEXING/ABSTRACTING

The *WJCC* is now indexed in Science Citation Index Expanded (also known as SciSearch®), Journal Citation Reports/Science Edition, Scopus, PubMed, and PubMed Central. The 2020 Edition of Journal Citation Reports® cites the 2019 impact factor (IF) for *WJCC* as 1.013; IF without journal self cites: 0.991; Ranking: 120 among 165 journals in medicine, general and internal; and Quartile category: Q3. The *WJCC*'s CiteScore for 2019 is 0.3 and Scopus CiteScore rank 2019: General Medicine is 394/529.

RESPONSIBLE EDITORS FOR THIS ISSUE

Production Editor: Ji-Hong Lin; Production Department Director: Xiang Li; Editorial Office Director: Jin-Lai Wang.

NAME OF JOURNAL

World Journal of Clinical Cases

ISSN

ISSN 2307-8960 (online)

LAUNCH DATE

April 16, 2013

FREQUENCY

Thrice Monthly

EDITORS-IN-CHIEF

Dennis A Bloomfield, Sandro Vento, Bao-Gan Peng

EDITORIAL BOARD MEMBERS

<https://www.wjgnet.com/2307-8960/editorialboard.htm>

PUBLICATION DATE

February 26, 2021

COPYRIGHT

© 2021 Baishideng Publishing Group Inc

INSTRUCTIONS TO AUTHORS

<https://www.wjgnet.com/bpg/gerinfo/204>

GUIDELINES FOR ETHICS DOCUMENTS

<https://www.wjgnet.com/bpg/GerInfo/287>

GUIDELINES FOR NON-NATIVE SPEAKERS OF ENGLISH

<https://www.wjgnet.com/bpg/gerinfo/240>

PUBLICATION ETHICS

<https://www.wjgnet.com/bpg/GerInfo/288>

PUBLICATION MISCONDUCT

<https://www.wjgnet.com/bpg/gerinfo/208>

ARTICLE PROCESSING CHARGE

<https://www.wjgnet.com/bpg/gerinfo/242>

STEPS FOR SUBMITTING MANUSCRIPTS

<https://www.wjgnet.com/bpg/GerInfo/239>

ONLINE SUBMISSION

<https://www.f6publishing.com>



Polidocanol sclerotherapy for multiple gastrointestinal hemangiomas: A case report

Huan Yao, Yu-Xin Xie, Jian-Yi Guo, Hui-Chao Wu, Rui Xie, Guo-Qing Shi

ORCID number: Huan Yao 0000-0002-4066-2311; Yu-Xin Xie 0000-0002-8924-4719; Jian-Yi Guo 0000-0002-0667-4319; Hui-Chao Wu 0000-0003-0740-5273; Rui Xie 0000-0001-7970-5916; Guo-Qing Shi 0000-0003-3597-8255.

Author contributions: Yao H and Xie YX contributed equally to this article; Yao H wrote the paper; Guo JY collected the case data; Shi GQ performed the endoscopic examination and treatment; Wu HC performed endoscopic ultrasound; Xie R revised the paper.

Informed consent statement: Informed written consent was obtained from the patient for publication of this report and any accompanying images.

Conflict-of-interest statement: The authors declare that they have no conflict of interest to report.

CARE Checklist (2016) statement: The authors have read the CARE Checklist (2016), and the manuscript was prepared and revised according to the CARE Checklist (2016).

Open-Access: This article is an open-access article that was selected by an in-house editor and fully peer-reviewed by external reviewers. It is distributed in

Huan Yao, Yu-Xin Xie, Jian-Yi Guo, Hui-Chao Wu, Rui Xie, Guo-Qing Shi, Department of Gastroenterology, Affiliated Hospital of Zunyi Medical University, Zunyi 563003, Guizhou Province, China

Corresponding author: Guo-Qing Shi, Doctor, Professor, Department of Gastroenterology, Affiliated Hospital of Zunyi Medical University, No. 149 Dalian Road, Zunyi 563003, Guizhou Province, China. sgqing973@sina.com

Abstract

BACKGROUND

Gastrointestinal (GI) hemangioma has a low incidence among systemic hemangiomas, and some GI hemangiomas occur in the intestine, stomach, and esophagus. Polidocanol has been increasingly used in sclerotherapy. However, this paper reports that minimally invasive treatment of multiple hemangiomas with large diameters can achieve satisfactory results by multipoint injection.

CASE SUMMARY

A 46-year-old female patient was hospitalized in another hospital for cough. We accidentally found thickening of the lower esophagus by chest computed tomography. The patient was eventually diagnosed with multiple GI hemangiomas and underwent a series of examinations including esophago-gastroduodenoscopy (EGD), endoscopic ultrasound, and magnetic resonance imaging. We calculated the dose of polidocanol according to the volumes of the hemangiomas, fixed the target vein with the help of a transparent cap, and then administered polidocanol *via* multipoint injection into the hemangiomas under endoscopic guidance. EGD and endoscopic ultrasound showed that the hemangiomas disappeared. The color of the esophageal mucosa returned to normal 1 mo after sclerotherapy.

CONCLUSION

Sclerotherapy may be a safe and effective method for treating multiple hemangiomas of the alimentary canal.

Key Words: Hemangioma; Polidocanol; Sclerotherapy; Stomach; Esophagus; Case report

©The Author(s) 2021. Published by Baishideng Publishing Group Inc. All rights reserved.

accordance with the Creative Commons Attribution NonCommercial (CC BY-NC 4.0) license, which permits others to distribute, remix, adapt, build upon this work non-commercially, and license their derivative works on different terms, provided the original work is properly cited and the use is non-commercial. See: <http://creativecommons.org/licenses/by-nc/4.0/>

Manuscript source: Unsolicited manuscript

Specialty type: Medicine, research and experimental

Country/Territory of origin: China

Peer-review report's scientific quality classification

Grade A (Excellent): 0
Grade B (Very good): 0
Grade C (Good): C, C
Grade D (Fair): 0
Grade E (Poor): 0

Received: November 14, 2020

Peer-review started: November 14, 2020

First decision: December 3, 2020

Revised: December 16, 2020

Accepted: December 27, 2020

Article in press: December 27, 2020

Published online: February 26, 2021

P-Reviewer: Gallo G

S-Editor: Gao CC

L-Editor: Wang TQ

P-Editor: Liu JH



Core Tip: Multiple gastrointestinal (GI) hemangiomas are rare in clinical practice, and the current treatment method for larger GI hemangiomas is surgery. In this case, multipoint injection of polidocanol was used to treat gastroesophageal hemangiomas. We used a reasonable dose of polidocanol and applied the treatment using a transparent cap. This sclerotherapy method successfully treated a patient with multiple hemangiomas without any complications.

Citation: Yao H, Xie YX, Guo JY, Wu HC, Xie R, Shi GQ. Polidocanol sclerotherapy for multiple gastrointestinal hemangiomas: A case report. *World J Clin Cases* 2021; 9(6): 1483-1489

URL: <https://www.wjgnet.com/2307-8960/full/v9/i6/1483.htm>

DOI: <https://dx.doi.org/10.12998/wjcc.v9.i6.1483>

INTRODUCTION

Hemangiomas can occur in various organs of the body. The incidence of oral and maxillofacial hemangioma accounts for 60% of the incidence of systemic hemangioma, followed by trunk hemangioma (25%) and limb hemangioma (15%). Gastrointestinal (GI) hemangioma is a rare benign vascular neoplasm and might be associated with congenital disorders such as Osler-Weber-Rendu disease, Maffucci's syndrome, or the congenital blue rubber bleb nevus syndrome^[1]. The main treatment for larger GI hemangioma is surgery. However, there are some disadvantages of surgical removal of GI hemangiomas, such as considerable trauma, long recovery period, and pain. Polidocanol injection sclerotherapy has been successfully applied for the treatment of cutaneous hemangiomas^[2] and venous malformations^[3]. In the treatment of GI hemangiomas, esophageal varices sclerotherapy, internal hemorrhoid sclerotherapy, and intestinal hemangioma sclerotherapy have been reported^[4-6]. In a case of using sclerotherapy to control bleeding, it was mentioned that sclerotherapy with 3% polidocanol foam induces an inflammatory reaction with sclerosis of the submucosal tissue and consequent suspension of the hemorrhoidal tissue^[7]. Markovic *et al*^[8] reported that sclerotherapy in the treatment of low flow vascular malformations did not significantly change hemodynamic consequences and reduce complications. However, endoscopic multipoint injection of polidocanol is rarely reported in the treatment of larger cavernous hemangiomas of the digestive tract. Previous reports showed that most of hemangiomas larger than 3 cm in diameter are treated by surgical treatment. We report a rare case of multiple GI hemangiomas with multiple cavities. Satisfactory treatment results have been achieved by using multi-point sclerotherapy.

CASE PRESENTATION

Chief complaints

A 46-year-old woman was admitted to our hospital because of cough and intermittent swallowing discomfort.

History of present illness

The patient was hospitalized because of dysphagia in another hospital. Computed tomography (CT) examination showed that the lower esophagus was thickened. In order to get better treatment, the patient came to our hospital on July 8, 2019.

History of past illness

She had a previous history of thyroid sarcoidosis but did not receive treatment.

Personal and family history

The patient had no significant family history.

Physical examination

On examination, the vital signs were normal with a respiratory rate of 20/min, heart

rate of 89/min, and blood pressure of 98/62 mmHg.

Laboratory examinations

The patient's biochemical indicators were normal.

Imaging examinations

T2-weighted magnetic resonance imaging (MRI) showed hyperintensity of the lower esophagus and the cardia, no abnormal signal was observed on diffusion weighted-imaging (DWI), and nodular delayed enhancement was observed in the enhanced portal vein phase and delayed phase. Upper esophagogastroduodenoscopy (EGD) performed on July 8, 2019 revealed a large submucosal bulge 30-35 mm from the incisors. The surface mucosa was smooth and blue, and the bulge was approximately 4.0 cm × 4.5 cm × 2 cm in size and involved 1/2 of the tube wall (Figure 1A). A submucosal bulge of approximately 2.5 cm × 3.0 cm × 2 cm in size was observed on the posterior wall of the bottom of the stomach, the surface of the mucosa was smooth, and the color of the mucosa was pale purple (Figure 2A). Upper gastrointestinal endoscopic ultrasound performed on July 8, 2019 showed that the lesions in the lower esophagus and posterior wall of the stomach originated from the submucosa, which protruded into a cavity with a grid-like echoless structure. The lesion was considered a cavernous hemangioma (Figures 1B and 2B).

FINAL DIAGNOSIS

Multiple cavernous hemangiomas were finally diagnosed by esophago-gastroduodenoscopy and endoscopic ultrasound.

TREATMENT

The patient refused to undergo surgical treatment for her own reasons, and after detailed communication with her, she decided to undergo treatment for her multiple GI hemangiomas with an endoscopic polidocanol (10 mL:100 mg, China's Shaanxi Tianyu Pharmaceutical) injection according to the surgeon's experience with endoscopic polidocanol sclerotherapy for esophageal and gastric varices. The injection dose must be based on the volume of the tumor, and according to the formula for tumor volume, 36 mL of polidocanol was calculated for injection of the esophageal hemangioma ($4.0 \text{ cm} \times 4.5 \text{ cm} \times 2 \text{ cm} = 36 \text{ cm}^3 = 36 \text{ mL}$), and 15 mL of polidocanol was calculated for injection of the gastric hemangioma ($2.5 \text{ cm} \times 3.0 \text{ cm} \times 2 \text{ cm} = 15 \text{ cm}^3 = 15 \text{ mL}$). A 25G endoscopic injection needle (Boston Science Company) was used to puncture the hemangioma, and then polidocanol was injected after blood return was observed. The posterior wall of the stomach was injected with 15 mL of polidocanol at three points (5 mL per point). After the needle was removed, the minimal bleeding at the eye of the needle resolved spontaneously. The esophagus was injected with 36 mL of polidocanol at three points (12 mL per point). The eye of the needle oozed after the needle was withdrawn, and the bleeding stopped after 3-5 min of compression with a needle sheath (Figures 1C and 2C). No abnormal changes in the heart rhythm, breathing, or blood pressure were observed during the operation. The patient was fasted for 24 h, proton pump inhibitors were administered to inhibit gastric acid, and she was observed for 48 h after surgery. The patient was discharged without discomfort and continued to be treated with proton pump inhibitors after discharge.

OUTCOME AND FOLLOW-UP

The patient was discharged without any complications and was in good clinical condition 1 wk after the treatment. EGD reexamination found that gastric hemangioma tumors were absent and the local mucosa was smooth without erosion or ulcers (Figures 1E and 2E) 1 mo after the treatment. One month later, endoscopic ultrasound showed that the bodies of the hemangiomas had disappeared, and no blood flow echo was observed (Figures 1D and 2D).

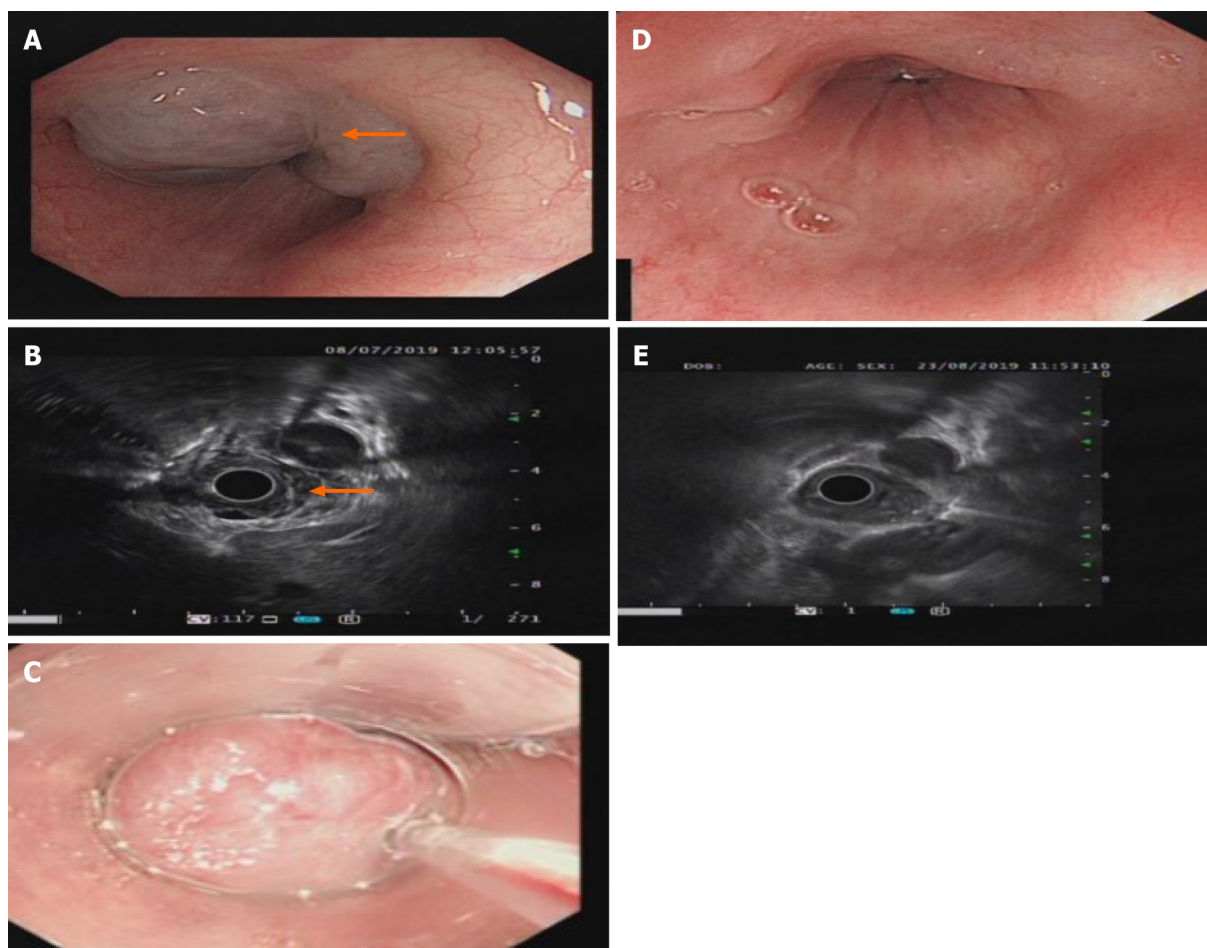


Figure 1 Gastroscopy and ultrasound images of the lower esophagus. A: Gastroscopy showing a bulge of about 4.0 cm × 4.5 cm × 2 cm in the lower esophagus. The mucosa was smooth and blue (as shown by the arrow in the picture); B: Endoscopic ultrasound showing lesions with multiple grids without echo structures and clear boundaries (as shown by the arrow in the picture); C: Twenty milliliters of polidocanol was injected into the hemangioma under a transparent cap with a 25G needle endoscope; D: The hemangioma at the esophageal lesion disappeared, and the mucosa was pink after treatment with polidocanol; E: Ultrasound showing that the non-echo structure disappeared after submucosal treatment with polidocanol.

DISCUSSION

Hemangiomas in the GI tract account for 0.05% of GI tumors^[9]. Compared with primary or metastatic tumors in the GI tract, the incidence of GI hemangioma is very low. Although the gold standard for the diagnosis of GI hemangiomas is histopathology, with the development of medical technology, CT and MRI combined with GI ultrasound and endoscopy are also sufficient for the clinical diagnosis. The sensitivity of ultrasound is 96.9%, and the specificity is 60.3%; the sensitivity of MRI is 100%, and the specificity is 85.7% in noninvasive diagnostic studies of hepatic hemangioma^[10]. Therefore, CT and MRI can obtain certain value in the diagnosis of GI hemangioma. Of course, EGD and endoscopic ultrasound have greater value in the diagnosis and treatment of submucosal hemangioma.

The main treatment methods for superficial hemangiomas include surgery, laser therapy, and sclerotherapy. For GI hemangiomas, most larger hemangiomas are treated by surgery or endoscopic mucosal dissection (ESD) (Table 1)^[9,11-21]. Surgery is associated with considerable trauma, long recovery period, and significant pain. Complications of ESD treatment include bleeding, perforation, subcutaneous emphysema, and infection; thus, other feasible minimally invasive treatment methods should be actively attempted. In the treatment of GI hemangioma, Fernandes and Fonseca reported a clinical study on the treatment of internal hemorrhoids with a large dose of 2% polidocanol, which successfully reduced the rebleeding rate^[5]. Igawa *et al*^[6] reported a clinical case of a small intestinal hemangioma successfully treated with single-point injection of polidocanol, and the amount of polidocanol was calculated according to the surface area of the hemangioma. Polidocanol can disintegrate the tumor tissue, make the tumor necrosis and fall off, achieve a similar effect to surgical resection, and obtain satisfactory results. Polidocanol is an ether compound with a

Table 1 Gastrointestinal hemangioma reports in recent years

No.	Ref.	Year	Age	Gender	Symptom	Site	Size (cm)	Treatment
1	Peng <i>et al</i> ^[11]	2015	43	F	Bloating, melena	Gastric	7.5 × 3.5 × 2	Surgery
2	Tai <i>et al</i> ^[12]	2012	23	F	Bloating, anemia	Gastric	24 × 14 × 5	Surgery
3	Feng <i>et al</i> ^[13]	2008	14	M	Hematemesis, melena	Gastric	10 × 15	Surgery
4	Shigemitsu <i>et al</i> ^[14]	2000	39	M	-	Esophagus	11 × 10	Laser
5	Shi <i>et al</i> ^[15]	2019	52	F	Dysphagia, thoracalgia	Esophagus	0.7 × 1.0	ESD
6	Gómez-Galán <i>et al</i> ^[16]	2016	43	F	Anemia	Duodenum, jejunum	4 × 2 × 1	Surgery
7	Mirioglu <i>et al</i> ^[17]	2016	70	M	Hematochezia, constipation	Rectum	Multiple	Surgery
8	Grgić <i>et al</i> ^[18]	2019	73	M	Anemia	Jejunum	2 × 2	Surgery
9	Grgić <i>et al</i> ^[18]	2019	63	M	Anemia	Ileum/Jejunum	8	Surgery
10	Kitahama <i>et al</i> ^[19]	2016	38	F	Diarrhea	Colon	3	Surgery
11	Fernandes <i>et al</i> ^[9]	2014	56	F	Hematochezia, syncope	Ileum	14	Surgery
12	Aoyama <i>et al</i> ^[20]	2020	58	F	Anemia	Duodenum Jejunum	Multiple	Sclerotherapy
13	Xiao <i>et al</i> ^[21]	2020	42	M	Melena, dizziness, and fatigue	Jejunum	-	Sclerotherapy

F: Female; M: Male.

slight anesthetic effect on local tissues that can reduce the pain of local lesions in patients after surgery. Polidocanol is hypoallergenic and has low toxicity^[2]. Polidocanol noninvasive treatment achieved satisfactory results. No adverse reactions such as fever, abdominal pain, or bleeding were observed during the follow-up period.

Compared with other reported cases, this case had the following characteristics: First, we report a case of multiple GI hemangiomas with multiple cavities. Multiple multicavity of GI hemangioma can be treated by injecting sclerosing agent into multiple sites. Multipoint injection can allow polidocanol to enter the entire tumor as much as possible. In addition, for conversion of the injection dose, we used the volume formula instead of the surface area formula, which can more accurately provide the specific dose required to eliminate the tumor. During the operation, the esophagus may be affected by peristalsis, respiration, the heartbeat, *etc.*, resulting in unclear visualization and difficulty in fixing the puncture needle. Accordingly, puncture can be performed with the help of a transparent cap. Transparent cap-assisted sclerotherapy provides a clear field of vision that assists in fixing the targeted veins, significantly reducing the use of the salvage hemostasis method during sclerotherapy for injection hemorrhage^[22].

CONCLUSION

For GI hemangioma, compared with gastroscopy and endoscopic ultrasound, CT or MRI has a certain value in the diagnosis of GI hemangioma. Multipoint polidocanol injection for the treatment of multiple GI hemangiomas under endoscopic guidance has the advantages of safety, efficacy, simplicity, cost effectiveness, and few adverse reactions.

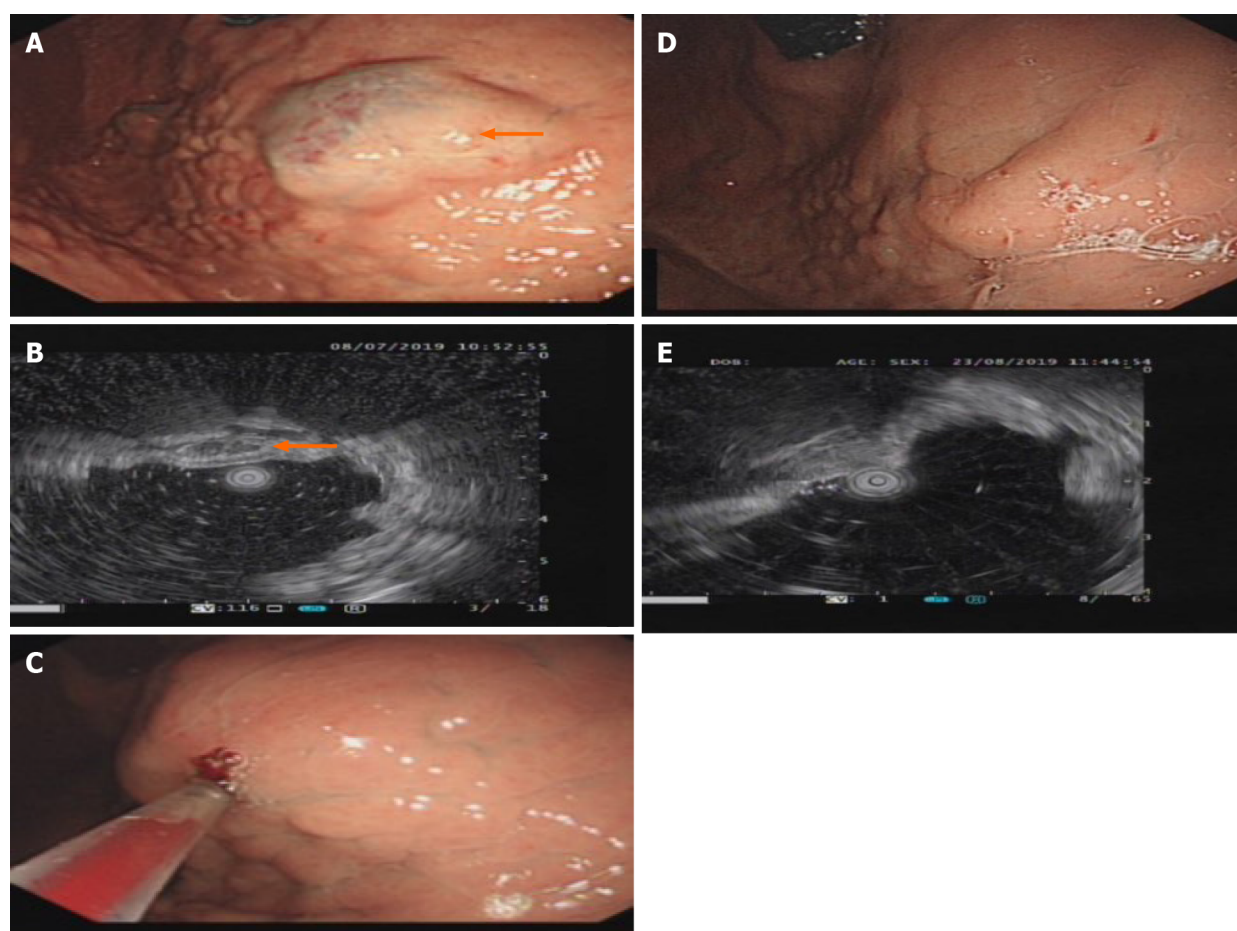


Figure 2 Gastroscopy and ultrasound images of the posterior wall of the bottom of the stomach. A: A 2.5 cm × 3.0 cm × 2 cm submucosal bulge of the posterior wall of the bottom of the stomach was seen on gastroscopy. The mucosa was smooth and the top of the mucosa was pale blue-purple (as shown by the arrow in the picture); B: Endoscopic ultrasound showing grid-like echoless structure with clear borders (as shown by the arrow in the picture); C: Fifteen milliliters of polidocanol was injected into the hemangioma under a transparent cap with a 25G needle endoscope; D: The submucosal bulge disappeared, and the mucosa color returned to normal on gastroscopy after treatment with polidocanol; E: The echoless structure of the lesions disappeared on endoscopic ultrasound after treatment with polidocanol.

REFERENCES

- 1 Levy AD, Abbott RM, Rohrmann CA Jr, Frazier AA, Kende A. Gastrointestinal hemangiomas: imaging findings with pathologic correlation in pediatric and adult patients. *AJR Am J Roentgenol* 2001; **177**: 1073-1081 [PMID: 11641173 DOI: 10.2214/ajr.177.5.1771073]
- 2 Grover C, Khurana A, Bhattacharya SN. Sclerotherapy for the treatment of infantile hemangiomas. *J Cutan Aesthet Surg* 2012; **5**: 201-203 [PMID: 23112519 DOI: 10.4103/0974-2077.101383]
- 3 Gao Z, Zhang Y, Li W, Shi C. Effectiveness and safety of polidocanol for the treatment of hemangiomas and vascular malformations: A meta-analysis. *Dermatol Ther* 2018; **31** [PMID: 29082587 DOI: 10.1111/dth.12568]
- 4 Wu K, Song Q, Gou Y, He S. Sandwich method with or without lauromacrogol in the treatment of gastric variceal bleeding with liver cirrhosis: A meta-analysis. *Medicine (Baltimore)* 2019; **98**: e16201 [PMID: 31261565 DOI: 10.1097/MD.00000000000016201]
- 5 Fernandes V, Fonseca J. Polidocanol Foam Injected at High Doses with Intravenous Needle: The (Almost) Perfect Treatment of Symptomatic Internal Hemorrhoids. *GE Port J Gastroenterol* 2019; **26**: 169-175 [PMID: 31192285 DOI: 10.1159/000492202]
- 6 Igawa A, Oka S, Tanaka S, Kuniyama S, Nakano M, Chayama K. Polidocanol injection therapy for small-bowel hemangioma by using double-balloon endoscopy. *Gastrointest Endosc* 2016; **84**: 163-167 [PMID: 26907744 DOI: 10.1016/j.gie.2016.02.021]
- 7 Lobascio P, Laforgia R, Novelli E, Perrone F, Di Salvo M, Pezzolla A, Trompetto M, Gallo G. Short-Term Results of Sclerotherapy with 3% Polidocanol Foam for Symptomatic Second- and Third-Degree Hemorrhoidal Disease. *J Invest Surg* 2020: 1-7 [PMID: 32290709 DOI: 10.1080/08941939.2020.1745964]
- 8 Markovic JN, Nag U, Shortell CK. Safety and efficacy of foam sclerotherapy for treatment of low-flow vascular malformations in children. *J Vasc Surg Venous Lymphat Disord* 2020; **8**: 1074-1082 [PMID: 32284312 DOI: 10.1016/j.jvsv.2019.11.023]

- 9 **Fernandes D**, Dionísio I, Neves S, Duarte P. Cavernous hemangioma of small bowel: a rare cause of digestive hemorrhage. *Rev Esp Enferm Dig* 2014; **106**: 214-215 [PMID: [25007019](#)]
- 10 **Toro A**, Mahfouz AE, Ardiri A, Malaguarnera M, Malaguarnera G, Loria F, Bertino G, Di Carlo I. What is changing in indications and treatment of hepatic hemangiomas. A review. *Ann Hepatol* 2014; **13**: 327-339 [PMID: [24927603](#)]
- 11 **Peng X**, Yang X, Fan CQ, Yang SM, Bai JY. A case of gastric cavernous hemangioma. *Jujie Shoushu Xue Zazhi* 2015; **24**: 698-699 [DOI: [10.11659/jjssx.02E015005](#)]
- 12 **Tai JD**, Zhao PW, Li B. A case of giant cavernous hemangioma of stomach. *Zhonghua Weichang Waike Zazhi* 2012; **15** [DOI: [10.3760/cma.j.issn.1671-0274.2012.06.033](#)]
- 13 **Feng HL**, Li CY, Yin XP. A case of giant gastric hemangioma with multiple hemangioma in liver. *Fangshe Xue Shijian Zazhi* 2008; **23** [DOI: [10.3969/j.issn.1000-0313.2008.01.042](#)]
- 14 **Shigemitsu K**, Naomoto Y, Yamatsuji T, Ono K, Aoki H, Haisa M, Tanaka N. Esophageal hemangioma successfully treated by fulguration using potassium titanyl phosphate/yttrium aluminum garnet (KTP/YAG) laser: a case report. *Dis Esophagus* 2000; **13**: 161-164 [PMID: [14601909](#) DOI: [10.1046/j.1442-2050.2000.00087.x](#)]
- 15 **Shi BP**, Fu Y, Liu GB, Qu GD, Li XH, Wei L, Li J, Lu ML. A case report of esophageal cavernous hemangioma. *Weichangbing Xue He Ganbing Xue Zazhi* 2019; **8**: 959-960
- 16 **Gómez-Galán S**, Mosquera-Paz MS, Ceballos J, Cifuentes-Grillo PA, Gutiérrez-Soriano L. Duodenal hemangiolymphangioma presenting as chronic anemia: a case report. *BMC Res Notes* 2016; **9**: 426 [PMID: [27581369](#) DOI: [10.1186/s13104-016-2214-0](#)]
- 17 **Mirioglu S**, Cavus B, Iliaz R, Besisik F. Diffuse Cavernous Hemangioma of the Colon. *Acta Gastroenterol Belg* 2016; **79**: 393-394 [PMID: [27821043](#)]
- 18 **Grgić D**, Prijić R, Romić I, Augustin G, Markoš P, Korša L, Marušić Z, Rustemović N, Krznarić Ž. A Single Small Bowel Hemangioma Detected by Video Capsule Endoscopy in a Patient Presenting with Iron-deficiency Anemia - Two Case Reports. *Prague Med Rep* 2019; **120**: 138-143 [PMID: [31935349](#) DOI: [10.14712/23362936.2019.19](#)]
- 19 **Kitahama A**, Katayama Y, Sugamata Y, Tamano M. Large venous malformation of right colonic flexure. *Korean J Intern Med* 2016; **31**: 1194-1195 [PMID: [27658503](#) DOI: [10.3904/kjim.2016.081](#)]
- 20 **Aoyama T**, Fukumoto A, Shigita K, Asayama N, Mukai S, Nagata S. Successful Endoscopic Sclerotherapy Using Polidocanol for Small Bowel Hemangioma. *Intern Med* 2020; **59**: 1727-1730 [PMID: [32238724](#) DOI: [10.2169/internalmedicine.4327-19](#)]
- 21 **Xiao NJ**, Ning SB, Li T, Li BR, Sun T. Small intestinal hemolymphangioma treated with enteroscopic injection sclerotherapy: A case report and review of literature. *World J Gastroenterol* 2020; **26**: 1540-1545 [PMID: [32308353](#) DOI: [10.3748/wjg.v26.i13.1540](#)]
- 22 **Ma L**, Huang X, Lian J, Wang J, Chen S. Transparent cap-assisted endoscopic sclerotherapy in esophageal varices: a randomized-controlled trial. *Eur J Gastroenterol Hepatol* 2018; **30**: 626-630 [PMID: [29505477](#) DOI: [10.1097/MEG.0000000000001107](#)]



Published by **Baishideng Publishing Group Inc**
7041 Koll Center Parkway, Suite 160, Pleasanton, CA 94566, USA

Telephone: +1-925-3991568

E-mail: bpgoffice@wjgnet.com

Help Desk: <https://www.f6publishing.com/helpdesk>

<https://www.wjgnet.com>

