


World Journal of *Clinical Cases*

World J Clin Cases 2021 March 6; 9(7): 1499-1760



Contents

Thrice Monthly Volume 9 Number 7 March 6, 2021

REVIEW

- 1499 Review of the risk factors for SARS-CoV-2 transmission

Li X, Xia WY, Jiang F, Liu DY, Lei SQ, Xia ZY, Wu QP

MINIREVIEWS

- 1513 Regulation of the expression of proinflammatory cytokines induced by SARS-CoV-2

Zhang XN, Wu LJ, Kong X, Zheng BY, Zhang Z, He ZW

ORIGINAL ARTICLE

Case Control Study

- 1524 Efficacy and safety of short duration radiotherapy combined with chemotherapy for advanced rectal cancer

Gao SQ, Zhang YC, Zhang C, Wang SJ, Ren W, Yuan N, Wen JY

Retrospective Study

- 1532 Effects of transjugular intrahepatic portosystemic shunt using the Viatorr stent on hepatic reserve function in patients with cirrhosis

Yao X, Zhou H, Huang S, Tang SH, Qin JP

- 1543 Primary and secondary postoperative hemorrhage in pediatric tonsillectomy

Xu B, Jin HY, Wu K, Chen C, Li L, Zhang Y, Gu WZ, Chen C

- 1554 Dynamic monitoring of serum liver function indexes in patients with COVID-19

Lin H, Wu LJ, Guo SQ, Chen RL, Fan JR, Ke B, Pan ZQ

- 1563 Construction of a clinical survival prognostic model for middle-aged and elderly patients with stage III rectal adenocarcinoma

Liu H, Li Y, Qu YD, Zhao JJ, Zheng ZW, Jiao XL, Zhang J

- 1580 Short-term outcomes of radiofrequency ablation for hepatocellular carcinoma using cone-beam computed tomography for planning and image guidance

Yao XS, Yan D, Jiang XX, Li X, Zeng HY, Li H

- 1592 Intra-arterial thrombolysis for early hepatic artery thrombosis after liver transplantation

Li T, Sun XD, Yu Y, Lv GY

- 1600 Study on pathogenic genes of dwarfism disease by next-generation sequencing

Yang LL, Liang SS

- 1610** Effects of cooperative nursing and patient education on postoperative infection and self-efficacy in gastrointestinal tumors

Qiao L, Zeng SQ, Zhang N

Observational Study

- 1619** Elevated soluble 4-1BB is associated with serum markers of hepatitis B virus in patients with chronic hepatitis B

Zhan MR, Gao XZ, Wang C, Peng F, Wang XM, Xu HQ, Niu JQ

CASE REPORT

- 1631** Balloon-assisted endoscopic submucosal dissection for treating small intestinal lipomas: Report of two cases

Chen HY, Ning SB, Yin X, Li BR, Zhang J, Jin XW, Sun T, Xia ZB, Zhang XP

- 1639** Dysphagia in a patient with ankylosing spondylitis: A case report

Wang XW, Zhang WZ

- 1646** Autologous scalp skin grafting to treat toxic epidermal necrolysis in a patient with a large skin injury: A case report

Xue DD, Zhou L, Yang Y, Ma SY

- 1654** Epstein-Barr virus-positive diffuse large B-cell lymphoma with human immunodeficiency virus mimicking complicated frontal sinusitis: A case report

Yoon S, Ryu KH, Baek HJ, An HJ, Joo YH

- 1661** Multiple well-differentiated retroperitoneal liposarcomas with different patterns of appearance on computed tomography: A case report

Xie TH, Ren XX, Fu Y, Ha SN, Liu LT, Jin XS

- 1668** Sarcomatoid carcinoma of the prostate with bladder invasion shortly after androgen deprivation: Two case reports

Wei W, Li QG, Long X, Hu GH, He HJ, Huang YB, Yi XL

- 1676** Metastatic thymic-enteric adenocarcinoma responding to chemoradiation plus anti-angiogenic therapy: A case report

Li M, Pu XY, Dong LH, Chang PY

- 1682** Solid pseudopapillary neoplasm-diagnostic approach and post-surgical follow up: Three case reports and review of literature

Abudalou M, Vega EA, Dhingra R, Holzwanger E, Krishnan S, Kondratiev S, Niakosari A, Conrad C, Stallwood CG

- 1696** Vancomycin-induced thrombocytopenia in endocarditis: A case report and review of literature

Guleng SR, Wu RH, Guo XB

- 1705** Human menstrual blood-derived stem cells as immunoregulatory therapy in COVID-19: A case report and review of the literature

Lu J, Xie ZY, Zhu DH, Li LJ

- 1714** Pure transvaginal natural orifice transluminal endoscopic surgery right hemicolectomy for colon cancer: A case report
Song ZJ, Shi YQ, Jiang YM, Liu K, Li Y, Wang CG, Zhao R
- 1720** Hyperglycemic hemianopia: A case report
Xiang XH, Fang JJ, Yang M, Zhao GH
- 1728** Mucinous appendiceal neoplasm: A case report
Chirca A, Negreanu L, Iliesiu A, Costea R
- 1734** Reconstructing abdominal wall defects with a free composite tissue flap: A case report
Wang J
- 1741** Mononeuropathy multiplex associated with systemic vasculitis: A case report
Chae HJ, Kim JW, Lee YL, Park JH, Lee SY
- 1748** Congenital fiber-type disproportion presenting with type II respiratory failure after delivery: A case report
Yang HM, Guo JX, Yang YM
- 1755** Use of three dimensional-printing in the management of floating aortic thrombus due to occult aortic dissection: A case report
Wang TH, Zhao JC, Xiong F, Yang Y

ABOUT COVER

Chin-Hsiao Tseng, MD, PhD, Full Professor, Department of Internal Medicine, National Taiwan University College of Medicine, No. 1 Jen Ai Road Section 1, Taipei 100, Taiwan. cckts@ms6.hinet.net

AIMS AND SCOPE

The primary aim of *World Journal of Clinical Cases* (WJCC, *World J Clin Cases*) is to provide scholars and readers from various fields of clinical medicine with a platform to publish high-quality clinical research articles and communicate their research findings online.

WJCC mainly publishes articles reporting research results and findings obtained in the field of clinical medicine and covering a wide range of topics, including case control studies, retrospective cohort studies, retrospective studies, clinical trials studies, observational studies, prospective studies, randomized controlled trials, randomized clinical trials, systematic reviews, meta-analysis, and case reports.

INDEXING/ABSTRACTING

The WJCC is now indexed in Science Citation Index Expanded (also known as SciSearch®), Journal Citation Reports/Science Edition, Scopus, PubMed, and PubMed Central. The 2020 Edition of Journal Citation Reports® cites the 2019 impact factor (IF) for WJCC as 1.013; IF without journal self cites: 0.991; Ranking: 120 among 165 journals in medicine, general and internal; and Quartile category: Q3. The WJCC's CiteScore for 2019 is 0.3 and Scopus CiteScore rank 2019: General Medicine is 394/529.

RESPONSIBLE EDITORS FOR THIS ISSUE

Production Editor: Yan-Xia Xing; **Production Department Director:** Yun-Xiaoqian Wu; **Editorial Office Director:** Jin-Li Wang.

NAME OF JOURNAL

World Journal of Clinical Cases

ISSN

ISSN 2307-8960 (online)

LAUNCH DATE

April 16, 2013

FREQUENCY

Thrice Monthly

EDITORS-IN-CHIEF

Dennis A Bloomfield, Sandro Vento, Bao-Gan Peng

EDITORIAL BOARD MEMBERS

<https://www.wjgnet.com/2307-8960/editorialboard.htm>

PUBLICATION DATE

March 6, 2021

COPYRIGHT

© 2021 Baishideng Publishing Group Inc

INSTRUCTIONS TO AUTHORS

<https://www.wjgnet.com/bpg/gerinfo/204>

GUIDELINES FOR ETHICS DOCUMENTS

<https://www.wjgnet.com/bpg/GerInfo/287>

GUIDELINES FOR NON-NATIVE SPEAKERS OF ENGLISH

<https://www.wjgnet.com/bpg/gerinfo/240>

PUBLICATION ETHICS

<https://www.wjgnet.com/bpg/GerInfo/288>

PUBLICATION MISCONDUCT

<https://www.wjgnet.com/bpg/gerinfo/208>

ARTICLE PROCESSING CHARGE

<https://www.wjgnet.com/bpg/gerinfo/242>

STEPS FOR SUBMITTING MANUSCRIPTS

<https://www.wjgnet.com/bpg/GerInfo/239>

ONLINE SUBMISSION

<https://www.f6publishing.com>



Balloon-assisted endoscopic submucosal dissection for treating small intestinal lipomas: Report of two cases

Hong-Yu Chen, Shou-Bin Ning, Xin Yin, Bai-Rong Li, Jing Zhang, Xiao-Wei Jin, Tao Sun, Zhi-Bo Xia, Xiao-Peng Zhang

ORCID number: Hong-Yu Chen 0000-0002-4602-0192; Shou-Bin Ning 0000-0002-1499-7468; Xin Yin 0000-0002-6677-6894; Bai-Rong Li 0000-0001-5758-4447; Jing Zhang 0000-0002-1356-6666; Xiao-Wei Jin 0000-0002-6219-3421; Tao Sun 0000-0002-2072-268x; Zhi-Bo Xia 0000-0003-4179-4380; Xiao-Peng Zhang 0000-0002-0482-0140.

Author contributions: Chen HY prepared the case and contributed to manuscript drafting; Yin X analyzed the case and reviewed the literature; Ning SB contributed to endoscopic therapy and manuscript guidance; Zhang J contributed to assistance of the endoscopic therapy; Li BR, Jin XW, Sun T, Zhang XP, and Xia ZB contributed to manuscript revision for important intellectual content; all authors gave final approval for the version to be submitted.

Informed consent statement: Informed written consent was obtained from the patients for publication of this report and any accompanying images.

Conflict-of-interest statement: The authors declare that they have no conflict of interest to report.

CARE Checklist (2016) statement: The authors have read the CARE Checklist (2016), and the

Hong-Yu Chen, Shou-Bin Ning, Xin Yin, Bai-Rong Li, Jing Zhang, Xiao-Wei Jin, Tao Sun, Zhi-Bo Xia, Xiao-Peng Zhang, Department of Gastroenterology, Air Force Medical Center, PLA of China, Beijing 100142, China

Corresponding author: Shou-Bin Ning, PhD, Chief Physician, Department of Gastroenterology, Air Force Medical Center, PLA of China, No. 30 Fucheng Road, Haidian District, Beijing 100142, China. shoubinning@126.com

Abstract

BACKGROUND

Most small intestinal lipomas are treated surgically, and some require repeated surgeries for multiple lipomas. However, application of endoscopic submucosal dissection (ESD) technology in the deep small intestine is rarely reported owing to the special anatomical structure of the small intestine, medical equipment limitations, and the lack of relevant experience among endoscopists.

CASE SUMMARY

Two patients with small intestinal lipomas treated at the Air Force Medical Center from November 2015 to September 2019 were selected to undergo balloon-assisted ESD to treat the lipomas and explore the technical feasibility and safety of ESD for treating small intestinal lipomas. The two patients successfully underwent balloon-assisted ESD to treat four small intestinal lipomas, with a complete resection rate of 100% (4/4), without intraoperative or postoperative bleeding, perforation, or other complications. After 3-6 mo of postoperative follow-up, the clinical symptoms caused by the lipomas were significantly relieved or disappeared after treatment.

CONCLUSION

Balloon-assisted ESD is a safe and reliable new method for treating deep intestinal lipomas and shows good clinical feasibility.

Key Words: Endoscopic submucosal dissection; Balloon-assisted endoscopy; Small intestinal lipoma; Gastrointestinal tumor; Case report

©The Author(s) 2021. Published by Baishideng Publishing Group Inc. All rights reserved.

manuscript was prepared and revised according to the CARE Checklist (2016).

Open-Access: This article is an open-access article that was selected by an in-house editor and fully peer-reviewed by external reviewers. It is distributed in accordance with the Creative Commons Attribution NonCommercial (CC BY-NC 4.0) license, which permits others to distribute, remix, adapt, build upon this work non-commercially, and license their derivative works on different terms, provided the original work is properly cited and the use is non-commercial. See: <http://creativecommons.org/licenses/by-nc/4.0/>

Manuscript source: Unsolicited manuscript

Specialty type: Medicine, research and experimental

Country/Territory of origin: China

Peer-review report's scientific quality classification

Grade A (Excellent): 0
Grade B (Very good): 0
Grade C (Good): C, C, C
Grade D (Fair): 0
Grade E (Poor): 0

Received: July 26, 2020

Peer-review started: July 26, 2020

First decision: August 7, 2020

Revised: August 21, 2020

Accepted: January 5, 2021

Article in press: January 5, 2021

Published online: March 6, 2021

P-Reviewer: Kawabata H, Sugimoto M

S-Editor: Fan JR

L-Editor: Wang TQ

P-Editor: Zhang YL



Core Tip: Endoscopic submucosal dissection (ESD) technology plays an increasingly important role in the treatment of early gastrointestinal cancer and benign gastrointestinal tumors, but its application in the deep small intestine is rarely reported. In this study, two patients with small intestinal lipoma were successfully treated by ESD with balloon-assisted endoscopy, without intraoperative or postoperative bleeding, perforation, or other complications. The clinical symptoms caused by the lipomas were relieved or disappeared in the postoperative follow-up. We believe that balloon-assisted ESD for the treatment of small intestinal lipoma is safe and reliable, with good clinical feasibility, and can be used as a new method for the treatment of deep intestinal lipomas.

Citation: Chen HY, Ning SB, Yin X, Li BR, Zhang J, Jin XW, Sun T, Xia ZB, Zhang XP. Balloon-assisted endoscopic submucosal dissection for treating small intestinal lipomas: Report of two cases. *World J Clin Cases* 2021; 9(7): 1631-1638

URL: <https://www.wjgnet.com/2307-8960/full/v9/i7/1631.htm>

DOI: <https://dx.doi.org/10.12998/wjcc.v9.i7.1631>

INTRODUCTION

Small intestinal lipomas are benign tumors that usually do not cause clinical symptoms. However, large intestinal lipomas can occasionally cause repeated intussusception, intestinal obstruction, and gastrointestinal bleeding, leading to more serious clinical consequences^[1]. Most small intestinal lipomas are treated surgically, but there are also some researchers who try to use endoscopic resection (Table 1). Endoscopic submucosal dissection (ESD) is a newer endoscopic treatment technology. As ESD technology develops, it plays an increasingly important role in treating early cancers and benign tumors of the digestive tract^[2]. Some researchers have used gastroscopy and colonoscopy to perform ESD to treat duodenal and ileal lipomas^[3,4]. However, application of ESD technology in the deep small intestine is rarely reported owing to the special anatomical structure of the small intestine, medical equipment limitations, and the lack of relevant experience among endoscopists. This study explored the clinical feasibility of ESD treatment for deep intestinal lipomas under single-balloon enteroscopy (SBE). The methods and cases are reported herein.

Cases and methods

Inclusion criteria: The inclusion criteria were: (1) Patients with small intestinal lipoma(s) admitted to the department of gastroenterology, Air Force Characteristic Medical Center of the PLA from November 2015 to September 2019; (2) Patients who had clinical symptoms such as repeated abdominal pain, abdominal distension, obstruction, and hemorrhage as well as patients in remission; (3) Lipoma base diameter was ≥ 1.5 cm, and the risks due to endoscopic mucosal resection (EMR) were expected to be high and (4) The patients and their families agreed to ESD treatment and provided informed consent.

Exclusion criteria: The exclusion criteria were: (1) Patients with severe basic diseases who could not tolerate anesthesia or endoscopic examination; (2) Complete intestinal obstruction made intestinal preparation impossible; (3) Presence of lipoma hemorrhage with hemorrhagic shock or extraluminal lipomas; (4) No consent to ESD treatment was provided; and (5) Diameter of the lipoma base was < 1.5 cm, and the risks due to EMR were expected to be low (could be treated by EMR and regular follow-up).

Equipment information: The following equipment was used: SBE (SIF-0260, Olympus), outer thimble (ST-SB1, Olympus), IT knife (KD-612U, Olympus), dual knife (KD-650U, Olympus), transparent cap (D-201-11804, Olympus), endoscopic injector (WS-2423PN, Wilson), argon plasma coagulation (APC2, ERBE), high-frequency electric knife (VID 300S, ERBE), hemostatic forceps (FD-411UR, Olympus), disposable metal clip (ROCC-D-26-230, Micro-Tech; Nanjing Co.), and instrument channel adaptor (MAJ-1606, Olympus; used to connect to the biopsy channel to temporarily replace the auxiliary water supply function of the balloon-assisted endoscopy as it

Table 1 Cases of lipoma of the small intestine with bleeding reported in the literature (2004–2013)

Ref.	Age	Sex	Location	Tumor size	Treatment
Baskaran <i>et al</i> ^[18]	55	M	Ileum	N/A	Surgical resection
Baskaran <i>et al</i> ^[18]	34	M	Ileum	N/A	Surgical resection
Pezzoli <i>et al</i> ^[19]	64	M	Jejunum	N/A	Surgical resection
Pezzoli <i>et al</i> ^[19]	44	M	Ileum	N/A	Surgical resection
Chou <i>et al</i> ^[20]	57	M	Ileum	3 cm × 1.5 cm × 1.5 cm	Surgical resection
Morimoto <i>et al</i> ^[21]	62	M	Ileum	> 3 cm	ESD with colonoscopy
Toya <i>et al</i> ^[21]	79	M	Jejunum	3.5 cm × 1.7 cm	EMR with DBE

EMR: Endoscopic mucosal resection; ESD: Endoscopic submucosal dissection; DBE: Double-balloon endoscopy.

does not have a special channel for the water supply).

Steps and key techniques of ESD with SBE for treating intestinal lipomas: Preoperative assessment: The general condition of the patients should be comprehensively evaluated, and the coagulation function should be corrected before treatment in patients with coagulation disorders.

As with routine SBE, once the SBE reaches the lesion, the outer thimble should be moved to the top and then pulled back with the SBE after inflating the balloon so that the lens can freely approach the lesion. After completing these steps, the endoscopist can begin the ESD as the assistant fixes the outer thimble.

Lesion marking: Marking is unnecessary if the lesion is prominent, and the basal area has a clear boundary; however, boundaries that are unclear or undetermined post injection should be marked accordingly.

Submucosal injections are performed with 1:4 diluted sodium hyaluronate. After sufficient submucosal injection, the mucosa is incised after being well elevated.

Mucosal incision and lipoma dissection: The mucosa is cut in an arc as close to the tumor edge as possible, with the gravity-side mucosa being incised first to enable more easily exposing the yellowish mass under the mucosa. During dissection, a clear field of vision must be maintained as far as possible to pretreat the large blood vessels as far as possible to avoid perioperative bleeding. Multiple submucosal injections can ensure sufficient separation of the lesion and muscle layer. Dissection should not be performed too quickly.

Postoperative wound management: After completely removing the tumor, the wound surface should be carefully examined. For visible bleeding or tiny blood vessels, coagulation treatments, such as argon plasma coagulation and thermal tweezers, can be used. If the muscle layer is damaged or perforated during the operation, the wound surface must be closed with metal clips. Postoperative perforation or bleeding is difficult to correct endoscopically because of the anatomy of the small intestine; therefore, the wound surface should be sutured as much as possible.

Postoperative management

Antibiotics were routinely administered within 48 postoperative hours to prevent wound infection. Patients were given intravenous nutrition for 3–5 d, then the diet was gradually restored according to recovery status.

CASE PRESENTATION

Chief complaints

Case 1: A 44-year-old male patient was admitted to our hospital because of repeated right lower abdominal pain for 5 years.

Case 2: A 62-year-old male patient was admitted to our hospital because of multiple masses in his small intestine and one of them caused intussusception.

History of present illness

Case 1: The patient underwent colonoscopy due to abdominal pain and showed a 3 cm × 4 cm yellowish mass in the terminal ileum 20 cm from the ileocecal valve, with a smooth surface. The mass could slide under the mucosa and occupied nearly the entire intestinal cavity.

Case 2: The patient underwent emergency surgical treatment in August 2017 because of small bowel intussusception. In addition to small intestinal intussusception, preoperative abdominal computed tomography (CT) examination revealed multiple fat-density mass shadows in his small intestine. Postoperative pathology showed that the intussusception was caused by a 5.2 cm × 4.5 cm × 3.1 cm intestinal submucosal lipoma. The patient continued to experience repeated abdominal distention and abdominal pain post surgery.

History of past illness

Case 1: The patient had no gastrointestinal solid tumor before.

Case 2: Abdominal CT showed multiple pancreatic lipomas.

Physical examination

Case 1: The patient had a flat and soft abdomen without tenderness, rebound pain, or muscle tension.

Case 2: Longitudinal scar about 10 cm long was seen in the center of the abdomen, with no other positive abdominal signs.

Laboratory examinations

Case 1: The results showed that no significant abnormality was found in tumor markers or other routine examinations.

Case 2: The results showed that no significant abnormality was found in tumor markers or other routine examinations.

Imaging examinations

Case 1: CT imaging showed a 2.3 cm × 1.3 cm fat density, with clear boundaries in the terminal ileum, causing the intestinal cavity to narrow. Contrast-enhanced scanning showed no enhancement.

Case 2: Abdominal CT in November 2018 showed multiple fat-density masses remaining in the small intestine with intestinal cavity dilatation, with the largest mass being approximately 5 cm in diameter.

FINAL DIAGNOSIS

Pathology confirmed that the small intestinal tumors were submucosal lipomas.

TREATMENT

Case 1: After communicating with the patient and his family, who expressed their willingness to try endoscopic treatment, we performed the ESD with SBE transanally in November 2015. The tumor was dissected successfully with no bleeding or muscle layer damage and the wound surface was sutured with three metal clips (**Figure 1**).

Case 2: Three SBEs were performed in our hospital. In November 2018, the first SBE showed a 3.0 cm × 6.0 cm yellowish mass in the jejunum 80 cm from the pylorus, with a smooth mucosal surface, accounting for 2/3 of the intestinal cavity. We communicated with the family and resected the tumor by ESD under SBE. The patient's abdominal distension and pain were significantly relieved after the ESD. After a month of recovery and communication with family members, we continued the endoscopic treatment of the remaining lipoma. To ensure the effectiveness and safety of the treatment, we only treated one site at a time. In December 2018, the second SBE showed a 3.0 cm × 3.0 cm yellowish mass with a smooth mucosal surface 140 cm from the pylorus and we performed ESD again. After two treatments, the

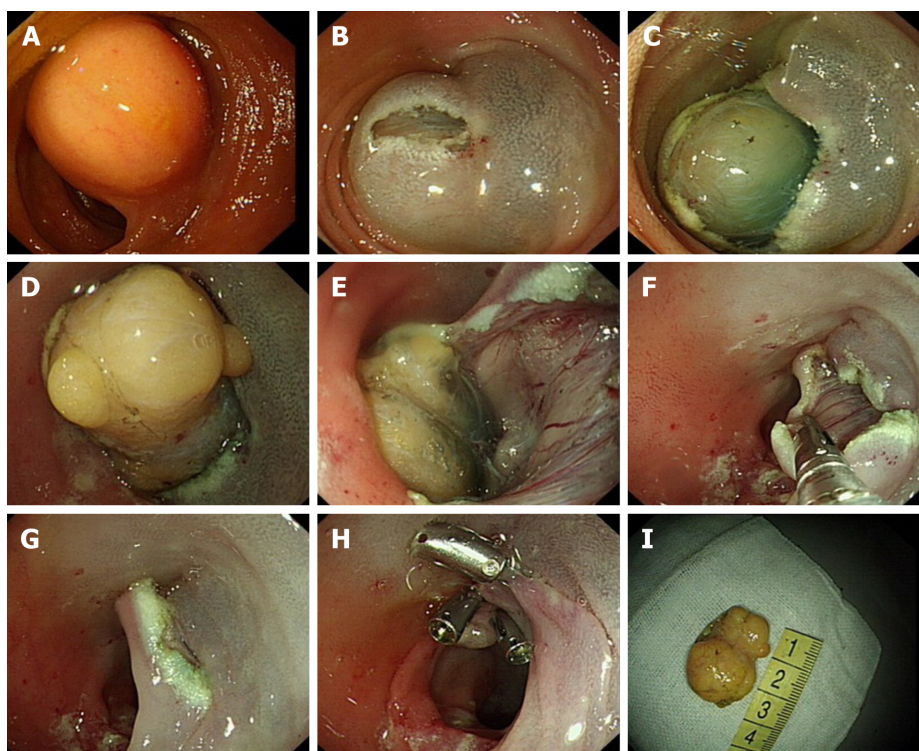


Figure 1 Endoscopic submucosal dissection treatment of a terminal ileal lipoma. A: Submucosal lipoma at the terminal ileum; B: Dual knife cut of approximately 1 cm transversely at the anal side of the tumor; C-E: Submucosal lipoma revealed; F: Wound surface after endoscopic submucosal dissection; G: Mucosa covered the wound surface after removing the tumor; H: The wound surface was closed with metal clips; I: Tumor *in vitro*.

patient's clinical symptoms were mostly relieved, but a slightly large intestinal lipoma remained. The patient chose clinical observation, but the abdominal pain reoccurred 9 mo later. Thus, we conducted the third SBE examination in September 2019. An anastomosis was observed in the jejunum 180 cm from the pylorus. The 3 cm × 3 cm lipoma was 320 cm from the pylorus and had the same smooth mucosal surface, accounting for approximately 1/2 of the intestinal cavity. No bleeding or muscle layer damage occurred, and no postoperative bleeding, delayed perforation, or other complications occurred during three ESD treatments (Figure 2).

OUTCOME AND FOLLOW-UP

The two patients underwent four ESDs with SBE; one patient underwent 3 ESDs for multiple small intestinal lipomas, all of which were completely removed, with no intraoperative or postoperative bleeding, perforation, stenosis, or other complications. Neither of the two patients had obvious postoperative discomfort, and the previous abdominal discomfort disappeared. The patients were followed for 3–6 mo postoperatively. CT and/or SBE showed good local mucosal recovery and no tumor recurrence (Table 2).

DISCUSSION

Small intestinal lipomas are rare benign tumors of the digestive tract, originating from submucosal or subserosal adipose tissue. Lipomas have clear boundaries and can be divided into intraluminal, extraluminal, intramural, and mixed types according to lesion location and growth mode. Intraluminal type is the most common and has a good prognosis^[5]. The cause of the disease is unclear and may be related to systemic fat metabolism disorders, Whipple disease, intestinal malnutrition, and inflammatory stimulation^[6]. Small intestinal lipomas are mostly asymptomatic and can be found accidentally during an endoscopic examination or surgery and generally do not require special treatment. Large lipomas (≥ 2 cm) often have complications such as

Table 2 Summary of patient treatments

Patient	Date of treatment	Site of lipoma	Size of lipoma (cm)	Treatment method	Clinical symptoms after treatment	Complications	Follow-up
No. 1	November 2015	Ileum 10 cm from the ileocecal valve	3.0 cm × 2.0 cm × 2.0 cm	ESD	Abdominal pain disappeared	None	No recurrence or long-term complications
No. 2	August 2017	Jejunum 180 cm from the pylorus	5.2 cm × 4.5 cm × 3.1 cm	Surgery	Repeated abdominal distention and abdominal pain		
	November 2018	Jejunum 80 cm from the pylorus	4.8 cm × 2.7 cm × 0.7 cm	ESD	Symptoms significantly relieved		
	December 2018	Jejunum 140 cm from the pylorus	2.4 cm × 1.7 cm × 1.7 cm	ESD	Symptoms basically relieved		
	September 2019	Jejunum 320 cm from the pylorus	2.0 cm × 2.0 cm × 1.0 cm	ESD	Symptoms disappeared		

ESD: Endoscopic submucosal dissection.

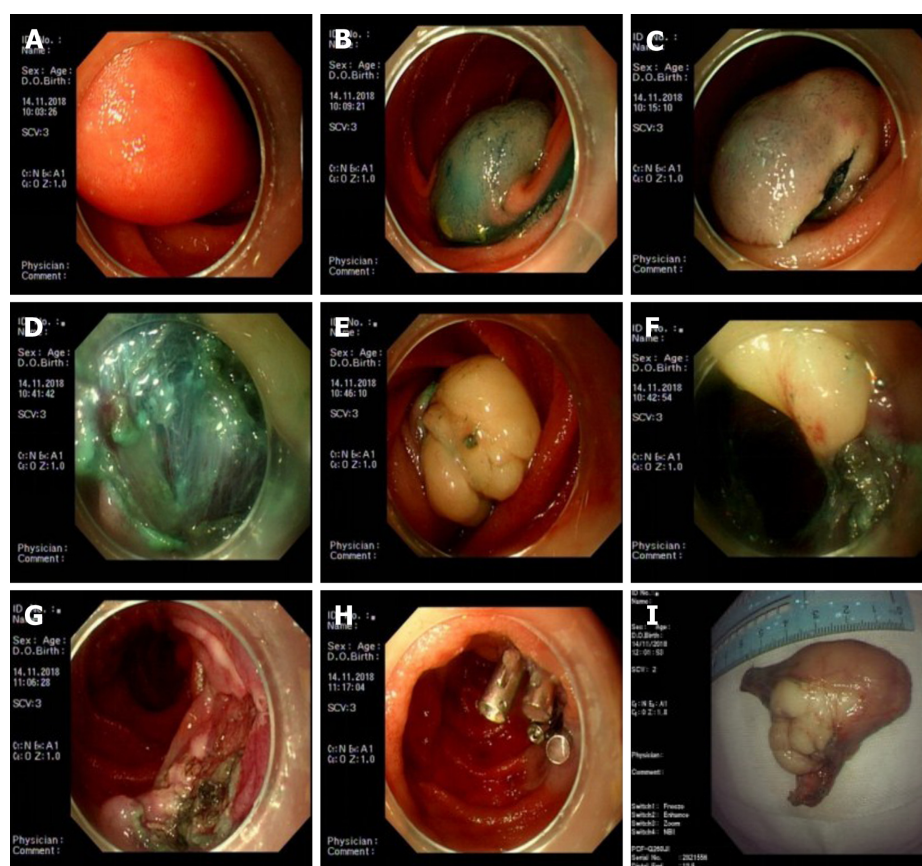


Figure 2 First endoscopic submucosal dissection treatment for lipoma in November 2012. A: Jejunal lipoma with a smooth mucosal surface, occupying 2/3 of the lumen; B: Good lifting *via* submucosal injection; C: Dual knife cut in an arc along the bottom of the tumor; D: The tumor was located in the submucosa during the dissection; E and F: Dissociated submucosal tumor; G: Wound surface after dissection; H: Metal clip closing the wound surface; I: Tumor *in vitro*.

intussusception and intestinal obstruction and can cause related clinical symptoms. Their clinical manifestations depend on the tumor size, location, and morphology and include abdominal distension, abdominal masses, and gastrointestinal bleeding. Surgery, including laparotomy and laparoscopic-assisted resection, is the first-choice treatment for symptomatic tumors^[7-9]. Gotoda, a Japanese scholar, reported the first case of successful resection of a gastrointestinal mass > 2 cm in diameter *via* ESD in 1999^[10]. As ESD technology gradually improves, it is being widely used in clinical practice for its advantages of less surgical trauma, fast postoperative recovery, and low cost. ESD is a reliable and minimally invasive method for treating early and benign

tumors in the esophagus, stomach, and colon, thus preventing many unnecessary surgeries.

Endoscopic treatment in the deep intestine is technically difficult because the small intestinal wall is thin, the mucosal blood supply is abundant, the intestinal tract is long and curved, and the intestinal cavity space is narrow. The duodenum is one of the most difficult areas to implement ESD^[11]. The clinical application of balloon-assisted endoscopy (including double-balloon and single-balloon colonoscopies) has enabled endoscopically treating small intestinal diseases^[11-14]. The authors' institution is exploring several new technologies for early diagnosing and treating small intestinal diseases by balloon-assisted endoscopy, such as resection of large polyps, metal stent placement, benign stricture dissection, and endoscopic hemostasis of hemangiomas and other hemorrhagic diseases. Our institution has accumulated experience in piecemeal resection and en bloc resection *via* EMR of large small intestinal polyps in patients with Peutz-Jeghers syndrome^[15,16].

Symptomatic small intestinal lipomas requiring treatment are usually large. Whether minimally invasive treatment can be performed under endoscopy requires clinical verification. Small intestinal lipomas are usually located in the submucosa and differ from small intestinal polyps derived from the mucosal layer. After submucosal injection, the degree of the polypectomy snare is difficult to control; if the snare is too shallow, it may not resect the whole tumor, and if it is too deep, it may cause intraoperative or postoperative perforation. ESD may be more effective because EMR is difficult and carries a high risk. A case report of ESD for a small intestinal lipoma in the terminal ileum *via* colonoscopy preliminarily demonstrated the feasibility of ESD in the small intestine^[3]. Because the endoscopy did not destroy the small intestinal mucosa circumferentially, and the tumor surface covering the mucosa was retained, postoperative small intestinal stricture was theoretically unlikely to occur. Recent accumulating literature has demonstrated the feasibility of ESD in the difficult sections of the colon under balloon-assisted endoscopy, such as ESD in the liver region of the colon, ascending colon, cecum, and ileocecal valve^[17]. Our institution has performed ESD in the difficult portions of the colon *via* balloon-assisted endoscopy and preliminarily verified its feasibility and safety. However, ESD for benign tumors of the deep intestine is rarely reported. Because both double-balloon endoscopy and SBE have no auxiliary water supply function, and because the long body of the small intestine is usually tortuous near the lesion, the treatment is more difficult. Therefore, the operator must retain superior endoscopic control ability.

CONCLUSION

ESD under balloon-assisted endoscopy has a high block resection rate for large small intestinal lipomas with no uncontrolled serious complications, which thus has high clinical application feasibility and safety. However, ESD treatment of small intestinal lipomas *via* balloon-assisted endoscopy confers technical difficulties; therefore, the endoscopist must master the operative skills needed for balloon-assisted endoscopy and be experienced in performing ESD. We recommend that highly experienced departments apply and promote this technology to provide a new alternative method for patients with small intestinal lipomas.

REFERENCES

- 1 **Wilson JM**, Melvin DB, Gray G, Thorbjarnarson B. Benign small bowel tumor. *Ann Surg* 1975; **181**: 247-250 [PMID: 1078626 DOI: 10.1097/0000658-197502000-00019]
- 2 **Zheng X**, Zuo N, Lin H, Zheng L, Ni M, Wu G, Chen J, Zhuo S. Margin diagnosis for endoscopic submucosal dissection of early gastric cancer using multiphoton microscopy. *Surg Endosc* 2020; **34**: 408-416 [PMID: 30972623 DOI: 10.1007/s00464-019-06783-1]
- 3 **Morimoto T**, Fu KI, Konuma H, Izumi Y, Matsuyama S, Ogura K, Miyazaki A, Watanabe S. Peeling a giant ileal lipoma with endoscopic unroofing and submucosal dissection. *World J Gastroenterol* 2010; **16**: 1676-1679 [PMID: 20355250 DOI: 10.3748/wjg.v16.i13.1676]
- 4 **Huang WH**, Peng CY, Yu CJ, Chou JW, Feng CL. Endoloop-assisted unroofing for the treatment of symptomatic duodenal lipomas. *Gastrointest Endosc* 2008; **68**: 1234-1236 [PMID: 19028236 DOI: 10.1016/j.gie.2008.03.003]
- 5 **Tahlan RN**, Garg P, Bishnoi PK, Singla SL. Mesenteric lipoma: an unusual cause of small intestinal volvulus. *Indian J Gastroenterol* 1997; **16**: 159 [PMID: 9357196]
- 6 **Nincheri Kunz M**, Evaristi L, Spadoni R, Cozzani R, Valle O, Bacigalupo B. [Lipoma of the small

- intestine as a rare cause of intestinal occlusion]. *Minerva Chir* 1994; **49**: 859-865 [PMID: 7991207]
- 7 **Yatagai N**, Ueyama H, Shibuya T, Haga K, Takahashi M, Nomura O, Sakamoto N, Osada T, Yao T, Watanabe S. Obscure gastrointestinal bleeding caused by small intestinal lipoma: a case report. *J Med Case Rep* 2016; **10**: 226 [PMID: 27520963 DOI: 10.1186/s13256-016-1014-4]
 - 8 **Oda I**, Gotoda T, Hamanaka H, Eguchi T, Saito Y, Matsuda T, Bhandari P, Emura F, Saito D, Ono H. Endoscopic submucosal dissection for early gastric cancer: Technical feasibility, operation time and complications from a large consecutive series. *Dig Endosc* 2017; **54**: 58 [DOI: 10.1111/j.1443-1661.2005.00459.x]
 - 9 **Gotoda T**. Endoscopic resection of early gastric cancer: the Japanese perspective. *Curr Opin Gastroenterol* 2006; **22**: 561-569 [PMID: 16891890 DOI: 10.1097/01.mog.0000239873.06243.00]
 - 10 **Gaspar JP**, Stelow EB, Wang AY. Approach to the endoscopic resection of duodenal lesions. *World J Gastroenterol* 2016; **22**: 600-617 [PMID: 26811610 DOI: 10.3748/wjg.v22.i2.600]
 - 11 **Yamamoto H**, Sugano K. A new method of enteroscopy--the double-balloon method. *Can J Gastroenterol* 2003; **17**: 273-274 [PMID: 12704472 DOI: 10.1155/2003/309532]
 - 12 **Yamamoto H**, Kita H, Sunada K, Hayashi Y, Sato H, Yano T, Iwamoto M, Sekine Y, Miyata T, Kuno A, Ajibe H, Ido K, Sugano K. Clinical outcomes of double-balloon endoscopy for the diagnosis and treatment of small-intestinal diseases. *Clin Gastroenterol Hepatol* 2004; **2**: 1010-1016 [PMID: 15551254 DOI: 10.1016/S1542-3565(04)00453-7]
 - 13 **May A**, Nachbar L, Ell C. Double-balloon enteroscopy (push-and-pull enteroscopy) of the small bowel: feasibility and diagnostic and therapeutic yield in patients with suspected small bowel disease. *Gastrointest Endosc* 2005; **62**: 62-70 [PMID: 15990821 DOI: 10.1016/S0016-5107(05)01586-5]
 - 14 **Tsujikawa T**, Saitoh Y, Andoh A, Imaeda H, Hata K, Minematsu H, Senoh K, Hayafuji K, Ogawa A, Nakahara T, Sasaki M, Fujiyama Y. Novel single-balloon enteroscopy for diagnosis and treatment of the small intestine: preliminary experiences. *Endoscopy* 2008; **40**: 11-15 [PMID: 18058613 DOI: 10.1055/s-2007-966976]
 - 15 **Zhang YF**, Ning SB, Li BR, Zhang J, Li J, Tang J, Zhu M, Jin XW, Zhao Q, Mao GP. Combined use of single-balloon enteroscope and colonoscope for self-expandable metal stent placement in patients with malignant small intestinal obstruction: a single-center comparative clinical observation. *J Huazhong Univ Sci Technolog Med Sci* 2017; **37**: 357-361 [PMID: 28585148 DOI: 10.1007/s11596-017-1740-x]
 - 16 **Ning S**, Zhang Y, Zu Z, Mao X, Mao G. Enteroscopic sclerotherapy in blue rubber bleb nevus syndrome. *Pak J Med Sci* 2015; **31**: 226-228 [PMID: 25878650 DOI: 10.12669/pjms.311.5858]
 - 17 **Yamashina T**, Hayashi Y, Sakamoto H, Yano T, Miura Y, Shinozaki S, Sunada K, Kawarai Lefor A, Yamamoto H. Balloon-assisted endoscopy facilitates endoscopic submucosal dissection of difficult superficial proximal colon tumors. *Endoscopy* 2018; **50**: 800-808 [PMID: 29433147 DOI: 10.1055/s-0044-100720]
 - 18 **Baskaran V**, Patnaik PK, Seth AK, Dogra R, Chaudhry R. Intestinal lipoma: a rare cause of lower gastrointestinal haemorrhage. *Trop Gastroenterol* 2003; **24**: 208-210 [PMID: 15164536]
 - 19 **Pezzoli A**, Pennazio M, Fusetti N, Simone L, Zelante A, Cifalà V, Sprujevnik T, Carella A, Gullini S. Occult intestinal haemorrhage due to lipoma of the small bowel detected with the combined use of the new endoscopic techniques. A report of two cases. *Dig Liver Dis* 2008; **40**: 306-309 [PMID: 18289948 DOI: 10.1016/j.dld.2007.02.004]
 - 20 **Chou JW**, Feng CL, Lai HC, Tsai CC, Chen SH, Hsu CH, Cheng KS, Peng CY, Chung PK. Obscure gastrointestinal bleeding caused by small bowel lipoma. *Intern Med* 2008; **47**: 1601-1603 [PMID: 18797119 DOI: 10.2169/internalmedicine.47.0963]
 - 21 **Toya Y**, Endo M, Orikasa S, Sugai T, Matsumoto T. Lipoma of the small intestine treated with endoscopic resection. *Clin J Gastroenterol* 2014; **7**: 502-505 [PMID: 25414085 DOI: 10.1007/s12328-014-0538-7]



Published by **Baishideng Publishing Group Inc**
7041 Koll Center Parkway, Suite 160, Pleasanton, CA 94566, USA

Telephone: +1-925-3991568

E-mail: bpgoffice@wjgnet.com

Help Desk: <https://www.f6publishing.com/helpdesk>

<https://www.wjgnet.com>

