

World Journal of *Clinical Cases*

World J Clin Cases 2021 March 6; 9(7): 1499-1760



Contents

Thrice Monthly Volume 9 Number 7 March 6, 2021

REVIEW

- 1499 Review of the risk factors for SARS-CoV-2 transmission

Li X, Xia WY, Jiang F, Liu DY, Lei SQ, Xia ZY, Wu QP

MINIREVIEWS

- 1513 Regulation of the expression of proinflammatory cytokines induced by SARS-CoV-2

Zhang XN, Wu LJ, Kong X, Zheng BY, Zhang Z, He ZW

ORIGINAL ARTICLE

Case Control Study

- 1524 Efficacy and safety of short duration radiotherapy combined with chemotherapy for advanced rectal cancer

Gao SQ, Zhang YC, Zhang C, Wang SJ, Ren W, Yuan N, Wen JY

Retrospective Study

- 1532 Effects of transjugular intrahepatic portosystemic shunt using the Viatorr stent on hepatic reserve function in patients with cirrhosis

Yao X, Zhou H, Huang S, Tang SH, Qin JP

- 1543 Primary and secondary postoperative hemorrhage in pediatric tonsillectomy

Xu B, Jin HY, Wu K, Chen C, Li L, Zhang Y, Gu WZ, Chen C

- 1554 Dynamic monitoring of serum liver function indexes in patients with COVID-19

Lin H, Wu LJ, Guo SQ, Chen RL, Fan JR, Ke B, Pan ZQ

- 1563 Construction of a clinical survival prognostic model for middle-aged and elderly patients with stage III rectal adenocarcinoma

Liu H, Li Y, Qu YD, Zhao JJ, Zheng ZW, Jiao XL, Zhang J

- 1580 Short-term outcomes of radiofrequency ablation for hepatocellular carcinoma using cone-beam computed tomography for planning and image guidance

Yao XS, Yan D, Jiang XX, Li X, Zeng HY, Li H

- 1592 Intra-arterial thrombolysis for early hepatic artery thrombosis after liver transplantation

Li T, Sun XD, Yu Y, Lv GY

- 1600 Study on pathogenic genes of dwarfism disease by next-generation sequencing

Yang LL, Liang SS

- 1610** Effects of cooperative nursing and patient education on postoperative infection and self-efficacy in gastrointestinal tumors

Qiao L, Zeng SQ, Zhang N

Observational Study

- 1619** Elevated soluble 4-1BB is associated with serum markers of hepatitis B virus in patients with chronic hepatitis B

Zhan MR, Gao XZ, Wang C, Peng F, Wang XM, Xu HQ, Niu JQ

CASE REPORT

- 1631** Balloon-assisted endoscopic submucosal dissection for treating small intestinal lipomas: Report of two cases

Chen HY, Ning SB, Yin X, Li BR, Zhang J, Jin XW, Sun T, Xia ZB, Zhang XP

- 1639** Dysphagia in a patient with ankylosing spondylitis: A case report

Wang XW, Zhang WZ

- 1646** Autologous scalp skin grafting to treat toxic epidermal necrolysis in a patient with a large skin injury: A case report

Xue DD, Zhou L, Yang Y, Ma SY

- 1654** Epstein-Barr virus-positive diffuse large B-cell lymphoma with human immunodeficiency virus mimicking complicated frontal sinusitis: A case report

Yoon S, Ryu KH, Baek HJ, An HJ, Joo YH

- 1661** Multiple well-differentiated retroperitoneal liposarcomas with different patterns of appearance on computed tomography: A case report

Xie TH, Ren XX, Fu Y, Ha SN, Liu LT, Jin XS

- 1668** Sarcomatoid carcinoma of the prostate with bladder invasion shortly after androgen deprivation: Two case reports

Wei W, Li QG, Long X, Hu GH, He HJ, Huang YB, Yi XL

- 1676** Metastatic thymic-enteric adenocarcinoma responding to chemoradiation plus anti-angiogenic therapy: A case report

Li M, Pu XY, Dong LH, Chang PY

- 1682** Solid pseudopapillary neoplasm-diagnostic approach and post-surgical follow up: Three case reports and review of literature

Abudalou M, Vega EA, Dhingra R, Holzwanger E, Krishnan S, Kondratiev S, Niakosari A, Conrad C, Stallwood CG

- 1696** Vancomycin-induced thrombocytopenia in endocarditis: A case report and review of literature

Guleng SR, Wu RH, Guo XB

- 1705** Human menstrual blood-derived stem cells as immunoregulatory therapy in COVID-19: A case report and review of the literature

Lu J, Xie ZY, Zhu DH, Li LJ

- 1714** Pure transvaginal natural orifice transluminal endoscopic surgery right hemicolectomy for colon cancer: A case report
Song ZJ, Shi YQ, Jiang YM, Liu K, Li Y, Wang CG, Zhao R
- 1720** Hyperglycemic hemianopia: A case report
Xiang XH, Fang JJ, Yang M, Zhao GH
- 1728** Mucinous appendiceal neoplasm: A case report
Chirca A, Negreanu L, Iliesiu A, Costea R
- 1734** Reconstructing abdominal wall defects with a free composite tissue flap: A case report
Wang J
- 1741** Mononeuropathy multiplex associated with systemic vasculitis: A case report
Chae HJ, Kim JW, Lee YL, Park JH, Lee SY
- 1748** Congenital fiber-type disproportion presenting with type II respiratory failure after delivery: A case report
Yang HM, Guo JX, Yang YM
- 1755** Use of three dimensional-printing in the management of floating aortic thrombus due to occult aortic dissection: A case report
Wang TH, Zhao JC, Xiong F, Yang Y

ABOUT COVER

Chin-Hsiao Tseng, MD, PhD, Full Professor, Department of Internal Medicine, National Taiwan University College of Medicine, No. 1 Jen Ai Road Section 1, Taipei 100, Taiwan. cckts@ms6.hinet.net

AIMS AND SCOPE

The primary aim of *World Journal of Clinical Cases* (WJCC, *World J Clin Cases*) is to provide scholars and readers from various fields of clinical medicine with a platform to publish high-quality clinical research articles and communicate their research findings online.

WJCC mainly publishes articles reporting research results and findings obtained in the field of clinical medicine and covering a wide range of topics, including case control studies, retrospective cohort studies, retrospective studies, clinical trials studies, observational studies, prospective studies, randomized controlled trials, randomized clinical trials, systematic reviews, meta-analysis, and case reports.

INDEXING/ABSTRACTING

The WJCC is now indexed in Science Citation Index Expanded (also known as SciSearch®), Journal Citation Reports/Science Edition, Scopus, PubMed, and PubMed Central. The 2020 Edition of Journal Citation Reports® cites the 2019 impact factor (IF) for WJCC as 1.013; IF without journal self cites: 0.991; Ranking: 120 among 165 journals in medicine, general and internal; and Quartile category: Q3. The WJCC's CiteScore for 2019 is 0.3 and Scopus CiteScore rank 2019: General Medicine is 394/529.

RESPONSIBLE EDITORS FOR THIS ISSUE

Production Editor: Yan-Xia Xing; **Production Department Director:** Yun-Xiaoqian Wu; **Editorial Office Director:** Jin-Li Wang.

NAME OF JOURNAL

World Journal of Clinical Cases

ISSN

ISSN 2307-8960 (online)

LAUNCH DATE

April 16, 2013

FREQUENCY

Thrice Monthly

EDITORS-IN-CHIEF

Dennis A Bloomfield, Sandro Vento, Bao-Gan Peng

EDITORIAL BOARD MEMBERS

<https://www.wjgnet.com/2307-8960/editorialboard.htm>

PUBLICATION DATE

March 6, 2021

COPYRIGHT

© 2021 Baishideng Publishing Group Inc

INSTRUCTIONS TO AUTHORS

<https://www.wjgnet.com/bpg/gerinfo/204>

GUIDELINES FOR ETHICS DOCUMENTS

<https://www.wjgnet.com/bpg/GerInfo/287>

GUIDELINES FOR NON-NATIVE SPEAKERS OF ENGLISH

<https://www.wjgnet.com/bpg/gerinfo/240>

PUBLICATION ETHICS

<https://www.wjgnet.com/bpg/GerInfo/288>

PUBLICATION MISCONDUCT

<https://www.wjgnet.com/bpg/gerinfo/208>

ARTICLE PROCESSING CHARGE

<https://www.wjgnet.com/bpg/gerinfo/242>

STEPS FOR SUBMITTING MANUSCRIPTS

<https://www.wjgnet.com/bpg/GerInfo/239>

ONLINE SUBMISSION

<https://www.f6publishing.com>



Autologous scalp skin grafting to treat toxic epidermal necrolysis in a patient with a large skin injury: A case report

Dong-Dong Xue, Ling Zhou, Yong Yang, Si-Yuan Ma

ORCID number: Dong-Dong Xue 0000-0003-1727-3497; Ling Zhou 0000-0002-2574-8483; Yong Yang 0000-0002-8525-8726; Si-Yuan Ma 0000-0002-3542-4490.

Author contributions: Xue DD, Zhou L and Yang Y contributed to the treatment, literature search and study design; Xue DD contributed to study conception and manuscript writing; Ma SY contributed to the treatment, study design and manuscript revision; all authors have read and approved the final manuscript.

Supported by: The State Key Laboratory of Trauma, Burns and Combined Injury, No. SKLJYJF18; and the First Affiliated Hospital, Army Medical University, No. SWH2019QNLC-04.

Informed consent statement: All study participants or their legal guardian provided informed written consent prior to study enrollment.

Conflict-of-interest statement: Dr. Ma reports grants from The State Key Laboratory of Trauma, Burns and Combined Injury, and grants from the First Affiliated Hospital, Army Medical University, during the conduct of the study.

CARE Checklist (2016) statement: The authors have read the CARE

Dong-Dong Xue, Ling Zhou, Yong Yang, Si-Yuan Ma, Southwest Hospital, Institute of Burn Research, Chongqing 400038, China

Corresponding author: Si-Yuan Ma, PhD, Attending Doctor, Southwest Hospital, Institute of Burn Research, No. 30 Gaotanyan Street, Shapingba District, Chongqing 400038, China. siyuan82@tmmu.edu.cn

Abstract

BACKGROUND

Toxic epidermal necrolysis (TEN) is often associated with skin wounds affecting large areas. Healing of this type of wound is difficult because of pressure, infection and other factors. It can increase the length of hospital stay and result in wound sepsis and even death.

CASE SUMMARY

A 49-year-old woman developed a skin lesion covering 80% of the total body surface area after using a kind of Chinese medicinal ointment on a burn wound on her back; she developed life-threatening wound sepsis and septic shock. Methicillin-resistant *Staphylococcus aureus*, carbapenem-resistant *Acinetobacter baumannii*, carbapenem-resistant *Pseudomonas aeruginosa* and other bacteria were cultured from wound tissue, deep venous catheter and blood samples. Imipenem cilastatin sodium, tigecycline and teicoplanin were used for anti-infection therapy. Finally, the patient was transferred to the burn department because of severe wound sepsis. In the burn intensive care unit, pain-free dressing changes and autologous scalp skin grafting were performed to heal the wound in addition to reasonable and effective antibacterial treatment according to microbial susceptibility test results. After three operations within 2 wk, the wound healed and sepsis resolved.

CONCLUSION

TEN patients with large areas of skin injury may develop wound infection and life-threatening wound sepsis. Autologous scalp skin grafting may be beneficial for rapid wound healing and reducing the risk of sepsis in TEN patients, and it leaves no scar at the donor site.

Key Words: Toxic epidermal necrolysis; Wound sepsis; Autologous skin grafting; Scalp; Burn; Case report

Checklist (2016), and the manuscript was prepared and revised according to the CARE Checklist (2016).

Open-Access: This article is an open-access article that was selected by an in-house editor and fully peer-reviewed by external reviewers. It is distributed in accordance with the Creative Commons Attribution NonCommercial (CC BY-NC 4.0) license, which permits others to distribute, remix, adapt, build upon this work non-commercially, and license their derivative works on different terms, provided the original work is properly cited and the use is non-commercial. See: <http://creativecommons.org/licenses/by-nc/4.0/>

Manuscript source: Unsolicited manuscript

Specialty type: Medicine, research and experimental

Country/Territory of origin: China

Peer-review report's scientific quality classification

Grade A (Excellent): 0
Grade B (Very good): B, B
Grade C (Good): 0
Grade D (Fair): 0
Grade E (Poor): 0

Received: August 4, 2020

Peer-review started: August 4, 2020

First decision: November 8, 2020

Revised: November 26, 2020

Accepted: December 10, 2020

Article in press: December 10, 2020

Published online: March 6, 2021

P-Reviewer: Morozov S

S-Editor: Chen XF

L-Editor: Filipodia

P-Editor: Wang LYT



©The Author(s) 2021. Published by Baishideng Publishing Group Inc. All rights reserved.

Core Tip: Toxic epidermal necrolysis is often associated with large skin wound areas. Healing the wound is difficult because of pressure, infection and other factors. Autologous scalp skin grafting may be a good option to promote rapid wound healing and reduce the risk of wound sepsis.

Citation: Xue DD, Zhou L, Yang Y, Ma SY. Autologous scalp skin grafting to treat toxic epidermal necrolysis in a patient with a large skin injury: A case report. *World J Clin Cases* 2021; 9(7): 1646-1653

URL: <https://www.wjgnet.com/2307-8960/full/v9/i7/1646.htm>

DOI: <https://dx.doi.org/10.12998/wjcc.v9.i7.1646>

INTRODUCTION

Toxic epidermal necrolysis (TEN) is considered a delayed allergic drug reaction that often manifests as fever and painful local erythema at onset, spreads quickly and causes slack bullae or epidermal peeling. Nikolsky's sign can be observed in patients, and extensive skin and mucous membrane erosion [skin injury area > 30% of total body surface area (TBSA) involvement] generally occurs within 24-72 h but can develop as long as 4-28 d after drug exposure^[1,2]. Almost any drug can cause a drug rash^[3]. When the skin injury area is large, at more than 50% TBSA, the condition is extremely serious and is considered a dermatological emergency, as it is associated with high risks of death and disability^[4-6]. The risk of mortality increases with increasing surface area involvement, and a meta-analysis of the literature showed the mortality risk to be between 16% and 55%^[7]. It becomes difficult to heal the wound because of pressure, infection and other factors^[8-10]. It eventually increases the length of hospital stay and can result in wound sepsis and even death. Thus, in such patients, guidance on how to promote quickly wound healing and reduce the occurrence of wound infection and systemic infection would be beneficial for designing treatment regimens. Dry exposed therapy, dressing changes, topical antibiotics and new-type dressings are often used to prevent secondary infections^[11]. In this report, the case of a patient with severe TEN with an 80% TBSA skin injury and wound sepsis treated by autologous scalp skin grafting is presented (Figure 1). The use of the patient's personal information and medical data in our manuscript has been approved by the Ethics Committee of the First Affiliated Hospital of Army Medical University.

CASE PRESENTATION

Chief complaints

A woman aged 49 years who suffered from a superficial partial-thickness steam burn (1% TBSA) was admitted to the hospital for a red rash that appeared locally on the back and elsewhere, such as the face and neck, after using a kind of Chinese medicinal ointment on the burn wound on her back.

History of present illness

Initially, the local hospital diagnosed the patient's condition as folliculitis, shingles or chickenpox and treated the patient with various drugs, including erythromycin and acyclovir. Her condition gradually worsened, with systemic rash development; blister formation; wide-spread peeling of the skin, mucosa and other epithelial tissue; dermis exposure and a high fever within 96 h. On the 8th d after onset, the patient was urgently transferred to the Dermatology Department at our hospital.

Physical examination

The patient presented with typical rash and lesion morphology, suggestive of a delayed drug allergic reaction (fever, painful local erythema at onset, slack bullae or epidermal peeling), Nikolsky's sign, extensive skin and mucous membrane erosion and skin injury covering approximately 80% of the TBSA (Figure 2).

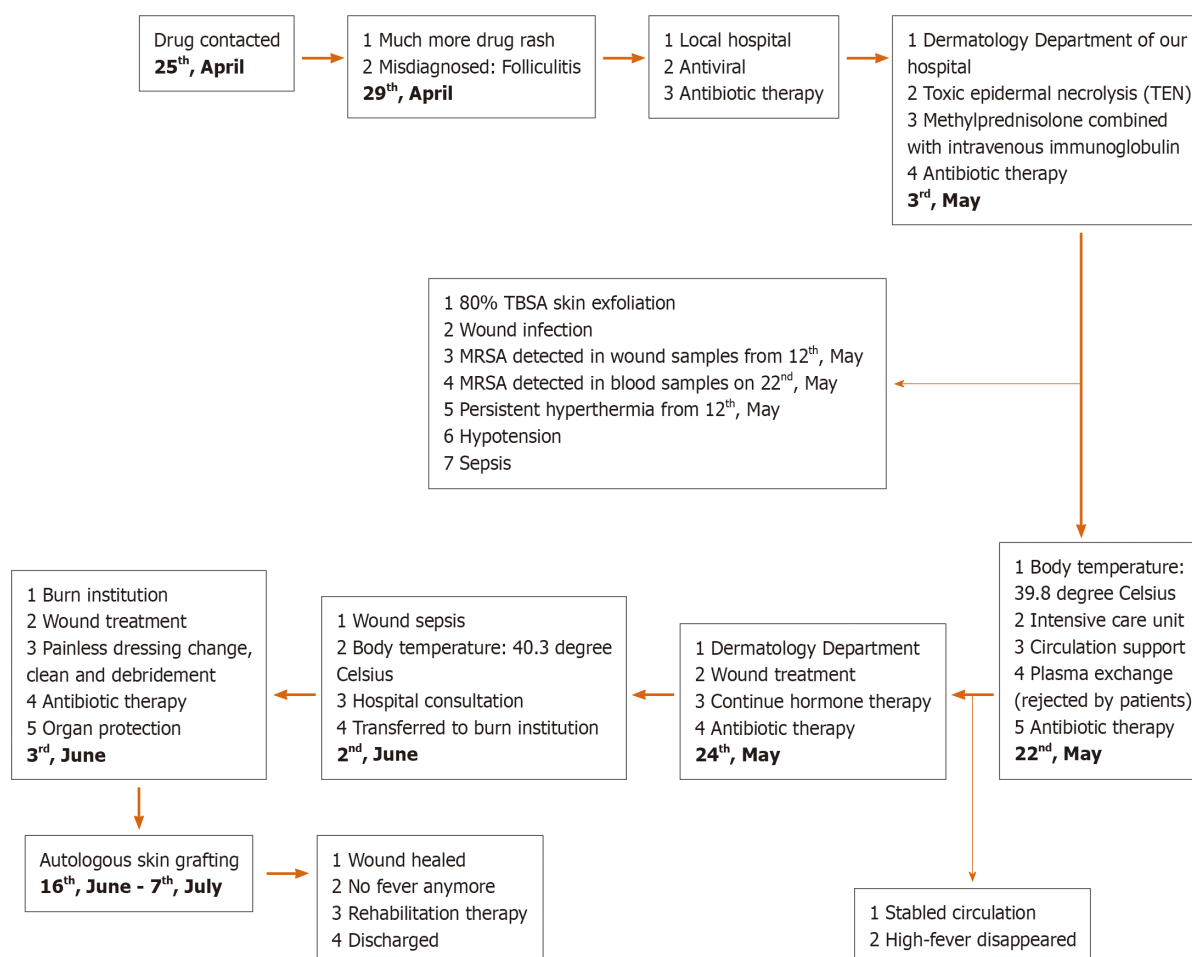


Figure 1 Timeline of the case, from drug contact to wound healing and rehabilitation, including treatment for toxic epidermal necrolysis and wound sepsis. MRSA: Methicillin-resistant *Staphylococcus aureus*; TBSA: Total body surface area; TEN: Toxic epidermal necrolysis.

FINAL DIAGNOSIS

The diagnosis was confirmed to be TEN according to typical rash and lesion morphologies and the patient's medical history.

TREATMENT

After prednisone pulse therapy, immunoglobulin fortification and anti-infection therapy, the rash was controlled, but damaged skin still covered approximately 80% of the TBSA. Wound healing was a challenge due to pressure and infection; subsequently, wound sepsis and systemic infection developed.

Methicillin-resistant *Staphylococcus aureus*, carbapenem-resistant *Acinetobacter baumannii*, carbapenem-resistant *Pseudomonas aeruginosa* and other bacteria were cultured from wound tissue, deep venous catheter and blood samples. The intensive care unit of our hospital recommended plasma exchange treatment, but the patient refused it. After fluid therapy, norepinephrine for circulation maintenance, a combined antibiotic regimen for anti-infection therapy [imipenem and cilastatin sodium (1000 mg every 8 h) combined with tigecycline (500 mg every 12 h)], organ function protection therapies and water and electrolyte balance correction, the woman's vital signs stabilized. After a hospital-wide discussion, the patient was finally transferred to the burn intensive care unit (BICU) because of the size of the wound and severe wound sepsis. In the BICU, we gradually reduced the steroid dose, performed additional microbiological investigations and strengthened anti-infection therapy. We particularly emphasized wound treatment. A Stryker frame was used to turn the body every 4 h (1/4 h) to reduce pressure and moisture on the back wound. Painless

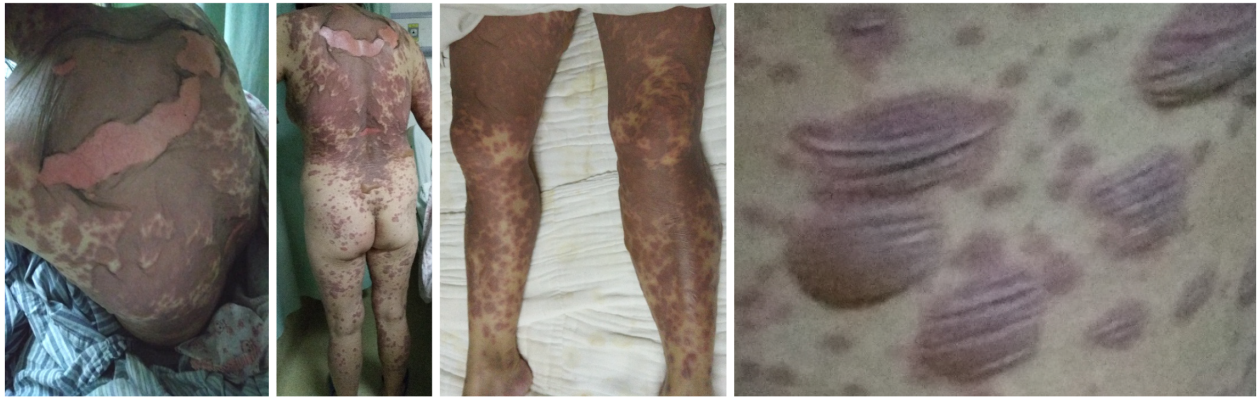
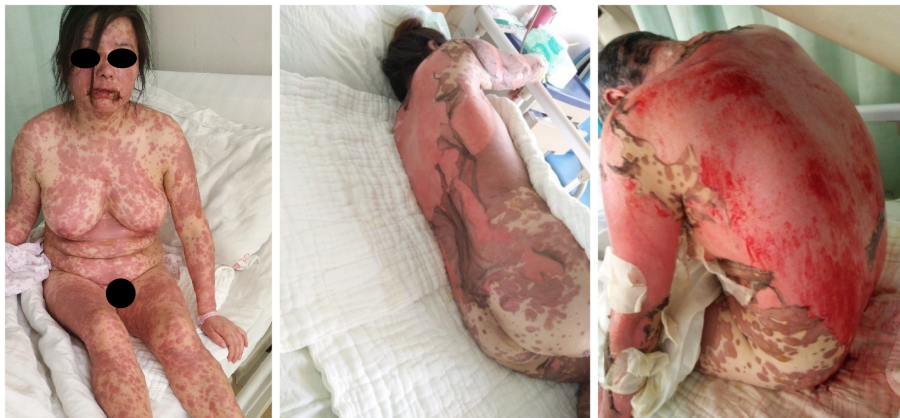The 9th dayThe 19th day

Figure 2 Skin injury involving drug rash with blister formation, wide-spread peeling and exposed dermis on the 9th d (4 May) and 19th d (14 May) after onset.

dressing changes under surgical anesthesia were conducted for thorough wound cleaning, including wound necrotic tissue removal. Mupirocin and epidermal growth factor were used to improve the wound bed. We also strengthened the management of various catheters, including the central venous catheter, tracheal tube, urinary catheter and nutrition support tube and provided psychological counseling and rehabilitation training (Figure 1).

When the general condition of the patient met the requirement for skin grafting, wound debridement and skin grafting were performed (Figures 3 and 4). Split-thickness scalp skin was used as an autologous skin source. The skin transplantation procedure was divided into two parts that were performed simultaneously. In one part, edematous granulation tissue and necrotic tissue were scraped off with a scalpel and repeatedly rinsed with hydrogen peroxide (0.1%) and normal saline three times. Gauze soaked with 1:20000 epinephrine solution was used to stop bleeding for 5 min. In the other part, normal saline containing 1:200000 epinephrine was injected into the scalp to promote skin swelling, resulting in hemostasis. A razor-thin slice of skin was cut with an air-driven dermatome, and the donor area of the head was covered with Vaseline and gauze; the multi-layer sterile dressing was applied under pressure. After cleaning with sterile normal saline, the split-thickness skin was cut into stamp-like pieces sized 0.5 cm × 0.5 cm; finally, the stamp-like skin from the scalp was transplanted onto the wound and bandaged with gauze.

OUTCOME AND FOLLOW-UP

After autologous scalp-skin grafting, all the wounds healed within 2 wk, and the infection indicators and vital signs returned to normal (Figure 5). The patient was discharged, with no recurrent wound infection or skin injury.

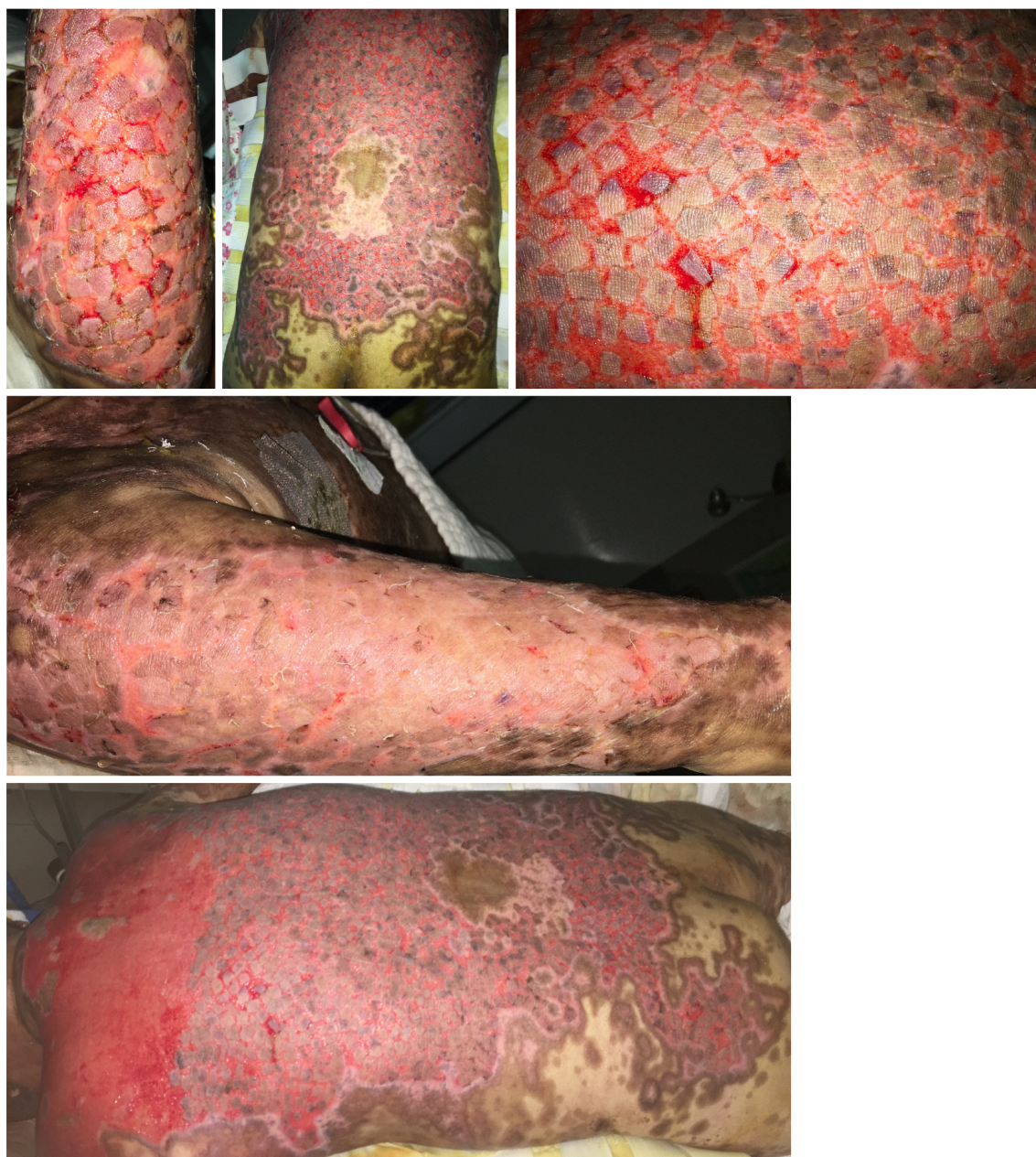


Figure 3 Wound healing after autografting on the back, buttocks and arms by stamp skin grafting after harvesting split-thickness skin grafts from the patient's scalp under general anesthesia.

DISCUSSION

Treatment of skin and mucosal wounds is important in TEN patients with large skin lesions over 50% of the TBSA. Studies have shown that when large areas of the skin are damaged, impaired skin barrier function can lead to electrolyte disturbance, hypermetabolism, excessive fluid exudation and increased risk of infection^[12]. However, many factors, such as pressure, infection, nutrition and immune status, may lead to deepening of the wound surface, resulting in healing difficulty or even no healing^[13,14]. How to prevent and treat wound deepening is important. Wound cleaning, debridement and drainage, frequent changes in body position to prevent wound pressure and moisture, regular dressing changes and the selection of appropriate new functional dressings are useful treatment strategies to promote wound healing^[15,16]. New antibacterial dressings containing silver ions, biological materials and allogeneic skin dressings have been demonstrated to be beneficial in wound healing^[17-19].

In the case presented here, more than 80% of the patient's skin wound was exposed

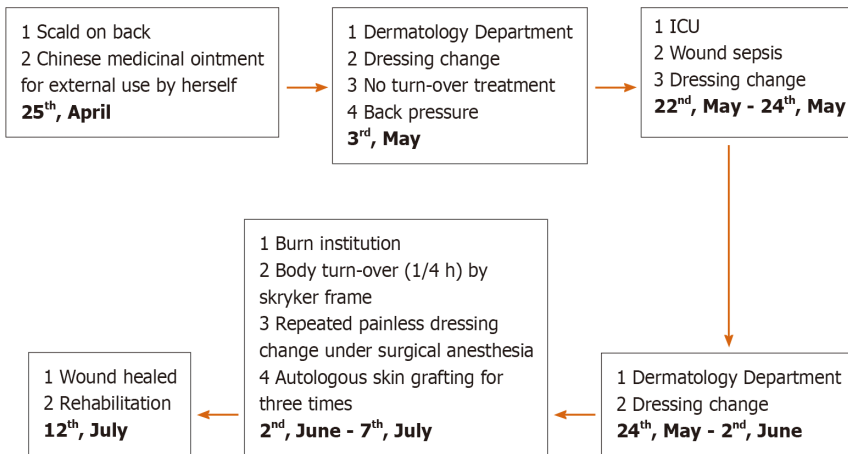


Figure 4 Wound treatment flowchart of main treatments, including external Chinese medicinal ointment use, dressing changes and debridement under surgical anesthesia, autologous skin grafting and rehabilitation. ICU: Intensive care unit.

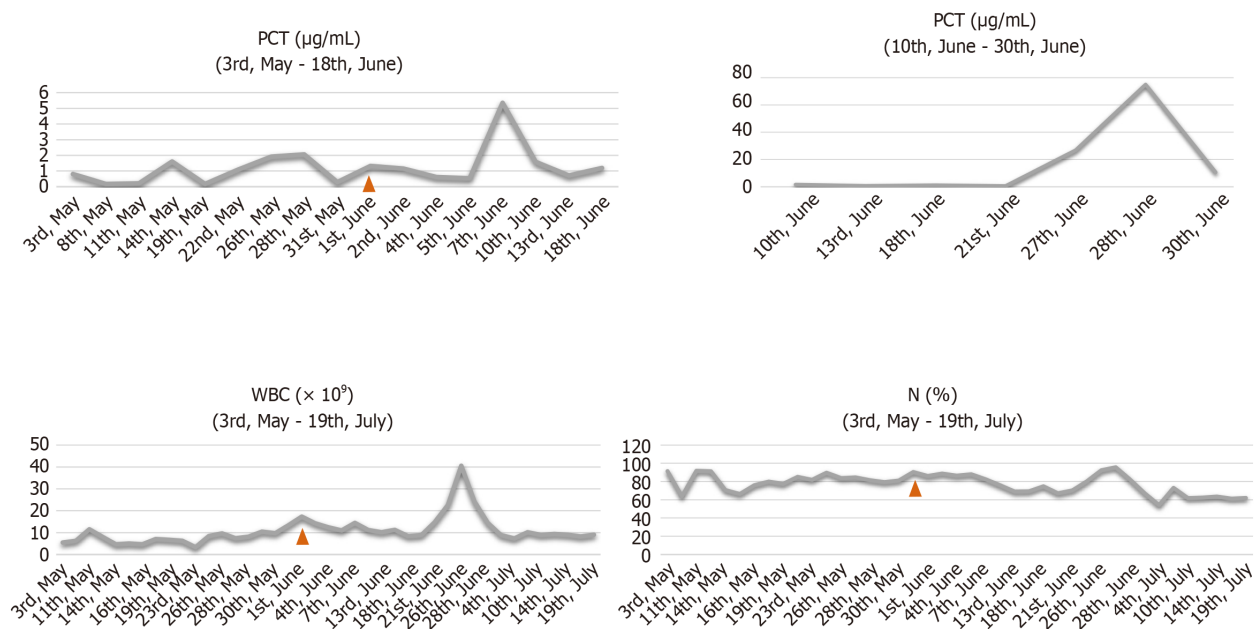


Figure 5 Trend chart of procalcitonin, white blood cell count and neutrophil percentage during the process of wound sepsis treatment. Infection indicators of wound sepsis increased significantly. When all the wounds were healed, the infection indicators gradually returned to normal. N: Neutrophils; PCT: Procalcitonin; WBC: White blood cell.

and infected, making healing difficult. Moreover, the patient eventually developed wound sepsis. For this patient, how to heal the wound quickly and effectively became the priority. Autologous skin grafting was performed as an alternative surgical treatment for rapid wound healing. Autologous skin grafting is a method of surgically harvesting the patient's own skin with skin cutting tools and then transplanting it onto a wound to promote rapid healing of the wound. Because of its strong regenerative ability, the scalp can heal with no scar after split-thickness skin is harvested. Skin harvesting from other donor body sites will produce scars, which will affect the appearance, feeling and function of the skin. Moreover, the scalp, as the donor site, can repeatedly supply split-thickness skin grafts up to 10 times. Autologous scalp-skin grafting provides a good alternative to surgical repair of large-area skin wound. The scalp generally produces no scarring at the donor site after healing. Additionally, combined with reasonable skin expansion techniques, such as postage stamp skin grafting (the skin expansion ratio is about 1:2 to 1:4) and Meek grafting (the skin expansion ratio is about 1:9)^[20], the coverage area of the wound was enlarged.

CONCLUSION

In TEN patients, when the wound has difficulty healing due to pressure, infection or other factors, autologous scalp skin grafting may be helpful in shortening hospitalization durations, reducing complications and preventing mortality.

REFERENCES

- 1 Carrasquillo OY, Santiago-Vazquez M, Cardona R, Cruz-Manzano M, Figueroa LD. Stevens-Johnson syndrome and toxic epidermal necrolysis: a retrospective descriptive study. *Int J Dermatol* 2019; **58**: 1293-1299 [PMID: 31166019 DOI: 10.1111/ijd.14493]
- 2 Bequignon E, Duong TA, Sbidian E, Valeyrie-Allanore L, Ingen-Housz-Oro S, Chatelin V, Coste A, Wolkenstein P, Chosidow O, Papon JF. Stevens-Johnson syndrome and toxic epidermal necrolysis: ear, nose, and throat description at acute stage and after remission. *JAMA Dermatol* 2015; **151**: 302-307 [PMID: 25671761 DOI: 10.1001/jamadermatol.2014.4844]
- 3 Gerull R, Nelle M, Schaible T. Toxic epidermal necrolysis and Stevens-Johnson syndrome: a review. *Crit Care Med* 2011; **39**: 1521-1532 [PMID: 21358399 DOI: 10.1097/CCM.0b013e31821201ed]
- 4 Nizamoglu M, Ward JA, Frew Q, Gerrish H, Martin N, Shaw A, Barnes D, Shelly O, Philp B, El-Muttardi N, Dziewulski P. Improving mortality outcomes of Stevens Johnson syndrome/toxic epidermal necrolysis: A regional burns centre experience. *Burns* 2018; **44**: 603-611 [PMID: 29029855 DOI: 10.1016/j.burns.2017.09.015]
- 5 McCullough M, Burg M, Lin E, Peng D, Garner W. Steven Johnson Syndrome and Toxic Epidermal Necrolysis in a burn unit: A 15-year experience. *Burns* 2017; **43**: 200-205 [PMID: 27554629 DOI: 10.1016/j.burns.2016.07.026]
- 6 Antoon JW, Goldman JL, Lee B, Schwartz A. Incidence, outcomes, and resource use in children with Stevens-Johnson syndrome and toxic epidermal necrolysis. *Pediatr Dermatol* 2018; **35**: 182-187 [PMID: 29315761 DOI: 10.1111/pde.13383]
- 7 Abela C, Hartmann CE, De Leo A, de Sica Chapman A, Shah H, Jawad M, Bunker CB, Williams GJ, Leon-Villapalos J. Toxic epidermal necrolysis (TEN): the Chelsea and Westminster Hospital wound management algorithm. *J Plast Reconstr Aesthet Surg* 2014; **67**: 1026-1032 [PMID: 24860933 DOI: 10.1016/j.bjps.2014.04.003]
- 8 Li J, Mao M, Tang N, Zhai R, Zhu W, Yi M, Chen M. [Clinical characteristics and prognosis for 126 patients with severe drug eruption]. *Zhong Nan Da Xue Xue Bao Yi Xue Ban* 2017; **42**: 953-957 [PMID: 28872088 DOI: 10.11817/j.issn.1672-7347.2017.08.013]
- 9 Papp A, Sikora S, Evans M, Song D, Kirchhof M, Miliszewski M, Dutz J. Treatment of toxic epidermal necrolysis by a multidisciplinary team. A review of literature and treatment results. *Burns* 2018; **44**: 807-815 [PMID: 29627131 DOI: 10.1016/j.burns.2017.10.022]
- 10 Lerch M, Mainetti C, Terziroli Beretta-Piccoli B, Harr T. Current Perspectives on Stevens-Johnson Syndrome and Toxic Epidermal Necrolysis. *Clin Rev Allergy Immunol* 2018; **54**: 147-176 [PMID: 29188475 DOI: 10.1007/s12016-017-8654-z]
- 11 Mahar PD, Wasiak J, Hii B, Cleland H, Watters DA, Gin D, Spinks AB. A systematic review of the management and outcome of toxic epidermal necrolysis treated in burns centres. *Burns* 2014; **40**: 1245-1254 [PMID: 24685065 DOI: 10.1016/j.burns.2014.02.006]
- 12 Rowan MP, Cancio LC, Elster EA, Burnmeister DM, Rose LF, Natesan S, Chan RK, Christy RJ, Chung KK. Burn wound healing and treatment: review and advancements. *Crit Care* 2015; **19**: 243 [PMID: 26067660 DOI: 10.1186/s13054-015-0961-2]
- 13 Han G, Ceilley R. Chronic Wound Healing: A Review of Current Management and Treatments. *Adv Ther* 2017; **34**: 599-610 [PMID: 28108895 DOI: 10.1007/s12325-017-0478-y]
- 14 Sekiguchi A, Motegi SI, Uchiyama A, Uehara A, Fujiwara C, Yamazaki S, Perera B, Nakamura H, Ogino S, Yokoyama Y, Akai R, Iwawaki T, Ishikawa O. Botulinum toxin B suppresses the pressure ulcer formation in cutaneous ischemia-reperfusion injury mouse model: Possible regulation of oxidative and endoplasmic reticulum stress. *J Dermatol Sci* 2018; **90**: 144-153 [PMID: 29402605 DOI: 10.1016/j.jdermsci.2018.01.006]
- 15 Obagi Z, Damiani G, Grada A, Falanga V. Principles of Wound Dressings: A Review. *Surg Technol Int* 2019; **35**: 50-57 [PMID: 31480092]
- 16 Childs DR, Murthy AS. Overview of Wound Healing and Management. *Surg Clin North Am* 2017; **97**: 189-207 [PMID: 27894427 DOI: 10.1016/j.suc.2016.08.013]
- 17 Young JB, Gondek SP, Troche M, Summitt JB, Rae L, Thayer WP, Kahn SA. The use of porcine xenografts in patients with toxic epidermal necrolysis. *Burns* 2016; **42**: 1728-1733 [PMID: 27350163 DOI: 10.1016/j.burns.2016.06.003]
- 18 Paggiaro AO, E Silva Filho ML, de Carvalho VF, Isaac C, Gemperli R. The Role of Biological Skin Substitutes in Stevens-Johnson Syndrome: Systematic Review. *Plast Surg Nurs* 2018; **38**: 121-127 [PMID: 30157125 DOI: 10.1097/PSN.0000000000000234]
- 19 Lee HY. Wound management strategies in Stevens-Johnson syndrome/toxic epidermal necrolysis: An unmet need. *J Am Acad Dermatol* 2018; **79**: e87-e88 [PMID: 29913262 DOI: 10.1016/j.jaad.2018.05.1258]
- 20 Quintero EC, Machado JFE, Robles RAD. Meek micrografting history, indications, technique,

physiology and experience: a review article. *J Wound Care* 2018; **27**: S12-S18 [PMID: [29419365](#)
DOI: [10.12968/jowc.2018.27.Sup2.S12](#)]



Published by **Baishideng Publishing Group Inc**
7041 Koll Center Parkway, Suite 160, Pleasanton, CA 94566, USA

Telephone: +1-925-3991568

E-mail: bpgoffice@wjgnet.com

Help Desk: <https://www.f6publishing.com/helpdesk>

<https://www.wjgnet.com>

