

# World Journal of *Clinical Cases*

*World J Clin Cases* 2021 March 6; 9(7): 1499-1760



## Contents

Thrice Monthly Volume 9 Number 7 March 6, 2021

## REVIEW

- 1499 Review of the risk factors for SARS-CoV-2 transmission

*Li X, Xia WY, Jiang F, Liu DY, Lei SQ, Xia ZY, Wu QP*

## MINIREVIEWS

- 1513 Regulation of the expression of proinflammatory cytokines induced by SARS-CoV-2

*Zhang XN, Wu LJ, Kong X, Zheng BY, Zhang Z, He ZW*

## ORIGINAL ARTICLE

## Case Control Study

- 1524 Efficacy and safety of short duration radiotherapy combined with chemotherapy for advanced rectal cancer

*Gao SQ, Zhang YC, Zhang C, Wang SJ, Ren W, Yuan N, Wen JY*

## Retrospective Study

- 1532 Effects of transjugular intrahepatic portosystemic shunt using the Viatorr stent on hepatic reserve function in patients with cirrhosis

*Yao X, Zhou H, Huang S, Tang SH, Qin JP*

- 1543 Primary and secondary postoperative hemorrhage in pediatric tonsillectomy

*Xu B, Jin HY, Wu K, Chen C, Li L, Zhang Y, Gu WZ, Chen C*

- 1554 Dynamic monitoring of serum liver function indexes in patients with COVID-19

*Lin H, Wu LJ, Guo SQ, Chen RL, Fan JR, Ke B, Pan ZQ*

- 1563 Construction of a clinical survival prognostic model for middle-aged and elderly patients with stage III rectal adenocarcinoma

*Liu H, Li Y, Qu YD, Zhao JJ, Zheng ZW, Jiao XL, Zhang J*

- 1580 Short-term outcomes of radiofrequency ablation for hepatocellular carcinoma using cone-beam computed tomography for planning and image guidance

*Yao XS, Yan D, Jiang XX, Li X, Zeng HY, Li H*

- 1592 Intra-arterial thrombolysis for early hepatic artery thrombosis after liver transplantation

*Li T, Sun XD, Yu Y, Lv GY*

- 1600 Study on pathogenic genes of dwarfism disease by next-generation sequencing

*Yang LL, Liang SS*

- 1610** Effects of cooperative nursing and patient education on postoperative infection and self-efficacy in gastrointestinal tumors

*Qiao L, Zeng SQ, Zhang N*

### Observational Study

- 1619** Elevated soluble 4-1BB is associated with serum markers of hepatitis B virus in patients with chronic hepatitis B

*Zhan MR, Gao XZ, Wang C, Peng F, Wang XM, Xu HQ, Niu JQ*

### CASE REPORT

- 1631** Balloon-assisted endoscopic submucosal dissection for treating small intestinal lipomas: Report of two cases

*Chen HY, Ning SB, Yin X, Li BR, Zhang J, Jin XW, Sun T, Xia ZB, Zhang XP*

- 1639** Dysphagia in a patient with ankylosing spondylitis: A case report

*Wang XW, Zhang WZ*

- 1646** Autologous scalp skin grafting to treat toxic epidermal necrolysis in a patient with a large skin injury: A case report

*Xue DD, Zhou L, Yang Y, Ma SY*

- 1654** Epstein-Barr virus-positive diffuse large B-cell lymphoma with human immunodeficiency virus mimicking complicated frontal sinusitis: A case report

*Yoon S, Ryu KH, Baek HJ, An HJ, Joo YH*

- 1661** Multiple well-differentiated retroperitoneal liposarcomas with different patterns of appearance on computed tomography: A case report

*Xie TH, Ren XX, Fu Y, Ha SN, Liu LT, Jin XS*

- 1668** Sarcomatoid carcinoma of the prostate with bladder invasion shortly after androgen deprivation: Two case reports

*Wei W, Li QG, Long X, Hu GH, He HJ, Huang YB, Yi XL*

- 1676** Metastatic thymic-enteric adenocarcinoma responding to chemoradiation plus anti-angiogenic therapy: A case report

*Li M, Pu XY, Dong LH, Chang PY*

- 1682** Solid pseudopapillary neoplasm-diagnostic approach and post-surgical follow up: Three case reports and review of literature

*Abudalou M, Vega EA, Dhingra R, Holzwanger E, Krishnan S, Kondratiev S, Niakosari A, Conrad C, Stallwood CG*

- 1696** Vancomycin-induced thrombocytopenia in endocarditis: A case report and review of literature

*Guleng SR, Wu RH, Guo XB*

- 1705** Human menstrual blood-derived stem cells as immunoregulatory therapy in COVID-19: A case report and review of the literature

*Lu J, Xie ZY, Zhu DH, Li LJ*

- 1714** Pure transvaginal natural orifice transluminal endoscopic surgery right hemicolectomy for colon cancer: A case report  
*Song ZJ, Shi YQ, Jiang YM, Liu K, Li Y, Wang CG, Zhao R*
- 1720** Hyperglycemic hemianopia: A case report  
*Xiang XH, Fang JJ, Yang M, Zhao GH*
- 1728** Mucinous appendiceal neoplasm: A case report  
*Chirca A, Negreanu L, Iliesiu A, Costea R*
- 1734** Reconstructing abdominal wall defects with a free composite tissue flap: A case report  
*Wang J*
- 1741** Mononeuropathy multiplex associated with systemic vasculitis: A case report  
*Chae HJ, Kim JW, Lee YL, Park JH, Lee SY*
- 1748** Congenital fiber-type disproportion presenting with type II respiratory failure after delivery: A case report  
*Yang HM, Guo JX, Yang YM*
- 1755** Use of three dimensional-printing in the management of floating aortic thrombus due to occult aortic dissection: A case report  
*Wang TH, Zhao JC, Xiong F, Yang Y*

**ABOUT COVER**

Chin-Hsiao Tseng, MD, PhD, Full Professor, Department of Internal Medicine, National Taiwan University College of Medicine, No. 1 Jen Ai Road Section 1, Taipei 100, Taiwan. cckts@ms6.hinet.net

**AIMS AND SCOPE**

The primary aim of *World Journal of Clinical Cases* (WJCC, *World J Clin Cases*) is to provide scholars and readers from various fields of clinical medicine with a platform to publish high-quality clinical research articles and communicate their research findings online.

WJCC mainly publishes articles reporting research results and findings obtained in the field of clinical medicine and covering a wide range of topics, including case control studies, retrospective cohort studies, retrospective studies, clinical trials studies, observational studies, prospective studies, randomized controlled trials, randomized clinical trials, systematic reviews, meta-analysis, and case reports.

**INDEXING/ABSTRACTING**

The WJCC is now indexed in Science Citation Index Expanded (also known as SciSearch®), Journal Citation Reports/Science Edition, Scopus, PubMed, and PubMed Central. The 2020 Edition of Journal Citation Reports® cites the 2019 impact factor (IF) for WJCC as 1.013; IF without journal self cites: 0.991; Ranking: 120 among 165 journals in medicine, general and internal; and Quartile category: Q3. The WJCC's CiteScore for 2019 is 0.3 and Scopus CiteScore rank 2019: General Medicine is 394/529.

**RESPONSIBLE EDITORS FOR THIS ISSUE**

**Production Editor:** Yan-Xia Xing; **Production Department Director:** Yun-Xiaoqian Wu; **Editorial Office Director:** Jin-Li Wang.

**NAME OF JOURNAL**

*World Journal of Clinical Cases*

**ISSN**

ISSN 2307-8960 (online)

**LAUNCH DATE**

April 16, 2013

**FREQUENCY**

Thrice Monthly

**EDITORS-IN-CHIEF**

Dennis A Bloomfield, Sandro Vento, Bao-Gan Peng

**EDITORIAL BOARD MEMBERS**

<https://www.wjgnet.com/2307-8960/editorialboard.htm>

**PUBLICATION DATE**

March 6, 2021

**COPYRIGHT**

© 2021 Baishideng Publishing Group Inc

**INSTRUCTIONS TO AUTHORS**

<https://www.wjgnet.com/bpg/gerinfo/204>

**GUIDELINES FOR ETHICS DOCUMENTS**

<https://www.wjgnet.com/bpg/GerInfo/287>

**GUIDELINES FOR NON-NATIVE SPEAKERS OF ENGLISH**

<https://www.wjgnet.com/bpg/gerinfo/240>

**PUBLICATION ETHICS**

<https://www.wjgnet.com/bpg/GerInfo/288>

**PUBLICATION MISCONDUCT**

<https://www.wjgnet.com/bpg/gerinfo/208>

**ARTICLE PROCESSING CHARGE**

<https://www.wjgnet.com/bpg/gerinfo/242>

**STEPS FOR SUBMITTING MANUSCRIPTS**

<https://www.wjgnet.com/bpg/GerInfo/239>

**ONLINE SUBMISSION**

<https://www.f6publishing.com>



## Vancomycin-induced thrombocytopenia in endocarditis: A case report and review of literature

Si-Ri Guleng, Ri-Han Wu, Xiao-Bin Guo

**ORCID number:** Si Ri Guleng 0000-0003-0705-1153; Ri-Han Wu 0000-0003-3878-4843; Xiao-Bin Guo 0000-0003-2733-5399.

**Author contributions:** Guleng SR and Wu RH collected the case information and drafted the manuscript; Guleng SR and Guo XB analyzed the data and revised the manuscript; all authors issued the final approval for the version to be submitted.

**Supported by** The Inner Mongolia Autonomous Region People's Hospital Training Talent Research Start-up Fund, No. BS201703.

**Informed consent statement:** An informed written consent was obtained from the patient for the publication of this report and any accompanying images.

**Conflict-of-interest statement:** The authors declare that they have no conflict of interest.

**CARE Checklist (2016) statement:** The authors have read the CARE Checklist (2016), and the manuscript was prepared and revised according to the CARE Checklist (2016).

**Open-Access:** This article is an open-access article that was selected by an in-house editor and fully peer-reviewed by external

**Si-Ri Guleng, Ri-Han Wu, Xiao-Bin Guo**, Department of Pharmacy, Inner Mongolia Autonomous Region People's Hospital, Hohhot 010010, Inner Mongolia Autonomous, China

**Corresponding author:** Si-Ri Guleng, PhD, Chief Doctor, Department of Pharmacy, Inner Mongolia Autonomous Region People's Hospital, No. 20 Zhaowuda Road, Saihan District, Hohhot 010010, Inner Mongolia Autonomous, China. [srgl985@126.com](mailto:srgl985@126.com)

### Abstract

#### BACKGROUND

Thrombocytopenia is a serious complication in the medical practice of numerous drugs. Vancomycin is frequently used for the prophylaxis and treatment of suspected or identified methicillin-resistant positive infections. Several cases with vancomycin-induced thrombocytopenia (VIT) have been reported. However, these have rarely been extensively reviewed. The present report describes a case of VIT in endocarditis, and reviews all VIT cases reported in the literature.

#### CASE SUMMARY

A 26-year-old male diagnosed with infective endocarditis was admitted. The patient was treated with multiple drugs, including vancomycin, which was initially intravenously given at 1000 mg every 12 h and subsequently at 500 mg every 8 h on day 3. On day 11, the platelet count decreased to  $51 \times 10^9/L$ , vancomycin was switched to 500 mg every 12 h, and platelet transfusion was given. On day 17, the platelet count dropped to  $27 \times 10^9/L$ , and platelet transfusion was administered again. On day 23, vancomycin was adjusted to 500 mg every 8 h as the trough concentration dropped to the minimum effective concentration. On day 33, the platelet count declined to approximately  $40 \times 10^9/L$ . After platelet transfusion, the platelet count rebounded to  $90 \times 10^9/L$  on day 35 but dropped again to  $42 \times 10^9/L$  on day 43. Based on the time-to-platelet count curve and Naranjo's Adverse Drug Reaction Probability Scale score, VIT was suspected. After vancomycin discontinuation and platelet transfusion, the platelet count gradually normalized.

#### CONCLUSION

The diagnosis of VIT can be achieved through the time-to-platelet count curve and Naranjo's Adverse Drug Reaction Probability Scale score. The platelet count cannot be normalized simply by platelet transfusion alone, and vancomycin discontinuation is essential.



reviewers. It is distributed in accordance with the Creative Commons Attribution NonCommercial (CC BY-NC 4.0) license, which permits others to distribute, remix, adapt, build upon this work non-commercially, and license their derivative works on different terms, provided the original work is properly cited and the use is non-commercial. See: <http://creativecommons.org/licenses/by-nc/4.0/>

**Manuscript source:** Unsolicited manuscript

**Specialty type:** Pharmacology and pharmacy

**Country/Territory of origin:** China

**Peer-review report's scientific quality classification**

Grade A (Excellent): 0  
Grade B (Very good): B  
Grade C (Good): 0  
Grade D (Fair): 0  
Grade E (Poor): 0

**Received:** October 13, 2020

**Peer-review started:** October 13, 2020

**First decision:** December 13, 2020

**Revised:** December 28, 2020

**Accepted:** January 22, 2021

**Article in press:** January 22, 2021

**Published online:** March 6, 2021

**P-Reviewer:** Momčilović S

**S-Editor:** Zhang H

**L-Editor:** Filipodia

**P-Editor:** Xing YX



**Key Words:** Case report; Vancomycin; Thrombocytopenia; Endocarditis; Platelet transfusion; Literature review

©The Author(s) 2021. Published by Baishideng Publishing Group Inc. All rights reserved.

**Core Tip:** The present report describes a case of vancomycin-induced thrombocytopenia (VIT) in endocarditis and reviews all VIT cases reported in the literature, in terms of indications, diagnosis, management, and potential molecular mechanisms. The present case highlights the importance of accurate diagnosis of VIT in endocarditis, which can be achieved through the time-to-platelet count curve and the Naranjo's Adverse Drug Reaction Probability Scale score. The platelet count cannot be normalized simply by platelet transfusion alone, and the discontinuation of vancomycin is essential. Due to the anamnestic response to vancomycin re-exposure and the formation of vancomycin-dependent antiplatelet antibodies, the re-administration of vancomycin should be avoided.

**Citation:** Guleng SR, Wu RH, Guo XB. Vancomycin-induced thrombocytopenia in endocarditis: A case report and review of literature. *World J Clin Cases* 2021; 9(7): 1696-1704

**URL:** <https://www.wjgnet.com/2307-8960/full/v9/i7/1696.htm>

**DOI:** <https://dx.doi.org/10.12998/wjcc.v9.i7.1696>

## INTRODUCTION

Thrombocytopenia, which is generally defined as a platelet count of less than  $100 \times 10^9$  /L of blood or a decrease in the platelet count of 20%-50% from baseline<sup>[1,2]</sup>, has been considered as an adverse reaction correlated to drugs used in the treatment of various diseases<sup>[3]</sup>. Drug-induced thrombocytopenia is mostly caused by immune-mediated platelet degradation and is always drug dependent, indicating that the platelet count can return to baseline levels after the discontinuation of medications<sup>[4]</sup>. Although it has been reported that approximately 10 million persons per year are suspected to suffer from drug-induced thrombocytopenia<sup>[5]</sup>, its incidence has not been well-defined<sup>[4]</sup>.

Antibiotic-induced thrombocytopenia has been documented<sup>[3]</sup>. The commonly reported antibiotics that induce thrombocytopenia are  $\beta$ -lactam antibiotics agents (such as penicillin, nafcillin, ticarcillin, cefazolin, cefuroxime, ceftriaxone, and piperacillin) and linezolid<sup>[6]</sup>. Vancomycin is a first-generation glycopeptide antibiotic that is often used for the prophylaxis and treatment of suspected or identified methicillin-resistant infections, such as *Staphylococcus aureus* infection<sup>[7]</sup>, and has been considered as an uncommon cause of thrombocytopenia<sup>[6]</sup>. Several clinical observational studies have suggested that the incidence of vancomycin-induced thrombocytopenia (VIT) might be higher than that induced by linezolid<sup>[1]</sup>. However, the incidence of VIT may have been overestimated, because the definition for thrombocytopenia used among these studies vary. A platelet count of less than  $150 \times 10^9$  /L was used in two studies<sup>[8,9]</sup>, and a decrease in platelet count of at least 50% from baseline was used in another study<sup>[1]</sup>. In addition, the clinical manifestations, diagnosis, and management of VIT have not been well-established, and the underlying molecular mechanisms by which vancomycin induces thrombocytopenia needs to be further elucidated<sup>[10]</sup>. Over the past two decades, cases with VIT have been continuously reported<sup>[11]</sup>. However, these cases have rarely been extensively reviewed.

In June 2019, a young male patient with endocarditis was admitted to our hospital, and he developed VIT after vancomycin therapy during the treatment for endocarditis. The present report describes this case and extensively reviews all VIT cases reported in the literature, in terms of indications, diagnosis, management, and potential molecular mechanisms.

## CASE PRESENTATION

### Chief complaints

A 26-year-old Chinese male presented with dyspnea, fatigue, arrhythmias, fever, and cough.

### History of present illness

The patient was admitted to the hospital on June 6, 2019 and diagnosed with infective endocarditis, heart failure, and ventricular septal defect, with a series of manifestations of inflammatory response syndrome.

### History of past illness

He had a medical history of uncontrolled hypotension and rheumatic heart disease.

### Personal and family history

He denied any family history.

### Physical examination

He had a body temperature of 39.1 °C and a heart rate of 100 beats per min.

### Laboratory examinations

Initial laboratory testing showed no abnormality.

### Imaging examinations

The electrocardiosignal data revealed a high echo of the tricuspid valve, suggesting a neoplasm.

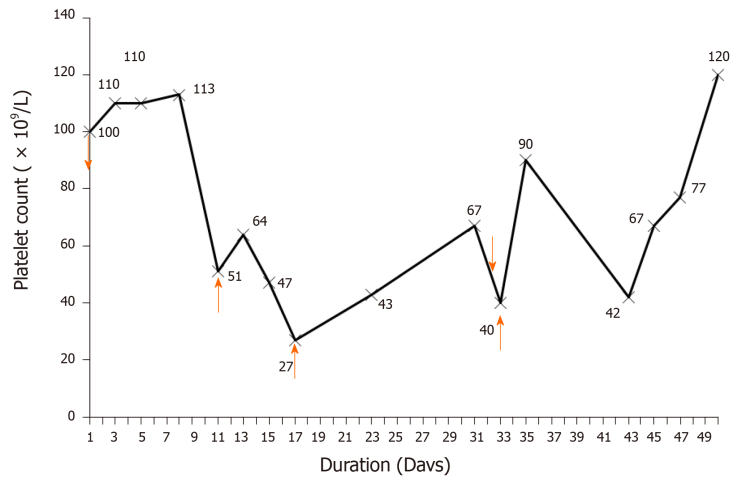
## FINAL DIAGNOSIS

Infective endocarditis, heart failure, and ventricular septal defect.

## TREATMENT

During hospitalization, the patient was treated with multiple courses of drug therapy, which included vancomycin, omeprazole (40 mg q.d. for 10 d), ceftazidime (2 g t.i.d. for 9 d) and metoprolol (50 mg q.d. for 11 d). Based on the bacterial culture and drug susceptibility test, methicillin-resistant *Staphylococcus aureus* was identified with the minimum inhibitory concentration of less than 2 mg/L. Therefore, according to The Clinical Practice Guidelines by the Infectious Diseases Society of America for the Treatment of Methicillin-Resistant *Staphylococcus aureus* Infections in Adults and Children<sup>[12]</sup>, vancomycin was prescribed for the patient with infective endocarditis. Initially, the patient was intravenously treated with 1000 mg of vancomycin every 12 h and 960 mg of benzylpenicillin every 8 h on day 2 for suspected gram-positive infections. The blood cultures were negative for two consecutive tests. Then, the intravenous administration of vancomycin was changed to 500 mg for every 8 h on day 3, for a trough concentration of 25.87 µg/mL beyond the upper limit of 20 µg/mL, and the platelet count was maintained within  $100\text{--}110 \times 10^9/\text{L}$  for 7 d. On day 11, the administration of vancomycin was switched to 500 mg every 12 h, because the platelet count decreased to  $51 \times 10^9/\text{L}$  and the peak concentration of vancomycin reached 57.2 µg/mL. Platelet transfusion (1 U) was given on day 11, and the platelet count slightly increased to  $64 \times 10^9/\text{L}$  on day 14, but dramatically dropped afterwards to  $27 \times 10^9/\text{L}$  on day 17. Then, platelet transfusion (1 U) was given again on day 17, and the platelet count steadily increased up to  $67 \times 10^9/\text{L}$  on day 31. The dose of vancomycin was adjusted to 500 mg every 8 h on day 23 when the trough concentration of vancomycin dropped to 8.86 µg/mL in order to ensure the minimal effective treatment concentration (10 µg/mL). However, on day 33, the hemoglobin level sharply dropped from 101 g/L to 54 g/L, the platelet count continuously declined to approximately  $40 \times 10^9/\text{L}$ , and platelet transfusion (1 U) was given. The platelet count rebounded to  $90 \times 10^9/\text{L}$  on day 35 but dropped to  $42 \times 10^9/\text{L}$  again on day 43. Based on these above observations, and along with the time-to-platelet count curve that illustrated the decline in platelet level after the administration of vancomycin (Figure 1), VIT was





**Figure 1 Time-to-platelet count curve during hospitalization.** Vancomycin was initiated on day 2 and continued on day 43, as indicated by the downward arrows. Platelet transfusion was given on day 11, 17, 33, and 43, as indicated by the upward arrows.

suspected, vancomycin was discontinued and replaced with daptomycin, and platelet transfusion (1 U) was given on the same day. The platelet count level increased and reached up to  $120 \times 10^9/L$  on day 50 and remained stable thereafter.

The concurrent antibiotic, benzylpenicillin, was continuously used during the period with little effect on the platelet count. The respiratory rate, white blood cell count, and hemodynamic variables remained stable, and the microbiological cultures from the sputum and urine revealed negative results, implying that no infection was correlated with thrombocytopenia for the present patient. The other causes of thrombocytopenia, including thrombotic thrombocytopenic purpura, hemolytic anemia, disseminated intravascular coagulation, and platelet-clumping pseudothrombocytopenia, were also excluded, because the results of the blood smear, bilirubin, and hemoglobin were normal. There have been no reports on the occurrence of drug-induced thrombocytopenia caused by other medications during treatment, including omeprazole, ceftazidime, and metoprolol. Therefore, a diagnosis of VIT was initially established using the time-to-platelet count curve. In addition, the Naranjo's Adverse Drug Reaction Probability Scale score (Naranjo score) for vancomycin was 8, indicating the probable correlation between thrombocytopenia and vancomycin.

## OUTCOME AND FOLLOW-UP

The patient was discharged from the hospital.

## DISCUSSION

A literature search for all case reports on VIT published in English from April 1985 to June 2020 was performed on PMC/PubMed, Scopus, and Web of Science. Keywords, which included vancomycin and thrombocytopenia, were used to search the titles and abstracts. References of relevant case reports, according to the brief research, were also carefully checked. The demographic data (*e.g.*, age and gender), platelet count, diagnosis, and treatment were recorded and analyzed.

A total of 36 articles that reported 37 cases with VIT were identified in the literature. Thus, the data of 38 cases, which included the case described in the present report, were reviewed and are summarized in Table 1. Among these cases, 14 cases were females and 24 cases were males. The mean age of these cases was  $51.19 \pm 26.98$  years-old (range: 3 mo to 81-years-old). Furthermore, four children were under 2-years-old, and 36 cases were adults 26-81 years-old. The most common indications for the treatment with vancomycin were endocarditis ( $n = 6$ ), sepsis ( $n = 6$ ), pneumonia ( $n = 5$ ), and cellulitis ( $n = 2$ ). These were followed by other various indications, such as prosthetic infection, hemodialysis, bone graft, acute pancreatitis, *etc.* The diagnosis of VIT mainly relied on the platelet count, with or without the Naranjo score<sup>[13]</sup>. The test

Table 1 Summary of case reports of vancomycin-induced thrombocytopenia

Author (publication year)	Age (yr)	Gender	Indication	Platelet count ( $10^9/L$ ) <sup>1</sup>	Naranjo Score	Treatment	Time for resolution (d) <sup>2</sup>	Vancomycin-dependent antibodies	Bleeding sign
Present case	26	M	Endocarditis	27	Probable	Platelet transfusion and daptomycin	12	NA	+
MacDougall <i>et al</i> <sup>[14]</sup> (2020)	81	M	Prosthetic infection	2	NA	Prednisone, immunoglobulin, and daptomycin	10	+	-
Ajit <i>et al</i> <sup>[27]</sup> (2019)	61	M	Hemodialysis	< 10	NA	Prednisone, immunoglobulin, eltrombopag and plasma exchange	15	+	+
Getz <i>et al</i> <sup>[18]</sup> (2019)	71	M	Transverse myelitis	8.6	Definite	Dexamethasone and immunoglobulin	8	+	+
Chen <i>et al</i> <sup>[16]</sup> (2018)	0	F	Purulent meningitis	8	Probable	Methylprednisolone	4	+	+
Danieletto <i>et al</i> <sup>[17]</sup> (2017)	57	F	Bone graft	9	Probable	Tigecycline	7	-	-
Kalra <i>et al</i> <sup>[28]</sup> (2016)	0.7	M	Sepsis	30	NA	Platelet transfusion	3	NA	-
Schueler <i>et al</i> <sup>[15]</sup> (2016)	55	M	Purpura	1	NA	Prednisone and immunoglobulin	3	NA	+
Yamanouchi <i>et al</i> <sup>[29]</sup> (2016)	72	F	Sepsis	2	NA	Steroid therapy and carbapenem	7	+	+
Lobo <i>et al</i> <sup>[13]</sup> (2015)	67	M	Pneumonia	2	Probable	Platelet transfusion, methylprednisolone and immunoglobulin	3	+	+
Ahmed <i>et al</i> <sup>[30]</sup> (2015)	63	M	Diabetic foot	2	Probable	Daptomycin	10	+	-
Candemir <i>et al</i> <sup>[10]</sup> (2013)	54	F	Hematoma	42	Probable	Platelet transfusion and daptomycin	4	NA	NA
Wetzel <i>et al</i> <sup>[31]</sup> (2013)	64	F	Sepsis	7	Probable	Prednisone and immunoglobulin	8	NA	+
Ruggero <i>et al</i> <sup>[32]</sup> (2012)	41	M	Pneumonia	15	Definite	Daptomycin	5	NA	+
Arnold <i>et al</i> <sup>[23]</sup> (2013)	66	F	Endocarditis	4	Probable	Platelet transfusion and immunoglobulin	5	+	+
Rowland <i>et al</i> <sup>[33]</sup> (2013)	51	M	Acute pancreatitis	9	Probable	Only vancomycin discontinuation	5	NA	+
Anand <i>et al</i> <sup>[34]</sup> (2011)	54	M	Cellulitis	1	Possible	Corticosteroids and daptomycin	2	+	+
Ganly <i>et al</i> <sup>[22]</sup> (2011)	67	M	Sepsis	2	NA	Platelet transfusion and immunoglobulin	8	NA	+
Shah <i>et al</i> <sup>[11]</sup> (2009)	60	M	Shoulder infection	9	Possible	Platelet transfusion	3	+	+
Lee <i>et al</i> <sup>[35]</sup> (2009)	76	M	Diabetic foot	< 15	Possible	Platelet transfusion and teicoplanin.	5	+	-
Apiwattanakul <i>et al</i> <sup>[36]</sup> (2008)	16	F	Endocarditis	123	Possible	Prednisone and cefotaxime	5	NA	-
Kenney <i>et al</i> <sup>[20]</sup> (2008)	61	M	Gangrene and bacteremia	3	Probable	Platelet transfusion and immunoglobulin	4	+	+
Pauldine <i>et al</i> <sup>[37]</sup> (2008)	60	M	Pneumonia	10	Possible	Platelet transfusion	12	+	+
Dilli <i>et al</i> <sup>[38]</sup> (2008)	0.6	M	Neonatal respiratory distress	41	NA	Only vancomycin discontinuation	3	-	NA

O'Donnell <i>et al</i> <sup>[21]</sup> (2007)	56	F	Prosthetic infection	2	Possible	Immunoglobulin	7	+	+
Bay <i>et al</i> <sup>[39]</sup> (2006)	2	M	Pneumonia	11	NA	Only vancomycin discontinuation	4	NA	NA
Winteroll <i>et al</i> <sup>[24]</sup> (2004)	72	M	Sepsis	3	Probable	Platelet transfusion	10	+	+
Peel <i>et al</i> <sup>[40]</sup> (2003)	45	M	Peritonitis	5	Probable	Platelet transfusion and prednisone	4	NA	+
Marraffa <i>et al</i> <sup>[41]</sup> (2003)	50	M	Endocarditis	10	Probable	Clindamycin and methylprednisolone	5	NA	+
Rocha <i>et al</i> <sup>[42]</sup> (2002)	38	F	Prosthetic infection	68	Possible	Only vancomycin discontinuation	4	NA	NA
Shahar <i>et al</i> <sup>[43]</sup> (2000)	43	F	Surgery-site infection	118	Probable	Only vancomycin discontinuation	3	NA	NA
Govindarajan <i>et al</i> <sup>[44]</sup> (1999)	72	M	Epidural abscess	13	Probable	Trimethoprim/sulfamethoxazole	10	NA	NA
Kuruppu <i>et al</i> <sup>[45]</sup> (1999)	72	F	Endocarditis	14	Possible	Only vancomycin discontinuation	5	-	NA
Mizon <i>et al</i> <sup>[46]</sup> (1997)	71	F	Sepsis	< 10	Probable	Antibiotics withdrawn	4	+	+
Zenon <i>et al</i> <sup>[47]</sup> (1991)	54	M	Cellulitis	17	Probable	Antibiotics withdrawn	7	NA	NA
Christie <i>et al</i> <sup>[48]</sup> (1990)	73	F	Pneumonia	14	Probable	Platelet transfusion	2	+	NA
Christie <i>et al</i> <sup>[48]</sup> (1990)	31	M	Fever	< 10	Possible	Platelet transfusion	11 (not continued)	+	NA
Carmichael <i>et al</i> <sup>[49]</sup> (1986)	42	F	Endocarditis	82	Possible	NA	9	NA	NA

<sup>1</sup>The lowest value during the vancomycin treatment.

<sup>2</sup>The time from vancomycin discontinuation to the resolution of vancomycin-induced thrombocytopenia. +: A positive result; -: A negative result. F: Female; M: Male; NA: Not available or not tested.

results for the vancomycin-dependent antibodies were available for 19 patients, and all except three were positive. Among the 27 patients with available bleeding information, 21 patients exhibited bleeding signs. The treatments for these cases comprised of platelet transfusion, prednisone, dexamethasone, immunoglobulin, and daptomycin, and the discontinuation of vancomycin. For the six cases with endocarditis, VIT was diagnosed as probable by the Naranjo score. The information on bleeding signs was available for four cases, and three of these cases presented with bleeding signs. The presence of vancomycin-dependent antibodies was examined only in two patients, and positive results were obtained in one of them. After vancomycin discontinuation, VIT was generally resolved for all patients within 4-15 d. Despite clinical significance revealed by the present literature review, it must be clearly stated that this is only a narrative review, which possesses all the limitations of the selection of papers. Thus, a methodologically acceptable systematic review should be carried out when more data with high quality are available in order to draw a firm conclusion.

The present patient with infective endocarditis was diagnosed with VIT, which rapidly progressed. The early diagnosis of VIT was performed using the time-to-platelet count curve and Naranjo score. During treatment, the repeated platelet transfusions failed to increase the platelet levels. Subsequently, simply switching vancomycin to daptomycin returned the platelet count close to the baseline level.

The early diagnosis of VIT is quite difficult due to many suspected causes, such as severe infection, disseminated intravascular coagulation, heparin, and other medications. The correct diagnosis can be masked by the simultaneous administration of medications, which can cause drug-induced immune thrombocytopenia<sup>[14]</sup> or a complicating disease, such as primary idiopathic thrombocytopenic purpura or chronic hepatitis C<sup>[15]</sup>. Therefore, the early recognition of VIT was of key importance for the following treatment. According to previous studies<sup>[6]</sup>, the investigators used the platelet count at different time points as the initial diagnosis of VIT, which can reveal a definite time-independent relationship with drug administration. All other causes of

thrombocytopenia were excluded. Furthermore, the Naranjo score, which has been applied to help with the diagnosis of VIT<sup>[16-18]</sup>, also indicated a probable correlation between thrombocytopenia and vancomycin. Noticeably, endocarditis represents the most common indication that is associated with VIT. The probable correlation between thrombocytopenia and vancomycin can be made through the Naranjo score for all cases, indicating that the Naranjo score is a useful tool to initially diagnose VIT in patients with endocarditis. A bleeding sign is also a useful clinical manifestation to which attention should be given in order to make a definite diagnosis, since most cases would present bleeding signs when VIT occurs. This is particularly true in patients with endocarditis, based on the analyzed data. However, the value of the detection of vancomycin-dependent antibodies in the diagnosis of VIT in patients with endocarditis remains to be elucidated due to the very limited data available.

The critical management after suspicions of VIT is to determine whether to continue or discontinue the vancomycin therapy. The seriousness of the bleeding and the dropping trend of the platelet count should be carefully considered and closely monitored when continuing the vancomycin therapy. However, once VIT is diagnosed, the vancomycin must be stopped, and the platelet transfusion should be taken into consideration as a supplemental treatment for some patients with various success rates, although there are still some transfusion-resistant patients<sup>[10,13,19,20]</sup>. If vancomycin is not stopped, the survival time of the transfused platelets would be obviously reduced, and the platelet transfusion will not always expectedly increase the platelet count of affected patients<sup>[3]</sup>. In any of these circumstances, platelet transfusion should be considered for severe thrombocytopenia with a platelet count of below  $20 \times 10^9/L$  and bleeding<sup>[19]</sup>. In addition to platelet transfusion, therapies with intravenous corticosteroids, intravenous immunoglobulins, rituximab, and plasma exchange have been shown to be beneficial in some cases after vancomycin discontinuation<sup>[3,21-23]</sup>. However, these medical approaches may not always be effective. In the present case, VIT was effectively resolved by platelet transfusion with the switching of vancomycin to daptomycin.

The mechanisms of VIT remains unclear. The formation of different drug-dependent platelet antibodies, including hapten-dependent, quinine-type, fiban-type and drug-specific antibodies, and other platelet destruction antibodies, are the widely documented mechanisms for VIT<sup>[11,21,24]</sup>. In contrast, naturally occurring antibodies may not contribute to VIT<sup>[25]</sup>. It has been postulated that vancomycin can bind to platelet glycoproteins and induce the generation of antibodies, which can attach to the drug-platelet complex, resulting in cell lysis<sup>[26]</sup>. In the present case, the platelet count gradually dropped after the administration of vancomycin (1000 mg per day) for 7 d. Although the vancomycin was changed to a low-dose (500 mg per day), the platelet count continued to drop. It was postulated that the persistent thrombocytopenia might be due to the anamnestic response for vancomycin re-exposure, and vancomycin-dependent antiplatelet antibodies were formed once vancomycin was re-used.

## CONCLUSION

The present case highlights the importance of the accurate diagnosis of VIT in patients with endocarditis. The time-to-platelet count curve and Naranjo score are useful tools for the diagnosis of VIT. The platelet count cannot be normalized simply by platelet transfusion alone. Instead, the discontinuation of vancomycin or switching vancomycin to other antibiotics, such as daptomycin, is essential for effectively treating VIT. Due to the anamnestic response to vancomycin re-exposure and the formation of vancomycin-dependent antiplatelet antibodies, the re-administration of vancomycin should be avoided.

## REFERENCES

- 1 **Patel N**, VanDeWall H, Tristani L, Rivera A, Woo B, Dihmess A, Li HK, Smith R, Lodise TP. A comparative evaluation of adverse platelet outcomes among Veterans' Affairs patients receiving linezolid or vancomycin. *J Antimicrob Chemother* 2012; **67**: 727-735 [PMID: 22174041 DOI: 10.1093/jac/dkr522]
- 2 **Rao N**, Ziran BH, Wagener MM, Santa ER, Yu VL. Similar hematologic effects of long-term linezolid and vancomycin therapy in a prospective observational study of patients with orthopedic infections. *Clin Infect Dis* 2004; **38**: 1058-1064 [PMID: 15095207 DOI: 10.1086/382356]
- 3 **van den Bemt PM**, Meyboom RH, Egberts AC. Drug-induced immune thrombocytopenia. *Drug Saf*

- 2004; **27**: 1243-1252 [PMID: [15588119](#) DOI: [10.2165/00002018-200427150-00007](#)]
- 4 **Aster RH**, Bougie DW. Drug-induced immune thrombocytopenia. *N Engl J Med* 2007; **357**: 580-587 [PMID: [17687133](#) DOI: [10.1056/NEJMra066469](#)]
- 5 **Aster RH**, Curtis BR, McFarland JG, Bougie DW. Drug-induced immune thrombocytopenia: pathogenesis, diagnosis, and management. *J Thromb Haemost* 2009; **7**: 911-918 [PMID: [19344362](#) DOI: [10.1111/j.1538-7836.2009.03360.x](#)]
- 6 **Loo AS**, Gerzenshtein L, Ison MG. Antimicrobial drug-induced thrombocytopenia: a review of the literature. *Semin Thromb Hemost* 2012; **38**: 818-829 [PMID: [23081819](#) DOI: [10.1055/s-0032-1328882](#)]
- 7 **Levine DP**. Vancomycin: understanding its past and preserving its future. *South Med J* 2008; **101**: 284-291 [PMID: [18364659](#) DOI: [10.1097/SMJ.0b013e3181647037](#)]
- 8 **Rao N**, Ziran BH, Hall RA, Santa ER. Successful treatment of chronic bone and joint infections with oral linezolid. *Clin Orthop Relat Res* 2004; 67-71 [PMID: [15552139](#) DOI: [10.1097/01.blo.0000144860.11193.5e](#)]
- 9 **Nasraway SA**, Shorr AF, Kuter DJ, O'Grady N, Le VH, Cammarata SK. Linezolid does not increase the risk of thrombocytopenia in patients with nosocomial pneumonia: comparative analysis of linezolid and vancomycin use. *Clin Infect Dis* 2003; **37**: 1609-1616 [PMID: [14689341](#) DOI: [10.1086/379327](#)]
- 10 **Candemir B**, Aribuca A, Koca C, Ozcan OU, Gerede M, Kaya CT. An unusual case of vancomycin-related systemic reaction accompanied with severe thrombocytopenia mimicking pacemaker-related infective endocarditis: a case report and review of literature. *J Interv Card Electrophysiol* 2013; **38**: 143-145 [PMID: [23080329](#) DOI: [10.1007/s10840-012-9738-6](#)]
- 11 **Shah RA**, Musthaq A, Khardori N. Vancomycin-induced thrombocytopenia in a 60-year-old man: a case report. *J Med Case Rep* 2009; **3**: 7290 [PMID: [19830166](#) DOI: [10.4076/1752-1947-3-7290](#)]
- 12 **Liu C**, Bayer A, Cosgrove SE, Daum RS, Fridkin SK, Gorwitz RJ, Kaplan SL, Karchmer AW, Levine DP, Murray BE, J Rybak M, Talan DA, Chambers HF; Infectious Diseases Society of America. Clinical practice guidelines by the infectious diseases society of america for the treatment of methicillin-resistant *Staphylococcus aureus* infections in adults and children. *Clin Infect Dis* 2011; **52**: e18-e55 [PMID: [21208910](#) DOI: [10.1093/cid/ciq146](#)]
- 13 **Lobo N**, Ejiofor K, Thurairaja R, Khan MS. Life-threatening haematuria caused by vancomycin-induced thrombocytopenia. *BMJ Case Rep* 2015; **2015** [PMID: [25716041](#) DOI: [10.1136/bcr-2014-208192](#)]
- 14 **MacDougall KN**, Parylo S, Sokoloff A. A Case of Vancomycin-Induced Immune Thrombocytopenia. *Cureus* 2020; **12**: e7940 [PMID: [32499980](#) DOI: [10.7759/cureus.7940](#)]
- 15 **Schueler SA**, Shet NS, Stienstra N, Chen DC. A Masked Case of Vancomycin-induced Immune Thrombocytopenia. *Am J Med Sci* 2016; **351**: 636 [PMID: [27238931](#) DOI: [10.1016/j.amjms.2016.03.005](#)]
- 16 **Chen QY**, Wan J, Yang JH, Lin M, Chen Y. Vancomycin-induced severe thrombocytopenia in a young infant. *Rev Soc Bras Med Trop* 2018; **51**: 873-875 [PMID: [30517547](#) DOI: [10.1590/0037-8682-0150-2018](#)]
- 17 **Danieletto CF**, Ferreira GZ, Farah GJ, Cuman RK. Vancomycin-induced thrombocytopenia: a rare adverse effect in a patient -submitted to bone graft in the jaw. *Spec Care Dentist* 2017; **37**: 38-42 [PMID: [27059302](#) DOI: [10.1111/scd.12182](#)]
- 18 **Getz TM**, Packer CD. Rapid-Onset Vancomycin-Induced Thrombocytopenia With Reexposure. *Ann Pharmacother* 2019; **53**: 1259-1261 [PMID: [31353923](#) DOI: [10.1177/1060028019867433](#)]
- 19 **Mohammadi M**, Jahangard-Rafsanjani Z, Sarayani A, Hadjibabaei M, Taghizadeh-Ghehi M. Vancomycin-Induced Thrombocytopenia: A Narrative Review. *Drug Saf* 2017; **40**: 49-59 [PMID: [27848200](#) DOI: [10.1007/s40264-016-0469-y](#)]
- 20 **Kenney B**, Tormey CA. Acute vancomycin-dependent immune thrombocytopenia as an anamnestic response. *Platelets* 2008; **19**: 379-383 [PMID: [18791945](#) DOI: [10.1080/09537100802082280](#)]
- 21 **O'Donnell E**, Shepherd C, Neff A. Immune thrombocytopenia from vancomycin in orthopedic cement. *Am J Hematol* 2007; **82**: 1122 [PMID: [17665503](#) DOI: [10.1002/ajh.20916](#)]
- 22 **Ganly P**, Downing J, Stiven P, Frizelle F, Badami K. Clinical and serological diagnoses of a patient with vancomycin-induced thrombocytopenia. *Transfus Med* 2011; **21**: 137-139 [PMID: [21083776](#) DOI: [10.1111/j.1365-3148.2010.01052.x](#)]
- 23 **Arnold DM**, Nazi I, Warkentin TE, Smith JW, Tolt LJ, George JN, Kelton JG. Approach to the diagnosis and management of drug-induced immune thrombocytopenia. *Transfus Med Rev* 2013; **27**: 137-145 [PMID: [23845922](#) DOI: [10.1016/j.tmr.2013.05.005](#)]
- 24 **Winteroll S**, Kerowgan M, Vahl CF, Leo A. Vancomycin-mediated drug-induced immune thrombocytopenia. *Transfus Med Hemother* 2004; **32**: 20-23 [DOI: [10.1159/000082126](#)]
- 25 **Von Drygalski A**, Curtis BR, Bougie DW, McFarland JG, Ahl S, Limbu I, Baker KR, Aster RH. Vancomycin-induced immune thrombocytopenia. *N Engl J Med* 2007; **356**: 904-910 [PMID: [17329697](#) DOI: [10.1056/NEJMoa065066](#)]
- 26 **Rondina MT**, Walker A, Pendleton RC. Drug-induced thrombocytopenia for the hospitalist physician with a focus on heparin-induced thrombocytopenia. *Hosp Pract (1995)* 2010; **38**: 19-28 [PMID: [20469610](#)]
- 27 **Ajit NE**, Devarashetty SP, Master S. Vancomycin Induced Thrombocytopenia - Protracted Course in a Hemodialysis Patient. *Case Rep Oncol* 2019; **12**: 749-754 [PMID: [31762746](#) DOI: [10.1159/000503418](#)]



- 28 **Kalra K**, Mittal HG, Maria A. Vancomycin-induced thrombocytopenia in a newborn. *Drug Metab Pers Ther* 2016; **31**: 235-237 [PMID: [27849621](#) DOI: [10.1515/dmpt-2016-0021](#)]
- 29 **Yamanouchi J**, Hato T, Shiraishi S, Takeuchi K, Yakushijin Y, Yasukawa M. Vancomycin-induced Immune Thrombocytopenia Proven by the Detection of Vancomycin-dependent Anti-platelet Antibody with Flow Cytometry. *Intern Med* 2016; **55**: 3035-3038 [PMID: [27746445](#) DOI: [10.2169/internalmedicine.55.6902](#)]
- 30 **Ahmed Y**, Sartin C, Umer I. Vancomycin-induced severe asymptomatic immune thrombocytopenia: a rare cause. *Southwest Respir Crit Care Chronicles* 2015; **3**: 42-45 [DOI: [10.12746/swrccc.v3i9.159](#)]
- 31 **Wetzel DR**, Njathi CW, Teleszm BJ, Stewartm TM, Smischney NJ. Thrombocytopenia of unusual etiology in the intensive care unit. *J Med Cases* 2013; **4**: 792-795 [DOI: [10.4021/jmc1555w](#)]
- 32 **Ruggero MA**, Abdelghany O, Topal JE. Vancomycin-induced thrombocytopenia without isolation of a drug-dependent antibody. *Pharmacotherapy* 2012; **32**: e321-5 [PMID: [23065779](#) DOI: [10.1002/phar.1132](#)]
- 33 **Rowland SP**, Rankin I, Sheth H. Vancomycin-induced thrombocytopenia in a patient with severe pancreatitis. *BMJ Case Rep* 2013; **2013** [PMID: [24132444](#) DOI: [10.1136/bcr-2013-200830](#)]
- 34 **Anand A**, Chauhan HK. Piperacillin and vancomycin induced severe thrombocytopenia in a hospitalized patient. *Platelets* 2011; **22**: 294-301 [PMID: [21309645](#) DOI: [10.3109/09537104.2010.549973](#)]
- 35 **Lee JH**, Kim DS, Lee HS, Choi SI, Cho YG. A case of vancomycin induced thrombocytopenia. *Korean J Hematol* 2009; **44**: 294-297 [DOI: [10.5045/kjh.2009.44.4.294](#)]
- 36 **Apiwattanakul N**, Wanitkun S, Chongtrakool P, Sirinavin S. A patient with penicillin-resistant viridans group streptococcal endocarditis and unusual reactions to vancomycin. *Southeast Asian J Trop Med Public Health* 2008; **39**: 1088-1091 [PMID: [19062700](#)]
- 37 **Pauldine R**, Pustavoitau A. Case report: vancomycin-induced thrombocytopenia in a burn patient. *Eplasty* 2008; **8**: e39 [PMID: [18725952](#)]
- 38 **Dilli D**, Oğuz SS, Dilmen U. A newborn with vancomycin-induced thrombocytopenia. *Pharmacology* 2008; **82**: 285-286 [PMID: [18931535](#) DOI: [10.1159/000163099](#)]
- 39 **Bay A**, Oner AF, Dogan M, Caksen H. A child with vancomycin-induced thrombocytopenia. *J Emerg Med* 2006; **30**: 99-100 [PMID: [16434347](#) DOI: [10.1016/j.jemermed.2005.11.017](#)]
- 40 **Peel RK**, Sykes A, Ashmore S, Turney JH, Woodrow G. A case of immune thrombocytopenic purpura from intraperitoneal vancomycin use. *Perit Dial Int* 2003; **23**: 506-508 [DOI: [10.1177/089686080302300520](#)]
- 41 **Marruffa J**, Guharoy R, Duggan D, Rose F, Nazeer S. Vancomycin-induced thrombocytopenia: a case proven with rechallenge. *Pharmacotherapy* 2003; **23**: 1195-1198 [PMID: [14524652](#) DOI: [10.1592/phco.23.10.1195.32765](#)]
- 42 **Rocha JL**, Kondo W, Baptista MI, Da Cunha CA, Martins LT. Uncommon vancomycin-induced side effects. *Braz J Infect Dis* 2002; **6**: 196-200 [PMID: [12204187](#) DOI: [10.1590/s1413-86702002000400007](#)]
- 43 **Shahar A**, Berner Y, Levi S. Fever, rash, and pancytopenia following vancomycin rechallenge in the presence of ceftazidime. *Ann Pharmacother* 2000; **34**: 263-264 [PMID: [10676837](#) DOI: [10.1345/aph.19051](#)]
- 44 **Govindarajan R**, Baxter D, Wilson C, Zent C. Vancomycin-induced thrombocytopenia. *Am J Hematol* 1999; **62**: 122-123 [PMID: [10509053](#) DOI: [10.1002/\(sici\)1096-8652\(199910\)62:2<122::aid-ajh14>3.0.co;2-r](#)]
- 45 **Kuruppu JC**, Le TP, Tuazon CU. Vancomycin-associated thrombocytopenia: case report and review of the literature. *Am J Hematol* 1999; **60**: 249-250 [PMID: [10072125](#) DOI: [10.1002/\(sici\)1096-8652\(199903\)60:3<249::aid-ajh20>3.0.co;2-h](#)]
- 46 **Mizon P**, Kiefel V, Mannessier L, Mueller-Eckhardt C, Goudemand J. Thrombocytopenia induced by vancomycin-dependent platelet antibody. *Vox Sang* 1997; **73**: 49-51 [PMID: [9269071](#) DOI: [10.1046/j.1423-0410.1997.7310049.x](#)]
- 47 **Zenon GJ**, Cadle RM, Hamill RJ. Vancomycin-induced thrombocytopenia. *Arch Intern Med* 1991; **151**: 995-996 [PMID: [2025149](#) DOI: [10.1001/archinte.1991.00400050133025](#)]
- 48 **Christie DJ**, van Buren N, Lennon SS, Putnam JL. Vancomycin-dependent antibodies associated with thrombocytopenia and refractoriness to platelet transfusion in patients with leukemia. *Blood* 1990; **75**: 518-523 [PMID: [2295006](#) DOI: [10.1182/blood.V75.2.518.518](#)]
- 49 **Carmichael A**, Al-Zahawi M. Drug points: pancytopenia associated with vancomycin. *Br Med J* 1986; **293**: 1103 [DOI: [10.1136/bmj.293.6554.1103-c](#)]





Published by **Baishideng Publishing Group Inc**  
7041 Koll Center Parkway, Suite 160, Pleasanton, CA 94566, USA

**Telephone:** +1-925-3991568

**E-mail:** [bpgoffice@wjgnet.com](mailto:bpgoffice@wjgnet.com)

**Help Desk:** <https://www.f6publishing.com/helpdesk>

<https://www.wjgnet.com>

