

World Journal of *Clinical Cases*

World J Clin Cases 2021 March 6; 9(7): 1499-1760



Contents

Thrice Monthly Volume 9 Number 7 March 6, 2021

REVIEW

- 1499 Review of the risk factors for SARS-CoV-2 transmission

Li X, Xia WY, Jiang F, Liu DY, Lei SQ, Xia ZY, Wu QP

MINIREVIEWS

- 1513 Regulation of the expression of proinflammatory cytokines induced by SARS-CoV-2

Zhang XN, Wu LJ, Kong X, Zheng BY, Zhang Z, He ZW

ORIGINAL ARTICLE

Case Control Study

- 1524 Efficacy and safety of short duration radiotherapy combined with chemotherapy for advanced rectal cancer

Gao SQ, Zhang YC, Zhang C, Wang SJ, Ren W, Yuan N, Wen JY

Retrospective Study

- 1532 Effects of transjugular intrahepatic portosystemic shunt using the Viatorr stent on hepatic reserve function in patients with cirrhosis

Yao X, Zhou H, Huang S, Tang SH, Qin JP

- 1543 Primary and secondary postoperative hemorrhage in pediatric tonsillectomy

Xu B, Jin HY, Wu K, Chen C, Li L, Zhang Y, Gu WZ, Chen C

- 1554 Dynamic monitoring of serum liver function indexes in patients with COVID-19

Lin H, Wu LJ, Guo SQ, Chen RL, Fan JR, Ke B, Pan ZQ

- 1563 Construction of a clinical survival prognostic model for middle-aged and elderly patients with stage III rectal adenocarcinoma

Liu H, Li Y, Qu YD, Zhao JJ, Zheng ZW, Jiao XL, Zhang J

- 1580 Short-term outcomes of radiofrequency ablation for hepatocellular carcinoma using cone-beam computed tomography for planning and image guidance

Yao XS, Yan D, Jiang XX, Li X, Zeng HY, Li H

- 1592 Intra-arterial thrombolysis for early hepatic artery thrombosis after liver transplantation

Li T, Sun XD, Yu Y, Lv GY

- 1600 Study on pathogenic genes of dwarfism disease by next-generation sequencing

Yang LL, Liang SS

- 1610** Effects of cooperative nursing and patient education on postoperative infection and self-efficacy in gastrointestinal tumors

Qiao L, Zeng SQ, Zhang N

Observational Study

- 1619** Elevated soluble 4-1BB is associated with serum markers of hepatitis B virus in patients with chronic hepatitis B

Zhan MR, Gao XZ, Wang C, Peng F, Wang XM, Xu HQ, Niu JQ

CASE REPORT

- 1631** Balloon-assisted endoscopic submucosal dissection for treating small intestinal lipomas: Report of two cases

Chen HY, Ning SB, Yin X, Li BR, Zhang J, Jin XW, Sun T, Xia ZB, Zhang XP

- 1639** Dysphagia in a patient with ankylosing spondylitis: A case report

Wang XW, Zhang WZ

- 1646** Autologous scalp skin grafting to treat toxic epidermal necrolysis in a patient with a large skin injury: A case report

Xue DD, Zhou L, Yang Y, Ma SY

- 1654** Epstein-Barr virus-positive diffuse large B-cell lymphoma with human immunodeficiency virus mimicking complicated frontal sinusitis: A case report

Yoon S, Ryu KH, Baek HJ, An HJ, Joo YH

- 1661** Multiple well-differentiated retroperitoneal liposarcomas with different patterns of appearance on computed tomography: A case report

Xie TH, Ren XX, Fu Y, Ha SN, Liu LT, Jin XS

- 1668** Sarcomatoid carcinoma of the prostate with bladder invasion shortly after androgen deprivation: Two case reports

Wei W, Li QG, Long X, Hu GH, He HJ, Huang YB, Yi XL

- 1676** Metastatic thymic-enteric adenocarcinoma responding to chemoradiation plus anti-angiogenic therapy: A case report

Li M, Pu XY, Dong LH, Chang PY

- 1682** Solid pseudopapillary neoplasm-diagnostic approach and post-surgical follow up: Three case reports and review of literature

Abudalou M, Vega EA, Dhingra R, Holzwanger E, Krishnan S, Kondratiev S, Niakosari A, Conrad C, Stallwood CG

- 1696** Vancomycin-induced thrombocytopenia in endocarditis: A case report and review of literature

Guleng SR, Wu RH, Guo XB

- 1705** Human menstrual blood-derived stem cells as immunoregulatory therapy in COVID-19: A case report and review of the literature

Lu J, Xie ZY, Zhu DH, Li LJ

- 1714** Pure transvaginal natural orifice transluminal endoscopic surgery right hemicolectomy for colon cancer: A case report
Song ZJ, Shi YQ, Jiang YM, Liu K, Li Y, Wang CG, Zhao R
- 1720** Hyperglycemic hemianopia: A case report
Xiang XH, Fang JJ, Yang M, Zhao GH
- 1728** Mucinous appendiceal neoplasm: A case report
Chirca A, Negreanu L, Iliesiu A, Costea R
- 1734** Reconstructing abdominal wall defects with a free composite tissue flap: A case report
Wang J
- 1741** Mononeuropathy multiplex associated with systemic vasculitis: A case report
Chae HJ, Kim JW, Lee YL, Park JH, Lee SY
- 1748** Congenital fiber-type disproportion presenting with type II respiratory failure after delivery: A case report
Yang HM, Guo JX, Yang YM
- 1755** Use of three dimensional-printing in the management of floating aortic thrombus due to occult aortic dissection: A case report
Wang TH, Zhao JC, Xiong F, Yang Y

ABOUT COVER

Chin-Hsiao Tseng, MD, PhD, Full Professor, Department of Internal Medicine, National Taiwan University College of Medicine, No. 1 Jen Ai Road Section 1, Taipei 100, Taiwan. ccktsh@ms6.hinet.net

AIMS AND SCOPE

The primary aim of *World Journal of Clinical Cases* (WJCC, *World J Clin Cases*) is to provide scholars and readers from various fields of clinical medicine with a platform to publish high-quality clinical research articles and communicate their research findings online.

WJCC mainly publishes articles reporting research results and findings obtained in the field of clinical medicine and covering a wide range of topics, including case control studies, retrospective cohort studies, retrospective studies, clinical trials studies, observational studies, prospective studies, randomized controlled trials, randomized clinical trials, systematic reviews, meta-analysis, and case reports.

INDEXING/ABSTRACTING

The WJCC is now indexed in Science Citation Index Expanded (also known as SciSearch®), Journal Citation Reports/Science Edition, Scopus, PubMed, and PubMed Central. The 2020 Edition of Journal Citation Reports® cites the 2019 impact factor (IF) for WJCC as 1.013; IF without journal self cites: 0.991; Ranking: 120 among 165 journals in medicine, general and internal; and Quartile category: Q3. The WJCC's CiteScore for 2019 is 0.3 and Scopus CiteScore rank 2019: General Medicine is 394/529.

RESPONSIBLE EDITORS FOR THIS ISSUE

Production Editor: Yan-Xia Xing; **Production Department Director:** Yun-Xiaoqian Wu; **Editorial Office Director:** Jin-Li Wang.

NAME OF JOURNAL

World Journal of Clinical Cases

ISSN

ISSN 2307-8960 (online)

LAUNCH DATE

April 16, 2013

FREQUENCY

Thrice Monthly

EDITORS-IN-CHIEF

Dennis A Bloomfield, Sandro Vento, Bao-Gan Peng

EDITORIAL BOARD MEMBERS

<https://www.wjgnet.com/2307-8960/editorialboard.htm>

PUBLICATION DATE

March 6, 2021

COPYRIGHT

© 2021 Baishideng Publishing Group Inc

INSTRUCTIONS TO AUTHORS

<https://www.wjgnet.com/bpg/gerinfo/204>

GUIDELINES FOR ETHICS DOCUMENTS

<https://www.wjgnet.com/bpg/GerInfo/287>

GUIDELINES FOR NON-NATIVE SPEAKERS OF ENGLISH

<https://www.wjgnet.com/bpg/gerinfo/240>

PUBLICATION ETHICS

<https://www.wjgnet.com/bpg/GerInfo/288>

PUBLICATION MISCONDUCT

<https://www.wjgnet.com/bpg/gerinfo/208>

ARTICLE PROCESSING CHARGE

<https://www.wjgnet.com/bpg/gerinfo/242>

STEPS FOR SUBMITTING MANUSCRIPTS

<https://www.wjgnet.com/bpg/GerInfo/239>

ONLINE SUBMISSION

<https://www.f6publishing.com>

Mucinous appendiceal neoplasm: A case report

Alexandru Chirca, Lucian Negreanu, Andreea Iliesiu, Radu Costea

ORCID number: Alexandru Chirca 0000-0002-2086-8689; Lucian Negreanu 0000-0003-3042-0754; Andreea Iliesiu 0000-0001-5075-6584; Radu Costea 0000-0003-0509-693X.

Author contributions: All authors were involved in the care of patient, writing and corrections and approved the final version of the manuscript.

Informed consent statement: Informed written consent was obtained from the patient for publication of this report and any accompanying images.

Conflict-of-interest statement: The authors declare that they have no conflict of interest.

CARE Checklist (2016) statement: The authors have read the CARE Checklist (2016), and the manuscript was prepared and revised according to the CARE Checklist (2016).

Open-Access: This article is an open-access article that was selected by an in-house editor and fully peer-reviewed by external reviewers. It is distributed in accordance with the Creative Commons Attribution NonCommercial (CC BY-NC 4.0) license, which permits others to distribute, remix, adapt, build upon this work non-commercially, and license their derivative works

Alexandru Chirca, Radu Costea, Surgery II Department, University Hospital, Carol Davila University, Bucharest, Bucharest 050098, Romania

Lucian Negreanu, Gastroenterology II Department, University Hospital, Carol Davila University, Bucharest, Bucharest 050098, Romania

Andreea Iliesiu, Pathology Department, University Hospital, Carol Davila University, Bucharest, Bucharest 050098, Romania

Corresponding author: Lucian Negreanu, MD, PhD, Professor, Gastroenterology II, University Hospital, Carol Davila University, Bucharest, Splaiul independentei 169, sector 5, Bucharest, Bucharest 050098, Romania. lucian.negreanu@umfcd.ro

Abstract

BACKGROUND

Primary appendiceal tumors are histologically diverse and have an insidious onset and few specific clinical manifestations. In the majority of cases, these tumors are discovered after appendectomy during pathological exam of the resected tissue. Treatment may include appendectomy (simple or radical) and right hemicolectomy depending on factors such as histological type, tumor size and lymph node/organ involvement. The aim of this case study is to describe a rare case of a giant appendicular mucocele and raise awareness of this condition and its management options and follow-up protocol.

CASE SUMMARY

We present the case of a 43-year-old patient who presented to our emergency department with mild right lower quadrant pain. After the initial check-up and imaging exams, he underwent surgery, where a giant 20 cm × 13 cm appendicular tumor was found and resected. Appendicular mucocele was suspected due to the macroscopic appearance and was later confirmed by the pathological exam. The patient's postoperative evolution was uneventful, and after discharge, he was included in our follow-up program.

CONCLUSION

In conclusion, mucinous appendiceal neoplasms embody a rare pathology; they are asymptomatic or have few, unspecific clinical signs and in many cases are discovered after appendectomy.

Key Words: Appendiceal tumors; Appendicular mucocele; Mucinous appendiceal neoplasms; Case report

on different terms, provided the original work is properly cited and the use is non-commercial. See: <http://creativecommons.org/licenses/by-nc/4.0/>

Manuscript source: Unsolicited manuscript

Specialty type: Surgery

Country/Territory of origin: Romania

Peer-review report's scientific quality classification

Grade A (Excellent): 0
Grade B (Very good): 0
Grade C (Good): C
Grade D (Fair): 0
Grade E (Poor): 0

Received: October 25, 2020

Peer-review started: October 25, 2020

First decision: November 26, 2020

Revised: December 5, 2020

Accepted: December 29, 2020

Article in press: December 29, 2020

Published online: March 6, 2021

P-Reviewer: Harada K

S-Editor: Chen XF

L-Editor: A

P-Editor: Xing YX



©The Author(s) 2021. Published by Baishideng Publishing Group Inc. All rights reserved.

Core Tip: Mucinous appendiceal neoplasms represents a rare pathology with unspecific sometimes asymptomatic clinical signs. Preoperative diagnosis or suspicion is important for the operative strategy. Based on staging and histological findings, simple or radical appendectomy using open or laparoscopic approach can be safely performed for low-grade appendiceal mucinous neoplasm, if the diagnostic criteria are met.

Citation: Chirca A, Negreanu L, Iliesiu A, Costea R. Mucinous appendiceal neoplasm: A case report. *World J Clin Cases* 2021; 9(7): 1728-1733

URL: <https://www.wjgnet.com/2307-8960/full/v9/i7/1728.htm>

DOI: <https://dx.doi.org/10.12998/wjcc.v9.i7.1728>

INTRODUCTION

Mucinous appendiceal neoplasms represent a rare and poorly understood heterogeneous pathology that is present in less than 0.3% of all appendectomies^[1,2]. They have a very low incidence in the general population, with age at diagnosis between 50 and 60 years and a male-to-female ratio slightly in favor of the latter^[1,3]. These types of neoplasms are incidentally discovered during appendectomies or in routine imaging for other conditions^[4]. From a clinical point of view, patients are often asymptomatic or present with right lower quadrant (RLQ) abdominal pain mimicking appendicitis; in most cases, laboratory findings are unspecific^[5].

Complications depend on tumor size and histological type and can range from intestinal obstruction and bleeding to spontaneous perforation and peritoneal dissemination causing pseudomyxoma peritonei (PMP)^[3,6].

In surgical treatment, the open approach is preferred to laparoscopic surgery for large appendiceal tumors due to the risk of iatrogenic rupture and mucin spread in the peritoneal cavity that can cause PMP, although minimally invasive approaches such as the robotic-assisted approach and the hand-assisted laparoscopic approach can be considered safe in the resection of appendiceal mucocèles in selected patients^[7-11]. We present our experience in a case of a giant appendiceal mucocèle as well as diagnostic methods, surgical management and prognosis for this rare pathology and we discuss the main problems encountered in the management of the case.

CASE PRESENTATION

Chief complaints

A 43-year-old overweight male patient with no prior medical history presented to the emergency department complaining of mild RLQ pain in the abdomen with a duration of 4 h.

History of present illness

The pain started 4 h before and was constant, located in the RLQ with no irradiation.

History of past illness

No data were available.

Personal and family history

No data were available.

Physical examination

The clinical exam revealed only mild pain during the palpation of the RLQ, and usual laboratory findings were normal.

Laboratory examinations

Further laboratory findings revealed normal carcinoembryonic antigen and cancer

antigen 19-9 Levels.

Imaging examinations

The patient underwent an abdominal ultrasound that found a large, 20 cm × 13 cm, multiseptated cystic mass in the RLQ (Figure 1). Computed tomography (CT) imaging was performed using intravenous contrast (Iomeron®) and revealed a well-defined 210 mm × 135 mm × 129 mm cystic mass that communicated with the cecum and ended like “a finger in a glove” with no other lesions (Figure 2).

FINAL DIAGNOSIS

The suspicion of appendiceal mucocoele was raised.

TREATMENT

The patient was admitted to the surgical department for further investigation and surgery. Due to the size of the cystic mass and the lack of definitive diagnosis pre-operatively, we opted for an open procedure, and a lower midline incision was performed. The open approach in this case permitted an evaluation of the lesion, its implantation base and was the less risky for an iatrogenic rupture.

OUTCOME AND FOLLOW-UP

During laparotomy, a giant appendiceal tumor with a thin fibrous wall was found, accompanied by a small quantity of serous peritoneal fluid that was gathered for cytological and bacteriological study. The tumor had an unmodified base of implantation in the cecum (Figure 3), and no lymphadenopathy or hepatic metastasis was found. The tumor's posterior wall and appendiceal tip were adherent to the mesentery through well-defined adhesions. Based on these findings simple appendectomy was performed after careful adhesion lysis. Further exploration of the abdominal cavity did not reveal any additional lesions. Single tube peritoneal drainage was followed by scar closure, and the resected mass was sent to the pathological department for further study. The results of the bacteriological exam of the peritoneal fluid collected during surgery was negative, and the cytological exam of the same fluid showed that only a few inflammatory cells were present with absence of mucin or epithelial cells. The pathological exam indicated that the mass was a low-grade appendiceal mucinous neoplasm (LAMN) that extended into the muscularis propria and was associated with an R0 type excision margin (Figure 4). The typical findings included flattened epithelial growth, expansive growth into the muscularis, dissection of mucin into the wall, fibrosis of the serosa but no high grade cytologic atypia as opposed to HAMN. Postoperative staging revealed a pTisN0M0 stage 0 LAMN (confined to the muscularis propria with mucin or mucinous epithelium may extend into the muscularis propria).

The patient did well after surgery, was discharged on the 7th hospital day, 5 d after surgery, and is presently included in our follow-up program, which consists of alternating abdominal ultrasound and CT scans every 6 mo for the next 2 years.

DISCUSSION

Appendiceal lesions are a rare entity; in a 10-year Dutch study, the incidence of appendiceal lesions was approximately 9 per million persons per year, with one in 113 resected appendices presenting a lesion (benign or malignant in nature)^[1]. The benign-to-malignant ratio was approximately three to one, although more recent studies present a higher disease incidence, malignant lesion rate and decreased age at diagnosis^[1,12,13]. Due to confusion in diagnostic terminology, contentious for many years, a consensus on classification has been reached by the Peritoneal Surface Oncology Group, grouping mucinous appendiceal neoplasms into adenoma, LAMNs, high-grade appendiceal mucinous neoplasms and mucinous adenocarcinomas^[14].

Patients with appendiceal tumors have unspecific clinical signs or are

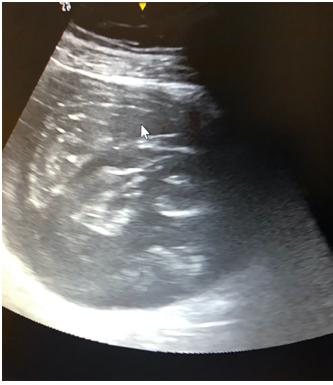

Figure 1 Ultrasound examination showing a voluminous septate cystic mass.

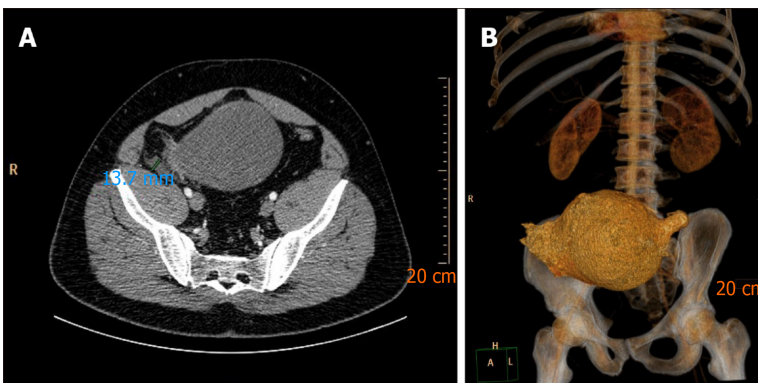


Figure 2 Computed tomography findings. A: Computed tomography (CT) scan showing voluminous cystic tumor communicating with the cecum; B: CT scan showing reconstruction image of the same lesion.

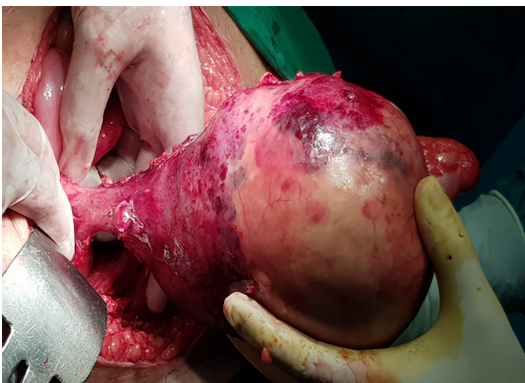

Figure 3 Intra-operative view of a large tumor implanted in the cecum.

asymptomatic, and in almost half of cases, they are diagnosed with acute appendicitis; therefore, preoperative imaging plays an important role not only in diagnosis but also in operative strategy^[12]. Ultrasound, which is fairly sensitive, is best suited for suspected cases and, when complemented by CT, is largely used for the diagnosis, staging and follow-up of appendiceal tumors. However, magnetic resonance imaging (MRI) is more sensitive in identifying peritoneal disease^[15]. Sometimes access to MRI is difficult in emergency cases, as it was in our patient, CT remaining the best available choice.

The standard of treatment in appendiceal tumors for many years has been appendectomy (for tumors under 2 cm) and right hemicolectomy (for tumors larger than 2 cm), although studies have suggested that an intact mucocoele with a normal base of implantation in the cecum is in most cases a rather benign lesion and simple, radical appendectomy can suffice with no difference in survival between these types of

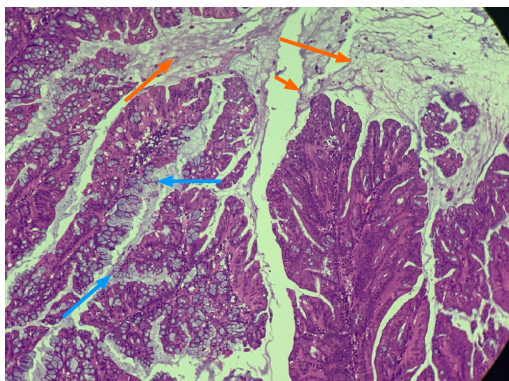


Figure 4 Hematoxylin and eosin stain (40 ×) depicting villous mucin secreting dysplastic epithelium (blue arrows) with dissecting pools of mucin (orange arrows).

procedures^[3,7-11,16,17].

In situations where total removal of the primary tumor cannot be performed by simple or radical appendectomy, where tumor lymph node involvement is found, or when a nonmucinous neoplasm type is present during pathological exam, right hemicolectomy is recommended as the standard procedure^[7-11]. Laparoscopic surgery has gained ground over the open approach in the last two decades, although open surgery can be more reliable in large and giant tumors due to the risk of iatrogenic rupture and mucin spread in the peritoneal cavity^[7-11]. Having this in mind, we preferred the open approach in our case in order to perform a complete local resection and then determine whether additional surgery is needed based on the final pathological results of the excised specimen. We also believe that especially for large lesions the open surgical approach allows a better damage control of the potential rupture and iatrogenic lesions. Also intraoperative findings allowed us to perform simple appendectomy, thus avoiding a right hemicolectomy in a young patient.

CONCLUSION

Mucinous appendiceal neoplasms are a rare pathology that present with unspecific clinical signs and, in many cases, are asymptomatic. Preoperative diagnosis or suspicion is important for the operative strategy and choice of operating technique. Based on histological findings and careful staging, simple or radical appendectomy can be safely performed for LAMN if the criteria are met.

REFERENCES

- 1 **Smeenk RM**, van Velthuysen ML, Verwaal VJ, Zoetmulder FA. Appendiceal neoplasms and pseudomyxoma peritonei: a population based study. *Eur J Surg Oncol* 2008; **34**: 196-201 [PMID: 17524597 DOI: 10.1016/j.ejso.2007.04.002]
- 2 **Shaib WL**, Assi R, Shamseddine A, Alese OB, Staley C 3rd, Memis B, Adsay V, Bekaii-Saab T, El-Rayes BF. Appendiceal Mucinous Neoplasms: Diagnosis and Management. *Oncologist* 2017; **22**: 1107-1116 [PMID: 28663356 DOI: 10.1634/theoncologist.2017-0081]
- 3 **Spyropoulos C**, Rentis A, Alexaki E, Triantafyllidis JK, Vagianos C. Appendiceal mucocoele and pseudomyxoma peritonei; the clinical boundaries of a subtle disease. *Am J Case Rep* 2014; **15**: 355-360 [PMID: 25163976 DOI: 10.12659/AJCR.890837]
- 4 **Wang H**, Chen YQ, Wei R, Wang QB, Song B, Wang CY, Zhang B. Appendiceal mucocoele: A diagnostic dilemma in differentiating malignant from benign lesions with CT. *AJR Am J Roentgenol* 2013; **201**: W590-W595 [PMID: 24059397 DOI: 10.2214/AJR.12.9260]
- 5 **Saad EA**, Elsamani EY, Abdelrahim WE, Elsiddig KE, Khalil EAG. Surgical treatment of mucocoele of the appendix: a systematic review and case report. *J Surg Case Rep* 2018; **2018**: rjy102 [PMID: 29991998 DOI: 10.1093/jscr/rjy102]
- 6 **Derelle AL**, Tissier S, Granger P, Barbary C, Rousseau A, Laurent V, Tortuyaux JM, Marchal F, Régent D. [Early diagnosis of pseudomyxoma peritonei localized to perforated appendiceal mucocoele: imaging and pathologic aspects]. *J Radiol* 2007; **88**: 289-295 [PMID: 17372560]
- 7 **Rampone B**, Roviello F, Marrelli D, Pinto E. Giant appendiceal mucocoele: report of a case and brief review. *World J Gastroenterol* 2005; **11**: 4761-4763 [PMID: 16094726 DOI: 10.3748/wjg.v11.i24.4761]

- 10.3748/wjg.v11.i30.4761]
- 8 **Caiazzo P**, Comentale A, Rampone B, Di Lascio P, Morlino A, Pastore M, Del Vecchio G, Tramutoli PR. [Giant appendiceal mucocoele during laparotomy for acute abdomen. Report of a case and brief review]. *G Chir* 2010; **31**: 511-513 [PMID: [21232194](#)]
 - 9 **Orcutt ST**, Anaya DA, Malafa M. Minimally invasive appendectomy for resection of appendiceal mucocoele: Case series and review of the literature. *Int J Surg Case Rep* 2017; **37**: 13-16 [PMID: [28618350](#) DOI: [10.1016/j.ijscr.2017.05.027](#)]
 - 10 **Park KB**, Park JS, Choi GS, Kim HJ, Park SY, Ryuk JP, Choi WH, Jang YS. Single-incision Laparoscopic Surgery for Appendiceal Mucocoeles: Safety and Feasibility in a Series of 16 Consecutive Cases. *J Korean Soc Coloproctol* 2011; **27**: 287-292 [PMID: [22259743](#) DOI: [10.3393/jksc.2011.27.6.287](#)]
 - 11 **Dhage-Ivatury S**, Sugarbaker PH. Update on the surgical approach to mucocoele of the appendix. *J Am Coll Surg* 2006; **202**: 680-684 [PMID: [16571440](#) DOI: [10.1016/j.jamcollsurg.2005.12.003](#)]
 - 12 **Tajima T**, Tajiri T, Mukai M, Sugiyama T, Hasegawa S, Yamamoto S, Sadahiro S, Shimada H, Makuuchi H. Single-center analysis of appendiceal neoplasms. *Oncol Lett* 2018; **15**: 6393-6399 [PMID: [29731850](#) DOI: [10.3892/ol.2018.8134](#)]
 - 13 **van den Heuvel MG**, Lemmens VE, Verhoeven RH, de Hingh IH. The incidence of mucinous appendiceal malignancies: a population-based study. *Int J Colorectal Dis* 2013; **28**: 1307-1310 [PMID: [23695388](#) DOI: [10.1007/s00384-013-1714-9](#)]
 - 14 **Carr NJ**, Bibeau F, Bradley RF, Dartigues P, Feakins RM, Geisinger KR, Gui X, Isaac S, Milione M, Misdraji J, Pai RK, Rodriguez-Justo M, Sobin LH, van Velthuisen MF, Yantiss RK. The histopathological classification, diagnosis and differential diagnosis of mucinous appendiceal neoplasms, appendiceal adenocarcinomas and pseudomyxoma peritonei. *Histopathology* 2017; **71**: 847-858 [PMID: [28746986](#) DOI: [10.1111/his.13324](#)]
 - 15 **Leonards LM**, Pahwa A, Patel MK, Petersen J, Nguyen MJ, Jude CM. Neoplasms of the Appendix: Pictorial Review with Clinical and Pathologic Correlation. *Radiographics* 2017; **37**: 1059-1083 [PMID: [28598731](#) DOI: [10.1148/rg.2017160150](#)]
 - 16 **Misdraji J**, Yantiss RK, Graeme-Cook FM, Balis UJ, Young RH. Appendiceal mucinous neoplasms: a clinicopathologic analysis of 107 cases. *Am J Surg Pathol* 2003; **27**: 1089-1103 [PMID: [12883241](#) DOI: [10.1097/00000478-200308000-00006](#)]
 - 17 **González-Moreno S**, Sugarbaker PH. Radical appendectomy as an alternative to right colon resection in patients with epithelial appendiceal neoplasms. *Surg Oncol* 2017; **26**: 86-90 [PMID: [28317590](#) DOI: [10.1016/j.suronc.2017.01.006](#)]



Published by **Baishideng Publishing Group Inc**
7041 Koll Center Parkway, Suite 160, Pleasanton, CA 94566, USA

Telephone: +1-925-3991568

E-mail: bpgoffice@wjgnet.com

Help Desk: <https://www.f6publishing.com/helpdesk>

<https://www.wjgnet.com>

