

World Journal of *Meta-Analysis*

World J Meta-Anal 2019 May 31; 7(5): 184-258





REVIEW

- 184 Current state and future direction of screening tool for colorectal cancer
Hong JT, Kim ER

MINIREVIEWS

- 209 Hepatitis B reactivation in patients with hepatitis B core antibody positive and surface antigen negative on immunosuppressants
Wu CCH, Kumar R
- 218 Present state of endoscopic ultrasonography-guided fine needle aspiration for the diagnosis of autoimmune pancreatitis type 1
Sugimoto M, Takagi T, Suzuki R, Konno N, Asama H, Sato Y, Irie H, Watanabe K, Nakamura J, Kikuchi H, Takasumi M, Hashimoto M, Hikichi T, Ohira H

SYSTEMATIC REVIEW

- 224 Hepatic gastrointestinal stromal tumor: Systematic review of an exceptional location
Manuel-Vázquez A, Latorre-Fragua R, de la Plaza-Llamas R, Ramia JM
- 234 Scoring criteria for determining the safety of liver resection for malignant liver tumors
Harada K, Nagayama M, Ohashi Y, Chiba A, Numasawa K, Meguro M, Kimura Y, Yamaguchi H, Kobayashi M, Miyanishi K, Kato J, Mizuguchi T

META-ANALYSIS

- 249 Pancreatic stents to prevent post-endoscopic retrograde cholangiopancreatography pancreatitis: A meta-analysis
Sugimoto M, Takagi T, Suzuki R, Konno N, Asama H, Sato Y, Irie H, Watanabe K, Nakamura J, Kikuchi H, Takasumi M, Hashimoto M, Hikichi T, Ohira H

ABOUT COVER

Editorial Board Member of *World Journal of Meta-Analysis*, Singh Rajender, PhD, Senior Scientist, Endocrinology Division, Central Drug Research Institute, Lucknow 226001, India

AIMS AND SCOPE

The *World Journal of Meta-Analysis* (WJMA) is an online, open-access, single-blind peer-reviewed journal that is published by Baishideng Publishing Group. Accepting both solicited and unsolicited manuscripts, the WJMA mainly publishes high quality meta-analysis and systematic review articles to lead the development of various fields of clinical medicine. The type of articles published in the WJMA include the editorial, minireview, review, meta-analysis, meta-regression, systematic review, and evidence-based practice.

The primary aim of the WJMA is to provide scholars and readers from various fields of clinical medicine with a platform to publish high quality meta-analysis and systematic review articles and communicate their research findings online.

The WJMA mainly publishes research results and findings obtained through meta-analysis and systematic review in a wide range of areas, including medicine, pharmacy, preventive medicine, stomatology, nursing, medical imaging, and laboratory medicine.

INDEXING/ABSTRACTING

The WJMA is now abstracted and indexed in Emerging Sources Citation Index (Web of Science), China National Knowledge Infrastructure (CNKI), China Science and Technology Journal Database (CSTJ), and Superstar Journals Database

**RESPONSIBLE EDITORS
FOR THIS ISSUE**

Responsible Electronic Editor: Yun-Xiaojian Wu Proofing Editorial Office Director: Jin-Lei Wang

NAME OF JOURNAL

World Journal of Meta-Analysis

ISSN

ISSN 2308-3840 (online)

LAUNCH DATE

May 26, 2013

FREQUENCY

Irregular

EDITORS-IN-CHIEF

Giuseppe Biondi-Zoccai

EDITORIAL BOARD MEMBERS

<https://www.wjnet.com/2308-3840/editorialboard.htm>

EDITORIAL OFFICE

Jin-Lei Wang, Director

PUBLICATION DATE

May 31, 2019

COPYRIGHT

© 2019 Baishideng Publishing Group Inc

INSTRUCTIONS TO AUTHORS

<https://www.wjnet.com/bpg/gerinfo/204>

GUIDELINES FOR ETHICS DOCUMENTS

<https://www.wjnet.com/bpg/GerInfo/287>

GUIDELINES FOR NON-NATIVE SPEAKERS OF ENGLISH

<https://www.wjnet.com/bpg/gerinfo/240>

PUBLICATION MISCONDUCT

<https://www.wjnet.com/bpg/gerinfo/208>

ARTICLE PROCESSING CHARGE

<https://www.wjnet.com/bpg/gerinfo/242>

STEPS FOR SUBMITTING MANUSCRIPTS

<https://www.wjnet.com/bpg/GerInfo/239>

ONLINE SUBMISSION

<https://www.f6publishing.com>

Hepatic gastrointestinal stromal tumor: Systematic review of an exceptional location

Alba Manuel-Vázquez, Raquel Latorre-Fragua, Roberto de la Plaza-Llamas, José Manuel Ramia

ORCID number: Alba Manuel-Vázquez (0000-0002-3267-0274); Raquel Aranzazu Latorre-Fragua (0000-0001-5311-0025); Roberto de la Plaza-Llamas (0000-0001-9501-5480); José M Ramia (0000-0003-1186-953X).

Author contributions: Manuel-Vázquez A designed the study, performed the research, analyzed data and wrote the paper. Latorre-Fragua R performed the research, analyzed and interpreted of data. de la Plaza-Llamas R critically reviewed. Ramia JM critically reviewed, finally approved and supervised the report.

Conflict-of-interest statement: The authors have no conflict of interest to declare.

PRISMA 2009 Checklist statement: The authors have read the PRISMA 2009 Checklist, and the manuscript was prepared and revised according to the PRISMA 2009 Checklist.

Open-Access: This article is an open-access article which was selected by an in-house editor and fully peer-reviewed by external reviewers. It is distributed in accordance with the Creative Commons Attribution Non Commercial (CC BY-NC 4.0) license, which permits others to distribute, remix, adapt, build upon this work non-commercially, and license their derivative works on different terms, provided the original work is properly cited and the use is non-commercial. See: <http://creativecommons.org/licenses/by-nc/4.0/>

Alba Manuel-Vázquez, Raquel Latorre-Fragua, Roberto de la Plaza-Llamas, José Manuel Ramia, General and Digestive Surgery, University Hospital of Guadalajara, Guadalajara 19002, Spain

Corresponding author: Alba Manuel Vázquez, MD, PhD, Doctor, Surgeon, Surgical Oncologist, General and Digestive Surgery, University Hospital of Guadalajara, Calle donante de sangre s/n, Guadalajara 19002, Spain. alba_manuel_vazquez@hotmail.com
Telephone: +34-949-209200

Abstract

BACKGROUND

A minor subset of primary gastrointestinal stromal tumors (GIST) can also arise outside the gastrointestinal tract, which is known as an extra-GIST (E-GIST). Primary GIST of the liver is an exceptional location.

AIM

To characterize epidemiological, clinical and pathological features and options of treatments.

METHODS

We performed a systematic review to search for articles on primary hepatic GIST.

RESULTS

This review shows that right hepatic lobe was the most frequent location. Regarding pathological and immunohistochemical features, mitotic count was $\geq 5/50$ High Power Fields in more than 50%; and CD117 was negative in only 1 patient. More than 70% of patients had a lesion with high risk of malignancy.

CONCLUSION

The diagnosis of E-GIST must be considered in a liver mass. Rendering an accurate diagnosis is a challenge, as well as the confirmation of their primary or metastatic nature.

Key words: Gastrointestinal stromal tumors; Extra-gastrointestinal stromal tumor; Primary hepatic tumor; CD117; Primary hepatic gastrointestinal stromal tumor; Primary gastrointestinal stromal tumor of the liver

©The Author(s) 2019. Published by Baishideng Publishing Group Inc. All rights reserved.

Core tip: A great majority of primary gastrointestinal stromal tumors (GISTs) outside the gastrointestinal tract (GI) are metastases; however, a minor subset of primary GISTs can

Manuscript source: Invited manuscript

Received: April 3, 2019

Peer-review started: April 3, 2019

First decision: April 30, 2019

Revised: May 11, 2019

Accepted: May 22, 2019

Article in press: May 26, 2019

Published online: May 31, 2019

P-Reviewer: Misiakos EP, Milone M

S-Editor: Dou Y

L-Editor: A

E-Editor: Wu YXJ



also arise outside the GI tract which is known as an extra-GIST (E-GIST). Among E-GIST, liver is an exceptional location. We systematically review the literature on primary GIST of the liver. Primary hepatic EGISTs have a male predominance and usually are incidental findings. The surgical approach is commonly performed, and the final diagnosis is made by pathological, immunohistochemical and molecular analysis. Primary hepatic EGISTs are often high-risk lesions. Literature is scarce and it is very difficult to establish guidelines for clinicians.

Citation: Manuel-Vázquez A, Latorre-Fragua R, de la Plaza-Llamas R, Ramia JM. Hepatic gastrointestinal stromal tumor: Systematic review of an exceptional location. *World J Meta-Anal* 2019; 7(5): 224-233

URL: <https://www.wjgnet.com/2308-3840/full/v7/i5/224.htm>

DOI: <https://dx.doi.org/10.13105/wjma.v7.i5.224>

INTRODUCTION

Gastrointestinal stromal tumors (GISTs) are a group of mesenchymal tumors characterized by the expression of KIT protein (CD117), with an overall incidence between 10-20 per million, which harbor different clinical behavior^[1,2]. These are the most common mesenchymal neoplasm of the gastrointestinal tract, which represent 0.1%-3% of all gastrointestinal neoplasms^[3,4].

Regarding the pathogenesis, GISTs are believed to originate from interstitial cells of Cajal (ICC), the pacemaker of gastrointestinal tract^[5-7], or to a common precursor cell of ICCs and smooth muscle cells^[8]. So, GISTs may arise anywhere along the gastrointestinal tract. Approximately 60%-70% of GIST occurs in the stomach, followed by 20%-30% in small intestine; colon and rectum (5%), esophagus (< 2%) and appendix are less frequent^[9,10].

A great majority of GISTs outside the GI tract are metastases from GI GISTs; however, a minor subset of primary GIST can also arise outside the GI tract which is known as an extra-GIST (E-GIST). According to Miettinen *et al*^[11], the frequency of EGISTs is no higher than 1% of all GISTs of defined origin, and they are characterized by the same morphological, immunohistochemical and molecular characteristic than conventional GIST^[12].

Regarding embryology, the origin of EGISTs remains controversial, with certain hypotheses. Since some researchers have observed "ICC-like" cells with a similar structure and function to ICCs in organs outside of the GI tract^[13,14], it is reasonable to presume that EGISTs originate from this common precursor cells of ICC. Other authors suggest that EGISTs may originate from a pool of undifferentiated pluripotent mesenchymal stem cells located outside GI tract, and then differentiate into ICCs^[15-17].

Among E-GIST, mesentery, retroperitoneum and pancreas are the most frequent and this type of tumor has been reported in the omentum, bladder, gallbladder and ureter also; while, primary GIST of the liver is an exceptional location and its definitive diagnosis requires ruling out other types of liver mesenchymal tumors and other tumor types, such as sarcoma^[6,12,15].

Most studies of E-GISTs are case reports, lacking enough information to clarify the disease; therefore, it is very difficult to establish guidelines for clinicians. In addition, if we refer to primary hepatic E-GIST, the literature is much scarcer due to this exceptional location.

This study is a systematic review of the literature on primary GIST of the liver. Our aim is to identify clinical and diagnostic features and treatment in this exceptional location of this type of mesenchymal tumor.

MATERIALS AND METHODS

We performed a search for articles on primary hepatic GIST in MEDLINE (PubMed), Tripdatabase, and Cochrane Library databases, with no restrictions on publication dates or author up until January 31, 2019.

The search items comprise the following MESH terms: "Extra-gastrointestinal stromal tumors" OR "extra-gastrointestinal stromal tumor" OR "extra-gastrointestinal stromal neoplasm" OR "extra-gastrointestinal stromal neoplasms" OR "E-GIST" OR

“E-GISTs” and the following no MESH terms: “Primary malignant gastrointestinal stromal tumor of the liver” OR “Primary hepatic gastrointestinal stromal tumor” OR “Primary gastrointestinal stromal tumor of the liver”.

The articles were included or rejected based on the information obtained from the title and summary, and in case of doubt, after reading the complete article.

To evaluate the quality of the studies selected, we used the scale designed by Manterola *et al*^[18] which evaluates each publication individually depending on the type of study, the sample size, and the methodology used. It has a range of 6 to 36 points, with a quality cutoff point of 18. We carried out a qualitative analysis of the studies included and their conclusions, based on the levels of evidence and degrees of recommendation proposed by Cook *et al*^[19].

RESULTS

After the both initial searches, 420 articles were obtained. Only 23 (5.48%) met the search criteria, one of which were excluded because language (one in Romanian). The flowchart diagram is shown in Figure 1. We included 22 articles, including 23 patients^[1,3,6,20-38].

The mean age was 56.18 years (± 15.4 SD), with a slightly male predominance (12/23). According country, 18 patients were from Southeast Asian, with 11 cases from China; while only 5 came from Western (France, Spain, Italy, United States). Right lobe was the most frequent location (12/23; 52.17%), and bilobar extension was present in 4 patients. Liu *et al*^[28] report the coexistence of a hepatic and a pancreatic primary lesion. The median size was 15 cm (range: 2.2-27 cm). Among the symptoms, nearly 50% of patients (10/23) have no symptoms, being incidental finding during follow-up or extension study for gastric cancer in 2 of them (Table 1)

Regarding the diagnosis referred in Table 2, upper and lower endoscopy studies were performed in 9 patients, with no findings in 8 cases and an early gastric cancer in the other (biopsy: signet ring cell carcinoma). Biopsy of hepatic lesion was performed in 8 patients; one of them was surgical one.

Regarding the treatment of the selected patients, the management was surgical in 16 cases, ranging from limited surgical excision or anatomic resection to liver transplantation or extracorporeal resection and auto transplantation.

Two patients were received local treatment, with radiofrequency ablation (RFA) and microwave ablation. Luo *et al*^[37] report a central hepatic lesion in a young patient. Liu *et al*^[28] report a pancreatic primary E-GIST coexisting with another hepatic primary E-GIST, where both lesions were treated by RFA.

There were two refusals for treatment; in one case the patient refused surgery and received imatinib mesylate, and the other refused any action. In only one patient, the finding was a non-resectable hepatic lesion and the patient was treated with imatinib mesylate (Table 3).

Regarding pathological, molecular and immunohistochemical findings, the most frequent cell type was spindle cells (17/23, 73.91%); molecular analysis was performed in 6 patients, with mutation in 5/6; mitotic count was $\geq 5/50$ High Power Fields in 12 cases (52.17%); and CD117 was negative in only 1 patient. The risk of malignancy was classified according to Fletcher *et al*^[2] and 17/23 (73.91%) patients had a lesion with high risk of malignancy (Table 4).

Mean follow-up was 14 mo (range: 3-252). During the follow-up, 10 patients were disease-free (follow-up: 3-30 mo) (Table 5).

DISCUSSION

Since Hu *et al*^[6] reported the first primary hepatic GIST in 2003, we should consider that not all tumors of the liver with GIST features are metastasis and the liver could itself be the primary GISTs location.

Primary hepatic E-GISTs are extremely uncommon compared with their alimentary counterparts; thus, E-GISTs presenting in the liver raise a difficult diagnosis, management and prognosis^[22].

In this review, primary E-GISTs of the liver have a slightly male predominance and the reported cases have a Southeast Asian predominance. Regarding symptoms, almost 50% have no clinical manifestations; among symptomatic patients, the symptoms are vague compared to GISTs, which commonly present with GI bleeding, abdominal pain, a palpable mass, weight loss, nausea and vomiting^[12]. Also, the size of the hepatic lesion may become larger, mean 15 cm in our review.

Once we find a tumor with GIST characteristics presenting in the liver, the main

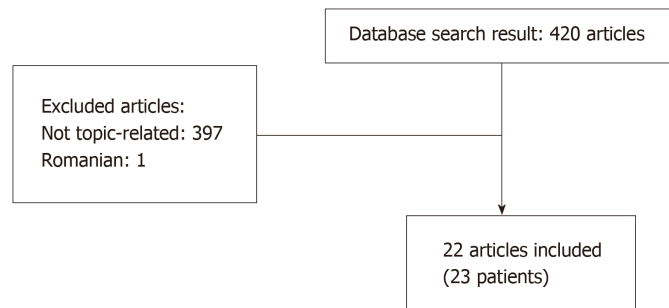


Figure 1 Flowchart.

challenge is determining whether this lesion is primary or metastatic, considering the liver is the most common site of distant metastasis for malignant GIST^[21,28].

All of the studies included in this systematic review are case report, lacking enough information to clarify the disease and making difficult to establish protocols. The differential diagnosis is the main challenge for primary hepatic E-GISTs, but there are no consensus guidelines. According to Joyon *et al*^[21], the diagnosis of primary E-GIST of the liver could be considered if these conditions are present: (1) Absence of GIST in the GI tract, with endoscopic and imaging studies; and absence of connection with the muscularis propria of the GI tract; (2) Absence of any past medical history which might suggest the resection of an overlooked or misdiagnosed GIST; and (3) Absence of GI tumor diagnosed during follow-up.

Thus, every hepatic GIST should be considered metastatic until no grossly nor histologically evidence of association with the muscularis propria have been shown and the remote medical history has been carefully explored, and no primary tumor could be found on long-term follow up^[39]. Not all case included in this systematic review have been described enough information to be sure that all these requirements are fulfilled. In one hand, Kim *et al*^[32] reported a patient with two synchronous lesions, an early gastric cancer and a primary hepatic GIST. Their preoperative diagnosis was a malignant hepatic lesion with an early gastric cancer, due to presence of signet ring cells in gastric carcinoma and radiological features of liver tumor. After surgery, the pathological study showed an early gastric cancer in the lesser gastric curvature, with signet ring cell carcinoma features, and spindle cells with a positive reactivity CD117 in hepatic tumor. Nagai *et al*^[25] reported a hepatic primary E-GIST in a patient with a previous gastric cancer 7 years earlier. Histologically, gastric cancer was a poorly differentiated adenocarcinoma, with lymph node involvement. When the hepatic mass was founded, upper and lower gastrointestinal endoscopic studies were performed, with no findings. Microscopically, the hepatic tumor was composed of spindle cells, with positive results for KIT and CD34^[25]. Ochiai *et al*^[38] reported a patient with surgical resection of a primary hepatic GIST, based on the positive immunostaining for CD34 and c-kit, and recurrent hepatic lesion and submucosal gastric tumor 2 years after first operation. After surgical removal of both hepatic and gastric lesions, both specimens showed GIST features with expression of c-kit and CD34, but the different morphological and molecular findings (gastric lesion: spindle cells and mutation in exon of c-kit; hepatic tumor: round cells and no mutation at exon 11) were enough for the authors to conclude that the hepatic GIST and gastric tumor were independent. In these patients, the different histological and immunohistochemical findings were the reason to define the hepatic lesion as a primary E-GIST. On the other hand, Liu *et al*^[28] reported two synchronous E-GISTs. The patient presented a 5 cm-pancreatic mass and a 2 cm-hepatic lesion, with the same radiological features, and no other lesions in upper/lower gastrointestinal endoscopic examinations. With the diagnosis of malignant pancreatic cancer with hepatic metastases, the authors performed a surgical fine-needle aspiration and pathological findings in the hepatic and pancreatic biopsy tissues indicated that the tumors were mitotic spindle cell with CD117+^[28]. The authors conclude that they are two independent lesions due to the pancreas and liver are exceptional location for primary GIST.

EGISTs have the same morphological, immunohistochemical and molecular features than conventional GISTs, including metastatic ones^[12]. The criteria for the histopathological diagnosis are now firmly established; tumor cells might present a spindle or an epithelioid appearance and show a distinctive immunophenotype characterized by the expression of KIT (CD 117)^[2,28,40]. Thus, the definitive diagnosis relies on the histopathological examination^[41]; however, none of the pathological

Table 1 Clinical characteristics and location in selected patients with extra-gastrointestinal stromal tumor of the liver

Ref.	Yr	Age / Sex	Country	Presentation	Location	Size (cm)	Multifocal
Hu <i>et al</i> ^[20]	2018	79/F	China	Epigastric discomfort	RL	3.2	No
Joyon <i>et al</i> ^[21]	2018	56/M	France	Abdominal pain	Bilobar (Segments VII/VIII and LL)	10	Yes
	2018	59/F	France	Abdominal pain, weight loss	RL	23	No
Carrillo <i>et al</i> ^[22]	2017	41/M	Spain	Abdominal pain, weight loss	RL (S. V-VI)	20	No
Lok <i>et al</i> ^[23]	2017	50/F	China	Abdominal pain	RL	15	Yes
Cheng <i>et al</i> ^[24]	2016	63/M	China	No symptoms	RL	15	No
Nagai <i>et al</i> ^[25]	2016	70/F	Japan	Follow-up gastric cancer, No symptoms	LL	6	No
Liu <i>et al</i> ^[26]	2016	NA	China	NA	NA	NA	NA
Wang <i>et al</i> ^[27]	2016	61/M	China	No symptoms	Caudate lobe	7.3	No
Liu <i>et al</i> ^[28]	2016	56/F	China	No symptoms	LL + Pancreas	2.2	No
Su <i>et al</i> ^[29]	2015	65/M	Taiwan	Malaise, loss of appetite, abdominal pain	LL	12	No
Bhoy <i>et al</i> ^[3]	2014	41/F	India	Abdominal pain, weight loss	RL (S.VI-VI) I	15	Yes
Lin <i>et al</i> ^[30]	2015	67/F	China	No symptoms	RL	7.4	No
Mao <i>et al</i> ^[31]	2015	60/F	China	No symptoms	Bilobar (S I, IV, V, VIII)	12.8	No
Kim <i>et al</i> ^[32]	2014	71/M	Korea	Study for early gastric cancer, No symptoms	LL	7	No
Louis <i>et al</i> ^[33]	2014	55/F	India	Abdominal pain, loss of appetite	Bilobar (SII, III, VI, VIII)	14.5	Yes
Zhou <i>et al</i> ^[34]	2014	56/M	China	No symptoms	RL	10	No
Li <i>et al</i> ^[35]	2012	53/M	China	Abdominal discomfort	RL	20	No
Yamamoto <i>et al</i> ^[36]	2010	70/M	Japan	Loss of appetite (12 years after gastric cancer)	LL	20	No
Luo <i>et al</i> ^[37]	2009	17/M	China	No symptoms	RL	5	No
Ochiai <i>et al</i> ^[38]	2009	30/M	Japan	Abdominal fullness	Bilobar	27	No
De Chiara <i>et al</i> ^[1]	2006	37/M	Italy	No symptoms	RL (SV)	18	No
Hu <i>et al</i> ^[6]	2003	79/F	USA	Shortness of breath, pleuritic chest pain	RL	15	No

M: Male; F: Female; RL: Right lobe; LL: Left lobe; NA: Not available.

features is constant and required for a definitive diagnosis, including KIT mutation, which is not detectable in almost 5% of cases^[29,34]. The concerning of KIT-negative GISTs could be solved after the discovery of novel mutations of the platelet derived growth factor receptor alpha oncogene as alternative pathogenetic mechanism^[39].

In the majority of cases of E-GISTs, preoperative diagnosis is not possible; therefore, patients may be easily misdiagnosed with different types of cancer and surgery is performed to make a confirm diagnosis after histological examination.

The overall management of hepatic E-GISTs is generally based on the recommendations for GI GIST. A large spectrum of therapeutic options has been proposed depending on the initial presentation and clinical context. As with GISTs, complete surgical resection is the mainstay of treatment for E-GISTs, as long as the lesion is resectable^[24,28].

A guided tumor biopsy must be considered for non-resectable tumors in order to assess the diagnosis and to offer another option for treatment such as radiofrequency, arterial embolization or chemoembolization may be considered^[24,28,37]. The challenge is the risk of tumor rupture by the biopsy, well-known adverse prognostic factor in conventional GIST^[42].

For E-GIST and as with GI GISTs, imatinib mesylate may be administered preoperatively in locally advanced tumor in order to minimizing the size, for adjuvant treatment for patients with a high recurrence risk or for palliative treatment in non-resectable lesions, which is similar to the guidelines for their alimentary counterparts^[1,28,29,30,43]. Rediti *et al*^[44] in 2014 and Wada *et al*^[45] in 2012 reported the complete remission in a patient with greater omentum-mesentery E-GIST and a peritoneal E-GIST, respectively, who received only imatinib mesylate as a treatment.

On 2001, National Institutes of Health proposed a consensus classification system for defining the risk of malignant behavior, based on mitotic count and tumor size and now is widely in use, also for E-GIST^[2]. Joensuu *et al*^[46] proposed a new modified classification including primary tumor site and tumor rupture in the item for classifying the risk of GIST and the indication for adjuvant treatment.

Table 2 Diagnostic characteristics in selected patients with extra-gastrointestinal stromal tumor of the liver

Ref.	Yr	Age / Sex	Endoscopy	Imaging	Biopsy
Hu <i>et al</i> ^[20]	2018	79/F	Yes (no findings)	CT	No
Joyon <i>et al</i> ^[21]	2018	56/M	NA	CT	Percutaneous
	2018	59/F	Yes (no findings)	CT	Guided
Carrillo <i>et al</i> ^[22]	2017	41/M	Yes (no findings)	CT / MRI	No
Lok <i>et al</i> ^[23]	2017	50/F	Yes (no findings)	CT	No
Cheng <i>et al</i> ^[24]	2016	63/M	NA	CT	No
Nagai <i>et al</i> ^[25]	2016	70/F	Yes (no findings)	CT / MRI	No
Liu <i>et al</i> ^[26]	2016	NA	NA	NA	NA
Wang <i>et al</i> ^[27]	2016	61/M	NA	CT	No
Liu <i>et al</i> ^[28]	2016	56/F	NA	CT	Surgical
Su <i>et al</i> ^[29]	2015	65/M	NA	CT	CT-guided
Bhoy <i>et al</i> ^[3]	2014	41/F	NA	US/ CT	FNA
Lin <i>et al</i> ^[30]	2015	67/F	Yes (no findings)	CT	No
Mao <i>et al</i> ^[31]	2015	60/F	Yes (no findings)	CT / MRI	No
Kim <i>et al</i> ^[32]	2014	71/M	Early gastric cancer	CT / MRI	No
Louis <i>et al</i> ^[33]	2014	55/F	NA	CT	US-FNA/CT-FNA
Zhou <i>et al</i> ^[34]	2014	56/M	Yes (no findings)	NA	No
Li <i>et al</i> ^[35]	2012	53/M	NA	CT	US-FNAB
Yamamoto <i>et al</i> ^[36]	2010	70/M	NA	CT	No
Luo <i>et al</i> ^[37]	2009	17/M	NA	CT/US	US-FNA
Ochiai <i>et al</i> ^[38]	2009	30/M	NA	CT/ MRI	No
De Chiara <i>et al</i> ^[1]	2006	37/M	NA	CT	No
Hu <i>et al</i> ^[6]	2003	79/F	NA	CT	No

M: Male; F: Female; RL: Right lobe; NA: Not available; US: Ultrasound; CT: Computerized tomography; MRI: Magnetic resonance image; FNA: Fine needle aspiration.

Compared with GIST, E-GISTs have been reported to be accompanied by adverse prognostic factors, including a high proliferative index, large size and distant metastasis^[15]; so E-GIST is considered to exhibit a worse prognosis, with a higher malignant potential and risk of recurrence following surgery compared with GISTs in the GI tract^[2,11,15,24,26,42]. Disease free-survival and disease specific-survival of hepatic GISTs are significantly worse than those of gastric and small intestine GISTs and the location is an independent prognostic factor^[26]. There is a trend that E-GIST is an aggressive group with worse outcome. In this review, which includes only case reports, 10/23 patients are DF with a follow-up between 3 and 30 mo, and 8/23 patients had progression of E-GIST or metastasis, with not available data in 5 patients.

In conclusion, the diagnosis of E-GIST must be considered in a liver mass. Rendering an accurate diagnosis is a challenge, as well as the confirmation of their primary or metastatic nature. The optimal treatment is surgery and imatinib mesylate has a role as neoadjuvant treatment for locally advanced tumors, adjuvant treatment if the lesion has a high risk for recurrence, and palliative treatment if there is distant metastasis. Literature on hepatic E-GIST is scarce and further studies such as multicentric databases are needed to clarify diagnosis and treatment.

Table 3 Treatment and adjuvant treatment in selected patients with extra-gastrointestinal stromal tumor of the liver

Ref.	Yr	Age / Sex	Treatment	Adjuvant imatinib mesylate
Hu <i>et al</i> ^[20]	2018	79/F	Curative surgical resection	Yes
Joyon <i>et al</i> ^[21]	2018	56/M	OLT	No
	2018	59/F	Refused surgery: imatinib mesylate	No
Carrillo <i>et al</i> ^[22]	2017	41/M	Segmentectomy V-VI	Yes
Lok <i>et al</i> ^[23]	2017	50/F	Right hepatectomy	Yes
Cheng <i>et al</i> ^[24]	2016	63/M	Right hepatectomy	Yes
Nagai <i>et al</i> ^[25]	2016	70/F	Left lateral segmentectomy	No
Liu <i>et al</i> ^[26]	2016	NA	NA	NA
Wang <i>et al</i> ^[27]	2016	61/M	Caudate lobe resection	No
Liu <i>et al</i> ^[28]	2016	56/F	Microwave ablation	Yes
Su <i>et al</i> ^[29]	2015	65/M	Irresectable: imatinib mesylate	No
Bhoy <i>et al</i> ^[3]	2014	41/F	Right hepatectomy	Yes
Lin <i>et al</i> ^[30]	2015	67/F	Surgical excision	Yes
Mao <i>et al</i> ^[31]	2015	60/F	ECHRA	Yes
Kim <i>et al</i> ^[32]	2014	71/M	Left lateral segmentectomy+excision of 1 intrabdominal nodule+total gastrectomy	NA
Louis <i>et al</i> ^[33]	2014	55/F	Segmentectomy III and atypical resection (segments II, VI and VIII)	Yes
Zhou <i>et al</i> ^[34]	2014	56/M	Anterior and median segmentectomy	No
Li <i>et al</i> ^[35]	2012	53/M	Refused treatment	No
Yamamoto <i>et al</i> ^[36]	2010	70/M	Left hepatectomy	NA
Luo <i>et al</i> ^[37]	2009	17/M	RFA	NA
Ochiai <i>et al</i> ^[38]	2009	30/M	L-Trisegmentectomy	Yes
De Chiara <i>et al</i> ^[1]	2006	37/M	NA	No
Hu <i>et al</i> ^[6]	2003	79/F	Right lobectomy	NA

M: Male; F: Female; OLT Ortotopic liver transplantation; ECHRA Extracorporeal hepatic resection and autotransplantation; NA: Not available; RFA: Radiofrequency ablation.

Table 4 Pathological, immunohistochemical and molecular findings, and risk of malignancy according to Fletcher *et al*^[2]

Ref.	Yr	Age / Sex	Cell type	Molecular analysis	Mitotic count (n° / 50 HPF)	IH	Risk of malignancy
Hu <i>et al</i> ^[20]	2018	79/F	Spindle cells	NA	NA	CD117+, CD34+	NA
Joyon <i>et al</i> ^[21]	2018	56/M	Spindle cells	NA	8	CD117+, CD 34+	High risk
	2018	59/F	Mixed (spindle and epithelioid)	6 bp deletion in KIT exon 11	42	CD117+	High risk
Carrillo <i>et al</i> ^[22]	2017	41/M	Spindle cells	9 deletion in KIT	5	CD 117+, CD 34-	High risk
Lok <i>et al</i> ^[23]	2017	50/F	Spindle cells	NA	70	CD117+, CD 34+	High risk
Cheng <i>et al</i> ^[24]	2016	63/M	Spindle cells	NA	>5	CD 117 +, CD 34-	High risk
Nagai <i>et al</i> ^[25]	2016	70/F	Spindle cells	NA	40	CD117+, CD 34+	High risk
Liu <i>et al</i> ^[26]	2016	NA	NA	NA	NA	NA	NA
Wang <i>et al</i> ^[27]	2016	61/M	Spindle cells	NA	NA	CD117+/CD34+	High risk
Liu <i>et al</i> ^[28]	2016	56/F	Spindle cells	NA	2	CD117+	Low risk
Su <i>et al</i> ^[29]	2015	65/M	Spindle cells	NA	5	CD117+, CD 34-	High risk
Bhoy <i>et al</i> ^[3]	2014	41/F	NA	NA	NA	CD 117+	High risk
Lin <i>et al</i> ^[30]	2015	67/F	Mixed (spindle and epithelioid)	Mutation in exon 11	8	CD117+, CD 34+	High risk
Mao <i>et al</i> ^[31]	2015	60/F	Spindle cells	Mutation in exon 11	>10	CD 117+, CD 34 -	High risk
Kim <i>et al</i> ^[32]	2014	71/M	Spindle cells	NA	30-32	CD117+	High risk
Louis <i>et al</i> ^[33]	2014	55/F	Spindle cells	NA	10	CD117+	High risk
Zhou <i>et al</i> ^[34]	2014	56/M	Spindle cells	NA	<5	CD117+/CD34+	Intermediate
Li <i>et al</i> ^[35]	2012	53/M	Spindle cells	NA	NA	CD117+, CD34+	High risk

Yamamoto <i>et al</i> ^[36]	2010	70/M	Epithelioid cells	mutation PDGFRA exon 12	1	CD 117-/CD34+	High risk
Luo <i>et al</i> ^[37]	2009	17/M	Spindle cells	NA	0	CD117+, CD 34+	Low risk
Ochiai <i>et al</i> ^[38]	2009	30/M	Mixed (spindle and epithelioid)	No mutation at exon 11	75	CD117+, CD 34+	High risk
De Chiara <i>et al</i> ^[1]	2006	37/M	Spindle cells	NA	20	CD117+, CD 34+	High risk
Hu <i>et al</i> ^[6]	2003	79/F	Spindle cells	NA	20	CD117+, CD 34+	Low risk

M: male; F: female; NA: not available; PDGFRA: Platelet derived Growth Factor Receptor Alpha; HPF: High Power Fields.

Table 5 Outcome and follow-up in selected patients with EGIST of the liver

Ref.	Yr	Outcome	Follow-up (mo)
Hu <i>et al</i> ^[20]	2018	NA	NA
Joyon <i>et al</i> ^[21]	2018	Local recurrence (12 yr)	252
	2018	DF	18
Carrillo <i>et al</i> ^[22]	2017	DF	18
Lok <i>et al</i> ^[23]	2017	Brain metastasis (6 mo)	6
Cheng <i>et al</i> ^[24]	2016	DF	30
Nagai <i>et al</i> ^[25]	2016	DF	10
Liu <i>et al</i> ^[26]	2016	NA	NA
Wang <i>et al</i> ^[27]	2016	DF	12
Liu <i>et al</i> ^[28]	2016	Abdominal metastasis	17
Su <i>et al</i> ^[29]	2015	Progression of disease (died 6 mo)	6
Bhoy <i>et al</i> ^[3]	2014	DF	5
Lin <i>et al</i> ^[30]	2015	Hepatic recurrence (24 mo)	72
Mao <i>et al</i> ^[31]	2015	DF	12
Kim <i>et al</i> ^[32]	2014	NA	NA
Louis <i>et al</i> ^[33]	2014	DF	6
Zhou <i>et al</i> ^[34]	2014	DF	12
Li <i>et al</i> ^[35]	2012	NA	NA
Yamamoto <i>et al</i> ^[36]	2010	NA	NA
Luo <i>et al</i> ^[37]	2009	DF	3
Ochiai <i>et al</i> ^[38]	2009	Hepatic recurrence, submucosal gastric tumor (24 mo)	25
De Chiara <i>et al</i> ^[1]	2006	Lung metastasis (14 mo)	39
Hu <i>et al</i> ^[6]	2003	Portal lymph node metastasis (16 mo)	16

NA: Not available; DF: Disease free.

ARTICLE HIGHLIGHTS

Research background

A minor subset of primary gastrointestinal stromal tumors (GIST) can also arise outside the gastrointestinal tract, which is known as an extra-GIST (E-GIST).

Research motivation

Primary GIST of the liver is an exceptional location and this study aimed to characterize epidemiological, clinical and pathological features and options of treatments.

Research objectives

Our aim is to characterize epidemiological, clinical and pathological features and options of treatments.

Research methods

We perform a system review including all patients with hepatic GISTs.

Research results

This review shows that right hepatic lobe was the most frequent location, the median size was higher, there was a Southeast Asian predominance, and nearly 50% of patients have no

symptoms. The most frequent treatment was surgery and more than 70% of patients had a lesion with high risk of malignancy.

Research conclusions

Literature on hepatic EGIST is scarce and further studies such as multicentric databases are needed to clarify diagnosis and treatment.

REFERENCES

- 1 **De Chiara A**, De Rosa V, Lastoria S, Franco R, Botti G, Iaffaioli VR, Apice G. Primary gastrointestinal stromal tumor of the liver with lung metastases successfully treated with STI-571 (imatinib mesylate). *Front Biosci* 2006; **11**: 498-501 [PMID: [16146747](#) DOI: [10.2741/1813](#)]
- 2 **Fletcher CD**, Berman JJ, Corless C, Gorstein F, Lasota J, Longley BJ, Miettinen M, O'Leary TJ, Remotti H, Rubin BP, Shmookler B, Sobin LH, Weiss SW. Diagnosis of gastrointestinal stromal tumors: A consensus approach. *Hum Pathol* 2002; **33**: 459-465 [PMID: [12094370](#) DOI: [10.1053/hupa.2002.123545](#)]
- 3 **Bhoy T**, Lalwani S, Mistry J, Varma V, Kumaran V, Nundy S, Mehta N. Primary hepatic gastrointestinal stromal tumor. *Trop Gastroenterol* 2014; **35**: 252-253 [PMID: [26349171](#) DOI: [10.7869/tg.225](#)]
- 4 **Sheppard K**, Kinross KM, Solomon B, Pearson RB, Phillips WA. Targeting PI3 kinase/AKT/mTOR signaling in cancer. *Crit Rev Oncog* 2012; **17**: 69-95 [PMID: [22471665](#) DOI: [10.1615/CritRevOncog.v17.i1.60](#)]
- 5 **Feng F**, Tian Y, Liu Z, Xu G, Liu S, Guo M, Lian X, Fan D, Zhang H. Clinicopathologic Features and Clinical Outcomes of Esophageal Gastrointestinal Stromal Tumor: Evaluation of a Pooled Case Series. *Medicine (Baltimore)* 2016; **95**: e2446 [PMID: [26765432](#) DOI: [10.1097/MD.0000000000002446](#)]
- 6 **Hu X**, Forster J, Damjanov I. Primary malignant gastrointestinal stromal tumor of the liver. *Arch Pathol Lab Med* 2003; **127**: 1606-1608 [PMID: [14632569](#)]
- 7 **Kindblom LG**, Remotti HE, Aldenborg F, Meis-Kindblom JM. Gastrointestinal pacemaker cell tumor (GIPACT): gastrointestinal stromal tumors show phenotypic characteristics of the interstitial cells of Cajal. *Am J Pathol* 1998; **152**: 1259-1269 [PMID: [9588894](#)]
- 8 **Vanel D**, Albiter M, Shapeero L, Le Cesne A, Bonvalot S, Le Pechoux C, Terrier P, Petrow P, Caillet H, Dromain C. Role of computed tomography in the follow-up of hepatic and peritoneal metastases of GIST under imatinib mesylate treatment: a prospective study of 54 patients. *Eur J Radiol* 2005; **54**: 118-123 [PMID: [15797301](#) DOI: [10.1016/j.ejrad.2005.01.012](#)]
- 9 **Zhao X**, Yue C. Gastrointestinal stromal tumor. *J Gastrointest Oncol* 2012; **3**: 189-208 [PMID: [22943011](#) DOI: [10.3978/j.issn.2078-6891.2012.031](#)]
- 10 **Miettinen M**, Majidi M, Lasota J. Pathology and diagnostic criteria of gastrointestinal stromal tumors (GISTs): a review. *Eur J Cancer* 2002; **38** Suppl 5: S39-S51 [PMID: [12528772](#) DOI: [10.1016/S0959-8049\(02\)80602-5](#)]
- 11 **Miettinen M**, Lasota J. Gastrointestinal stromal tumors: pathology and prognosis at different sites. *Semin Diagn Pathol* 2006; **23**: 70-83 [PMID: [17193820](#) DOI: [10.1053/j.semdp.2006.09.001](#)]
- 12 **Reith JD**, Goldblum JR, Lyles RH, Weiss SW. Extragastric (soft tissue) stromal tumors: an analysis of 48 cases with emphasis on histologic predictors of outcome. *Mod Pathol* 2000; **13**: 577-585 [PMID: [10824931](#) DOI: [10.1038/modpathol.3880099](#)]
- 13 **Min KW**, Leabu M. Interstitial cells of Cajal (ICC) and gastrointestinal stromal tumor (GIST): facts, speculations, and myths. *J Cell Mol Med* 2006; **10**: 995-1013 [PMID: [17125601](#) DOI: [10.1111/j.1582-4934.2006.tb00541.x](#)]
- 14 **Huizinga JD**, Faussone-Pellegrini MS. About the presence of interstitial cells of Cajal outside the musculature of the gastrointestinal tract. *J Cell Mol Med* 2005; **9**: 468-473 [PMID: [15963266](#) DOI: [10.1111/j.1582-4934.2005.tb00372.x](#)]
- 15 **Yi JH**, Sim J, Park BB, Lee YY, Jung WS, Jang HJ, Ha TK, Paik SS. The primary extra-gastrointestinal stromal tumor of pleura: a case report and a literature review. *Jpn J Clin Oncol* 2013; **43**: 1269-1272 [PMID: [24168806](#) DOI: [10.1093/jcco/hyt158](#)]
- 16 **Miettinen M**, Lasota J. Gastrointestinal stromal tumors--definition, clinical, histological, immunohistochemical, and molecular genetic features and differential diagnosis. *Virchows Arch* 2001; **438**: 1-12 [PMID: [11213830](#) DOI: [10.1007/s004280000338](#)]
- 17 **Miettinen M**, Sarlomo-Rikala M, Lasota J. Gastrointestinal stromal tumors: recent advances in understanding of their biology. *Hum Pathol* 1999; **30**: 1213-1220 [PMID: [10534170](#) DOI: [10.1016/S0046-8177\(99\)90040-0](#)]
- 18 **Manterola C**, Vial M, Pineda V, Sanhueza A. Systematic review of literature with different types of designs. *Int J Morphol* 2009; **27**: 1179-1186 [DOI: [10.4067/S0717-95022009000400035](#)]
- 19 **Cook DJ**, Guyatt GH, Laupacis A, Sackett DL. Rules of evidence and clinical recommendations on the use of antithrombotic agents. *Chest* 1992; **102**: 305S-311S [PMID: [1395818](#) DOI: [10.1378/chest.102.4_Supplement.305S](#)]
- 20 **Hu HJ**, Fu YY, Li FY. Primary Gastrointestinal Stromal Tumor of the Liver. *Clin Gastroenterol Hepatol* 2018 [PMID: [30077788](#) DOI: [10.1016/j.cgh.2018.07.035](#)]
- 21 **Joyon N**, Dumortier J, Aline-Fardin A, Caramella C, Valette PJ, Blay JY, Scoazec JY, Dartigues P. Gastrointestinal stromal tumors (GIST) presenting in the liver: Diagnostic, prognostic and therapeutic issues. *Clin Res Hepatol Gastroenterol* 2018; **42**: e23-e28 [PMID: [28645742](#) DOI: [10.1016/j.clinre.2017.05.010](#)]
- 22 **Carrillo Colmenero AM**, Serradilla Martín M, Redondo Olmedilla MD, Ramos Pleguezuelos FM, López Leiva P. Giant primary extra gastrointestinal stromal tumor of the liver. *Cir Esp* 2017; **95**: 547-550 [PMID: [28153448](#) DOI: [10.1016/j.ciresp.2016.12.005](#)]
- 23 **Lok HT**, Chong CN, Chan AW, Fong KW, Cheung YS, Wong J, Lee KF, Lai PB. Primary hepatic gastrointestinal stromal tumor presented with rupture. *Hepatobiliary Surg Nutr* 2017; **6**: 65-66 [PMID: [28261601](#) DOI: [10.21037/hbsn.2017.01.11](#)]
- 24 **Cheng X**, Chen D, Chen W, Sheng Q. Primary gastrointestinal stromal tumor of the liver: A case report and review of the literature. *Oncol Lett* 2016; **12**: 2772-2776 [PMID: [27698856](#) DOI: [10.3892/ol.2016.4981](#)]
- 25 **Nagai T**, Ueda K, Hakoda H, Okata S, Nakata S, Taira T, Aoki S, Mishima H, Sako A, Maruyama T,

- Okumura M. Primary gastrointestinal stromal tumor of the liver: a case report and review of the literature. *Surg Case Rep* 2016; **2**: 87 [PMID: 27586264 DOI: 10.1186/s40792-016-0218-6]
- 26 **Liu Z**, Tian Y, Liu S, Xu G, Guo M, Lian X, Fan D, Zhang H, Feng F. Clinicopathological feature and prognosis of primary hepatic gastrointestinal stromal tumor. *Cancer Med* 2016; **5**: 2268-2275 [PMID: 27484851 DOI: 10.1002/cam4.808]
- 27 **Wang Y**, Liu Y, Zhong Y, Ji B. Malignant extra-gastrointestinal stromal tumor of the liver: A case report. *Oncol Lett* 2016; **11**: 3929-3932 [PMID: 27313719 DOI: 10.3892/ol.2016.4531]
- 28 **Liu L**, Zhu Y, Wang D, Yang C, Zhang QI, Li X, Bai Y. Coexisting and possible primary extra-gastrointestinal stromal tumors of the pancreas and liver: A single case report. *Oncol Lett* 2016; **11**: 3303-3307 [PMID: 27123107 DOI: 10.3892/ol.2016.4420]
- 29 **Su YY**, Chiang NJ, Wu CC, Chen LT. Primary gastrointestinal stromal tumor of the liver in an anorectal melanoma survivor: A case report. *Oncol Lett* 2015; **10**: 2366-2370 [PMID: 26622853 DOI: 10.3892/ol.2015.3561]
- 30 **Lin XK**, Zhang Q, Yang WL, Shou CH, Liu XS, Sun JY, Yu JR. Primary gastrointestinal stromal tumor of the liver treated with sequential therapy. *World J Gastroenterol* 2015; **21**: 2573-2576 [PMID: 25741171 DOI: 10.3748/wjg.v21.i8.2573]
- 31 **Mao L**, Chen J, Liu Z, Liu CJ, Tang M, Qiu YD. Extracorporeal hepatic resection and autotransplantation for primary gastrointestinal stromal tumor of the liver. *Transplant Proc* 2015; **47**: 174-178 [PMID: 25645799 DOI: 10.1016/j.transproceed.2014.09.111]
- 32 **Kim HO**, Kim JE, Bae KS, Choi BH, Jeong CY, Lee JS. Imaging findings of primary malignant gastrointestinal stromal tumor of the liver. *Jpn J Radiol* 2014; **32**: 365-370 [PMID: 24682930 DOI: 10.1007/s11604-014-0307-z]
- 33 **Louis AR**, Singh S, Gupta SK, Sharma A. Primary GIST of the liver masquerading as primary intra-abdominal tumour: a rare extra-gastrointestinal stromal tumour (EGIST) of the liver. *J Gastrointest Cancer* 2014; **45**: 392-394 [PMID: 23749608 DOI: 10.1007/s12029-013-9514-6]
- 34 **Zhou B**, Zhang M, Yan S, Zheng S. Primary gastrointestinal stromal tumor of the liver: report of a case. *Surg Today* 2014; **44**: 1142-1146 [PMID: 23681598 DOI: 10.1007/s00595-013-0521-9]
- 35 **Li ZY**, Liang QL, Chen GQ, Zhou Y, Liu QL. Extra-gastrointestinal stromal tumor of the liver diagnosed by ultrasound-guided fine needle aspiration cytology: a case report and review of the literature. *Arch Med Sci* 2012; **8**: 392-397 [PMID: 22662017 DOI: 10.5114/aoms.2012.28572]
- 36 **Yamamoto H**, Miyamoto Y, Nishihara Y, Kojima A, Imamura M, Kishikawa K, Takase Y, Ario K, Oda Y, Tsuneyoshi M. Primary gastrointestinal stromal tumor of the liver with PDGFRA gene mutation. *Hum Pathol* 2010; **41**: 605-609 [PMID: 20096441 DOI: 10.1016/j.humpath.2009.09.016]
- 37 **Luo XL**, Liu D, Yang JJ, Zheng MW, Zhang J, Zhou XD. Primary gastrointestinal stromal tumor of the liver: a case report. *World J Gastroenterol* 2009; **15**: 3704-3707 [PMID: 19653356 DOI: 10.3748/wjg.15.3704]
- 38 **Ochiai T**, Sonoyama T, Kikuchi S, Ikoma H, Kubota T, Nakanishi M, Ichikawa D, Kikuchi S, Fujiwara H, Okamoto K, Sakakura C, Kokuba Y, Taniguchi H, Otsuji E. Primary large gastrointestinal stromal tumor of the liver: report of a case. *Surg Today* 2009; **39**: 633-636 [PMID: 19562456 DOI: 10.1007/s00595-008-3885-5]
- 39 **Agaimy A**, Wünsch PH. Gastrointestinal stromal tumours: a regular origin in the muscularis propria, but an extremely diverse gross presentation. A review of 200 cases to critically re-evaluate the concept of so-called extra-gastrointestinal stromal tumours. *Langenbecks Arch Surg* 2006; **391**: 322-329 [PMID: 16402273 DOI: 10.1007/s00423-005-0005-5]
- 40 **Miettinen M**, Lasota J. Gastrointestinal stromal tumors. *Gastroenterol Clin North Am* 2013; **42**: 399-415 [PMID: 23639648 DOI: 10.1016/j.gtc.2013.01.001]
- 41 **Sarlomo-Rikala M**, Kovatich AJ, Barusevicius A, Miettinen M. CD117: a sensitive marker for gastrointestinal stromal tumors that is more specific than CD34. *Mod Pathol* 1998; **11**: 728-734 [PMID: 9720500]
- 42 **Joensuu H**, Vehtari A, Riihimäki J, Nishida T, Steigen SE, Brabec P, Plank L, Nilsson B, Cirilli C, Braconi C, Bordoni A, Magnusson MK, Linke Z, Sufliarsky J, Federico M, Jonasson JG, Dei Tos AP, Rutkowski P. Risk of recurrence of gastrointestinal stromal tumour after surgery: an analysis of pooled population-based cohorts. *Lancet Oncol* 2012; **13**: 265-274 [PMID: 22153892 DOI: 10.1016/S1470-2045(11)70299-6]
- 43 **von Mehren M**, Randall RL, Benjamin RS, Boles S, Bui MM, Casper ES, Conrad EU, DeLaney TF, Ganjoo KN, George S, Gonzalez RJ, Heslin MJ, Kane JM, Mayerson J, McGarry SV, Meyer C, O'Donnell RJ, Pappo AS, Paz IB, Pfeifer JD, Riedel RF, Schuetze S, Schupak KD, Schwartz HS, Van Tine BA, Wayne JD, Bergman MA, Sundar H. Gastrointestinal stromal tumors, version 2.2014. *J Natl Compr Canc Netw* 2014; **12**: 853-862 [PMID: 24925196]
- 44 **Rediti M**, Pellegrini E, Molinara E, Cerullo C, Fonte C, Lunghi A, Iori A, Neri B. Complete pathological response in advanced extra-gastrointestinal stromal tumor after imatinib mesylate therapy: a case report. *Anticancer Res* 2014; **34**: 905-907 [PMID: 24511030]
- 45 **Wada Y**, Ogata H, Misawa S, Shimada A, Kinugasa E. A hemodialysis patient with primary extra-gastrointestinal stromal tumor: favorable outcome with imatinib mesylate. *Intern Med* 2012; **51**: 1561-1565 [PMID: 22728491 DOI: 10.2169/internalmedicine.51.6709]
- 46 **Joensuu H**. Risk stratification of patients diagnosed with gastrointestinal stromal tumor. *Hum Pathol* 2008; **39**: 1411-1419 [PMID: 18774375 DOI: 10.1016/j.humpath.2008.06.025]



Published By Baishideng Publishing Group Inc
7041 Koll Center Parkway, Suite 160, Pleasanton, CA 94566, USA
Telephone: +1-925-2238242
Fax: +1-925-2238243
E-mail: bpgoffice@wjgnet.com
Help Desk: <https://www.f6publishing.com/helpdesk>
<https://www.wjgnet.com>

