

Artificial Intelligence in *Gastroenterology*

Artif Intell Gastroenterol 2020 September 28; 1(3): 51-59





Artificial Intelligence in Gastroenterology

Contents

Bimonthly Volume 1 Number 3 September 28, 2020

MINIREVIEWS

- 51 Artificial intelligence for the study of colorectal cancer tissue slides

Formica V, Morelli C, Riondino S, Renzi N, Nitti D, Roselli M

ABOUT COVER

Editorial board member of *Artificial Intelligence in Gastroenterology*, Dr. Elshaarawy is a Clinical Lecturer and Consultant of gastroenterology and hepatology at the National Liver Institute of Menoufia University (Egypt) and Salem Medical Center and Center of Alcohol Research at the University of Heidelberg (Germany). He holds a PhD in internal medicine, an MD, and an MSc in hepatology and gastroenterology. Currently, he serves as a member of the Young Endoscopists Committee in the European Society of Gastrointestinal Endoscopy, Chair of the Young Gastrointestinal section of the Egyptian Association for Research and Training in Hepatogastroenterology and the Young Representative of the Society at the United European Gastroenterology, and Chief Editor of the Translational Medicine section and Associate Editor of Molecular Medicine in the "Maqal Elmy" project. (L-Editor: Filipodia)

AIMS AND SCOPE

The primary aim of *Artificial Intelligence in Gastroenterology* (AIG, *Artif Intell Gastroenterol*) is to provide scholars and readers from various fields of artificial intelligence in gastroenterology with a platform to publish high-quality basic and clinical research articles and communicate their research findings online.

AIG mainly publishes articles reporting research results obtained in the field of artificial intelligence in gastroenterology and covering a wide range of topics, including artificial intelligence in gastrointestinal cancer, liver cancer, pancreatic cancer, hepatitis B, hepatitis C, nonalcoholic fatty liver disease, inflammatory bowel disease, irritable bowel syndrome, and *Helicobacter pylori* infection.

INDEXING/ABSTRACTING

There is currently no indexing.

RESPONSIBLE EDITORS FOR THIS ISSUE

Production Editor: *Yu-Jie Ma*; Production Department Director: *Xiang Li*; Editorial Office Director: *Jin-Lai Wang*.

NAME OF JOURNAL

Artificial Intelligence in Gastroenterology

ISSN

ISSN 2644-3236 (online)

LAUNCH DATE

June 28, 2020

FREQUENCY

Bimonthly

EDITORS-IN-CHIEF

Rajvinder Singh, Ferruccio Bonino

EDITORIAL BOARD MEMBERS

<https://www.wjgnet.com/2644-3236/editorialboard.htm>

PUBLICATION DATE

September 28, 2020

COPYRIGHT

© 2020 Baishideng Publishing Group Inc

INSTRUCTIONS TO AUTHORS

<https://www.wjgnet.com/bpg/gerinfo/204>

GUIDELINES FOR ETHICS DOCUMENTS

<https://www.wjgnet.com/bpg/GerInfo/287>

GUIDELINES FOR NON-NATIVE SPEAKERS OF ENGLISH

<https://www.wjgnet.com/bpg/gerinfo/240>

PUBLICATION ETHICS

<https://www.wjgnet.com/bpg/GerInfo/288>

PUBLICATION MISCONDUCT

<https://www.wjgnet.com/bpg/gerinfo/208>

ARTICLE PROCESSING CHARGE

<https://www.wjgnet.com/bpg/gerinfo/242>

STEPS FOR SUBMITTING MANUSCRIPTS

<https://www.wjgnet.com/bpg/GerInfo/239>

ONLINE SUBMISSION

<https://www.f6publishing.com>



Artificial intelligence for the study of colorectal cancer tissue slides

Vincenzo Formica, Cristina Morelli, Silvia Riondino, Nicola Renzi, Daniele Nitti, Mario Roselli

ORCID number: Vincenzo Formica 0000-0002-5380-3144; Cristina Morelli 0000-0003-1797-7259; Silvia Riondino 0000-0002-2965-402X; Nicola Renzi 0000-0002-9385-2178; Daniele Nitti 0000-0003-0348-8112; Mario Roselli 0000-0002-2431-6689.

Author contributions: Formica V, Morelli C, Riondino S and Roselli M designed the research study; Nitti D and Renzi N performed the research for retrieval of relevant articles; Formica V, Morelli C and Riondino S analyzed the articles and wrote the manuscript; All authors have read and approve the final manuscript.

Conflict-of-interest statement: None to declare.

Open-Access: This article is an open-access article that was selected by an in-house editor and fully peer-reviewed by external reviewers. It is distributed in accordance with the Creative Commons Attribution NonCommercial (CC BY-NC 4.0) license, which permits others to distribute, remix, adapt, build upon this work non-commercially, and license their derivative works on different terms, provided the original work is properly cited and the use is non-commercial. See: <http://creativecommons.org/licenses/by-nc/4.0/>

Manuscript source: Invited manuscript

Vincenzo Formica, Cristina Morelli, Silvia Riondino, Nicola Renzi, Daniele Nitti, Mario Roselli, Department of Systems Medicine, Medical Oncology Unit, Tor Vergata University Hospital, Rome 00133, Italy

Corresponding author: Vincenzo Formica, MD, PhD, Chief Doctor, Department of Systems Medicine, Medical Oncology Unit, Tor Vergata University Hospital, Viale Oxford 81, Rome 00133, Italy. vincenzo.formica@uniroma2.it

Abstract

Artificial intelligence (AI) is gaining incredible momentum as a companion diagnostic in a number of fields in oncology. In the present mini-review, we summarize the main uses and findings of AI applied to the analysis of digital histopathological images of slides from colorectal cancer (CRC) patients. Machine learning tools have been developed to automatically and objectively recognize specific CRC subtypes, such as those with microsatellite instability and high lymphocyte infiltration that would optimally respond to specific therapies. Also, AI-based classification in distinct prognostic groups with no studies of the basic biological features of the tumor have been attempted in a methodological approach that we called "biology-agnostic".

Key Words: Artificial intelligence; Colorectal cancer; Digital pathology; Deep learning; Machine learning; Tumor-infiltrating lymphocytes

©The Author(s) 2020. Published by Baishideng Publishing Group Inc. All rights reserved.

Core Tip: Artificial intelligence (AI) is gaining incredible momentum as a companion diagnostic in a number of fields in oncology. In the present mini-review, we summarize the main uses and findings of AI applied to the analysis of digital histopathological images of slides from colorectal cancer patients.

Citation: Formica V, Morelli C, Riondino S, Renzi N, Nitti D, Roselli M. Artificial intelligence for the study of colorectal cancer tissue slides. *Artif Intell Gastroenterol* 2020; 1(3): 51-59

URL: <https://www.wjgnet.com/2644-3236/full/v1/i3/51.htm>

DOI: <https://dx.doi.org/10.35712/aig.v1.i3.51>

Received: June 29, 2020**Peer-review started:** June 29, 2020**First decision:** July 28, 2020**Revised:** September 25, 2020**Accepted:** September 27, 2020**Article in press:** September 27, 2020**Published online:** September 28, 2020**P-Reviewer:** Cheng X,
Lalmuanawma S**S-Editor:** Wang JL**L-Editor:** Filipodia**P-Editor:** Ma YJ

INTRODUCTION

Artificial intelligence (AI) refers to any form of machine activity that attempts to mimic human intelligence. The main abilities of the human intelligence objective of AI research are performing complex tasks and achieving goals through processes that are typical of the human cognitive functions, such as “learning” [which in this case is termed “machine learning” (ML)] and “problem solving”^[1-4].

“Deep” learning (DL) is a basic method of ML. It is based on specific computer algorithms that recall neural networking and that try to model data-rich input for the identification of general and meaningful features/patterns or for the prediction of specific outcomes^[5]. The term “deep” refers to the organization in layers of the artificial neural network, with deep layers of analysis being crucial to infer more complex and higher-level characteristics up to the final layer of the label/output that is pursued (Figure 1 and Figure 2).

ML has been successfully applied in the so-called digital pathology^[6-8], where histological images are deeply analyzed in every single pixel for color and light intensity by computer algorithms, to deduce a final diagnosis or prognostic/predictive feature.

The use of AI in cancer histopathology has been possible since the advent of histologic images digitalization^[6]. Widely available image scanners are currently used in clinical practice, also for the acquisition of initial hematoxylin and eosin (HE) stained slides. Mukhopadhyay *et al*^[9] performed a comparison between digital pathology and classical microscopy in a large multi-center cohort of patients and confirmed the exceptional utility of the digital support. Early studies were based on the analysis and segmentation of specific slide regions, such as the tumor center, margins, stroma or others, mainly in order to recognize specific objects and structures^[10]. More recently, with the ability of the computational analysis of higher digital dimension, automated analysis of whole HE-stained tumor tissue slides has been possible and inference of patient outcome and prognosis has been attempted^[11,12]. In the present mini-review, we summarize the latest findings for the application of AI tools for the digital pathology of colorectal cancer (CRC). In general, two research fields have been identified: AI instruments for identification of specific biologic features and AI instruments for prediction of patient outcome independently of the cancer biology.

ML FOR DETECTION OF SPECIFIC BIOLOGIC FEATURES

One typical approach of AI in pathology is to use pre-defined key image features as building block for AI-algorithm development. These are usually termed “hand-crafted” features and are engineered based on biological insights. Typical examples of “hand-crafted” features are shape and orientation of the cell nuclei^[13], that can be used to recognize cancer cells or tumor infiltrating lymphocytes or other cell types.

Assessment of shape and organization of cancer cells

Shape and orientation of cancer cells are among the most commonly assessed variables to predict patient outcome^[14]. A predictive, ML-based algorithm for lymph node metastasis (LNM) on whole slide images in early CRC with pathological submucosal invasion (pT1) has proven useful when using data from cancer cell morphology^[16]. After delineating cancer cell regions by using immunohistochemistry for cytokeratins, Takamatsu *et al*^[15] analyzed tissue slides from over 300 CRC patients diagnosed as pT1, looking for predictors of LNM. They used the popular ImageJ software, released by the United States’ National Institutes of Health, and JPEG images. Digital parameters extracted from the slides essentially referred to shape, circularity, orientation and organization of cancer cells (*e.g.*, Feret’s diameter), and these were used to feed a supervised ML algorithm based on random forest classifier. AI prediction was proved to be superior to human conventional assessment, with a discriminatory power of area under the curve (commonly known as AUC) 94% *vs* 83%, respectively.

Sailem *et al*^[16] proposed a data-rich integrated platform that utilized a ML approach to conjugate high-throughput gene perturbation analysis with morphological features of CRC and, in particular, single cell morphology and cell population organization. After identification of TGF β and WNT signaling genes and olfactory receptors genes as key altered genes in CRC, they validated their association with single cell and cell population morphology and grade of differentiation in CRC. Those specific gene alterations were associated to abnormal organization of HCT116 CRC cell cultures and

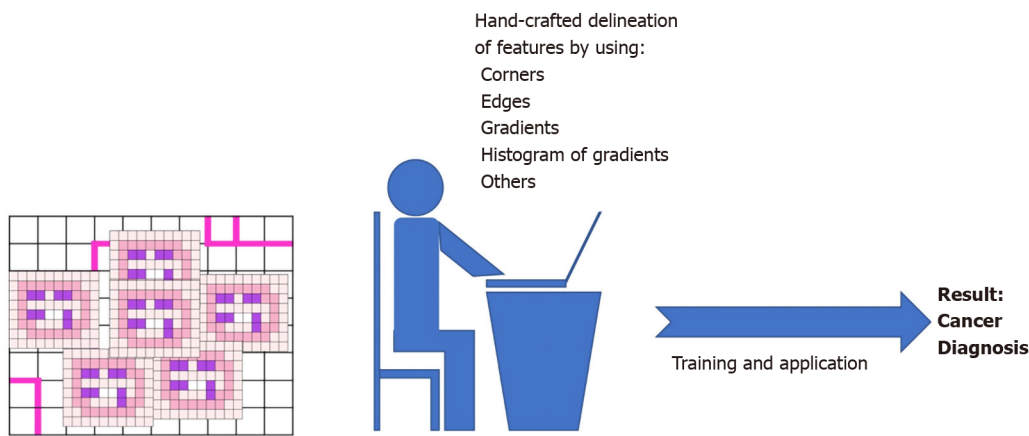


Figure 1 Exemplified representation of hand-crafted feature-based machine learning.

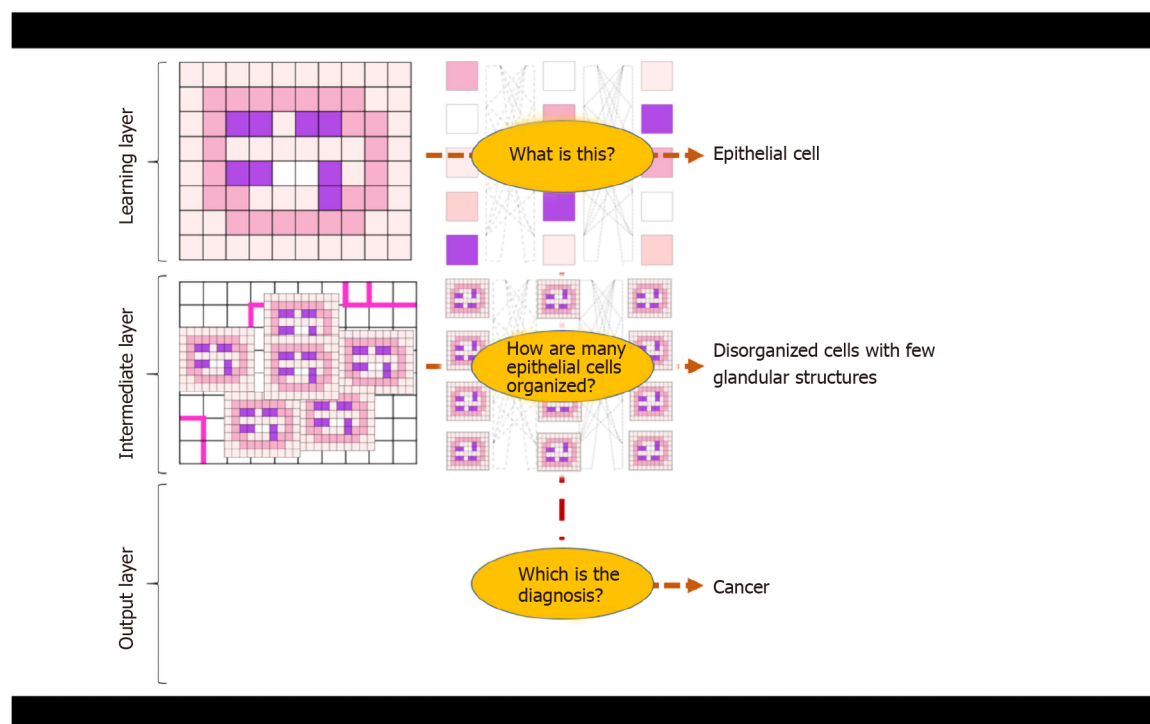


Figure 2 Exemplified explanation of deep learning for tumor tissue slide analysis.

also to specific CRC molecular subtypes (the well-known consensus molecular subtypes – CSM^[17]) in over 550 patients from The Cancer Genome Atlas (referred to as TCGA) database.

Assessment of tumor infiltrating lymphocytes

In recent years, the development of immunotherapy has revolutionized the care of cancer^[18], and great attention has been placed upon assessment of the immune response surrounding the tumor tissue^[19]. Most reports are focused on specific immune cells and chiefly on tumor-induced cytotoxic T cells. Indeed, a high T-cell infiltration appears to be associated with a decreased risk of tumor dissemination and improved survival in most solid tumors. Väyrynen *et al*^[20] have recently proposed an AI-based assessment of CRC slides, simultaneously evaluating different cell populations involved in immune response against the tumor. Scanned HE-stained images of CRC cases from two United States' prospective cohorts [the Nurses' Health Study (referred to as NHS), and the Health Professionals Follow-up Study (referred to as HPFS)] were analyzed with an open source software (QuPath v0.1.2), enabling the

recognition of cancer epithelial cells and four immune cell types with distinct morphological features: lymphocytes, plasma cells, eosinophils, and neutrophils. Moreover, QuPath v0.1.2 was able to distinguish between two tissue regions: the intraepithelial region and stromal region^[21]. Densities of immune cells in the intraepithelial and stromal regions, together with a function (G-cross function) measuring the proximity of immune cells to cancer cells (expressed as AUC within a distance of 20 μm) were calculated. Findings from NHS and HPFS cohorts were validated in a set of 570 CRC from TCGA with available digitalized pathological images in the data portal. Automated quantification of immune cells was compared to manual count by pathologists.

A high correlation between measurement of immune cell densities performed by automated AI classifiers and manual counts performed by experienced pathologist was found (Spearman's rho 0.71-0.96). Moreover AI-determined stromal density of lymphocytes and eosinophils were independently correlated with survival in a multivariable Cox regression analysis, with higher densities associated with longer cancer-specific survival (P for trend across quartiles of density < 0.001 for both cell types). The multivariate analysis included very important molecular factors which were available for the post-hoc analysis of NHS and HPFS populations and partly associated with immune response, such as microsatellite instability (MSI), CpG island methylator phenotype, *KRAS*, *BRAF*, and *PIK3CA* mutations, and LINE-1 methylation level. High G cross function for Tumor: Lymphocyte and Tumor: Eosinophil proximity was also associated with longer cancer-specific survival (P_{trend} 0.002 and < 0.001, respectively). High stromal eosinophil density was associated with better cancer-specific survival also in the TCGA cohort (P_{trend} < 0.001).

AI can also improve CRC cancer staging and, consequently, patient prognosis. Reichling and co-workers^[22], using a LASSO algorithm, DGMate (DiGital tuMor pArameTErs), combined the analysis of tumor stroma and tumor cell intrinsic variables, in association with immune cell infiltrate of tumor samples from stage III CRC patients of the PETACC8 study cohort, and were able to detect digital parameters within the tumor cells related to patients' outcomes^[23]. Similarly, clinically relevant information were gained in the study of Yoo *et al.*^[24], in which ML-based analysis was applied to study the quantitative parameters of immune infiltrate within the tumor immune microenvironment. By quantifying intraepithelial tumor-infiltrating lymphocytes, stromal tumor-infiltrating lymphocytes, and the tumor-stroma ratio from CD3 and CD8 immunohistochemical stained whole-slide images, the authors classified five CRC subgroups with distinctive biological features and different prognostic behaviors. Indeed, the CD3+ and CD8+ T-cell infiltration is considered an important independent prognostic factor predicting CRC patient survival^[25]. An automated image analysis-based workflow quantifying the tumor-infiltrating immune cells and tumor budding, at the invasive front, combined with a ML approach, demonstrated that the spatial association of lymphocytes and tumor buddings could provide a high prognostic significance in stage II CRC patients^[26].

AI for identification of peculiar molecular subgroups

MSI-high (MSI-H) tumors are a peculiar molecular subgroup of CRC characterized by deficient expression of mismatch repair proteins (dMMR phenotype)^[27]. MSI-H is associated with the inherited Lynch syndrome and found to be a marker of increased tumor mutational burden, neoantigen generation and exceptional sensitivity to immune checkpoint inhibitors^[28]. It accounts for 4%-5% of metastatic CRC and its early recognition is now crucial to avoid useless treatment with conventional chemotherapy and to tailor adequate and effective immunotherapy. Kather *et al.*^[29] have recently built an AI-classifier of conventionally HE-stained slides of gastric and CRC for the detection of MSI-H. The model used Resnet18, a residual learning convolutional neural network (CNN), which was trained and validated, both internally and externally, in a very large cohort of gastrointestinal cancer. In particular, Resnet18 was initially trained to automatically identify tumor areas within the normal tissue background in common histological slides. In a second step, it was trained to define the degree of MSI using TCGA bank, and specifically 315 and 360 formalin-fixed paraffin embedded gastric and CRC specimens, respectively, and 378 snap-frozen CRC samples. TCGA of stomach cancer was 80% from non-Asian patients, and authors tested the possible influence of ethnicity on the model performance by validating the AI classifier in an external cohort of 185 Japanese patients.

The discriminatory power of the AI tool for the MSI-H status identification was impressively high (AUC around 80% in almost all experiments) across all the different sets: gastric *vs* CRC tissues, Asian *vs* non-Asian patients, and formalin-fixed paraffin embedded *vs* snap-frozen samples. Moreover, it was found that minimal required

number of histological “tiles” on which to train and interrogate the algorithm (the ML process starts by fragmenting the entire histologic digital image in multiple elementary color-normalized slide tiles) was as small as those encompassed in a common core needle biopsy (performance plateaued at approximately 100 “slide tiles” of 256 μm edge length). The logical next step in this field will be to test the predictive value of AI-based MSI-H diagnosis for immunotherapy efficacy.

In another study by the same research group, a DL model for MSI definition was trained and validated in a cohort of nearly 9000 patients from Germany, Netherlands, United Kingdom and United States by using standard HE-stained slides and immunohistochemistry for mismatch repair proteins or conventional genetic test of microsatellite regions as ground truth for MSI status. In the validation step, the DL tool demonstrated an impressively high ability to correctly classify MSI-H patients with a discriminatory power > 95% (AUROC 0.95-0.96)^[30].

AI for the quantification of stromal tissue

In CRC, the so-called desmoplastic reaction, *i.e.* a pronounced stromal tissue growth within the tumor mass, has been associated with reduced prognosis^[31]. Desmoplastic reaction is driven by differentiated cells responsible for the deposition of extracellular fibrotic material, the cancer-associated fibroblasts (CAFs). Kather *et al*^[32] have used DL for automatic quantification of stromal tissue proportion in CRC tissues and set up a “deep stroma score”. They first trained the DL instrument with over 100000 digital image patches of HE-stained tumors from 86 CRC patients where stromal and non-stromal areas were hand-delineated. The DL tool so obtained was then tested in an independent set of over 7000 images from 25 patients, where it demonstrated an accuracy of > 94%.

The tool, that was able to recognize tissue-specific features, was finally used to produce the “deep stroma score” which was calculated for a cohort of 500 colorectal patients from the TCGA repository and correlated with survival. The stroma score significantly and independently associated with overall survival with a hazard ratio of 1.99, $P = 0.003$. In the same patient group, manual stroma quantification by experienced pathologists or stromal assessment by means of gene expression profiles attributable to CAFs had an inferior performance in terms of survival prediction across the different tumor stages (from I to IV). The DL stroma score yielded similar prognostic efficacy in an independent validation cohort of over 400 patients from Germany: hazard ratio for overall survival 2.29, $P = 0.0004$.

BIOLOGY-AGNOSTIC ML

DL is a novel type of ML that uses a more “blind” approach to analyze the input data with no pre-definition of hand-crafted features to train the model. An extreme way to apply DL is the direct correlation of the digital input data to the final outcome, for example risk of disease relapse *vs* definitive care after surgical removal of the tumor, with no specific “biological insights” fed into the machine. Skrede *et al*^[33] have applied an advanced DL method to analyze whole-slide image, using CNN. CNN makes use of mathematical convolutions, *i.e.* resulting mathematical functions obtained by combining more primary functions reversed and shifted in time. In Skrede *et al*^[33]'s experiment, no clinical or biological information (such as grade of histological differentiation, neurovascular invasion, depth of tumor infiltration within the colon wall, or others) was fed into the model, and the final objective was to identify “biology-agnostic” digital image profiles (purely based on patterns of pixel color or intensity of the digital images) predictive of CRC specific survival in surgically-resected patients (stages II and III). Four large cohorts of approximately 1000 patients each were used (training, tuning, test and validation cohorts). The CNN-based automatic prognostic classifier, that authors called DoMore-v1-CRC, was initially trained for outcome prediction in a cohort of patients constituted of two subgroups with “pre-labeled” distinct outcomes: good (survival > 2 years) *vs* poor (relapse within 6 mo) outcome. DoMore-v1-CRC was then tuned, tested and validated in cohorts with non-prelabeled outcome to define its prognostic ability. The DoMore-v1-CRC had an output of three possible classes, good *vs* uncertain *vs* poor prognosis. The DoMore-v1-CRC-based classification had an independent prognostic value in a multivariable survival analysis that included and adjusted for well-known and broadly-used clinical and biological factors, such as pN stage, pT stage, lymphatic invasion, and venous vascular invasion (hazard ratio for DoMore-v1-CRC-defined poor *vs* good prognosis 3.04, $P < 0.0001$). Accuracy in predicting cancer-specific survival was around 70% in all

cohorts. The prognostic power remained high for both stage II and stage III tumors, and for groups of slides prepared in different laboratories, thus confirming its robustness against inter-laboratory variability in tissue preparation and staining. Moreover, the prognostic yield remained high when two different image scanners were compared (NanoZoomer XR *vs* Aperio AT2 scanner). Interestingly, even though derived from a biology-agnostic approach, DoMore-v1-CRC significantly correlated with clinical and biological markers, such as age, pN stage, pT stage, histological grade, tumor sidedness, BRAF mutation, and microsatellite instability.

CONCLUSION

Even if still at the early stages, AI in digital pathology is increasingly gaining momentum, for a number of reasons: (1) worldwide transferability; (2) high-dimension of analyzable data; and (3) automated procedural approaches. Far from being conceived as substitutive of human intelligence, it can be seen as a useful companion diagnostic in oncology and as pre-screening/pre-selection tool. Both biology-driven and biology-agnostic algorithms have been pursued in the implementation of AI in the CRC pathology field (Table 1).

The main challenges for AI-supported digital pathology are currently to demonstrate that can diffusely be applied and significantly help in the clinical decision-making especially as predictor of efficacy of specific therapeutic options. Such a demonstration can only come with an enhancement of the AI application itself to different cancer patient settings and different clinical scenarios and problem-solving tasks. Future directions rely on the prospective validation of AI-based tools in randomized phase III trials, which delineates the so-called “IA level” of evidence.

Table 1 Summary of main applications and findings of artificial intelligence in colorectal cancer digital pathology

| Target | Description | Ref. |
|--|---|---------------|
| Cancer cell shape and organization to predict N+ | Digital assessment of cancer cells using Feret's diameters allows to predict lymph node metastasis in pT1 colon cancer | [11] |
| Assessment of anti-cancer immune response | Simultaneous assessment of all immune cell subpopulations and demonstration that eosinophils, other than T cells, may play a role in CRC immune response | [12,14,15,17] |
| Identification of Microsatellite instable tumors | Rapid and large size screening of histopathologic features in conventional HE-stained slides increasing the probability of being a MSI-H tumor, without the need of specific immunohistochemical or molecular testing | [18] |
| Quantification of stroma within the tumor | Algorithms for tissue -specific recognition, even when sparse within the tumor mass have been development. These algorithms have allowed the validation of "deep stroma score" which is significantly associated with survival in CRC | [20] |
| Biology-agnostic prediction of survival | Development of tissue "digital" profiles without specific underlying biologic background or significance that are predictive of distinct survivals, bad vs good outcome | [21] |

CRC: Colorectal cancer; MSI-H: Microsatellite instability high.

REFERENCES

- Bi WL, Hosny A, Schabath MB, Giger ML, Birkbak NJ, Mehrta A, Allison T, Arnaout O, Abbosh C, Dunn IF, Mak RH, Tamimi RM, Tempany CM, Swanton C, Hoffmann U, Schwartz LH, Gillies RJ, Huang RY, Aerts HJWL. Artificial intelligence in cancer imaging: Clinical challenges and applications. *CA Cancer J Clin* 2019; **69**: 127-157 [PMID: 30720861 DOI: 10.3322/caac.21552]
- Dasgupta P. Science, technology and artificial intelligence. *BJU Int* 2018; **122**: 913 [PMID: 30460789 DOI: 10.1111/bju.14595]
- He J, Baxter SL, Xu J, Xu J, Zhou X, Zhang K. The practical implementation of artificial intelligence technologies in medicine. *Nat Med* 2019; **25**: 30-36 [PMID: 30617336 DOI: 10.1038/s41591-018-0307-0]
- Le Berre C, Sandborn WJ, Aridhi S, Devignes MD, Fournier L, Smail-Tabbone M, Danese S, Peyrin-Biroulet L. Application of Artificial Intelligence to Gastroenterology and Hepatology. *Gastroenterology* 2020; **158**: 76-94.e2 [PMID: 31593701 DOI: 10.1053/j.gastro.2019.08.058]
- Sherbet GV, Woo WL, Dlay S. Application of Artificial Intelligence-based Technology in Cancer Management: A Commentary on the Deployment of Artificial Neural Networks. *Anticancer Res* 2018; **38**: 6607-6613 [PMID: 30504368 DOI: 10.21873/anticancer.13027]
- Bera K, Schalper KA, Rimm DL, Velcheti V, Madabhushi A. Artificial intelligence in digital pathology - new tools for diagnosis and precision oncology. *Nat Rev Clin Oncol* 2019; **16**: 703-715 [PMID: 31399699 DOI: 10.1038/s41571-019-0252-y]
- Niazi MKK, Parwani AV, Gurcan MN. Digital pathology and artificial intelligence. *Lancet Oncol* 2019; **20**: e253-e261 [PMID: 31044723 DOI: 10.1016/S1470-2045(19)30154-8]
- Ruffle JK, Farmer AD, Aziz Q. Artificial Intelligence-Assisted Gastroenterology- Promises and Pitfalls. *Am J Gastroenterol* 2019; **114**: 422-428 [PMID: 30315284 DOI: 10.1038/s41395-018-0268-4]
- Mukhopadhyay S, Feldman MD, Abels E, Ashfaq R, Beltaifa S, Cacciabeve NG, Cathro HP, Cheng L, Cooper K, Dickey GE, Gill RM, Heaton RP Jr, Kerstens R, Lindberg GM, Malhotra RK, Mandell JW, Manluco ED, Mills AM, Mills SE, Moskaluk CA, Nelis M, Patil DT, Przybycin CG, Reynolds JP, Rubin BP, Saboorian MH, Salicru M, Samols MA, Sturgis CD, Turner KO, Wick MR, Yoon JY, Zhao P, Taylor CR. Whole Slide Imaging Versus Microscopy for Primary Diagnosis in Surgical Pathology: A Multicenter Blinded Randomized Noninferiority Study of 1992 Cases (Pivotal Study). *Am J Surg Pathol* 2018; **42**: 39-52 [PMID: 28961557 DOI: 10.1097/PAS.0000000000000948]
- Al-Kofahi Y, Lassoued W, Lee W, Roysam B. Improved automatic detection and segmentation of cell nuclei in histopathology images. *IEEE Trans Biomed Eng* 2010; **57**: 841-852 [PMID: 19884070 DOI: 10.1109/TBME.2009.2035102]
- Lu C, Romo-Bucheli D, Wang X, Janowczyk A, Ganesan S, Gilmore H, Rimm D, Madabhushi A. Nuclear shape and orientation features from H&E images predict survival in early-stage estrogen receptor-positive breast cancers. *Lab Invest* 2018; **98**: 1438-1448 [PMID: 29959421 DOI: 10.1038/s41374-018-0095-7]
- Corredor G, Wang X, Zhou Y, Lu C, Fu P, Syrigos K, Rimm DL, Yang M, Romero E, Schalper KA, Velcheti V, Madabhushi A. Spatial Architecture and Arrangement of Tumor-Infiltrating Lymphocytes for Predicting Likelihood of Recurrence in Early-Stage Non-Small Cell Lung Cancer. *Clin Cancer Res* 2019; **25**: 1526-1534 [PMID: 30201760 DOI: 10.1158/1078-0432.CCR-18-2013]
- Sirinukunwattana K, Ahmed Raza SE, Yee-Wah Tsang, Snead DR, Cree IA, Rajpoot NM. Locality Sensitive Deep Learning for Detection and Classification of Nuclei in Routine Colon Cancer Histology Images. *IEEE Trans Med Imaging* 2016; **35**: 1196-1206 [PMID: 26863654 DOI: 10.1109/TMI.2016.2525803]
- Gisselsson D, Björk J, Höglund M, Mertens F, Dal Cin P, Akerman M, Mandahl N. Abnormal nuclear shape in solid tumors reflects mitotic instability. *Am J Pathol* 2001; **158**: 199-206 [PMID: 11141493 DOI: 10.1016/S0002-9440(10)63958-2]
- Takamatsu M, Yamamoto N, Kawachi H, Chino A, Saito S, Ueno M, Ishikawa Y, Takazawa Y, Takeuchi K. Prediction of early colorectal cancer metastasis by machine learning using digital slide images. *Comput Methods Programs Biomed* 2019; **178**: 155-161 [PMID: 31416544 DOI: 10.1016/j.cmpb.2019.06.022]
- Sailem HZ, Rittscher J, Pelkmans L. KCML: a machine-learning framework for inference of multi-scale

- gene functions from genetic perturbation screens. *Mol Syst Biol* 2020; **16**: e9083 [PMID: [32141232](#) DOI: [10.15252/msb.20199083](#)]
- 17 **Guinney J**, Dienstmann R, Wang X, de Reyniès A, Schlicker A, Soneson C, Marisa L, Roepman P, Nyamundanda G, Angelino P, Bot BM, Morris JS, Simon IM, Gerster S, Fessler E, De Sousa E Melo F, Missiaglia E, Ramay H, Barras D, Homicsko K, Maru D, Manyam GC, Broom B, Boige V, Perez-Villamil B, Laderas T, Salazar R, Gray JW, Hanahan D, Tabernero J, Bernards R, Friend SH, Laurent-Puig P, Medema JP, Sadanandam A, Wessels L, Delorenzi M, Kopetz S, Vermeulen L, Tejpar S. The consensus molecular subtypes of colorectal cancer. *Nat Med* 2015; **21**: 1350-1356 [PMID: [26457759](#) DOI: [10.1038/nm.3967](#)]
 - 18 **Waldman AD**, Fritz JM, Lenardo MJ. A guide to cancer immunotherapy: from T cell basic science to clinical practice. *Nat Rev Immunol* 2020 [PMID: [32433532](#) DOI: [10.1038/s41577-020-0306-5](#)]
 - 19 **Byrne A**, Savas P, Sant S, Li R, Virassamy B, Luen SJ, Beavis PA, Mackay LK, Neeson PJ, Loi S. Tissue-resident memory T cells in breast cancer control and immunotherapy responses. *Nat Rev Clin Oncol* 2020; **17**: 341-348 [PMID: [32112054](#) DOI: [10.1038/s41571-020-0333-y](#)]
 - 20 **Väyrynen JP**, Lau MC, Haruki K, Väyrynen SA, Dias Costa A, Borowsky J, Zhao M, Fujiyoshi K, Arima K, Twombly TS, Kishikawa J, Gu S, Aminmzaffari S, Shi S, Baba Y, Akimoto N, Ugai T, Da Silva A, Song M, Wu K, Chan AT, Nishihara R, Fuchs CS, Meyerhardt JA, Giannakis M, Ogino S, Nowak JA. Prognostic Significance of Immune Cell Populations Identified by Machine Learning in Colorectal Cancer Using Routine Hematoxylin and Eosin-Stained Sections. *Clin Cancer Res* 2020; **26**: 4326-4338 [PMID: [32439699](#) DOI: [10.1158/1078-0432.CCR-20-0071](#)]
 - 21 **Bankhead P**, Loughrey MB, Fernández JA, Dombrowski Y, McArt DG, Dunne PD, McQuaid S, Gray RT, Murray LJ, Coleman HG, James JA, Salto-Tellez M, Hamilton PW. QuPath: Open source software for digital pathology image analysis. *Sci Rep* 2017; **7**: 16878 [PMID: [29203879](#) DOI: [10.1038/s41598-017-17204-5](#)]
 - 22 **Taieb J**, Tabernero J, Mini E, Subtil F, Folprecht G, Van Laethem JL, Thaler J, Bridgewater J, Petersen LN, Blons H, Collette L, Van Cutsem E, Rougier P, Salazar R, Bedenne L, Emile JF, Laurent-Puig P, Lepage C; PETACC-8 Study Investigators. Oxaliplatin, fluorouracil, and leucovorin with or without cetuximab in patients with resected stage III colon cancer (PETACC-8): an open-label, randomised phase 3 trial. *Lancet Oncol* 2014; **15**: 862-873 [PMID: [24928083](#) DOI: [10.1016/S1470-2045\(14\)70227-X](#)]
 - 23 **Reichling C**, Taieb J, Derangere V, Klopfenstein Q, Le Malicot K, Gornet JM, Becheur H, Fein F, Cojocarasu O, Kaminsky MC, Lagasse JP, Luet D, Nguyen S, Etienne PL, Gasmi M, Vanoli A, Perrier H, Puig PL, Emile JF, Lepage C, Ghiringhelli F. Artificial intelligence-guided tissue analysis combined with immune infiltrate assessment predicts stage III colon cancer outcomes in PETACC08 study. *Gut* 2020; **69**: 681-690 [PMID: [31780575](#) DOI: [10.1136/gutjnl-2019-319292](#)]
 - 24 **Yoo SY**, Park HE, Kim JH, Wen X, Jeong S, Cho NY, Gwon HG, Kim K, Lee HS, Jeong SY, Park KJ, Han SW, Kim TY, Bae JM, Kang GH. Whole-Slide Image Analysis Reveals Quantitative Landscape of Tumor-Immune Microenvironment in Colorectal Cancers. *Clin Cancer Res* 2020; **26**: 870-881 [PMID: [31757879](#) DOI: [10.1158/1078-0432.CCR-19-1159](#)]
 - 25 **Galon J**, Mlecnik B, Bindea G, Angell HK, Berger A, Lagorce C, Lugli A, Zlobec I, Hartmann A, Bifulco C, Nagtegaal ID, Palmqvist R, Masucci GV, Botti G, Tatangelo F, Delrio P, Maio M, Laghi L, Grizzi F, Asslaber M, D'Arrigo C, Vidal-Vanaclocha F, Zavadova E, Chouchane L, Ohashi PS, Hafezi-Bakhtiari S, Wouters BG, Roehrl M, Nguyen L, Kawakami Y, Hazama S, Okuno K, Ogino S, Gibbs P, Waring P, Sato N, Torigoe T, Itoh K, Patel PS, Shukla SN, Wang Y, Kopetz S, Sinicrope FA, Scripcariu V, Ascierto PA, Marincola FM, Fox BA, Pagès F. Towards the introduction of the 'Immunoscore' in the classification of malignant tumours. *J Pathol* 2014; **232**: 199-209 [PMID: [24122236](#) DOI: [10.1002/path.4287](#)]
 - 26 **Nearchou IP**, Lillard K, Gavriel CG, Ueno H, Harrison DJ, Caie PD. Automated Analysis of Lymphocytic Infiltration, Tumor Budding, and Their Spatial Relationship Improves Prognostic Accuracy in Colorectal Cancer. *Cancer Immunol Res* 2019; **7**: 609-620 [PMID: [30846441](#) DOI: [10.1158/2326-6066.CIR-18-0377](#)]
 - 27 **Innocenti F**, Ou FS, Qu X, Zemla TJ, Niedzwiecki D, Tam R, Mahajan S, Goldberg RM, Bertagnoli MM, Blanke CD, Sanoff H, Atkins J, Polite B, Venook AP, Lenz HJ, Kabbarah O. Mutational Analysis of Patients With Colorectal Cancer in CALGB/SWOG 80405 Identifies New Roles of Microsatellite Instability and Tumor Mutational Burden for Patient Outcome. *J Clin Oncol* 2019; **37**: 1217-1227 [PMID: [30865548](#) DOI: [10.1200/JCO.18.01798](#)]
 - 28 **Overman MJ**, Lonardi S, Wong KYM, Lenz HJ, Gelsomino F, Aglietta M, Morse MA, Van Cutsem E, McDermott R, Hill A, Sawyer MB, Hendlisz A, Neyns B, Svrcek M, Moss RA, Ledezne JM, Cao ZA, Kamble S, Kopetz S, André T. Durable Clinical Benefit With Nivolumab Plus Ipilimumab in DNA Mismatch Repair-Deficient/Microsatellite Instability-High Metastatic Colorectal Cancer. *J Clin Oncol* 2018; **36**: 773-779 [PMID: [29355075](#) DOI: [10.1200/JCO.2017.76.9901](#)]
 - 29 **Kather JN**, Pearson AT, Halama N, Jäger D, Krause J, Loosen SH, Marx A, Boor P, Tacke F, Neumann UP, Grabsch HI, Yoshikawa T, Brenner H, Chang-Claude J, Hoffmeister M, Trautwein C, Luedde T. Deep learning can predict microsatellite instability directly from histology in gastrointestinal cancer. *Nat Med* 2019; **25**: 1054-1056 [PMID: [31160815](#) DOI: [10.1038/s41591-019-0462-y](#)]
 - 30 **Echle A**, Grabsch HI, Quirke P, van den Brandt PA, West NP, Hutchins GGA, Heij LR, Tan X, Richman SD, Krause J, Alwers E, Jenniskens J, Offermans K, Gray R, Brenner H, Chang-Claude J, Trautwein C, Pearson AT, Boor P, Luedde T, Gaisa NT, Hoffmeister M, Kather JN. Clinical-Grade Detection of Microsatellite Instability in Colorectal Tumors by Deep Learning. *Gastroenterology* 2020 [PMID: [32562722](#) DOI: [10.1053/j.gastro.2020.06.021](#)]
 - 31 **Danielsen HE**, Hveem TS, Domingo E, Pradhan M, Kleppe A, Syvrtens RA, Kostolomov I, Nesheim JA, Askautrud HA, Nesbakken A, Lothe RA, Svindland A, Shepherd N, Novelli M, Johnstone E, Tomlinson I, Kerr R, Kerr DJ. Prognostic markers for colorectal cancer: estimating ploidy and stroma. *Ann Oncol* 2018; **29**: 616-623 [PMID: [29293881](#) DOI: [10.1093/annonc/mdx794](#)]
 - 32 **Kather JN**, Krisam J, Charoentong P, Luedde T, Herpel E, Weis CA, Gaiser T, Marx A, Valous NA, Ferber D, Jansen L, Reyes-Aldasoro CC, Zörnig I, Jäger D, Brenner H, Chang-Claude J, Hoffmeister M, Halama N. Predicting survival from colorectal cancer histology slides using deep learning: A retrospective multicenter study. *PLoS Med* 2019; **16**: e1002730 [PMID: [30677016](#) DOI: [10.1371/journal.pmed.1002730](#)]

- 33 **Skrede OJ**, De Raedt S, Kleppe A, Hveem TS, Liestøl K, Maddison J, Askautrud HA, Pradhan M, Nesheim JA, Albrechtsen F, Farstad IN, Domingo E, Church DN, Nesbakken A, Shepherd NA, Tomlinson I, Kerr R, Novelli M, Kerr DJ, Danielsen HE. Deep learning for prediction of colorectal cancer outcome: a discovery and validation study. *Lancet* 2020; **395**: 350-360 [PMID: [32007170](#) DOI: [10.1016/S0140-6736\(19\)32998-8](#)]



Published by **Baishideng Publishing Group Inc**
7041 Koll Center Parkway, Suite 160, Pleasanton, CA 94566, USA

Telephone: +1-925-3991568

E-mail: bpgoffice@wjgnet.com

Help Desk: <https://www.f6publishing.com/helpdesk>

<https://www.wjgnet.com>

