

Artificial Intelligence in *Gastrointestinal Endoscopy*

Artif Intell Gastrointest Endosc 2021 August 28; 2(4): 95-197





Artificial Intelligence in Gastrointestinal Endoscopy

Contents

Bimonthly Volume 2 Number 4 August 28, 2021

OPINION REVIEW

- 95 Artificial intelligence assisted assessment of endoscopic disease activity in inflammatory bowel disease
Lo B, Burisch J
- 103 Robotic pancreaticoduodenectomy: Where do we stand?
Khachfe HH, Habib JR, Chahrour MA, Nassour I

MINIREVIEWS

- 110 Robotic surgery in colon cancer: current evidence and future perspectives – narrative review
Tagliabue F, Burati M, Chiarelli M, Cioffi U, Zago M
- 117 Artificial intelligence in endoscopy: The challenges and future directions
Gao X, Braden B
- 127 Deep learning applied to the imaging diagnosis of hepatocellular carcinoma
Ballotin VR, Bigarella LG, Soldera J, Soldera J
- 136 Role of capsule endoscopy in inflammatory bowel disease: Anything new?
Pérez de Arce E, Quera R, Núñez F P, Araya R
- 149 Role of optical coherence tomography in Barrett's esophagus
Gupta N, Yelamanchi R, Agrawal H, Agarwal N
- 157 Artificial intelligence and colonoscopy – enhancements and improvements
Yoo BS, D'Souza SM, Houston K, Patel A, Lau J, Elmahdi A, Parekh PJ, Johnson D
- 168 Impact of endoscopic ultrasound elastography in pancreatic lesion evaluation
Lesmana CRA, Paramitha MS
- 179 Artificial intelligence as a means to improve recognition of gastrointestinal angiodysplasia in video capsule endoscopy
Cox II GA, Jackson CS, Vega KJ
- 185 Early gastrointestinal cancer: The application of artificial intelligence
Yang H, Hu B

Contents

Artificial Intelligence in Gastrointestinal Endoscopy

Bimonthly Volume 2 Number 4 August 28, 2021

ABOUT COVER

Associate Editor of *Artificial Intelligence in Gastrointestinal Endoscopy*, Peter Bauerfeind, MD, Professor, Department of Gastroenterology and Hepatology, University hospital Zurich, Zurich 8091, Switzerland.
peter.bauerfeind@usz.ch

AIMS AND SCOPE

The primary aim of *Artificial Intelligence in Gastrointestinal Endoscopy* (AIGE, *Artif Intell Gastrointest Endosc*) is to provide scholars and readers from various fields of artificial intelligence in gastrointestinal endoscopy with a platform to publish high-quality basic and clinical research articles and communicate their research findings online.

AIGE mainly publishes articles reporting research results obtained in the field of artificial intelligence in gastrointestinal endoscopy and covering a wide range of topics, including artificial intelligence in capsule endoscopy, colonoscopy, double-balloon enteroscopy, duodenoscopy, endoscopic retrograde cholangio-pancreatography, endosonography, esophagoscopy, gastrointestinal endoscopy, gastroscopy, laparoscopy, natural orifice endoscopic surgery, proctoscopy, and sigmoidoscopy.

INDEXING/ABSTRACTING

There is currently no indexing.

RESPONSIBLE EDITORS FOR THIS ISSUE

Production Editor: *Lin-YuTong Wang*; Production Department Director: *Xiang Li*; Editorial Office Director: *Jin-Li Wang*.

NAME OF JOURNAL

Artificial Intelligence in Gastrointestinal Endoscopy

ISSN

ISSN 2689-7164 (online)

LAUNCH DATE

July 28, 2020

FREQUENCY

Bimonthly

EDITORS-IN-CHIEF

Fatih Altintoprak, Sahin Coban, Krish Ragunath

EDITORIAL BOARD MEMBERS

<https://www.wjgnet.com/2689-7164/editorialboard.htm>

PUBLICATION DATE

August 28, 2021

COPYRIGHT

© 2021 Baishideng Publishing Group Inc

INSTRUCTIONS TO AUTHORS

<https://www.wjgnet.com/bpg/gerinfo/204>

GUIDELINES FOR ETHICS DOCUMENTS

<https://www.wjgnet.com/bpg/gerinfo/287>

GUIDELINES FOR NON-NATIVE SPEAKERS OF ENGLISH

<https://www.wjgnet.com/bpg/gerinfo/240>

PUBLICATION ETHICS

<https://www.wjgnet.com/bpg/gerinfo/288>

PUBLICATION MISCONDUCT

<https://www.wjgnet.com/bpg/gerinfo/208>

ARTICLE PROCESSING CHARGE

<https://www.wjgnet.com/bpg/gerinfo/242>

STEPS FOR SUBMITTING MANUSCRIPTS

<https://www.wjgnet.com/bpg/gerinfo/239>

ONLINE SUBMISSION

<https://www.f6publishing.com>

© 2021 Baishideng Publishing Group Inc. All rights reserved. 7041 Koll Center Parkway, Suite 160, Pleasanton, CA 94566, USA

E-mail: bpgoffice@wjgnet.com <https://www.wjgnet.com>



Role of optical coherence tomography in Barrett's esophagus

Nikhil Gupta, Raghav Yelamanchi, Himanshu Agrawal, Nitin Agarwal

ORCID number: Nikhil Gupta 0000-0001-7265-8168; Raghav Yelamanchi 0000-0001-6786-8056; Himanshu Agrawal 0000-0001-7994-2356; Nitin Agarwal 0000-0002-4820-9896.

Author contributions: Gupta N performed the literature review and critically reviewed the manuscript; Yelamanchi R performed the literature review and drafted the manuscript; Agrawal H and Agarwal N reviewed the manuscript; all authors read and approved the final manuscript.

Conflict-of-interest statement: None of the authors has any conflict of interest or financial ties to disclose.

Open-Access: This article is an open-access article that was selected by an in-house editor and fully peer-reviewed by external reviewers. It is distributed in accordance with the Creative Commons Attribution NonCommercial (CC BY-NC 4.0) license, which permits others to distribute, remix, adapt, build upon this work non-commercially, and license their derivative works on different terms, provided the original work is properly cited and the use is non-commercial. See: <http://creativecommons.org/licenses/by-nc/4.0/>

Manuscript source: Invited manuscript

Nikhil Gupta, Raghav Yelamanchi, Himanshu Agrawal, Department of Surgery, Atal Bihari Vajpayee Institute of Medical Sciences and Dr. Ram Manohar Lohia Hospital, Delhi 110001, India

Nitin Agarwal, Department of Surgical Disciplines, Postgraduate Institute of Medical Education and Research and Dr. Ram Manohar Lohia Hospital, Delhi 110001, India

Corresponding author: Nikhil Gupta, FACS, FRCS (Gen Surg), Professor, Surgeon, Department of Surgery, Atal Bihari Vajpayee Institute of Medical Sciences and Dr. Ram Manohar Lohia Hospital, BKS Marg, Delhi 110001, India. nikhil_ms26@yahoo.co.in

Abstract

Traditional endoscopic techniques for Barrett's esophagus (BE) surveillance relied on factor of probability as endoscopists performed cumbersome random biopsies of low yield. Optical coherence tomography (OCT) is a novel technique based on tissue light interference and is set to break conventional barriers. OCT was initially introduced in ophthalmology but was soon adopted by other areas of medicine. When applied to endoscopy, OCT can render images of the superficial layers of the gastrointestinal tract and is highly sensitive in detecting dysplasia in BE. Volumetric laser endomicroscopy is a second generation OCT endoscope device which is able to identify buried glands after ablation. Addition of artificial intelligence to OCT has rendered it more productive. The newer additions to OCT such as angiogram and laser marking will increase the accuracy of investigation. In spite of the few inevitable drawbacks associated with the technology, it presently outperforms all newer endoscopic techniques for the surveillance of BE.

Key Words: Optical coherence tomography; Volume laser endomicroscopy; Esophageal adenocarcinoma; Endoscopy; Gastroesophageal reflux disease

©The Author(s) 2021. Published by Baishideng Publishing Group Inc. All rights reserved.

Core Tip: Surveillance of Barrett's esophagus for dysplasia is a long-debated and intensively researched topic. Optical coherence tomography (OCT) is a breakthrough technology in the medical field that enables the visualization of the layers of a structure in an office setting. The application of artificial intelligence (AI) to OCT endoscopy is the latest addition to the armamentarium of endoscopists. AI-based diagnostic algorithm scores are proven to be better than clinical scores. The accuracy of AI-based

Specialty type: Gastroenterology and hepatology

Country/Territory of origin: India

Peer-review report's scientific quality classification

Grade A (Excellent): 0

Grade B (Very good): 0

Grade C (Good): C

Grade D (Fair): 0

Grade E (Poor): 0

Received: May 9, 2021

Peer-review started: May 9, 2021

First decision: May 19, 2021

Revised: May 20, 2021

Accepted: July 19, 2021

Article in press: July 19, 2021

Published online: August 28, 2021

P-Reviewer: Morozov S

S-Editor: Fan JR

L-Editor: A

P-Editor: Zhang YL



system is enhanced further by using color coding software and convolutional neural networks. Multi-center randomized control trials validating these technologies is the need of the hour.

Citation: Gupta N, Yelamanchi R, Agrawal H, Agarwal N. Role of optical coherence tomography in Barrett's esophagus. *Artif Intell Gastrointest Endosc* 2021; 2(4): 149-156

URL: <https://www.wjgnet.com/2689-7164/full/v2/i4/149.htm>

DOI: <https://dx.doi.org/10.37126/aige.v2.i4.149>

INTRODUCTION

Barrett's esophagus (BE) is defined as columnar metaplasia (or intestinal metaplasia, as some authorities prefer to call it) of the stratified squamous epithelium, lining the lower end of the esophagus[1]. It occurs due to chronic exposure of the distal esophagus to acidic contents as a part of gastroesophageal reflux disease. The prevalence of BE is around 1.6% in general population[2]. It varies in different regions of the world with increased prevalence in the western population. Apart from the gastroesophageal reflux disease, other risk factors for BE include advancing age, male gender, obesity, tobacco consumption, and Caucasian race[3].

Once the diagnosis of BE is made based on endoscopy, the endoscopist evaluates its extent as *per* the Prague C and M classification. All cases of BE should be biopsied at multiple levels as *per* the Seattle biopsy protocol to identify the presence of dysplasia or adenocarcinoma, which is the main concern. Traditional endoscopic techniques relied on the chance factor as endoscopists performed random cumbersome biopsies of low yield. The early diagnosis of esophageal neoplasia is important because it helps to initiate curative therapies for cancer. This has directed the path of research to identify newer techniques and technologies to increase the accuracy of biopsies during endoscopy[4]. Optical coherence tomography (OCT) is one of such techniques which is set to break conventional barriers.

Humans are prone to do errors due to fatigue, increased workload and working environment. The use of artificial intelligence (AI) has grown rapidly in the past few decades from using technology to perform simple household tasks to piloting aircraft. AI is also adopted into the medical field in the form of surgical robots in the last decade. The application of AI to endoscopy is widely researched as newer technologies of endoscopy are being developed. The purpose of this narrative review is to enlighten the readers about the principles of OCT and its application to BE and the use of AI in the OCT endoscopy.

OCT

OCT is an imaging modality based on light interference. It is used to produce cross-sectional images of a structure based on the differential properties of various layers with respect to light refraction[5]. The basic setup of OCT consists of a light source which is a low-coherence semiconductor super-luminescent diode. The light is split into two beams by an optical splitter: A reference beam and a sample beam. The reference beam is reflected back by a mirror, while the sample beam is focused onto the tissue to be imaged. Based on the refractory properties of the layers of the tissue, the sample beam is variably reflected back. The reflected light from the reference and sample beams are coupled in a coupler, producing interference patterns which are analyzed, after which a cross-sectional image is created (Figure 1). The axial resolution of OCT will depend on the spectral band of the light source with large spectral bands having better resolution[5]. The transverse resolution is independent of axial resolution and will depend on the numerical aperture of the lens through which the light beam passes[5].

The conventional OCT technology is based on the time-domain (TD-OCT) concept in which variations in the time of the travelled beams of light are analyzed to form an image with the help of moving mirrors. The technology has now evolved into the Fourier-domain (FD-OCT) which uses static mirrors so an image is formed based on the modulations in the source spectrum. The FD-OCT has higher image acquisition

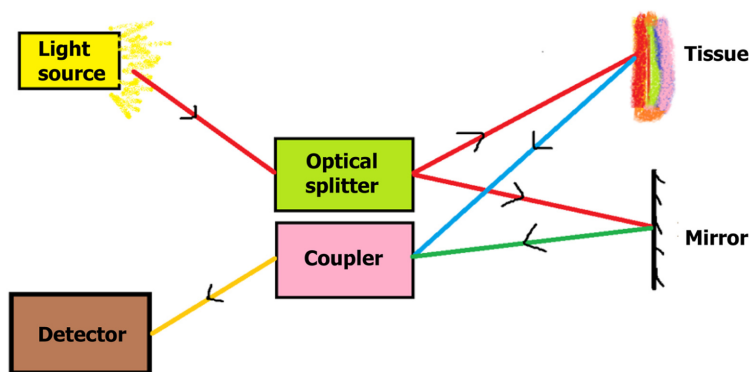


Figure 1 Basic schematic representation of the principle of optical coherence tomography.

speeds than TD-OCT. The resolution of FD-OCT is 1-3 μm , which is far better than the 10 μm resolution of TD-OCT. The FD-OCT is based on either charge-coupled device-based image acquisition (spectral-domain OCT) or photodetector-based image detection with longer wavelengths of the light source (swept-source OCT)[6]. The swept-source OCT has better resolution and twice the image acquisition speed compared to spectral-domain OCT[6].

OCT was initially introduced in ophthalmology as a method to visualize the layers of the retina but it was soon adopted into other areas of medicine. Nevertheless, the utility of OCT is still only the “tip of the iceberg” with its vast potential yet to be unleashed. When applied to endoscopy, OCT is able to render images of the superficial layers of the gastrointestinal tract. OCT can be combined with either a forward-viewing endoscope or a side-viewing endoscope, with the forward-viewing endoscope enabling the sampling of the desired tissue[7]. There are two main types of OCT endoscopes: The proximal scanning rotating endoscope, which is less expensive but has lower capture speed, and the distal scanning endoscope, which comes with a micromotor, acquires images at a much higher speed but comes at a cost higher than the proximal scanning endoscope[7].

Volumetric laser endomicroscopy (VLE) is a second generation OCT endoscope device presently used for imaging[8] (Figure 2). It uses balloon centered imaging probes for imaging with a high axial resolution of 7 μm and a depth of 3 mm, which is 10 times greater compared to the standard endoscopic ultrasound[9]. It images the esophagus in six-centimeter intervals and is quite fast in image acquisition compared to the conventional OCT. It images about 1200 cross-sectional areas in the six cm span which are reconstructed. The application of VLE in BE is mainly to diagnose suspicious areas of mucosal abnormalities and in the post-treatment surveillance of BE and early neoplastic lesions.

PREDICTIVE FEATURES OF DYSPLASIA IN BE USING OCT/VLE AND THE USE OF AI

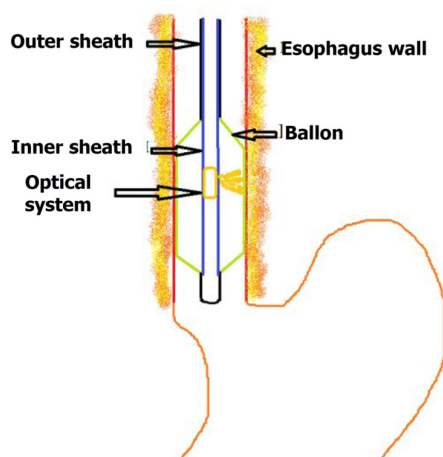
The absence of layering, surface maturation, and gland maturation are the three independent predictive factors for dysplasia in OCT imaging. The surface maturation is assessed in terms of the surface OCT signal, which if equal or stronger than the sub-surface signal, is predictive of dysplasia. Gland maturation is assessed in terms of the number of abnormal glands identified in imaging with more than five glands predictive of dysplasia.

AI is based on computer algorithms which provide result based on the received input. The algorithms are created based on previous OCT images which are correlated with histological diagnosis. The AI system has been automated to evolve with time, based on its previous results just as a human brain which is known as machine learning. Machine learning may be supervised, semi-supervised or unsupervised. Hence, AI is said to as good as a human brain and sometimes even better. Swager *et al* [10] created an AI-based VLE prediction score using multivariable logistic regression analysis of 60 VLE images[10]. The components of the score were: the lack of layering of superficial layers, higher surface intensity than sub-surface intensity, and the number of abnormal glands (Table 1). A cut-off score of ≥ 8 was predicative of dysplasia with a sensitivity and specificity of 83% and 71% respectively[10]. This VLE

Table 1 Volumetric laser endomicroscopy prediction score and diagnostic algorithm[9]

VLE prediction score		
Parameter		Score
Layering	Layering present-more than 50%	0
	Layering present-less than 50%	8
Surface signal	Surface signal < subsurface signal	0
	Surface signal = subsurface signal	6
	Surface signal > subsurface signal	8
Abnormal glands	0-5	0
	> 5	5
VLE-diagnostic algorithm		
Mucosal layer partial effacement	Abnormal glands > 5	Dysplasia
	Abnormal glands ≤ 5	Non-dysplasia
Mucosal layer complete effacement	Surface intensity > subsurface intensity	Dysplasia
	Surface intensity ≤ subsurface intensity	Non-dysplasia

VLE: Volumetric laser endomicroscopy.

**Figure 2** Parts of the volumetric laser endomicroscopy device.

prediction score based on computer-based VLE diagnostic algorithm (VLE-DA) was more sensitive (86%) and specific (88%) than the clinical VLE prediction score[10-12]. The components of VLE-DA are listed in Table 1.

Outcomes of first generation OCT

The traditional OCT criteria were found to be 97% sensitive and 93% specific when applied to BE surveillance prospectively in a study by Poneros *et al*[13] in 2001. The accuracy of OCT in diagnosing dysplasia in BE was about 78% in a double-blinded study by Isenberg *et al*[14] in 2005. The utility of OCT in diagnosing dysplasia was also confirmed in a study by Evans *et al*[15] using the dysplasia index which was 83% sensitive and 75% specific[15]. Chen *et al*[16] used ultra-high-resolution OCT for diagnosing dysplasia and adenocarcinoma with an accuracy of 83.3% and 100% respectively[16]. The utility of ultra-high-resolution OCT was also confirmed in the study by Cobb *et al*[17].

OUTCOMES OF SECOND-GENERATION OCT

The imaging capability of three-dimensional OCT is faster than conventional OCT. Its utility was proved in the study by Adler *et al*[18]. VLE has been found to be more sensitive and specific than random blind biopsies as *per* Seattle protocol. The role of VLE was initially proved in a study by Vakoc *et al*[19], while in a study by Trindade *et al*[20] five out of six patients were upstaged due to the diagnosis of dysplasia which was missed by conventional endoscopy and narrow band imaging[19,20]. The sensitivity and specificity of VLE in diagnosing dysplasia was 86% and 88% in a study by Leggett *et al*[11]. In a study by Jain *et al*[21], VLE was compared with histology; the sensitivity in diagnosing BE-related dysplasia was 50% and specificity was 47.1%[21]. The false negative rate was 2.9%. Even though the specificity was low in the study, it is far better than the random biopsies. In a systematic review by Kohli *et al*[22], the sensitivity and specificity of OCT in diagnosing dysplasia and early malignancy was in the ranges of 68%-83% and 75%-82% respectively[22].

POST-ABLATION BE SURVEILLANCE USING OCT

A variety of ablation therapies such as radiofrequency ablation, cryoablation, laser ablation, photodynamic therapy, *etc.* are used for the treatment of high-grade BE dysplasia and insitu carcinoma. One of the main disadvantages of these procedures is the occurrence of buried glands or subsquamous glandular structures[23,24]. These glands, present beneath the epithelium, may undergo dysplastic changes and turn malignant, but are not visualized on routine endoscopy as the surface epithelium appears normal. OCT is one of the few techniques able to diagnose buried glands[25]. The sensitivity and specificity in identifying buried glands in post-treatment BE using VLE was shown to be 92.3% and 23.8% in a study by Jain *et al*[21]. However, in the study by Swager *et al*[26], most of the subsquamous glandular structures identified on OCT were histologically normal[26]. The role of OCT in post-ablative surveillance was also proved in a study by Benjamin *et al*[27].

Doppler-OCT is useful in detecting the changes in the sub-mucosal micro-vascular network, which further improves the accuracy of OCT. Doppler-OCT is also used to detect the change in the vascular pattern during post-photodynamic therapy for BE. Doppler-OCT helps to monitor the dose of photodynamic therapy[28,29].

NEWER ADDITIONS TO OCT

As neoplasia is associated with neovascularization, this is one of the features used to distinguish benign epithelium from malignancy. OCT angiography is used to image the subsurface vasculature without the need for any contrast and is useful in diagnosing neoplasia[30]. The changes in the OCT signal caused by the movement of erythrocytes are quantified by calculating the decorrelation. However, this makes the OCT signal susceptible to artifacts due to respiratory and cardiac movements.

As a balloon is used to augment the scanning speed in VLE, simultaneous sampling of mucosa is not possible. The biopsy taken from the mucosa may not be the original mucosa intended on imaging. This disadvantage is overcome by using laser marking along with VLE. The laser fiber is used for creating point coagulation spots which act as markers for biopsy after the scan[31,32]. Simultaneous laser coagulation along with OCT is also possible[32].

The addition of deep learning to AI-based OCT systems further improved the accuracy of prediction of BE related dysplasia. Deep learning is one kind of machine learning where multiple diagnostic algorithms are layered to form a convolutional neural network just as a human brain. The output from one layer is fed to the next layer which further processes it and feeds it to the next layer to produce a refined output[33]. Deep learning also increases the speed of processing the images.

Trindade *et al*[34] used an AI-based new software termed intelligent real-time image segmentation for BE surveillance. The software provided color codes based on the degree of dysplasia using the previously mentioned VLE prediction features[34]. A multi-center randomized control trial with trial number NCT03814824 is going on, validating the above software, the results of which are awaited.

OCT IN COMPARISON TO OTHER ADVANCED ENDOSCOPIC IMAGING

VLE has been proved to be better than confocal laser endomicroscopy (CLE), which is one of the emerging endoscopic imaging techniques for BE and associated dysplasia. The sensitivity and specificity of VLE using VLE-DA were higher than CLE in a study by Leggett *et al*[11]. CLE is also disadvantageous as it requires injection of contrast into the blood and a limited field of view and imaging depth[35]. Endoscopic ultrasound is an excellent imaging modality for assessing the depth of tumor involvement. However, its accuracy is lower in differentiating early invasive carcinoma (T1 and T2). In a study by Kahn *et al*[36], VLE showed good results in differentiating T1a lesions from T1b lesions[36].

DRAWBACKS OF OCT

All technologies have one or more drawbacks and OCT is no exception. The main drawback of OCT is the absence of real-time imaging, as it is the case with other imaging modalities. Even the fastest OCT technology and probes require seconds to process the reflected waves. VLE requires balloon apposition and although perfect apposition is theoretically possible, it is rare in reality. The mucous layer on the surface epithelium, the contractions of the esophagus, and the presence of blood interfere with the close approximation resulting in artifacts. Simultaneous biopsy is not possible during imaging in VLE probes, which may pose a difficulty in biopsying the originally identified area. Movement artifacts are common in Doppler-OCT and OCT angiography. Unlike endoscopic ultrasound, OCT cannot be used to image the deeper tissues. Finally, cost is one of the main limiting factors for the widespread usage in all institutes.

The application of AI to OCT requires inputs from a large number of experts with expertise in this new technology who are fewer at present. The accuracy of the AI systems is based on the data fed which requires advanced imaging techniques and higher quality images. As AI and machine learning require input from humans it may be the victim of human errors during data input. Much of the knowledge of AI in OCT is based on pilot studies and case series. The number of randomized control trials and multi-center trials are very less due to concerns raised by ethical committees.

CONCLUSION

Surveillance of BE for dysplasia is a long-debated and intensively researched topic. OCT is a breakthrough technology in the medical field that enables the visualization of the layers of a structure in an office setting. The application of OCT to endoscopy is the latest addition to the armamentarium of endoscopists. Even though earlier OCT instruments were slow to image tissues, the newer AI-based technologies are fast enough to add only a few minutes to the conventional endoscopy time and are highly accurate compared to clinical diagnosis. OCT is highly sensitive in detecting dysplasia in BE. Even though the specificity in diagnosing dysplasia is lower, it is far more efficient than the conventional blind biopsy protocol. An especially important feature is the ability of VLE to identify buried glands after ablation. The newer additions to OCT, such as angiogram and laser marking, will help to increase the accuracy of the investigation. The AI software systems and deep learning systems are evolving over time. However, the utility of AI to BE surveillance is still at its bud stage. In spite of the few unavoidable drawbacks associated with the technology, AI-based OCT system is presently the most promising of all newer endoscopic techniques for the surveillance of BE.

REFERENCES

- 1 Naini BV, Souza RF, Odze RD. Barrett's Esophagus: A Comprehensive and Contemporary Review for Pathologists. *Am J Surg Pathol* 2016; **40**: e45-e66 [PMID: 26813745 DOI: 10.1097/PAS.0000000000000598]
- 2 Dam AN, Klapman J. A narrative review of Barrett's esophagus in 2020, molecular and clinical update. *Ann Transl Med* 2020; **8**: 1107 [PMID: 33145326 DOI: 10.21037/atm-20-4406]
- 3 Qumseya BJ, Bukannan A, Gendy S, Ahemd Y, Sultan S, Bain P, Gross SA, Iyer P, Wani S.

- Systematic review and meta-analysis of prevalence and risk factors for Barrett's esophagus. *Gastrointest Endosc* 2019; **90**: 707-717.e1 [PMID: [31152737](#) DOI: [10.1016/j.gie.2019.05.030](#)]
- 4 **Sharma P**. New endoscopic techniques for detecting dysplasia in barrett esophagus. *Gastroenterol Hepatol (NY)* 2008; **4**: 460-461 [PMID: [21960917](#)]
 - 5 **Popescu DP**, Choo-Smith LP, Flueraru C, Mao Y, Chang S, Disano J, Sherif S, Sowa MG. Optical coherence tomography: fundamental principles, instrumental designs and biomedical applications. *Biophys Rev* 2011; **3**: 155 [PMID: [28510064](#) DOI: [10.1007/s12551-011-0054-7](#)]
 - 6 **Gabriele ML**, Wollstein G, Ishikawa H, Kagemann L, Xu J, Folio LS, Schuman JS. Optical coherence tomography: history, current status, and laboratory work. *Invest Ophthalmol Vis Sci* 2011; **52**: 2425-2436 [PMID: [21493951](#) DOI: [10.1167/iops.10-6312](#)]
 - 7 **Gora MJ**, Suter MJ, Tearney GJ, Li X. Endoscopic optical coherence tomography: technologies and clinical applications [Invited]. *Biomed Opt Express* 2017; **8**: 2405-2444 [PMID: [28663882](#) DOI: [10.1364/BOE.8.002405](#)]
 - 8 **Wolfsen HC**. Volumetric Laser Endomicroscopy in Patients With Barrett Esophagus. *Gastroenterol Hepatol (NY)* 2016; **12**: 719-722 [PMID: [28035200](#)]
 - 9 **Rodriguez MAC**, de Moura DTH, Ribeiro IB, Bernardo WM, Morita FHA, Marques SB, Sakai P, de Moura EGH. Volumetric laser endomicroscopy and optical coherence tomography in Barrett's esophagus: a systematic review and meta-analysis. *Endosc Int Open* 2019; **7**: E1078-E1091 [PMID: [31475224](#) DOI: [10.1055/a-0965-6487](#)]
 - 10 **Swager AF**, Tearney GJ, Leggett CL, van Oijen MGH, Meijer SL, Weusten BL, Curvers WL, Bergman JJGHM. Identification of volumetric laser endomicroscopy features predictive for early neoplasia in Barrett's esophagus using high-quality histological correlation. *Gastrointest Endosc* 2017; **85**: 918-926.e7 [PMID: [27658906](#) DOI: [10.1016/j.gie.2016.09.012](#)]
 - 11 **Leggett CL**, Gorospe EC, Chan DK, Muppa P, Owens V, Smyrk TC, Anderson M, Lutzke LS, Tearney G, Wang KK. Comparative diagnostic performance of volumetric laser endomicroscopy and confocal laser endomicroscopy in the detection of dysplasia associated with Barrett's esophagus. *Gastrointest Endosc* 2016; **83**: 880-888.e2 [PMID: [26344884](#) DOI: [10.1016/j.gie.2015.08.050](#)]
 - 12 **Struyvenberg MR**, van der Sommen F, Swager AF, de Groof AJ, Rikos A, Schoon EJ, Bergman JJ, de With PHN, Curvers WL. Improved Barrett's neoplasia detection using computer-assisted multiframe analysis of volumetric laser endomicroscopy. *Dis Esophagus* 2020; **33** [PMID: [31364700](#) DOI: [10.1093/dote/doz065](#)]
 - 13 **Poneros JM**, Brand S, Bouma BE, Tearney GJ, Compton CC, Nishioka NS. Diagnosis of specialized intestinal metaplasia by optical coherence tomography. *Gastroenterology* 2001; **120**: 7-12 [PMID: [11208708](#) DOI: [10.1053/gast.2001.20911](#)]
 - 14 **Isenberg G**, Sivak MV Jr, Chak A, Wong RC, Willis JE, Wolf B, Rowland DY, Das A, Rollins A. Accuracy of endoscopic optical coherence tomography in the detection of dysplasia in Barrett's esophagus: a prospective, double-blinded study. *Gastrointest Endosc* 2005; **62**: 825-831 [PMID: [16301020](#) DOI: [10.1016/j.gie.2005.07.048](#)]
 - 15 **Evans JA**, Poneros JM, Bouma BE, Bressner J, Halpern EF, Shishkov M, Lauwers GY, Mino-Kenudson M, Nishioka NS, Tearney GJ. Optical coherence tomography to identify intramucosal carcinoma and high-grade dysplasia in Barrett's esophagus. *Clin Gastroenterol Hepatol* 2006; **4**: 38-43 [PMID: [16431303](#) DOI: [10.1053/S1542-3565\(05\)00746-9](#)]
 - 16 **Chen Y**, Aguirre AD, Hsiung PL, Desai S, Herz PR, Pedrosa M, Huang Q, Figueiredo M, Huang SW, Koski A, Schmitt JM, Fujimoto JG, Mashimo H. Ultrahigh resolution optical coherence tomography of Barrett's esophagus: preliminary descriptive clinical study correlating images with histology. *Endoscopy* 2007; **39**: 599-605 [PMID: [17611914](#) DOI: [10.1055/s-2007-966648](#)]
 - 17 **Cobb MJ**, Hwang JH, Upton MP, Chen Y, Oelschlaeger BK, Wood DE, Kimmy MB, Li X. Imaging of subsquamous Barrett's epithelium with ultrahigh-resolution optical coherence tomography: a histologic correlation study. *Gastrointest Endosc* 2010; **71**: 223-230 [PMID: [19846077](#) DOI: [10.1016/j.gie.2009.07.005](#)]
 - 18 **Adler DC**, Zhou C, Tsai TH, Lee HC, Becker L, Schmitt JM, Huang Q, Fujimoto JG, Mashimo H. Three-dimensional optical coherence tomography of Barrett's esophagus and buried glands beneath neosquamous epithelium following radiofrequency ablation. *Endoscopy* 2009; **41**: 773-776 [PMID: [19746317](#) DOI: [10.1055/s-0029-1215045](#)]
 - 19 **Vakoc BJ**, Shishko M, Yun SH, Oh WY, Suter MJ, Desjardins AE, Evans JA, Nishioka NS, Tearney GJ, Bouma BE. Comprehensive esophageal microscopy by using optical frequency-domain imaging (with video). *Gastrointest Endosc* 2007; **65**: 898-905 [PMID: [17383652](#) DOI: [10.1016/j.gie.2006.08.009](#)]
 - 20 **Trindade AJ**, George BJ, Berkowitz J, Sejjal DV, McKinley MJ. Volumetric laser endomicroscopy can target neoplasia not detected by conventional endoscopic measures in long segment Barrett's esophagus. *Endosc Int Open* 2016; **4**: E318-E322 [PMID: [27004250](#) DOI: [10.1055/s-0042-101409](#)]
 - 21 **Jain D**, Fatima S, Jain S, Singhal S. Volumetric Laser Endomicroscopy for Barrett's Esophagus - Looking at the Fine Print. *J Gastrointest Liver Dis* 2017; **26**: 291-297 [PMID: [28922442](#) DOI: [10.15403/jgl.2014.1121.263.jai](#)]
 - 22 **Kohli DR**, Schubert ML, Zfass AM, Shah TU. Performance characteristics of optical coherence tomography in assessment of Barrett's esophagus and esophageal cancer: systematic review. *Dis Esophagus* 2017; **30**: 1-8 [PMID: [28881898](#) DOI: [10.1093/dote/dox049](#)]
 - 23 **Castela J**, Serrano M, Ferro SM, Pereira DV, Chaves P, Pereira AD. Buried Barrett's Esophagus with High-Grade Dysplasia after Radiofrequency Ablation. *Clin Endosc* 2019; **52**: 269-272 [PMID: [31364700](#) DOI: [10.1093/dote/doz065](#)]

- 30300980 DOI: [10.5946/ce.2018.124](https://doi.org/10.5946/ce.2018.124)]
- 24 **Spechler SJ**. Buried (but not dead) Barrett's metaplasia: tales from the crypts. *Gastrointest Endosc* 2012; **76**: 41-43 [PMID: [22726464](https://pubmed.ncbi.nlm.nih.gov/22726464/) DOI: [10.1016/j.gie.2012.02.053](https://doi.org/10.1016/j.gie.2012.02.053)]
 - 25 **Zhou C**, Tsai TH, Lee HC, Kirtane T, Figueiredo M, Tao YK, Ahsen OO, Adler DC, Schmitt JM, Huang Q, Fujimoto JG, Mashimo H. Characterization of buried glands before and after radiofrequency ablation by using 3-dimensional optical coherence tomography (with videos). *Gastrointest Endosc* 2012; **76**: 32-40 [PMID: [22482920](https://pubmed.ncbi.nlm.nih.gov/22482920/) DOI: [10.1016/j.gie.2012.02.003](https://doi.org/10.1016/j.gie.2012.02.003)]
 - 26 **Swager AF**, Boerwinkel DF, de Bruin DM, Faber DJ, van Leeuwen TG, Weusten BL, Meijer SL, Bergman JJ, Curvers WL. Detection of buried Barrett's glands after radiofrequency ablation with volumetric laser endomicroscopy. *Gastrointest Endosc* 2016; **83**: 80-88 [PMID: [26124075](https://pubmed.ncbi.nlm.nih.gov/26124075/) DOI: [10.1016/j.gie.2015.05.028](https://doi.org/10.1016/j.gie.2015.05.028)]
 - 27 **Benjamin T**, Shakya S, Thota PN. Feasibility of volumetric laser endomicroscopy in Barrett's esophagus with dysplasia and in post-ablation surveillance. *J Gastrointest Liver Dis* 2016; **25**: 407-408 [PMID: [27689210](https://pubmed.ncbi.nlm.nih.gov/27689210/) DOI: [10.15403/jgld.2014.1121.253.brt](https://doi.org/10.15403/jgld.2014.1121.253.brt)]
 - 28 **Standish BA**, Yang VX, Munce NR, Wong Kee Song LM, Gardiner G, Lin A, Mao YI, Vitkin A, Marcon NE, Wilson BC. Doppler optical coherence tomography monitoring of microvascular tissue response during photodynamic therapy in an animal model of Barrett's esophagus. *Gastrointest Endosc* 2007; **66**: 326-333 [PMID: [17643708](https://pubmed.ncbi.nlm.nih.gov/17643708/) DOI: [10.1016/j.gie.2007.02.040](https://doi.org/10.1016/j.gie.2007.02.040)]
 - 29 **Li H**, Standish BA, Mariampillai A, Munce NR, Mao Y, Chiu S, Marcon NE, Wilson BC, Vitkin A, Yang VX. Feasibility of interstitial Doppler optical coherence tomography for in vivo detection of microvascular changes during photodynamic therapy. *Lasers Surg Med* 2006; **38**: 754-761 [PMID: [16927368](https://pubmed.ncbi.nlm.nih.gov/16927368/) DOI: [10.1002/Lsm.20387](https://doi.org/10.1002/Lsm.20387)]
 - 30 **Lee HC**, Ahsen OO, Liang K, Wang Z, Figueiredo M, Giacomelli MG, Potsaid B, Huang Q, Mashimo H, Fujimoto JG. Endoscopic optical coherence tomography angiography microvascular features associated with dysplasia in Barrett's esophagus (with video). *Gastrointest Endosc* 2017; **86**: 476-484.e3 [PMID: [28167119](https://pubmed.ncbi.nlm.nih.gov/28167119/) DOI: [10.1016/j.gie.2017.01.034](https://doi.org/10.1016/j.gie.2017.01.034)]
 - 31 **Beaudette K**, Baac HW, Madore WJ, Villiger M, Godbout N, Bouma BE, Boudoux C. Laser tissue coagulation and concurrent optical coherence tomography through a double-clad fiber coupler. *Biomed Opt Express* 2015; **6**: 1293-1303 [PMID: [25909013](https://pubmed.ncbi.nlm.nih.gov/25909013/) DOI: [10.1364/BOE.6.001293](https://doi.org/10.1364/BOE.6.001293)]
 - 32 **Uno K**, Koike T, Shimosegawa T. Recent development of optical coherence tomography for preoperative diagnosis of esophageal malignancies. *World J Gastrointest Endosc* 2015; **7**: 872-880 [PMID: [26240688](https://pubmed.ncbi.nlm.nih.gov/26240688/) DOI: [10.4253/wjge.v7.i9.872](https://doi.org/10.4253/wjge.v7.i9.872)]
 - 33 **de Groof AJ**, Struyvenberg MR, Fockens KN, van der Putten J, van der Sommen F, Boers TG, Zinger S, Bisschops R, de With PH, Pouw RE, Curvers WL, Schoon EJ, Bergman JJGHM. Deep learning algorithm detection of Barrett's neoplasia with high accuracy during live endoscopic procedures: a pilot study (with video). *Gastrointest Endosc* 2020; **91**: 1242-1250 [PMID: [31926965](https://pubmed.ncbi.nlm.nih.gov/31926965/) DOI: [10.1016/j.gie.2019.12.048](https://doi.org/10.1016/j.gie.2019.12.048)]
 - 34 **Trindade AJ**, McKinley MJ, Fan C, Leggett CL, Kahn A, Pleskow DK. Endoscopic Surveillance of Barrett's Esophagus Using Volumetric Laser Endomicroscopy With Artificial Intelligence Image Enhancement. *Gastroenterology* 2019; **157**: 303-305 [PMID: [31078625](https://pubmed.ncbi.nlm.nih.gov/31078625/) DOI: [10.1053/j.gastro.2019.04.048](https://doi.org/10.1053/j.gastro.2019.04.048)]
 - 35 **Tsai TH**, Fujimoto JG, Mashimo H. Endoscopic Optical Coherence Tomography for Clinical Gastroenterology. *Diagnostics (Basel)* 2014; **4**: 57-93 [PMID: [26852678](https://pubmed.ncbi.nlm.nih.gov/26852678/) DOI: [10.3390/diagnostics4020057](https://doi.org/10.3390/diagnostics4020057)]
 - 36 **Kahn A**, Kamboj AK, Muppa P, Sawas T, Lutzke LS, Buras MR, Golafshar MA, Katzka DA, Iyer PG, Smyrk TC, Wang KK, Leggett CL. Staging of T1 esophageal adenocarcinoma with volumetric laser endomicroscopy: a feasibility study. *Endosc Int Open* 2019; **7**: E462-E470 [PMID: [30931378](https://pubmed.ncbi.nlm.nih.gov/30931378/) DOI: [10.1055/a-0838-5326](https://doi.org/10.1055/a-0838-5326)]



Published by **Baishideng Publishing Group Inc**
7041 Koll Center Parkway, Suite 160, Pleasanton, CA 94566, USA

Telephone: +1-925-3991568

E-mail: bpgoffice@wjgnet.com

Help Desk: <https://www.f6publishing.com/helpdesk>

<https://www.wjgnet.com>

