


Artificial Intelligence in *Gastrointestinal Endoscopy*

Artif Intell Gastrointest Endosc 2023 December 8; 4(2): 12-26





Artificial Intelligence in Gastrointestinal Endoscopy

Contents

Quarterly Volume 4 Number 2 December 8, 2023

MINIREVIEWS

- 12 Role of endoscopic ultrasound in non-variceal upper gastrointestinal bleeding management
Lesmana CRA

ORIGINAL ARTICLE

Retrospective Cohort Study

- 18 Artificial intelligence fails to improve colonoscopy quality: A single centre retrospective cohort study
Goetz N, Hanigan K, Cheng RKY

Contents

Artificial Intelligence in Gastrointestinal Endoscopy
Quarterly Volume 4 Number 2 December 8, 2023

ABOUT COVER

Editorial Board Member of *Artificial Intelligence in Gastrointestinal Endoscopy*, Amaninder Dhaliwal, MD, Assistant Professor, Department of Gastroenterology and Hepatology, Mcleod Regional Medical Center, Florence, SC 29501, United States. dramaninderdhaliwal@gmail.com

AIMS AND SCOPE

The primary aim of *Artificial Intelligence in Gastrointestinal Endoscopy* (AIGE, *Artif Intell Gastrointest Endosc*) is to provide scholars and readers from various fields of artificial intelligence in gastrointestinal endoscopy with a platform to publish high-quality basic and clinical research articles and communicate their research findings online.

AIGE mainly publishes articles reporting research results obtained in the field of artificial intelligence in gastrointestinal endoscopy and covering a wide range of topics, including artificial intelligence in capsule endoscopy, colonoscopy, double-balloon enteroscopy, duodenoscopy, endoscopic retrograde cholangio-pancreatography, endosonography, esophagoscopy, gastrointestinal endoscopy, gastroscopy, laparoscopy, natural orifice endoscopic surgery, proctoscopy, and sigmoidoscopy.

INDEXING/ABSTRACTING

The AIGE is now abstracted and indexed in Reference Citation Analysis, China Science and Technology Journal Database.

RESPONSIBLE EDITORS FOR THIS ISSUE

Production Editor: *Yi-Xuan Cai*, Production Department Director: *Xiang Li*, Editorial Office Director: *Jin-Lei Wang*.

NAME OF JOURNAL

Artificial Intelligence in Gastrointestinal Endoscopy

ISSN

ISSN 2689-7164 (online)

LAUNCH DATE

July 28, 2020

FREQUENCY

Quarterly

EDITORS-IN-CHIEF

Fatih Altintoprak, Sahin Coban, Krish Ragunath

EDITORIAL BOARD MEMBERS

<https://www.wjgnet.com/2689-7164/editorialboard.htm>

PUBLICATION DATE

December 8, 2023

COPYRIGHT

© 2023 Baishideng Publishing Group Inc

INSTRUCTIONS TO AUTHORS

<https://www.wjgnet.com/bpg/gerinfo/204>

GUIDELINES FOR ETHICS DOCUMENTS

<https://www.wjgnet.com/bpg/gerinfo/287>

GUIDELINES FOR NON-NATIVE SPEAKERS OF ENGLISH

<https://www.wjgnet.com/bpg/gerinfo/240>

PUBLICATION ETHICS

<https://www.wjgnet.com/bpg/gerinfo/288>

PUBLICATION MISCONDUCT

<https://www.wjgnet.com/bpg/gerinfo/208>

ARTICLE PROCESSING CHARGE

<https://www.wjgnet.com/bpg/gerinfo/242>

STEPS FOR SUBMITTING MANUSCRIPTS

<https://www.wjgnet.com/bpg/gerinfo/239>

ONLINE SUBMISSION

<https://www.f6publishing.com>

© 2023 Baishideng Publishing Group Inc. All rights reserved. 7041 Koll Center Parkway, Suite 160, Pleasanton, CA 94566, USA

E-mail: bpgoffice@wjgnet.com <https://www.wjgnet.com>

Role of endoscopic ultrasound in non-variceal upper gastrointestinal bleeding management

Cosmas Rinaldi Adithya Lesmana

Specialty type: Gastroenterology & hepatology

Provenance and peer review:
Invited article; Externally peer reviewed.

Peer-review model: Single blind

Peer-review report's scientific quality classification

Grade A (Excellent): 0
Grade B (Very good): B
Grade C (Good): 0
Grade D (Fair): 0
Grade E (Poor): 0

P-Reviewer: Rodrigo L, Spain

Received: July 28, 2023

Peer-review started: July 28, 2023

First decision: September 29, 2023

Revised: October 14, 2023

Accepted: December 4, 2023

Article in press: December 4, 2023

Published online: December 8, 2023



Cosmas Rinaldi Adithya Lesmana, Department of Internal Medicine, Hepatobiliary Division, Dr. Cipto Mangunkusumo National General Hospital, Medical Faculty Universitas Indonesia, Jakarta 10430, DKI, Indonesia

Cosmas Rinaldi Adithya Lesmana, Digestive Disease & GI Oncology Center, Medistra Hospital, Jakarta 12950, Indonesia

Cosmas Rinaldi Adithya Lesmana, Gastrointestinal Cancer Center, MRCCC Siloam Semanggi Hospital, Jakarta 12930, Indonesia

Corresponding author: Cosmas Rinaldi Adithya Lesmana, FACP, FACP, MD, PhD, Associate Professor, Department of Internal Medicine, Hepatobiliary Division, Dr. Cipto Mangunkusumo National General Hospital, Medical Faculty Universitas Indonesia, JL. Diponegoro 71, Jakarta 10430, DKI, Indonesia. medicaldr2001id@yahoo.com

Abstract

Non-variceal upper gastrointestinal bleeding (NVUGIB) is one of the challenging situations in clinical practice. Despite that gastric ulcer and duodenal ulcer are still the main causes of acute NVUGIB, there are other causes of bleeding which might not always be detected through the standard endoscopic evaluation. Standard endoscopic management of UGIB consists of injection, thermal coagulation, hemoclips, and combination therapy. However, these methods are not always successful for rebleeding prevention. Endoscopic ultrasound (EUS) has been used recently for portal hypertension management, especially in managing acute variceal bleeding. EUS has been considered a better tool to visualize the bleeding vessel in gastroesophageal variceal bleeding. There have been studies looking at the role of EUS for managing NVUGIB; however, most of them are case reports. Therefore, it is important to review back to see the evolution and innovation of endoscopic treatment for NVUGIB and the role of EUS for possibility to replace the standard endoscopic haemostasis management in daily practice.

Key Words: Non-variceal upper gastrointestinal bleeding; Endoscopic haemostasis; Endoscopic ultrasound; Bleeding vessel; Doppler image

©The Author(s) 2023. Published by Baishideng Publishing Group Inc. All rights reserved.

Core Tip: Non-variceal upper gastrointestinal bleeding is still one of the challenging situations in clinical practice. Standard endoscopic hemostasis has shown to have a high successful bleeding control rate; however, in some types of bleeding, there is still a possibility for endoscopic treatment failure. Endoscopic ultrasound can give a better bleeding vessel visualization, and it has shown to be a promising tool for non-variceal upper gastrointestinal bleeding management.

Citation: Lesmana CRA. Role of endoscopic ultrasound in non-variceal upper gastrointestinal bleeding management. *Artif Intell Gastrointest Endosc* 2023; 4(2): 12-17

URL: <https://www.wjgnet.com/2689-7164/full/v4/i2/12.htm>

DOI: <https://dx.doi.org/10.37126/aige.v4.i2.12>

INTRODUCTION

Upper gastrointestinal bleeding (UGIB) is one of the challenging situations in clinical practice due to its etiology, location, types of bleeding, and severity. It comprises of non-variceal and variceal bleeding[1,2]. In the past, there has been no significant change from time to time regarding the etiology of non-variceal upper gastrointestinal bleeding (NVUGIB). Gastric ulcer (GU) and duodenal ulcer (DU) are still the main causes of acute NVUGIB, where hemorrhage and perforation are the major causes for mortality[3,4]. A recent large multicenter study showed that the bleeding etiology for NVUGIB was dominated by DU, followed by GU, whereas neoplasia was ranked as the fourth common cause of NVUGIB when compared to other non-malignant causes, such as Mallory-Weiss, esophagitis, and Dieulafoy's lesion. Recurrent bleeding was found in 3.2% of patients, with a 4.5% mortality rate in 30 d. Standard endoscopic treatment, which consists of injection, thermal coagulation, hemoclips, and combination therapy, has shown a good bleeding control rate. However, endoscopic treatment failure was still found to be higher in patients with several predictors, such as in-hospital bleeding, hematemesis, renal failure, neoplasia, and liver cirrhosis[5]. Recently, there has been innovation management using endoscopic ultrasound (EUS) for managing variceal bleeding as it can target the bleeding vessel much better than conventional endoscopic management[6]. Therefore, in this review, the role of EUS will be discussed further.

METHODS

We collected all articles which have been published on standard endoscopic management as well as endoscopic ultrasound guided management in UGIB through the Medline/PubMed databases. The keywords used were EUS-guided vascular therapy, upper gastrointestinal bleeding, and non-variceal upper gastrointestinal bleeding. The purpose of this review was to elaborate the standard endoscopic management, limitations, new development or technique innovation, bleeding causes, and patient's outcome.

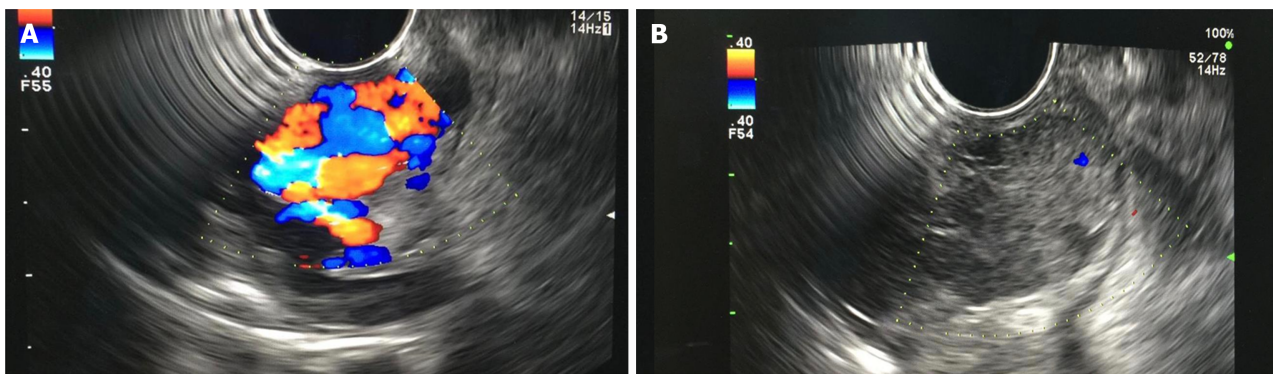
ENDOSCOPIC MANAGEMENT FOR NON-VARICEAL UPPER GASTROINTESTINAL BLEEDING

Standard endoscopic hemostasis treatment for NVUGIB consists of drug injection (epinephrine, cyanoacrylate, and other sclerosing agents), thermal coagulation, mechanical method, as well as topical treatment[7]. Endoscopic findings and bleeding ulcer stratification based on Forrest class have been routinely used as a standard parameter for the decision of endoscopic treatment options. Based on the Forrest classification, active bleeding (classes IA and B) has a 55% rebleeding rate with a 11% mortality rate, followed by visible vessel (class IIA) with a 43% rebleeding rate and 11% mortality rate, adherent clot (class IIB) with a 22% rebleeding rate and 7% mortality rate, flat spot (class IIC) with a 10% rebleeding rate and 3% mortality rate, and clean base ulcer (class III) with a 5% rebleeding rate and 2% mortality rate[8]. A randomized controlled trial by Chau *et al*[9] looking at the role of epinephrine injection combined with heat probe coagulation therapy *vs* epinephrine injection combined with argon plasma coagulation treatment in patients with bleeding peptic ulcers showed no significant difference between the two combined methods in achieving successful hemostasis (95.9% *vs* 97.7%). This study mostly included patients with Forrest classes IB and IIA. However, the rebleeding rate from both of groups was still high (21.6% and 17.0%), and the hospital mortality was 6.2% and 5.7%, respectively. Another randomized controlled trial by Lo *et al*[10] showed that combined therapy using epinephrine injection with hemoclip therapy *vs* epinephrine injection alone was more effective in reducing the rebleeding rate (100% *vs* 33%, $P = 0.02$). In fact, no surgery was even required in the combination treatment group when compared to the single treatment group ($P = 0.023$). The use of clips in NVUGIB might be associated with less mucosal injury when compared to thermal therapy[11]. In 2010, a novel endoscopic method using electrocautery forceps alone or with combined method based on retrospective multicenter data from patients with nonmalignant gastroduodenal ulcer bleeding in Japan showed that the rate of successful bleeding control was achieved in 96.8% of peptic ulcer patients, and 100% of artificial ulcer patients. However, there were 12 patients with rebleeding, which consisted of seven (11.5%) peptic ulcer patients and five (7.6%) artificial ulcer patients. In the rebleeding management, only one patient needed repeat endoscopic hemostasis treatment, and one patient required surgery after undergoing combination treatment. However, this study has been limited by the patient's selection bias as

well as the endoscopist's procedure skill[12]. Another innovation on endoscopic management on UGIB using a novel hemostatic powder (the "GRAPHE" registry), TC-325, showed that the immediate bleeding control effect was achieved by 96.5% of the patients; however, recurrent bleeding was found in 26.7% of patients at day 8 and 33.5% at day 30. Melena and pulsatile bleeding were the two most important factors for recurrent bleeding[13]. A large multicenter prospective study by Kawaguchi *et al*[14] showed that the most frequent cause of NVUGIB was gastric ulcer (GU; 69%), followed by DU (27%) and gastroduodenal ulcer (4%). The in-hospital 4-wk mortality rate was 5%, where two patients who died were associated with the bleeding itself. Patients with DU had a significantly higher mortality rate when compared to patients with GU (16% *vs* 4%, $P = 0.014$). In this study, 20 patients (8%) had unsuccessful endoscopic treatment. Other factors were comorbidities, the use of antithrombotic agent, and in-hospital onset. Based on the guideline recommendations from the international consensus group for NVUGIB management, it has been suggested that TC-325 can become a temporary treatment option with low evidence. This is due to its high rebleeding rates after 72 h and 1 wk. Endoscopic treatment, such as epinephrine injection, thermal coagulation, and clipping, is still considered as the main treatment. However, there was no significant difference in term of mortality rate even with combination therapy [15].

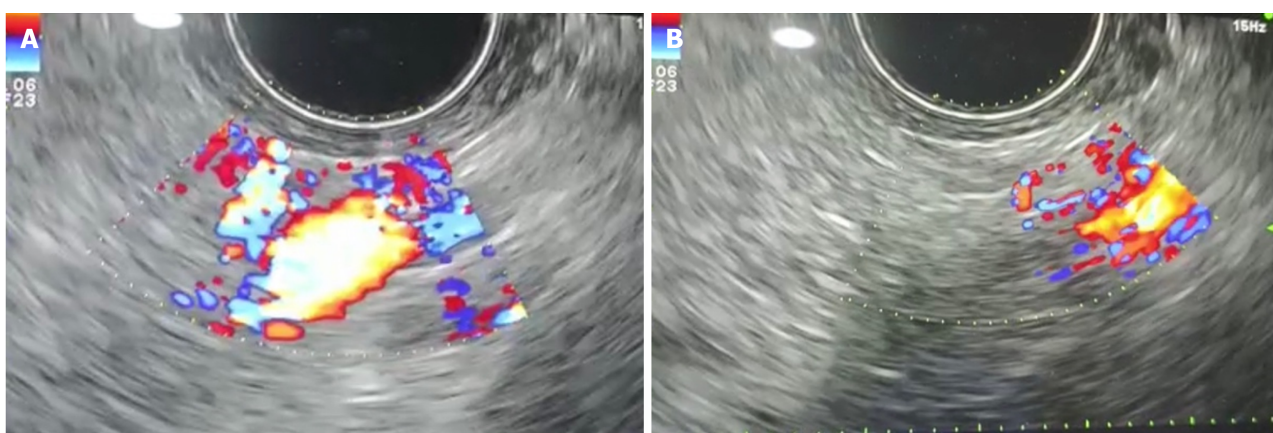
ENDOSCOPIC ULTRASOUND EVOLUTION AND INNOVATION IN MANAGING NON-VARICEAL UPPER GASTROINTESTINAL BLEEDING

In the evolution of therapeutic EUS development, a pioneer study by Boustière *et al*[16] performed EUS in liver cirrhotic patients, where gastric varices could be identified and stratified much better than esophageal varices. All cases suspected with the presence of GV was confirmed by EUS examination. In 2000, Lee *et al*[17] published a study on EUS-guided cyanoacrylate injection for bleeding GV showed that repeated injection under EUS guidance might improve patient survival as the recurrent bleeding incidence was decreased significantly when compared to on-demand treatment. Another small case series study by Romero-Castro *et al*[18] showed successful EUS-guided cyanoacrylate injection for the perforating veins related to GV. These innovation studies also have been supported by a recent acute variceal bleeding case series study[19], which concluded that EUS can give accurate approach in varices treatment (Figure 1). In 2011, a study by Binmoeller *et al*[20] showed that EUS-guided transesophageal combined treatment using coil and cyanoacrylate for GV management achieved a success in all cases. The rebleeding was noted to be not associated with the variceal bleeding. This was followed and supported by a recent study published by Bick *et al*[21], where they showed that by using EUS, the GV can be covered in a larger number when compared to the standard endoscopic injection. In fact, the use of EUS for NVUGIB management also has been studied in the past; however, most of them were only case report studies[22]. The first well-known case series study was published in 1996, which described the use of EUS examination for Dieulafoy's lesion evaluation and management. Three patients underwent sclerotherapy injection using 1% polidocanol under EUS guidance successfully without any adverse events[23]. This study was supported by other two case reports in patients who experienced bleeding due to Dieulafoy's lesion. One case report described the treatment using thermal contact with 7F Bicap probe (Boston Scientific). This probe was passed through the EUS channel combined with 2.5 mL absolute alcohol, which resulted in deep mucosal thermal burn, thus reducing the amplitude of arterial wave form. Another case underwent endoscopic band ligation after EUS evaluation. There was no rebleeding after the first procedure in both cases[24,25]. In 2008, Levy *et al*[26] published a study on EUS-guided angiotherapy for refractory NVUGIB, which consisted of bleeding due to hemosuccus pancreaticus, Dieulafoy's lesion, DU, and gastrointestinal stromal tumor (GIST), and occult GI bleeding. In this case series study, absolute alcohol injection was performed for hemosuccus pancreaticus bleeding and Dieulafoy's lesion, and cyanoacrylate injection for DU and GIST patients. All patients in this study did not have any rebleeding episodes, even after more than 12 mo. A larger case series study by Law *et al*[27] on the use of EUS-guided hemostasis treatment in patients with resistant non-variceal bleeding (GIST, colorectal vascular malformations, duodenal masses or polyps, Dieulafoy's lesions, DUs, and rectally invasive prostate cancer), showed that the complete vascular cessation was achieved in 63% of patients and the flow decrease in 37% of patients. There were no adverse events observed after the procedure. No patients had rebleeding within 12 mo follow-up after the procedure. Two studies reported only bleeding due to pancreatic pseudoaneurysm. One study reported a patient with chronic pancreatitis and splenic vein thrombosis with portal hypertension, who underwent EUS-guided pancreatic pseudocyst drainage and endoscopic retrograde cholangiopancreatography, followed by laparoscopic cholecystectomy for biliary tract stones. The late bleeding was due to the presence of pseudoaneurysm close to the pancreatic pseudocyst drainage area. The bleeding was controlled with *n*-butyl cyanoacrylate injection under EUS guidance. No recurrent bleeding was observed after the hemostatic procedure. The other case was a patient experiencing pseudoaneurysm induced by hemosuccus pancreaticus which has been confirmed by computed tomography angiography. This patient underwent EUS-guided coil embolization. No bleeding was recorded after more than a year[28,29]. The role of EUS-guided vascular therapy also has been reported in visceral pseudoaneurysm. The first case was reported by Lameris *et al* [30], where a thrombin-collagen compound was injected into pseudoaneurysm and the Doppler study revealed complete obliteration. No rebleeding occurred during 10 mo follow-up. Sharma *et al*[31] reported bleeding from visceral pseudoaneurysm due to acute pancreatitis, and it was successfully controlled by human thrombin injection. A recent single-blind study by Jensen *et al*[32] in 148 patients with severe NVUGIB who underwent endoscopic hemostasis under Doppler guidance showed that the rebleeding rate was significantly lower when compared to the control group (11.1% *vs* 26.3%, $P = 0.0214$). However, the use of EUS with Doppler guidance would give more accuracy and advantage to detect the bleeding source and manage severe NVUGIB due to possible poor visualization during standard endoscopic hemostasis procedure (Figure 2).



DOI: 10.37126/aige.v4.i2.12 Copyright ©The Author(s) 2023.

Figure 1 Gastric varices images before and after endoscopic ultrasound guided cyanoacrylate injection. A: Endoscopic ultrasound (EUS) image of large gastric varices; B: EUS image of gastric varices post cyanoacrylate injection. Endoscopy database Medistra Hospital, Jakarta.



DOI: 10.37126/aige.v4.i2.12 Copyright ©The Author(s) 2023.

Figure 2 Deep vascular bleeding source detection through endoscopic ultrasound (EUS) and after EUS-guided cyanoacrylate injection. A: Deep vascular bleeding source detection based on endoscopic ultrasound (EUS); B: EUS image after cyanoacrylate injection to control the bleeding source. Endoscopy database Medistra Hospital, Jakarta.

CONCLUSION

NVUGIB is still a challenging situation where there are a variety of causes which sometimes cannot be detected through standard endoscopic examination. EUS has shown that it has an important role in managing UGIB, especially in NVUGIB. However, it still needs larger study before it can be recommended as the first-line approach in managing NVUGIB.

FOOTNOTES

Author contributions: Lesmana CRA conceptualized the review, and wrote and edited the manuscript.

Conflict-of-interest statement: Cosmas Rinaldi Adithya Lesmana has no conflict of interest to disclose.

Open-Access: This article is an open-access article that was selected by an in-house editor and fully peer-reviewed by external reviewers. It is distributed in accordance with the Creative Commons Attribution NonCommercial (CC BY-NC 4.0) license, which permits others to distribute, remix, adapt, build upon this work non-commercially, and license their derivative works on different terms, provided the original work is properly cited and the use is non-commercial. See: <https://creativecommons.org/licenses/by-nc/4.0/>

Country/Territory of origin: Indonesia

ORCID number: Cosmas Rinaldi Adithya Lesmana 0000-0002-8218-5971.

S-Editor: Liu JH

L-Editor: Wang TQ

REFERENCES

- 1 **van Leerdam ME.** Epidemiology of acute upper gastrointestinal bleeding. *Best Pract Res Clin Gastroenterol* 2008; **22**: 209-224 [PMID: 18346679 DOI: 10.1016/j.bpg.2007.10.011]
- 2 **Orpen-Palmer J, Stanley AJ.** Update on the management of upper gastrointestinal bleeding. *BMJ Med* 2022; **1**: e000202 [PMID: 36936565 DOI: 10.1136/bmjmed-2022-000202]
- 3 **Elashoff JD, Grossman MI.** Trends in hospital admissions and death rates for peptic ulcer in the United States from 1970 to 1978. *Gastroenterology* 1980; **78**: 280-285 [PMID: 7350051]
- 4 **Koo J, Ngan YK, Lam SK.** Trends in hospital admission, perforation and mortality of peptic ulcer in Hong Kong from 1970 to 1980. *Gastroenterology* 1983; **84**: 1558-1562 [PMID: 6840485]
- 5 **Marmo R, Koch M, Cipolletta L, Capurso L, Pera A, Bianco MA, Rocca R, Dezi A, Fasoli R, Brunati S, Lorenzini I, Germani U, Di Matteo G, Giorgio P, Imperiali G, Minoli G, Barberani F, Boschetto S, Martorano M, Gatto G, Amuso M, Pastorelli A, Torre ES, Triossi O, Buzzi A, Cestari R, Della Casa D, Proietti M, Tanzilli A, Aragona G, Giangregorio F, Allegrretta L, Tronci S, Michetti P, Romagnoli P, Nucci A, Rogai F, Piubello W, Tebaldi M, Bonfante F, Casadei A, Cortini C, Chiozzini G, Girardi L, Leoci C, Bagnalasta G, Segato S, Chianese G, Salvagnini M, Rotondano G.** Predictive factors of mortality from nonvariceal upper gastrointestinal hemorrhage: a multicenter study. *Am J Gastroenterol* 2008; **103**: 1639-47; quiz 1648 [PMID: 18564127 DOI: 10.1111/j.1572-0241.2008.01865.x]
- 6 **McCarty TR, Bazarbashi AN, Hathorn KE, Thompson CC, Ryou M.** Combination therapy versus monotherapy for EUS-guided management of gastric varices: A systematic review and meta-analysis. *Endosc Ultrasound* 2020; **9**: 6-15 [PMID: 31417066 DOI: 10.4103/eus.eus_37_19]
- 7 **Cañamares-Orbis P, Chan FKL.** Endoscopic management of nonvariceal upper gastrointestinal bleeding. *Best Pract Res Clin Gastroenterol* 2019; **42-43**: 101608 [PMID: 31785733 DOI: 10.1016/j.bpg.2019.04.001]
- 8 **Hui AJ, Sung JJ.** Endoscopic Treatment of Upper Gastrointestinal Bleeding. *Curr Treat Options Gastroenterol* 2005; **8**: 153-162 [PMID: 15769437 DOI: 10.1007/s11938-005-0008-x]
- 9 **Chau CH, Siu WT, Law BK, Tang CN, Kwok SY, Luk YW, Lao WC, Li MK.** Randomized controlled trial comparing epinephrine injection plus heat probe coagulation versus epinephrine injection plus argon plasma coagulation for bleeding peptic ulcers. *Gastrointest Endosc* 2003; **57**: 455-461 [PMID: 12665753 DOI: 10.1016/s0016-5107(03)80008-1]
- 10 **Lo CC, Hsu PI, Lo GH, Lin CK, Chan HH, Tsai WL, Chen WC, Wu CJ, Yu HC, Cheng JS, Lai KH.** Comparison of hemostatic efficacy for epinephrine injection alone and injection combined with hemoclip therapy in treating high-risk bleeding ulcers. *Gastrointest Endosc* 2006; **63**: 767-773 [PMID: 16650535 DOI: 10.1016/j.gie.2005.11.048]
- 11 **Laine L, McQuaid KR.** Endoscopic therapy for bleeding ulcers: an evidence-based approach based on meta-analyses of randomized controlled trials. *Clin Gastroenterol Hepatol* 2009; **7**: 33-47; quiz 1 [PMID: 18986845 DOI: 10.1016/j.cgh.2008.08.016]
- 12 **Fujishiro M, Abe N, Endo M, Kawahara Y, Shimoda R, Nagata S, Homma K, Morita Y, Uedo N.** Retrospective multicenter study concerning electrocautery forceps with soft coagulation for nonmalignant gastroduodenal ulcer bleeding in Japan. *Dig Endosc* 2010; **22** Suppl 1: S15-S18 [PMID: 20590763 DOI: 10.1111/j.1443-1661.2010.00962.x]
- 13 **Haddara S, Jacques S, Lecleire S, Branche J, Leblanc S, Le Baleur Y, Privat J, Heyries L, Bichard P, Granval P, Chaput U, Koch S, Levy J, Godart B, Charachon A, Bourgaux JF, Metivier-Cesbron E, Chabrun E, Quentin V, Perrot B, Vanbiervliet G, Coron E.** A novel hemostatic powder for upper gastrointestinal bleeding: a multicenter study (the "GRAPHE" registry). *Endoscopy* 2016; **48**: 1084-1095 [PMID: 27760437 DOI: 10.1055/s-0042-116148]
- 14 **Kawaguchi K, Yoshida A, Yuki T, Shibagaki K, Tanaka H, Fujishiro H, Miyaoka Y, Yanagitani A, Koda M, Ikuta Y, Hamamoto T, Mukoyama T, Sasaki Y, Kushiyama Y, Yuki M, Noguchi N, Miura M, Ikebuchi Y, Yashima K, Kinoshita Y, Ishihara S, Isomoto H.** A multicenter prospective study of the treatment and outcome of patients with gastroduodenal peptic ulcer bleeding in Japan. *Medicine (Baltimore)* 2022; **101**: e32281 [PMID: 36626498 DOI: 10.1097/MD.00000000000032281]
- 15 **Barkun AN, Almadi M, Kuipers EJ, Laine L, Sung J, Tse F, Leontiadis GI, Abraham NS, Calvet X, Chan FKL, Douketis J, Enns R, Gralnek IM, Jairath V, Jensen D, Lau J, Lip GYH, Loffroy R, Maluf-Filho F, Meltzer AC, Reddy N, Saltzman JR, Marshall JK, Bardou M.** Management of Nonvariceal Upper Gastrointestinal Bleeding: Guideline Recommendations From the International Consensus Group. *Ann Intern Med* 2019; **171**: 805-822 [PMID: 31634917 DOI: 10.7326/M19-1795]
- 16 **Boustière C, Dumas O, Jouffre C, Letard JC, Patouillard B, Etaix JP, Barthélémy C, Audigier JC.** Endoscopic ultrasonography classification of gastric varices in patients with cirrhosis. Comparison with endoscopic findings. *J Hepatol* 1993; **19**: 268-272 [PMID: 8301060 DOI: 10.1016/s0168-8278(05)80581-1]
- 17 **Lee YT, Chan FK, Ng EK, Leung VK, Law KB, Yung MY, Chung SC, Sung JJ.** EUS-guided injection of cyanoacrylate for bleeding gastric varices. *Gastrointest Endosc* 2000; **52**: 168-174 [PMID: 10922086 DOI: 10.1067/mge.2000.107911]
- 18 **Romero-Castro R, Pellicer-Bautista FJ, Jimenez-Saenz M, Marcos-Sanchez F, Caunedo-Alvarez A, Ortiz-Moyano C, Gomez-Parra M, Herreras-Gutierrez JM.** EUS-guided injection of cyanoacrylate in perforating feeding veins in gastric varices: results in 5 cases. *Gastrointest Endosc* 2007; **66**: 402-407 [PMID: 17643723 DOI: 10.1016/j.gie.2007.03.008]
- 19 **Kalista KF, Hanif SA, Nababan SH, Lesmana CRA, Hasan I, Gani R.** The Clinical Role of Endoscopic Ultrasound for Management of Bleeding Esophageal Varices in Liver Cirrhosis. *Case Rep Gastroenterol* 2022; **16**: 295-300 [PMID: 35814797 DOI: 10.1159/000524529]
- 20 **Binmoeller KF, Weibert F, Shah JN, Kim J.** EUS-guided transesophageal treatment of gastric fundal varices with combined coiling and cyanoacrylate glue injection (with videos). *Gastrointest Endosc* 2011; **74**: 1019-1025 [PMID: 21889139 DOI: 10.1016/j.gie.2011.06.030]
- 21 **Bick BL, Al-Haddad M, Liangpunsakul S, Ghabril MS, DeWitt JM.** EUS-guided fine needle injection is superior to direct endoscopic injection of 2-octyl cyanoacrylate for the treatment of gastric variceal bleeding. *Surg Endosc* 2019; **33**: 1837-1845 [PMID: 30259158 DOI: 10.1007/s00464-018-6462-z]
- 22 **De Angelis CG, Cortegoso Valdivia P, Rizza S, Venezia L, Rizzi F, Gesualdo M, Saracco GM, Pellicano R.** Endoscopic Ultrasound-Guided Treatments for Non-Variceal Upper GI Bleeding: A Review of the Literature. *J Clin Med* 2020; **9** [PMID: 32245209 DOI: 10.3390/jcm9030866]
- 23 **Fockens P, Meenan J, van Dullemen HM, Bolwerk CJ, Tytgat GN.** Dieulafoy's disease: endosonographic detection and endosonography-

- guided treatment. *Gastrointest Endosc* 1996; **44**: 437-442 [PMID: 8905365 DOI: 10.1016/s0016-5107(96)70096-2]
- 24 **Ribeiro A**, Vazquez-Sequeiros E, Wiersema MJ. Doppler EUS-guided treatment of gastric Dieulafoy's lesion. *Gastrointest Endosc* 2001; **53**: 807-809 [PMID: 11375598 DOI: 10.1067/mge.2001.113913]
 - 25 **Folvik G**, Nesje LB, Berstad A, Odegaard S. Endosonography-guided endoscopic band ligation of Dieulafoy's malformation: a case report. *Endoscopy* 2001; **33**: 636-638 [PMID: 11473339 DOI: 10.1055/s-2001-15322]
 - 26 **Levy MJ**, Wong Kee Song LM, Farnell MB, Misra S, Sarr MG, Gostout CJ. Endoscopic ultrasound (EUS)-guided angiotherapy of refractory gastrointestinal bleeding. *Am J Gastroenterol* 2008; **103**: 352-359 [PMID: 17986314 DOI: 10.1111/j.1572-0241.2007.01616.x]
 - 27 **Law R**, Fujii-Lau L, Wong Kee Song LM, Gostout CJ, Kamath PS, Abu Dayyeh BK, Gleeson FC, Rajan E, Topazian MD, Levy MJ. Efficacy of endoscopic ultrasound-guided hemostatic interventions for resistant nonvariceal bleeding. *Clin Gastroenterol Hepatol* 2015; **13**: 808-12.e1 [PMID: 25245627 DOI: 10.1016/j.cgh.2014.09.030]
 - 28 **Mönkemüller K**, Neumann H, Meyer F, Kuhn R, Malfertheiner P, Fry LC. A retrospective analysis of emergency double-balloon enteroscopy for small-bowel bleeding. *Endoscopy* 2009; **41**: 715-717 [PMID: 19670141 DOI: 10.1055/s-0029-1214974]
 - 29 **Jeffers K**, Majumder S, Vege SS, Levy M. EUS-guided pancreatic pseudoaneurysm therapy: better to be lucky than good. *Gastrointest Endosc* 2018; **87**: 1155-1156 [PMID: 29024704 DOI: 10.1016/j.gie.2017.09.043]
 - 30 **Lameris R**, du Plessis J, Nieuwoudt M, Scheepers A, van der Merwe SW. A visceral pseudoaneurysm: management by EUS-guided thrombin injection. *Gastrointest Endosc* 2011; **73**: 392-395 [PMID: 20630509 DOI: 10.1016/j.gie.2010.05.019]
 - 31 **Sharma M**, Somani P, Sunkara T, Prajapati R, Talele R. Endoscopic ultrasound-guided coil embolization and thrombin injection of a bleeding gastroduodenal artery pseudoaneurysm. *Endoscopy* 2019; **51**: E36-E37 [PMID: 30537784 DOI: 10.1055/a-0790-8134]
 - 32 **Jensen DM**, Kovacs TOG, Ohning GV, Ghassemi K, Machicado GA, Dulai GS, Sedarat A, Jutabha R, Gornbein J. Doppler Endoscopic Probe Monitoring of Blood Flow Improves Risk Stratification and Outcomes of Patients With Severe Nonvariceal Upper Gastrointestinal Hemorrhage. *Gastroenterology* 2017; **152**: 1310-1318.e1 [PMID: 28167214 DOI: 10.1053/j.gastro.2017.01.042]



Published by **Baishideng Publishing Group Inc**
7041 Koll Center Parkway, Suite 160, Pleasanton, CA 94566, USA

Telephone: +1-925-3991568

E-mail: bpgoffice@wjgnet.com

Help Desk: <https://www.f6publishing.com/helpdesk>

<https://www.wjgnet.com>

