



Transanal excision of a malignant fibrous histiocytoma of anal canal: A case report and literature review

Beom Gyu Kim, In Taik Chang, Jun Seok Park, Yoo Shin Choi, Gi Hyeon Kim, Eon Sub Park, Chang Hwan Choi

Beom Gyu Kim, In Taik Chang, Jun Seok Park, Yoo Shin Choi, Department of Surgery, College of Medicine, Chung-Ang University, Seoul 156-755, Korea

Gi Hyeon Kim, Department of Radiology, College of Medicine, Chung-Ang University, Seoul 156-755, Korea

Eon Sub Park, Department of Pathology, College of Medicine, Chung-Ang University, Seoul 156-755, Korea

Chang Hwan Choi, Department of Internal Medicine, College of Medicine, Chung-Ang University, Seoul 156-755, Korea

Author contributions: Kim BG and Park JS contributed equally to this work; Kim GH and Choi CW provided diagnostic tools; Park ES and Choi YS worked with Chang IT to discuss the present case; Kim BG, Park JS and Chang IT wrote the paper.

Correspondence to: Professor In Taik Chang, Department of Surgery, Chung-Ang University College of Medicine, 224-1 Heukseok-Dong, Dongjak-Gu, Seoul 156-755, Korea. caumed5@freechal.com

Telephone: +82-2-62991548 Fax: +82-2-8247869

Received: November 11, 2007 Revised: December 20, 2007

Abstract

Malignant fibrous histiocytoma, which is composed of spindle-shaped cells arranged in a pleomorphic and storiform pattern, is rarely found in the colorectum. Although complete surgical excision remains the main stem of therapy, an optimal treatment strategy according to the stage has not been elucidated. We report a case of a 63-year-old woman with an ulcerative lesion in the anorectal junction and a final diagnosis of malignant fibrous histiocytoma. We introduced an access for transanal local excision and adjuvant radiotherapy because the patient refused abdominoperineal resection. No local recurrences or distant metastases were observed 15 mo after the operation. To our knowledge, this is the first case reported in the English literature of a malignant fibrous histiocytoma treated with the transanal local excision and adjuvant radiotherapy. This report showed that this approach is selectively reserved for early-stage malignant fibrous histiocytoma and for those patients who refuse radical surgery because of the risk in a permanent colostomy.

© 2008 WJG. All rights reserved.

Key words: Malignant fibrous histiocytoma; Anorectal junction; Transanal local excision

Peer reviewer: Marc Basson, MD, PhD, MBA, Chief of Surgery, John D. Dingell VA Medical Center, 4646 John R. Street, Detroit, MI 48301, United States

Kim BG, Chang IT, Park JS, Choi YS, Kim GH, Park ES, Choi CH. Transanal excision of a malignant fibrous histiocytoma of anal canal: A case report and literature review. *World J Gastroenterol* 2008; 14(9): 1459-1462 Available from: URL: <http://www.wjgnet.com/1007-9327/14/1459.asp> DOI: <http://dx.doi.org/10.3748/wjg.14.1459>

INTRODUCTION

Malignant fibrous histiocytoma (MFH) is a soft-tissue sarcoma composed of anaplastic-appearing fibroblasts and histiocytes arranged in a storiform collagenous matrix. MFH is the most common type of soft-tissue sarcoma in adults and it usually localizes in the lower extremities, especially the thigh^[1,2]. Colorectal MFH, however, remains extremely rare and only a few cases have been reported worldwide^[3-23]. Surgical resection is thought to be the most effective treatment. Adjuvant chemotherapy or radiotherapy may be advisable, but the optimal histology-specific treatment protocol of this disease has not been clarified.

We report a case of a 63-year-old patient with MFH of the anorectal junction who was treated by transanal local excision and adjuvant radiotherapy. We also briefly discuss the diagnosis, surgical treatment, and adjuvant therapy of this rare case.

CASE REPORT

A 63-year-old woman was referred to our institution because of blood tinged stool and anal mass that was discovered during screening colonoscopy. She had no history of anal surgery or radiation therapy. A well defined mass on the right anterior aspect of the anal canal was palpated *via* digital rectal examination and was located 3 cm from the anal verge. Routine laboratory data and levels of tumor marker, carcinoembryonic antigen, alpha-fetoprotein, and carbohydrate antigen 19-9 revealed no marked abnormalities.

On colonoscopy examination, an ulcerative fungating mass, beginning proximal to the dentate line and extending cranially for about 1 cm, was found (Figure 1). Computed tomography of the abdomen and pelvis did not show the presence of the mass. However, anal magnetic resonance imaging confirmed a tumor of at least 1.5 cm diameter growing into the distal rectal lumen (Figure 2). The surrounding structures appeared to be free from invasion,

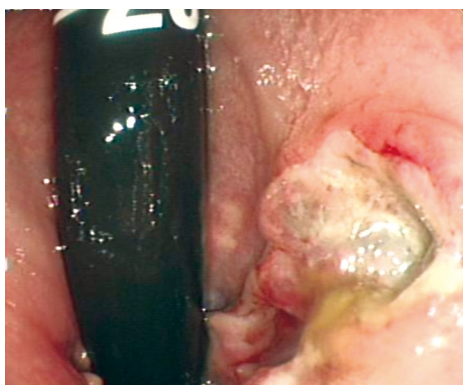

Figure 1 On colonoscopy, an ulcerated fungating mass was detected 3 cm from the anal verge.

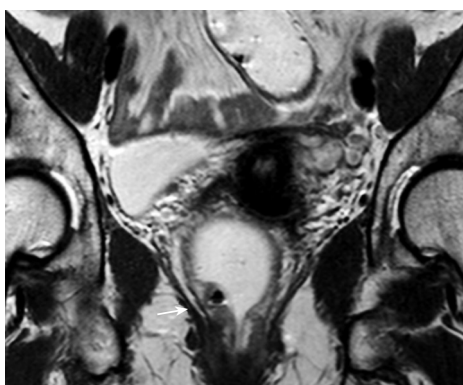


Figure 2 Magnetic resonance imaging shows a T1-weighted of low signal area (arrow) growing in the anterior portion of the anorectal junction.

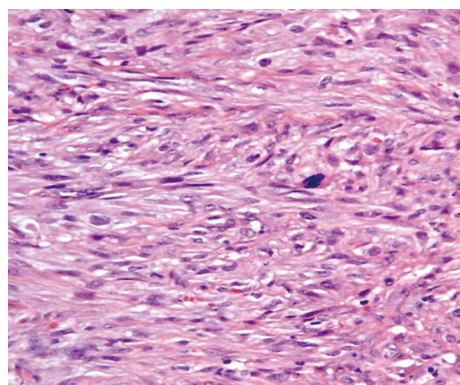


Figure 3 Histological section shows a typical malignant fibrous histiocytoma featuring spindle cells arranged in a storiform pattern (HE, $\times 400$).

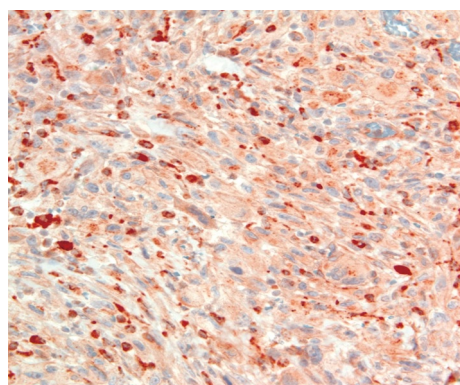


Figure 4 Tumor cells show positive immunostaining for CD68 ($\times 400$).

and we excluded extension into the muscularis propria of the bowel wall. These results were consistent with anal or rectal cancer. However, a colonoscopic biopsy specimen revealed a few giant malignant cells arranged in a sheet like pattern among necrotic granulation tissues. We made a preoperative diagnosis of a malignant spindle-shaped tumor or nonepithelial malignant tumor.

Our first plan, an abdominoperineal resection with end colostomy, was refused by the patient. The alternative, a sphincter-sparing transabdominal approach with colonal anastomosis, seemed to be technically difficult because of the tumor's its low location and possible focal involvement of the dentate line. We decided to use the initial transanal approach to define the tumor character and the risk of aggressive behavior, and to consider a more aggressive treatment if the tumor belonged to a high-risk group. Under general anesthesia, the patient was placed in the jack-knife position, and a transanal local excision was made. The tumor was located in the submucosal layer and was excised completely with just a small amount of adherent fiber of the anal sphincter and a resection-free margin of 1 cm. After excision, we obtained a further resection margin through multiple punch biopsies, which included the proximal and distal margin, right and left lateral margin, and deep margin around the surgical bed. The muscular layer of the surgical bed was closed with Dexon sutures.

Gross pathological examination showed a 1.7 cm \times

1.3 cm \times 0.3 cm fibrous-elastic mass. On the cut section, the tumor was firm in consistency, solid, and yellowish in color. Histological examination showed that the tumor was pleomorphic and composed of atypical spindle cells. These cells were arranged in a storiform pattern (Figure 3). The resection margins of the specimen and all the punch-biopsied tissue were free of tumor. Immunohistochemical stains were positive for CD68, vimentin and negative for cytokeratins, CD117, CD34, alpha smooth muscle actin, desmin, S-100 protein, and HMB-45 (Figure 4). The final histopathological diagnosis was MFH of the anal canal.

The patient had an uneventful postoperative course. No implication in anal continence was observed, and she was discharged on the fifth postoperative day. She received postoperative radiation (60 gray/30 fractions) to the surgical bed. Follow-up studies after 15 mo, including colonoscopy, computed tomography, anal magnetic resonance imaging, and ^{18}F -fluorodeoxyglucose positron emission tomography scan showed no evidence of local recurrence or distant metastasis.

DISCUSSION

MFH was first described in 1963 by Ozello *et al* and was established by O'Brien and Stout in 1964, which refers to a group of soft tissue sarcoma composed of both histiocytic and fibrous elements, often has some common features,

Table 1 Clinical features of malignant fibrous histiocytoma of anorectum reported in literature

Author (year)	Age/sex	Site	Tumor size (cm)	Primary therapy	Adjuvant therapy	Metastasis/recurrence	Outcome (mo. from first op.)	Remark
Verma (1979) ^[3]	38/M	Rectum	12	APR	No	NED	Alive (14)	AV 6 cm
Spagnoli (1984) ^[9]	68/M	Anal cannal	2.0 × 1.6	APR	NA	Lung	Dead (24)	NA
Flood (1989) ^[12]	41/M	Anal cannal	6	APR	Radiation	NED	Alive (16)	Anal sphincter ¹
Singh (1999) ^[21]	55/M	Rectum	4 × 2.5	APR	Chemorad	NED	Alive (46)	AV 4 cm
Present case (2007)	63/F	Anal cannal	1.7 × 1.3	TAE	Radiation	NED	Alive (15)	AV 3 cm

NA: No available information; M: Male; F: Female; APR: Abdominoperineal resection; TAE: Transanal local excision; Chemorad: Adjuvant chemo-radiation therapy; NED: No evidence of disease relapse; AV: Anal verge. ¹Tumor located in the deeper part of anal sphincter (left ischiorectal fossa).

such as pleomorphism and storiform pattern of growth and is accompanied by inflammatory cells^[24,25]. The most frequent site of MFH is the deep tissue of the extremities and trunk. In a retrospective series of 167 patients, 50% of MFH arose in the lower limb, 24% in the upper limbs, 16% in the trunk and 9% retroperitoneum^[26].

The large bowel is an exceedingly rare site of primary MFH. We found only 21 reported cases of primary MFH originating from the colorectum^[3-23]. The median age of these patients, including our patient, is 62 years, with a range of 12-85 years and two pediatric cases have been described^[5,16]. A female predominance has been suggested for extremity MFH, otherwise a review of the literature revealed 19 male and six female patients with colorectal MFH^[20]. Most tumors are large, ranging from 2 cm to 19 cm in diameter (median diameter, 7 cm), and the tumor in our patient is probably one of the smallest tumor observed. The distribution differs from more common types of colorectal cancer^[22]. The tumor locations include nine in the right-sided colon, seven in the transverse and descending colon, three in the sigmoid colon, and four in the anorectum. From the literature, we identified four cases with colorectal MFH which were located in the anorectum (Table 1). All reported lesions were located within 6 cm above the dentate line and were removed by abdominoperineal resection. Two patients treated with radiation as adjuvant treatment survived and were disease free 16 and 46 mo after the initial surgery.

The diagnosis of MFH depends on an accurate differential diagnosis from other sarcomas. The differential diagnosis includes gastrointestinal stromal tumor, fibrosarcoma, leiomyosarcoma, and myxoid sarcoma. Gastrointestinal stromal tumor can be easily identified on the immunohistochemical stains which are positive for CD117 and CD34. The uniform population of spindle cells and the absence of histiocytoid cells and storiform pattern areas may aid the diagnosis of fibrosarcoma. The presence of cells with perinuclear vacuoles, intracytoplasmic glycogen, and desmin positivity is suggestive of leiomyosarcoma; and finally, a diffuse, prominent myxoid background with interspersed atypical pleomorphic spindle cells is reminiscent of myxoid sarcoma. It was reported that MFH frequently expresses vimentin, actin, alpha 1-antitrypsin and CD68^[27]. Therefore, MFH in the current patient was diagnosed based on the histological findings of the characteristic storiform pattern and the positive immunohistochemical staining for vimentin and CD68.

The efficacy of radiation therapy is well established in

the treatment of soft tissue sarcoma of extremities^[28]. After postoperative radiation therapy, the local recurrence rate is lower (27%) than in patients with similar tumor-related characteristics who were not treated with radiation (58%). The effect of adjuvant radiotherapy to gastrointestinal MFH is unclear. In the current case, there were concerns that a microscopic residual tumor infiltrating through the circumference tissue might remain because we could not perform the radical resection. Moreover, as local recurrence is found in the most common pattern of colorectal MFH, we decided to perform adjuvant radiation therapy in our patient.

Previous studies reported that radical excision, like amputation, decreases the local recurrence rates in soft tissue sarcoma of the extremities. However, limb salvage with more conservative surgery or function sparing-surgery is performed increasingly. As for anorectal gastrointestinal stromal tumors, some authors suggested that most tumors with a diameter less than 5 cm treated with local excision and radical surgery including abdominoperineal resection are associated with high mortality and morbidity^[29]. It is thought that the natural history of these patients partly excludes the benefit of radical surgery. In our patient, because the primary lesion was detected at an early stage by a screening colonoscopy, we could excise the tumor completely using the transanal approach. Fortunately, no clinical signs of local recurrence or metastasis were detected at the follow-up examination after 15 mo. Based on our experience, we think this approach enables an alternative for early stage patients who cannot tolerate radical surgery or refuse the abdominal-perineal resection.

Due to the rarity of anorectal MFH, there is an absence of histology-specific treatment protocol at present. More data are needed about the oncologic outcomes of sphincter preserving operations with multimodality therapy, as well as the feasibility and safety of salvage operations in case of local recurrence.

REFERENCES

- 1 Weiss SW, Enzinger FM. Malignant fibrous histiocytoma: an analysis of 200 cases. *Cancer* 1978; **41**: 2250-2266
- 2 Peiper M, Zurakowski D, Knoefel WT, Izbicki JR. Malignant fibrous histiocytoma of the extremities and trunk: an institutional review. *Surgery* 2004; **135**: 59-66
- 3 Verma P, Chandra U, Bhatia PS. Malignant histiocytoma of the rectum: report of a case. *Dis Colon Rectum* 1979; **22**: 179-182
- 4 Sewell R, Levine BA, Harrison GK, Tio F, Schwesinger WH. Primary malignant fibrous histiocytoma of the intestine: intussusception of a rare neoplasm. *Dis Colon Rectum* 1980; **23**:

- 198-201
- 5 **Levinson MM**, Tsang D. Multicentric malignant fibrous histiocytomas of the colon. Report of a case and review of the subject. *Dis Colon Rectum* 1982; **25**: 327-331
- 6 **Waxman M**, Faegenburg D, Waxman JS, Janelli DE. Malignant fibrous histiocytoma of the colon associated with diverticulitis. *Dis Colon Rectum* 1983; **26**: 339-343
- 7 **Rubbini M**, Marzola A, Spanedda R, Scalco GB, Zamboni P, Guerrero C, Donini I. Primary malignant fibrous histiocytoma of the sigmoid colon: a case report. *Ital J Surg Sci* 1983; **13**: 299-302
- 8 **Adams HW**. Malignant fibrous histiocytoma associated with diverticulitis of the colon. *J Miss State Med Assoc* 1984; **25**: 205-206
- 9 **Spagnoli LG**, Dell'Isola C, Sportelli G, Mauriello A, Rizzo F, Casciani CU. Primary malignant fibrous histiocytoma of storiform-pleomorphic type: a case report of an ano-rectal localization. *Tumori* 1984; **70**: 567-570
- 10 **Baratz M**, Ostrzega N, Michowitz M, Messer G. Primary inflammatory malignant fibrous histiocytoma of the colon. *Dis Colon Rectum* 1986; **29**: 462-465
- 11 **Satake T**, Matsuyama M. Cytologic features of ascites in malignant fibrous histiocytoma of the colon. *Acta Pathol Jpn* 1988; **38**: 921-928
- 12 **Flood HD**, Salman AA. Malignant fibrous histiocytoma of the anal canal. Report of a case and review of the literature. *Dis Colon Rectum* 1989; **32**: 256-259
- 13 **Katz RN**, Waye JD, Batzel EL, Reiner MA, Freed JS. Malignant fibrous histiocytoma of the gastrointestinal tract in a patient with neurofibromatosis. *Am J Gastroenterol* 1990; **85**: 1527-1530
- 14 **Fukino S**, Fukata T, Okano K, Hamasaki T, Inoue A, Yukawa K, Kamba S. A case of malignant fibrous histiocytoma of the cecum. *Nippon Geka Gakkai Zasshi* 1990; **91**: 1752-1755
- 15 **Murata I**, Makiyama K, Miyazaki K, Kawamoto AS, Yoshida N, Muta K, Itsuno M, Hara K, Nakagoe T, Tomita M. A case of inflammatory malignant fibrous histiocytoma of the colon. *Gastroenterol Jpn* 1993; **28**: 554-563
- 16 **Huang Z**, Wei K. Malignant fibrous histiocytoma of the ascending colon in a child. *Am J Gastroenterol* 1993; **88**: 972-973
- 17 **Makino M**, Kimura O, Kaibara N. Radiation-induced malignant fibrous histiocytoma of the transverse colon: case report and review of the literature. *J Gastroenterol* 1994; **29**: 767-771
- 18 **Kawashima H**, Ikeue S, Takahashi Y, Kashiya M, Hara T, Yamazaki S, Hirao M, Okamoto K. Primary malignant fibrous histiocytoma of the descending colon. *Surg Today* 1997; **27**: 851-854
- 19 **Hiraoka N**, Mukai M, Suzuki M, Maeda K, Nakajima K, Hashimoto M, Hosoda Y, Hata J. Malignant fibrous histiocytoma of the cecum: report of a case and review of the literature. *Pathol Int* 1997; **47**: 718-724
- 20 **Udaka T**, Suzuki Y, Kimura H, Miyashita K, Suwaki T, Yoshino T. Primary malignant fibrous histiocytoma of the ascending colon: report of a case. *Surg Today* 1999; **29**: 160-164
- 21 **Singh DR**, Aryya NC, Sahi UP, Shukla VK. Malignant fibrous histiocytoma of the rectum. *Eur J Surg Oncol* 1999; **25**: 447-448
- 22 **Okubo H**, Ozeki K, Tanaka T, Matsuo T, Mochinaga N. Primary malignant fibrous histiocytoma of the ascending colon: report of a case. *Surg Today* 2005; **35**: 323-327
- 23 **Bosmans B**, de Graaf EJ, Torenbeek R, Tetteroo GW. Malignant fibrous histiocytoma of the sigmoid: a case report and review of the literature. *Int J Colorectal Dis* 2007; **22**: 549-552
- 24 **Ozzello L**, Stout AP, Murray MR. Cultural characteristics of malignant histiocytomas and fibrous xanthomas. *Cancer* 1963; **16**: 331-344
- 25 **O'Brien JE**, Stout AP. Malignant fibrous xanthomas. *Cancer* 1964; **17**: 1445-1455
- 26 **Kearney MM**, Soule EH, Ivins JC. Malignant fibrous histiocytoma: a retrospective study of 167 cases. *Cancer* 1980; **45**: 167-178
- 27 **Anagnostopoulos G**, Sakorafas GH, Grigoriadis K, Kostopoulos P. Malignant fibrous histiocytoma of the liver: a case report and review of the literature. *Mt Sinai J Med* 2005; **72**: 50-52
- 28 **Peiper M**, Zurakowski D, Knoefel WT, Izbicki JR. Malignant fibrous histiocytoma of the extremities and trunk: an institutional review. *Surgery* 2004; **135**: 59-66
- 29 **Miettinen M**, Furlong M, Sarlomo-Rikala M, Burke A, Sobin LH, Lasota J. Gastrointestinal stromal tumors, intramural leiomyomas, and leiomyosarcomas in the rectum and anus: a clinicopathologic, immunohistochemical, and molecular genetic study of 144 cases. *Am J Surg Pathol* 2001; **25**: 1121-1133

S- Editor Zhong XY L- Editor Ma JY E- Editor Ma WH