



A rare etiology of post-endoscopic retrograde cholangiopancreatography pneumoperitoneum

Stelios F Assimakopoulos, Konstantinos C Thomopoulos, Sofia Giali, Christos Triantos, Dimitrios Siagris, Charalambos Gogos

Stelios F Assimakopoulos, Sofia Giali, Dimitrios Siagris, Charalambos Gogos, Department of Internal Medicine, School of Medicine, University of Patras, Patras 26110, Greece
Konstantinos C Thomopoulos, Christos Triantos, Division of Gastroenterology, Department of Internal Medicine, School of Medicine, University of Patras, Patras 26110, Greece
Author contributions: Assimakopoulos SF, Giali S and Siagris D were the patient's doctors in the clinic; Thomopoulos KC and Triantos C performed the ERCP and gastroenterological consultation; Assimakopoulos SF and Gogos C had the idea for case presentation; all authors acquired the data; Assimakopoulos SF wrote the manuscript; Thomopoulos KC and Gogos C revised the manuscript.

Correspondence to: Dr. Stelios F Assimakopoulos, Department of Internal Medicine, School of Medicine, University of Patras, Vironos 18, Patras 26224, Greece. sassim@upatras.gr
Telephone: +30-2610-346946 Fax: +30-2610-993982
Received: January 25, 2008 Revised: March 24, 2008

Abstract

Major complications of endoscopic retrograde cholangiopancreatography (ERCP) include pancreatitis, hemorrhage, cholangitis, and duodenal perforation. The occurrence of free air in the peritoneal cavity post-ERCP is a rare event (< 1%), which is usually the result of duodenal or ductal perforation related to therapeutic ERCP with sphincterotomy. We describe for the first time a different aetiology of pneumoperitoneum, in an 84-year-old woman with pancreatic cancer and a large hepatic metastasis, after ERCP with common bile duct stent deployment. Our patient developed pneumoperitoneum due to air leakage from rupture of intrahepatic bile ducts and Glisson's capsule in the area of a peripheral large hepatic metastasis. The potential mechanism underlying this complication might be post-ERCP pneumobilia and increased pressure of intrahepatic bile ducts leading to rupture of intrahepatic bile ducts in the liver metastatic mass owing to neoplastic tissue friability. This case indicates the need for close clinical and radiological observation of patients with hepatic masses (primary or metastatic) subjected to ERCP. In such patients, avoidance of excessive air insufflation during ERCP and/or placement of a nasogastric tube for bowel decompression immediately after ERCP might be a reasonable strategy to prevent such unusual complications.

Key words: Endoscopic retrograde cholangiopancreatography; Pneumoperitoneum; Complications; Pneumobilia; Hepatic metastases

Peer reviewer: Markus Reiser, Professor, Dr, Gastroenterology-Hepatology, Ruhr-University Bochum, Bürkle-de-la-Camp-Platz 1, Bochum 44789, Germany

Assimakopoulos SF, Thomopoulos KC, Giali S, Triantos C, Siagris D, Gogos C. A rare etiology of post-endoscopic retrograde cholangiopancreatography pneumoperitoneum. *World J Gastroenterol* 2008; 14(18): 2917-2919 Available from: URL: <http://www.wjgnet.com/1007-9327/14/2917.asp> DOI: <http://dx.doi.org/10.3748/wjg.14.2917>

INTRODUCTION

Endoscopic retrograde cholangiopancreatography (ERCP) and sphincterotomy are increasingly used in the diagnosis and management of patients with pancreaticobiliary diseases, carrying a lower morbidity and mortality rate than surgery^[1]. This invasive procedure has been proven to be a safe and effective method for diagnosis and treatment of biliary and pancreatic disorders, with a very low rate of complications even in the very old (> 80 years old) patients despite the higher prevalence of co-morbidities^[2,3].

Major complications of ERCP include pancreatitis, hemorrhage, cholangitis, and duodenal perforation^[4,5]. Pneumoperitoneum occurring after ERCP is usually a sinister sign of bowel or ductal perforation^[6,7]. We describe for the first time a case of post-ERCP pneumoperitoneum in an 84-year-old woman due to air leakage from rupture of intrahepatic bile ducts and Glisson's capsule in the area of a large hepatic metastasis.

CASE REPORT

An 84-year-old woman with a past medical history of a carcinoma of the head of the pancreas with hepatic and lung metastases, who underwent an ERCP with stent placement because of obstructive jaundice at the time of diagnosis two months ago, was admitted again to our department because of icterus.

At admission, physical examination was unremarkable except for the presence of skin and conjunctival icterus. Initial laboratory evaluation confirmed the cholestatic

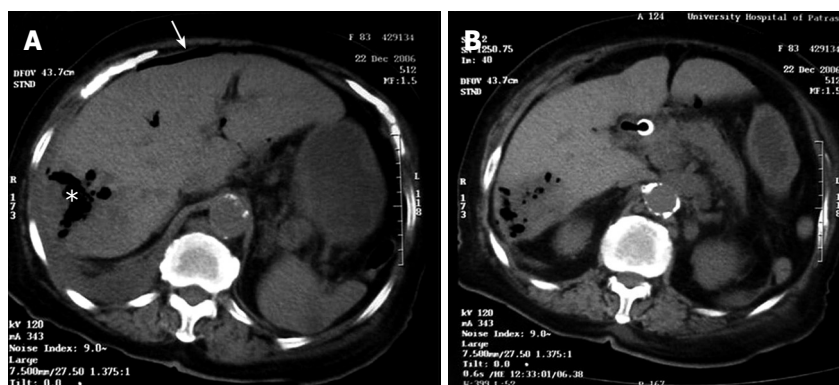


Figure 1 Contrast-enhanced abdominal CT showing an extensive necrotic air-containing lesion touching Glisson's capsule in the posterior right hepatic lobe within a metastatic hepatic mass (asterisk) and free air (arrow) (A). The metallic stent in the common bile duct is at the proper position and there is pneumobilia of the common bile duct and intrahepatic bile ducts of the metastatic mass in the posterior right hepatic lobe (B).

syndrome [total bilirubin = 8.13 mg/dL (reference range 0.1-1.3 mg/dL), direct bilirubin = 5.6 mg/dL (reference range < 0.4 mg/dL), γ -glutamyl-transaminase = 386 IU/L (reference range 10-50 IU/L), alkaline phosphatase = 541 IU/L (reference range 34-104 IU/L), aspartate aminotransferase = 510 IU/L (reference range 5-40 IU/L) and alanine aminotransferase = 413 IU/L (reference range 5-40 IU/L)]. An upper abdominal ultrasound showed a significant dilatation of the common bile duct and a hypoechoic mass of the right lobe of the liver (known metastasis). The patient underwent a second ERCP to check the stent's patency, function and position. The stent was found to be partially obstructed by tumor ingrowth and reopened by placing a new stent through the previous one. Cholangiography after stent deployment showed that the endoprosthesis was at a correct position and fully expanded, whilst there was a free contrast medium flowing to the common bile duct without any leakage. On the next day, the patient complained of distending abdominal discomfort. Physical examination showed that the patient was afebrile, hemodynamically stable, with abdominal distension but no signs of acute abdomen, such as guarding or rebound tenderness. The peripheral blood cell count showed leukocytosis ($27\,000/\text{mm}^3$, with 94% of neutrophils). An urgent contrast-enhanced abdominal computed tomography (CT) scan was performed, demonstrating the presence of free air in the peritoneal cavity, mainly perihepatically (Figure 1). There was no evidence of pneumoretroperitoneum, extraluminal contrast medium leakage or intraperitoneal fluid collection on computed tomography. Beyond the known tumour of the head of the pancreas, the abdominal CT showed that the metallic stent was at the proper position within the common bile duct and that there was pneumobilia of the common bile duct and intrahepatic bile ducts. At the position of the known large metastatic mass of the right hepatic lobe, there was an extensive necrotic air-containing lesion touching Glisson's capsule. The patient was treated conservatively, under close clinical surveillance, with no oral intake of, analgesics and systemic broad-spectrum antibiotics (meropenem, 1 g, three times a day and teicoplanin, 12 mg/kg per day), nasogastric drainage and intravenous fluid replacement. The patient's condition was gradually improved, oral feeding was reinstituted on post-ERCP day 10 without problems and she was discharged in a good condition on post-ERCP d 14.

DISCUSSION

Major complications of ERCP include pancreatitis, hemorrhage, cholangitis, and duodenal perforation^[4,5]. The occurrence of free air in the peritoneal cavity post-ERCP is usually the result of duodenal or ductal perforation related to therapeutic ERCP and sphincterotomy^[4,6-8]. Given that the overall incidence of duodenal and common bile duct perforations is about 1% and most of these cases (80%) have retroperitoneal perforations causing pneumoretroperitoneum, it becomes apparent that post-ERCP pneumoperitoneum is a very rare complication^[4].

In our patient, the developed post-ERCP pneumoperitoneum was considered benign in nature as it was not accompanied with peritonitis. The use of contrast-enhanced abdominal CT was helpful in excluding ERCP-related retroperitoneal and bowel perforation, as demonstrated by the absence of pneumoretroperitoneum, extraluminal contrast medium leakage or abnormal intra-abdominal fluid collection. Also the cholangiogram obtained during ERCP after endoprosthesis deployment did not demonstrate any contrast medium leakage secondary to common bile duct injury. Surprisingly, the abdominal CT revealed a large necrotic air-containing lesion in a metastatic mass of the right hepatic lobe, touching Glisson's capsule, suggesting that air from this lesion can pass into the peritoneal cavity through rupture of Glisson's capsule. Analytically, the development of pneumoperitoneum in our patient may result from (1) air insufflation during ERCP leading to bowel distension, (2) retrograde airflow through the widely patent biliary tract after metallic stent deployment, (3) increased pressure of intrahepatic bile ducts and pneumobilia due to ERCP manipulations and retrograde airflow, (4) rupture of intrahepatic bile ducts of the liver metastatic mass owing to neoplastic tissue friability, (5) development of a necrotic air containing cavity in the liver metastatic mass touching Glisson's capsule, and (6) rupture of Glisson's capsule with subsequent air leakage in the peritoneal cavity.

Although there are data on the conservative or surgical management of duodenal perforations complicating ERCP, no previous experience with such an unusual complication is available. There are only scarce reports on benign pneumoperitoneum successfully managed with conservative treatment after endoscopic biliary procedures^[9]. Regarding the management of ERCP-related duodenal perforations, arguments have been made about

both surgical^[10-12] and non-surgical management^[13]. Stapfer and colleagues^[14] analyzed fourteen cases of ERCP-related perforations and concluded that patients with no peritonitis, sepsis, significant contrast medium leak during ERCP or follow-up upper gastrointestinal study, and retro- or intraperitoneal fluid collections during computed tomography, can be successfully managed conservatively. Based on these criteria, we decided to treat our patient conservatively under frequent clinical re-evaluation for the early recognition of the potential need for surgical treatment. Our patient's rare post-ERCP complication was successfully treated conservatively without need for surgical intervention.

In conclusion, this is the first report of post-ERCP pneumoperitoneum caused by rupture of intrahepatic bile ducts and Glisson's capsule in the area of a large peripheral hepatic metastasis. This case indicates the need for close clinical and radiological observation of patients with hepatic masses (primary or metastatic) subjected to ERCP. In such patients, avoidance of excessive air insufflation during ERCP and/or placement of a nasogastric tube for bowel decompression immediately after ERCP might be a reasonable strategy to prevent such unusual complications.

REFERENCES

- 1 Carr-Locke DL. Therapeutic role of ERCP in the management of suspected common bile duct stones. *Gastrointest Endosc* 2002; **56**: S170-S174
- 2 Koklu S, Parlak E, Yuksel O, Sahin B. Endoscopic retrograde cholangiopancreatography in the elderly: a prospective and comparative study. *Age Ageing* 2005; **34**: 572-577
- 3 Thomopoulos KC, Vagenas K, Assimakopoulos SF, Giannikoulis C, Arvaniti V, Pagoni N, Nikolopoulou VN. Endoscopic retrograde cholangiopancreatography is safe and effective method for diagnosis and treatment of biliary and pancreatic disorders in octogenarians. *Acta Gastroenterol Belg* 2007; **70**: 199-202
- 4 Loperfido S, Angelini G, Benedetti G, Chilovi F, Costan F, De Berardinis F, De Bernardin M, Ederle A, Fina P, Fratton A. Major early complications from diagnostic and therapeutic ERCP: a prospective multicenter study. *Gastrointest Endosc* 1998; **48**: 1-10
- 5 Salminen P, Laine S, Gullichsen R. Severe and fatal complications after ERCP: Analysis of 2555 procedures in a single experienced center. *Surg Endosc* 2008; **22**: 1965-1970
- 6 Baron TH. Complications of endoscopic biliary sphincterotomy: the first cut is the deepest. *Clin Gastroenterol Hepatol* 2004; **2**: 968-970
- 7 Menuck L, Siemers PT. Pneumoperitoneum: importance of right upper quadrant features. *AJR Am J Roentgenol* 1976; **127**: 753-756
- 8 Pannu HK, Fishman EK. Complications of endoscopic retrograde cholangiopancreatography: spectrum of abnormalities demonstrated with CT. *Radiographics* 2001; **21**: 1441-1453
- 9 Hui YT, Lam WM, Lam TW, Cheung WC, Sze SF, Wong CT. Benign pneumoperitoneum developed after endoscopic biliary metallic stent placement with the rendezvous procedure. *Gastrointest Endosc* 2008; **67**: 179-180
- 10 Sarr MG, Fishman EK, Milligan FD, Siegelman SS, Cameron JL. Pancreatitis or duodenal perforation after peri-Vaterian therapeutic endoscopic procedures: diagnosis, differentiation, and management. *Surgery* 1986; **100**: 461-466
- 11 Bell RC, Van Stiegmann G, Goff J, Reveille M, Norton L, Pearlman NW. Decision for surgical management of perforation following endoscopic sphincterotomy. *Am Surg* 1991; **57**: 237-240
- 12 Martin DF, Tweedle DE. Retroperitoneal perforation during ERCP and endoscopic sphincterotomy: causes, clinical features and management. *Endoscopy* 1990; **22**: 174-175
- 13 Scarlett PY, Falk GL. The management of perforation of the duodenum following endoscopic sphincterotomy: a proposal for selective therapy. *Aust N Z J Surg* 1994; **64**: 843-846
- 14 Stapfer M, Selby RR, Stain SC, Katkhouda N, Parekh D, Jabbour N, Garry D. Management of duodenal perforation after endoscopic retrograde cholangiopancreatography and sphincterotomy. *Ann Surg* 2000; **232**: 191-198

S- Editor Li DL L- Editor Wang XL E- Editor Ma WH