



CASE REPORT

Tuberculous lymphadenitis as a cause of obstructive jaundice: A case report and literature review

Radoje Colovic, Nikica Grubor, Rada Jesic, Marjan Micev, Tanja Jovanovic, Natasa Colovic, Henry Dushan Atkinson

Radoje Colovic, Nikica Grubor, Rada Jesic, Marjan Micev, Natasa Colovic, Institute for Digestive Diseases, First Surgical Clinic, Clinical Center of Serbia, Belgrade 11000, Serbia

Tanja Jovanovic, Institute of Microbiology, Belgrade School of Medicine, Belgrade 11000, Serbia

Henry Dushan Atkinson, Imperial College School of Medicine, St Mary's Hospital, Praed Street, London W2 1NY, United Kingdom

Author contributions: Colovic R, Grubor N, Jesic R and Colovic N undertook the surgery and clinical care of the patient; Jovanovic T made PCR analysis; Micev M performed histopathological analysis; Colovic R, Atkinson HD, Grubor N and Colovic N wrote the paper.

Correspondence to: Nikica Grubor, MD, Institute for Digestive Diseases, First Surgical Clinic, Clinical Center of Serbia, Koste Todorovica 6, Belgrade 11000, Serbia. ngrubor@eunet.yu

Telephone: +381-11-3610715 Fax: +381-11-3615569

Received: January 3, 2008 Revised: March 24, 2008

Key words: Obstructive jaundice; Common bile duct stricture; Tuberculous lymphadenitis; Surgical excision; Roux en Y

Peer reviewers: William Dickey, Altnagelvin Hospital, Londonderry, Northern Ireland BT47 6SB, United Kingdom; Serdar Karakose, Department of Radiology, Meram Medical Faculty, Selcuk University, Konya 42080, Turkey; Qin Su, Department of Pathology, Cancer Hospital and Cancer Institute, Chinese Academy of Medical Sciences and Peking Medical College, PO Box 2258, Beijing 100021, China

Colovic R, Grubor N, Jesic R, Micev M, Jovanovic T, Colovic N, Atkinson HD. Tuberculous lymphadenitis as a cause of obstructive jaundice: A case report and literature review. *World J Gastroenterol* 2008; 14(19): 3098-3100 Available from: URL: <http://www.wjgnet.com/1007-9327/14/3098.asp> DOI: <http://dx.doi.org/10.3748/wjg.14.3098>

Abstract

Obstructive jaundice secondary to tuberculosis (TB) is extremely rare. It can be caused by TB enlargement of the head of the pancreas, TB lymphadenitis, TB stricture of the biliary tree, or a TB mass of the retroperitoneum. A 29-year-old man with no previous history of TB presented with abdominal pain, obstructive jaundice, malaise and weight loss. Ultrasonography (US), computer tomography (CT) scan and endoscopic retrograde cholangiopancreatography (ERCP) were suggestive of a stenosis of the distal common bile duct (CBD) caused by a mass in the posterior head of the pancreas. Tumor markers, CEA and CA19-9 were within normal limits. At operation, an enlarged, centrally caseous lymph node of the posterior head of the pancreas was found, causing inflammatory stenosis and a fistula with the distal CBD. The lymph node was removed and the bile duct resected and anastomosed with the Roux-en Y jejunal limb. Histology and PCR based-assay confirmed tuberculous lymphadenitis. After an uneventful postoperative recovery, the patient was treated with anti-tuberculous medication and remained well 2.5 years later. Though obstructive jaundice secondary to tuberculous lymphadenitis is rare, abdominal TB should be considered as a differential diagnosis in immunocompromised patients and in TB endemic areas. Any stenosis or fistulation into the CBD should also be taken into consideration, and biliary bypass surgery be performed to both relieve jaundice and prevent further stricture.

© 2008 WJG. All rights reserved.

INTRODUCTION

Abdominal tuberculosis (ATB) is rare and obstructive jaundice caused by tuberculosis (TB) is extremely rare. ATB can mimic more common noninfectious abdominal syndromes and is often overlooked because of its low incidence. The mechanisms by which ATB causes bile duct obstruction are varied. We describe a patient with biliary obstruction caused by enlarged tuberculous lymph nodes.

CASE REPORT

A 29-year-old man presented to our unit with epigastric pain and tenderness on examination, and jaundice, steatorrhea, malaise and weight loss of 7 kg over the preceding 6 mo. Total bilirubin was 163 $\mu\text{mol/L}$ and direct bilirubin 88 $\mu\text{mol/L}$; SGOT, SGPT, gamma GT and alkaline phosphatase were moderately elevated. Other laboratory tests including the tumor markers CEA and CA19-9 were all within normal limits. HBsAg and HCV were negative. Abdominal ultrasonography (US) revealed a semi-solid hypoechogenic lesion 39 mm \times 40 mm in size around the head of the pancreas, with two enlarged lymph nodes lying above this, and a common bile duct measuring 10 mm in diameter. Computer tomography (CT) scan showed a low density mass on the posterior aspect of the head of the pancreas with a contrast enhancing solid-rim (Figure 1). Pancreatography was normal, however severe narrowing of the distal common bile duct (CBD) was seen on endoscopic retrograde cholangiopancreatography (ERCP) (Figure 2A and B).

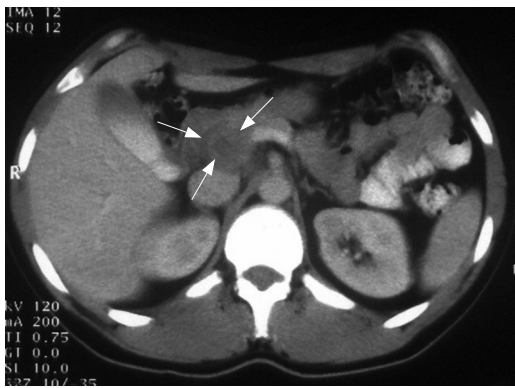


Figure 1 Abdominal CT-scan showing a low density mass on the posterior aspect of the head of the pancreas with contrast enhancing solid rim (arrow).

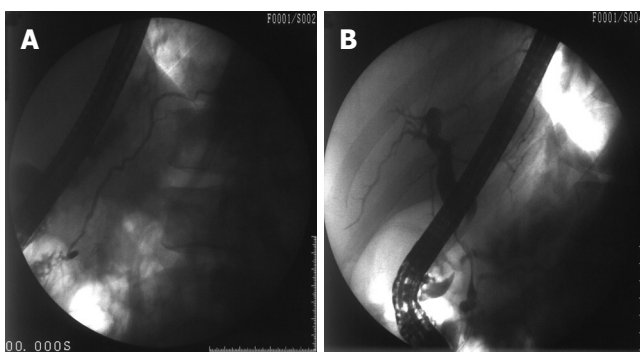


Figure 2 A: ERCP with a normal pancreatogram; B: A smooth long severe narrowing of the distal common bile duct.

The patient underwent open surgery, and at operation the liver was found to be slightly firm, gallbladder moderately dilated, Lund's lymph node enlarged (about 1.5 cm), common bile duct moderately dilated and two lymph nodes close to the common hepatic artery also enlarged (2 cm and 3 cm). After mobilizing the duodenum and the head of the pancreas, an enlarged (4 cm) soft lymph node adherent to the distal CBD, was removed. The lymph node had a solid surface with a soft and caseous centre, and had a fistulous connection with the posterior aspect of the CBD. Frozen section histology of the lymph node revealed chronic granulomatous inflammation. The gallbladder, Lund's lymph node, the two other enlarged lymph nodes lying close to the common hepatic artery, and a specimen of liver was removed and sent for histology. The narrowed distal CBD was resected, the distal end over sewn, and the proximal end anastomosed with a Roux-en-Y jejunal limb. The resected specimen included the fistulous opening on the posterior wall of the CBD (Figure 3).

The patient had an uneventful postoperative recovery, and bilirubin levels normalised within two weeks. Histology of the liver and gallbladder was normal. The resected CBD showed epithelial ulceration and inflammation with a number of necrotizing granulomata. The lymph nodes had a chronic granulomatous appearance with large merged necrotic areas, and smaller epithelioid-type granulomata with occasional multinuclear giant cells (Figure 4A and B) suggestive of tuberculous lymphadenitis. The diagnosis was confirmed with a polymerase chain

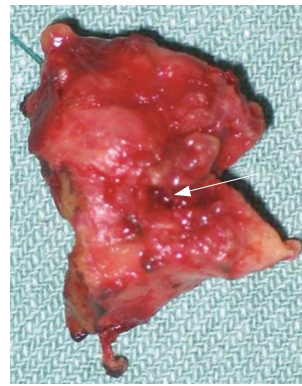


Figure 3 The resected part of the common bile duct with fistula on the posterior wall (arrow).

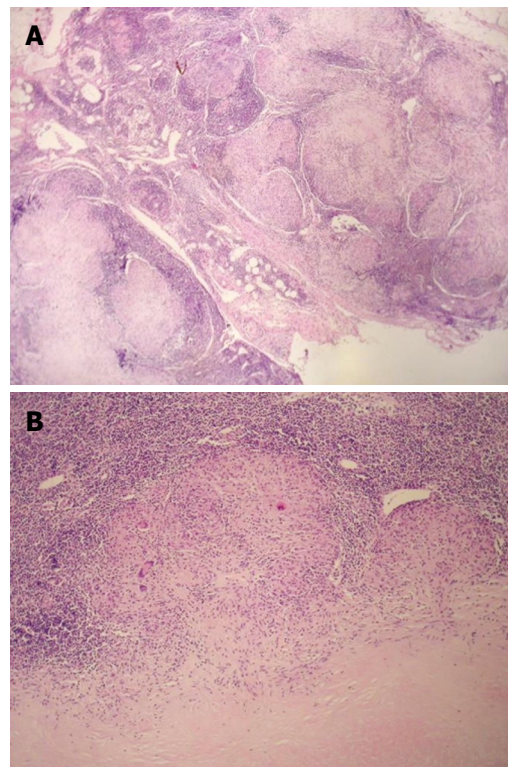


Figure 4 A: Extensive chronic granulomatous lymphadenitis (HE, × 13); B: Focal tuberculoid granuloma formation (HE, × 64).

reaction (PCR) using automated analyzer Cobas/Roche/, with the Amplicor Mycobacterium tuberculosis assay. No previous specific risk for TB was found in the patient. He was treated with anti-tuberculous quadruple therapy and achieved gradual clinical improvement, with resolution of pain and malaise, and a weight gain of 10 kg over the next 6 mo. He remained well at 2.5 years postoperatively.

DISCUSSION

Obstructive jaundice secondary to abdominal TB is extremely rare. Four mechanisms have been described: TB of the pancreas itself may cause pseudoneoplastic obstructive jaundice^[1-10]; it may be secondary to TB lymphadenitis causing compression and inflammation of the lymph nodes and the CBD^[6,11-19], as in our case, with caseation of the lymph node causing fistulation into the CBD; biliary TB itself may lead to single or multiple

strictures, mimicking cholangiocarcinoma^[20-25]; and TB can create a retroperitoneal mass leading to biliary tree obstruction^[26].

The diagnosis of abdominal TB should be considered in the context of a mass in the head of the pancreas in the immunocompromised patients and in countries with endemic TB^[7], after the exclusion of malignancy and other biliary inflammation. TB lymphadenitis can be suspected when a contrast-enhanced CT scan demonstrates low density masses surrounded by an enhancing solid rim^[14], or when ERCP demonstrates a normal pancreatogram with a smooth narrowing of the CBD^[18], as were seen in our patient. FDG-PET scanning has not been shown to be useful in distinguishing TB from pancreatic malignancy, as both conditions have an increased uptake of the FDG metabolite^[18]. US or CT-guided percutaneous fine needle aspiration (FNA) of the enlarged lymph nodes may be useful^[7], but is often not definitive^[21]. Cytology of CBD aspirate, however, obtained by ERCP, may be confirmatory in the presence of the acid-fast bacillus (*Mycobacterium tuberculosis*); alternatively PCR of the aspirate may be diagnostic^[19]. However, in the case of a periportal lymphadenopathy causing obstructive jaundice, as in our patient, these FNA tests are only positive if a fistula exists between the TB lymph node and the CBD, allowing bacilli to pass into the CBD^[19]. Other potential diagnostic methods include obtaining tissue specimens by laparoscopy^[17] or endoscopic ultrasound with FNA^[27]. Though in practice, the diagnosis is often established at operation^[6,7,18,26] or even after surgery by histology^[4] or PCR-based assay^[2,4,6,8,10], as was the case in our patient.

The great benefit of a preoperative diagnosis of TB causing the obstruction is that a more conservative path could be followed, involving removal of the obstructing lymph node alone, followed by anti-TB medications^[18]. In our case more elaborate CBD resective surgery was undertaken for presumed malignancy.

However, even though TB lymphadenitis was suspected in our patient after intraoperative frozen section, resection of the involved part of the CBD was necessary as the bile duct was already strictured, and eventual closure of the fistula would probably result in additional stenosis or even complete obstruction of the CBD. Thus inexplicable stenosis of the CBD should be taken into consideration in the context of pancreatic or TB lymphadenitis associated with obstructive jaundice and be treated by biliary bypass surgery^[7] in addition to anti-TB medication.

REFERENCES

- Crowson MC, Perry M, Burden E. Tuberculosis of the pancreas: a rare cause of obstructive jaundice. *Br J Surg* 1984; **71**: 239
- Chen CH, Yang CC, Yeh YH, Yang JC, Chou DA. Pancreatic tuberculosis with obstructive jaundice--a case report. *Am J Gastroenterol* 1999; **94**: 2534-2536
- Shan YS, Sy ED, Lin PW. Surgical resection of isolated pancreatic tuberculosis presenting as obstructive jaundice. *Pancreas* 2000; **21**: 100-101
- Kouraklis G, Glinavou A, Karayiannakis A, Karatzas G. Primary tuberculosis of the pancreas mimicking a pancreatic tumor. *Int J Pancreatol* 2001; **29**: 151-153
- Singh B, Moodley J, Batitang S, Chetty R. Isolated pancreatic tuberculosis and obstructive jaundice. *S Afr Med J* 2002; **92**: 357-359
- Xia F, Poon RT, Wang SG, Bie P, Huang XQ, Dong JH. Tuberculosis of pancreas and peripancreatic lymph nodes in immunocompetent patients: experience from China. *World J Gastroenterol* 2003; **9**: 1361-1364
- El Mansari O, Tajdine MT, Mikou I, Janati MI. [Pancreatic tuberculosis. Report of two cases] *Gastroenterol Clin Biol* 2003; **27**: 548-550
- Panzuto F, D'Amato A, Laghi A, Cadau G, D'Ambra G, Aguzzi D, Iannaccone R, Montesani C, Caprilli R, Delle Fave G. Abdominal tuberculosis with pancreatic involvement: a case report. *Dig Liver Dis* 2003; **35**: 283-287
- Kumar R, Kapoor D, Singh J, Kumar N. Isolated tuberculosis of the pancreas: a report of two cases and review of the literature. *Trop Gastroenterol* 2003; **24**: 76-78
- Beaulieu S, Chouillard E, Petit-Jean B, Vitte RL, Eugene C. [Pancreatic tuberculosis: a rare cause of pseudoneoplastic obstructive jaundice] *Gastroenterol Clin Biol* 2004; **28**: 295-298
- Kohen MD, Altman KA. Jaundice due to a rare cause: tuberculous lymphadenitis. *Am J Gastroenterol* 1973; **59**: 48-53
- Murphy TF, Gray GF. Biliary tract obstruction due to tuberculous adenitis. *Am J Med* 1980; **68**: 452-454
- Stanley JH, Yantis PL, Marsh WH. Periportal tuberculous adenitis: a rare cause of obstructive jaundice. *Gastrointest Radiol* 1984; **9**: 227-229
- Mathieu D, Ladeb MF, Guigui B, Rousseau M, Vasile N. Periportal tuberculous adenitis: CT features. *Radiology* 1986; **161**: 713-715
- Alvarez SZ, Sollano JD Jr. ERCP in hepatobiliary tuberculosis. *Gastrointest Endosc* 1998; **47**: 100-104
- Queralt CB, Cruz JM, Comet V Jr, Almajano C, Val-Carreres C. [Obstructive jaundice due to peripancreatic tuberculous adenitis] *Rev Esp Enferm Dig* 1992; **82**: 201-202
- Poon RT, Lo CM, Fan ST. Diagnosis and management of biliary obstruction due to periportal tuberculous adenitis. *Hepatogastroenterology* 2001; **48**: 1585-1587
- Obama K, Kanai M, Taki Y, Nakamoto Y, Takabayashi A. Tuberculous lymphadenitis as a cause of obstructive jaundice: report of a case. *Surg Today* 2003; **33**: 229-231
- Probst A, Schmidbaur W, Jechart G, Hammond A, Zentner J, Niculescu E, Messmann H. Obstructive jaundice in AIDS: diagnosis of biliary tuberculosis by ERCP. *Gastrointest Endosc* 2004; **60**: 145-148
- Fan ST, Ng IO, Choi TK, Lai EC. Tuberculosis of the bile duct: a rare cause of biliary stricture. *Am J Gastroenterol* 1989; **84**: 413-414
- Behera A, Kochhar R, Dhavan S, Aggarwal S, Singh K. Isolated common bile duct tuberculosis mimicking malignant obstruction. *Am J Gastroenterol* 1997; **92**: 2122-2123
- Yeh TS, Chen NH, Jan YY, Hwang TL, Jeng LB, Chen MF. Obstructive jaundice caused by biliary tuberculosis: spectrum of the diagnosis and management. *Gastrointest Endosc* 1999; **50**: 105-108
- Kok KY, Yapp SK. Tuberculosis of the bile duct: a rare cause of obstructive jaundice. *J Clin Gastroenterol* 1999; **29**: 161-164
- Inal M, Aksungur E, Akgul E, Demirbas O, Oguz M, Erkocak E. Biliary tuberculosis mimicking cholangiocarcinoma: treatment with metallic biliary endoprosthesis. *Am J Gastroenterol* 2000; **95**: 1069-1071
- Prasad A, Pandey KK. Tuberculous biliary strictures: uncommon cause of obstructive jaundice. *Australas Radiol* 2001; **45**: 365-368
- Jazet IM, Perk L, De Roos A, Bolk JH, Arend SM. Obstructive jaundice and hematemesis: two cases with unusual presentations of intra-abdominal tuberculosis. *Eur J Intern Med* 2004; **15**: 259-261
- Woodfield JC, Windsor JA, Godfrey CC, Orr DA, Officer NM. Diagnosis and management of isolated pancreatic tuberculosis: recent experience and literature review. *ANZ J Surg* 2004; **74**: 368-371