



RAPID COMMUNICATION

Treatment of polycystic liver disease with resection-fenestration and a new classification

Tuan-Jie Li, Hai-Bin Zhang, Jun-Hua Lu, Jun Zhao, Ning Yang, Guang-Shun Yang

Tuan-Jie Li, Hai-Bin Zhang, Jun-Hua Lu, Jun Zhao, Ning Yang, Guang-Shun Yang, Eastern Hepatobiliary Hospital, Second Military Medical University, Shanghai 200438, China
Author contributions: Li TJ and Zhang HB contributed equally to this work; Yang GS and Lu JH designed the study; Zhao J and Yang N performed the study; Li TJ and Zhang HB wrote the paper.

Correspondence to: Dr. Guang-Shun Yang, Eastern Hepatobiliary Hospital, Second Military Medical University, Shanghai 200438, China. gs_yang00@yahoo.com
Telephone: +86-21-25070789 Fax: +86-21-25070789
Received: April 15, 2008 Revised: June 30, 2008
Accepted: July 7, 2008
Published online: August 28, 2008

Key words: Autosomal dominant polycyst liver disease; Autosomal dominant polycyst kidney disease; Fenestration

Peer reviewer: James Neuberger, Professor, Liver Unit, Queen Elizabeth Hospital, Birmingham B15 2TH, United Kingdom

Li TJ, Zhang HB, Lu JH, Zhao J, Yang N, Yang GS. Treatment of polycystic liver disease with resection-fenestration and a new classification. *World J Gastroenterol* 2008; 14(32): 5066-5072 Available from: URL: <http://www.wjgnet.com/1007-9327/14/5066.asp> DOI: <http://dx.doi.org/10.3748/wjg.14.5066>

Abstract

AIM: To evaluate outcomes in patients with autosomal dominant polycyst liver disease (APLD) treated by combined hepatic resection and fenestration. A new classification was recommended to presume postoperative complications and long outcome of patients.

METHODS: Twenty-one patients with APLD were treated by a combined hepatic resection and fenestration technique. All patients were reviewed retrospectively, and clinical symptoms, performance status and morbidity were recorded. A new classification of APLD is recommended here.

RESULTS: All patients were discharged when free of symptoms. The mean follow-up time was 55.7 mo and three patients had a recurrence of symptoms at 81, 68 and 43 mo after operation, respectively. The overall morbidity rate was 76.2%. Two patients with Type B-II and Type B-I developed biliary leakage. Four patients had severe ascites, including three with Type B-III and one with Type B-II. Nine patients had pleural effusion, including one with Type A-I; one with Type B-I; five with Type B-II; one with Type A-III and one with Type B-III. Three patients with Type B had recurrence of symptoms, while none with Type A had severe complications.

CONCLUSION: Combined hepatic resection and fenestration is an acceptable procedure for treatment of APLD. According to our classification, postoperative complications and long outcome can be predicted before surgery.

INTRODUCTION

Autosomal dominant polycyst liver disease (APLD) is a genetic heterogeneous disorder characterized by progressive development of multiple fluid-filled, biliary epithelial liver cysts^[1-5], and is frequently associated with autosomal dominant polycystic kidney disease^[5-7]. Most cases of APLD are asymptomatic and do not require surgical treatment. However, a number of patients with highly symptomatic cystic hepatomegaly or with a complicated presentation would benefit from surgical decompression of the hepatomegaly^[8]. Currently, there is controversy over what is the most appropriate therapeutic approach for APLD. Transient improvement with non-surgical treatment such as sclerosing agents has been reported^[9,10]. Surgical therapies include laparoscopic fenestration^[11-14], open fenestration^[15-18], liver resection and fenestration^[19-22], and liver transplantation^[23-26]. In 1997, Giot *et al*^[1] recommended a stratification scheme for the most appropriate surgical approach. In the present study, we evaluated outcomes in patients with APLD treated by combined hepatic resection and fenestration, and provided a new classification to presume the postoperative complications and long-term outcome of patients with APLD.

MATERIALS AND METHODS

Between May 1995 and May 2007, 21 patients with APLD-associated severe symptoms were referred to Eastern Hepatobiliary Surgery Hospital of the Second Military Medical University in Shanghai. They were

treated by a medical team headed by Dr. Yang *et al.*, using the combined hepatic resection and fenestration technique. The patients included 19 women and two men ranging in age from 34 years to 63 years with a mean of 44.7 (median, 43) years. Of the 21 patients, 12 patients (57.1%) had a familial history of polycyst liver disease (PLD), and 17 patients (81.1%) had associated autosomal dominant polycystic kidney disease. The mean time lap between the diagnosis of APLD and surgery was 65.3 mo (median, 60; range, 1-240 mo). The mean duration of symptoms was 30.6 mo (median, 24; range, 1-168 mo). Specific symptoms included massive abdominal distention (20/21, 95.2%), early satiety (11/21, 52.4%), chronic abdominal pain (9/21, 42.9%), hypertension (8/21, 38.1%), ascites (5/21, 23.8%), supine dyspnea (3/21, 14.3%), elevated temperature related to superinfected cysts (2/21, 9.5%), regurgitation (2/21, 9.5%) and pleural effusion (2/21, 9.5%). Abdominal examination revealed hepatomegaly in all patients. Eleven patients had received treatment previously, including percutaneous cyst aspiration with alcohol sclerotherapy in eight patients, laparotomic fenestration in two patients, and laparoscopic fenestration in one patient. Liver function tests were essentially normal, except for mild elevation of serum alkaline phosphatase in two patients, glutamyltranspeptidase in five patients, hypoalbuminemia and hyperbilirubinemia in four patients. All patients underwent an abdominal computed tomography (CT) scan in order to delineate cyst distribution, assess portal vein patency, and provide baseline measurement for follow-up comparison in each patient. Since some of the patients in our series were not appropriate for Giot classification^[1], a new classification of APLD patients that is different from Giot classification was recommended. This new classification involved a preoperative evaluation of the number of deep cysts in the liver parenchyma that could not be treated during operation. Based on the preoperative evaluation, APLD patients were classified into two types: Type A, with a small number of cysts that could not be treated and left in the deep site of the liver parenchyma (usually ≤ 15), and Type B, with a large number of such cysts (usually ≥ 15). For each type, according to the location of cysts diffused in the liver, they were further classified into three grades: Grade I included patients with diffused cysts occupying less than one lobe of the liver; Grade III was a severe form of APLD with liver parenchyma involving fewer than 3 segments; and Grade II was the grade between Grade I and III, where liver parenchyma was limited in the right lobe or left lobe of the liver, or involving 3-4 segments, but not limited in one lobe of the liver (Figure 1).

Preoperative preparations of each patient included: electrocardiography (ECG), gastroscopy and pulmonary function, major medical contraindications for surgical resection were identified, and specific hepatic factors were evaluated. In 13 patients, prothrombin time (PT) was prolonged (within 3 s above the normal reference). Venous catheterization was also important with these

patients. The abdomen was explored through a bilateral subcoastal incision. The hepatoduodenal ligament was explored to provide access to vascular clamping areas and to identify major vascular and biliary structures. The liver was mobilized by the division of hepatic peritoneal attachments, which was facilitated by sequential fenestration of accessible cysts according to the Lin technique^[15]. Liver segments spared of cystic involvement were identified to define limits of resection. No anatomic segmental or lobar planes were removed even if cysts distorted the normal anatomy. Liver segments spared of cystic involvement were identified prior to parenchymal transaction to define limits of resection. Significant islands of functional liver parenchyma were preserved when possible. Two to five segments were resected during operation. After resection of the major cyst segments, extensive fenestration of the residual cysts in the parenchyma was addressed by excision of the cyst walls. Using cautery, the transection plane was developed further by division and excision of the inter-cystic septa^[27]. Vascular and biliary radicals that coursed through the cyst septa were lighted as indicated. Finally, cyst cavities exposed to the peritoneum were fulgurated by argon beam coagulation (Bard Electromedical Systems, USA) in 15 patients in an attempt to ablate secretory epithelium and reduce postoperative peritoneal fluid losses^[28]. The portal vein, hepatic vein and small bile duct were identified and carefully protected in order to avoid hemorrhage and bile leakage. Cholecystectomy was performed in seven patients. The hepatic resection beds were drained by two large closed suction drains. Eighteen patients were monitored in the intensive care unit. Both colloid and crystalloid fluids were used for volume replacement to compensate for expected postoperative fluid losses and excessive peritoneal drainage. Fluid maintenance and hemodynamic balance were aided by central venous pressure. Postoperative blood gas analysis was examined in all patients. All patients were followed-up through either telephone calls or at clinical visits. Special data included CT scan and current hepatic and renal function test. SPSS 10.0 was used for statistical analysis.

RESULTS

No patient died during the operation. All 21 patients were discharged from the hospital free of the preoperative symptoms. The mean postoperative hospital stay was 15.5 d (median, 13; range, 6-60 d). The mean operation time was 247.6 min (median, 225 min; range, 150-435 min). Component transfusion was given intraoperatively and during hospitalization in 16 patients. The median transfusion of packed red blood cells was 4.5 units (range, 1-20 units). The median transfusion of blood plasma was 1400 mL (range, 200-4600 mL). Fifteen patients had ascites. The mean duration of drainage was 8.29 d (median, 5 d; range, 2-57 d). Needle aspiration was attempted to prevent ascites from infection. Seven patients received continuous needle aspiration to relieve ascites, with a

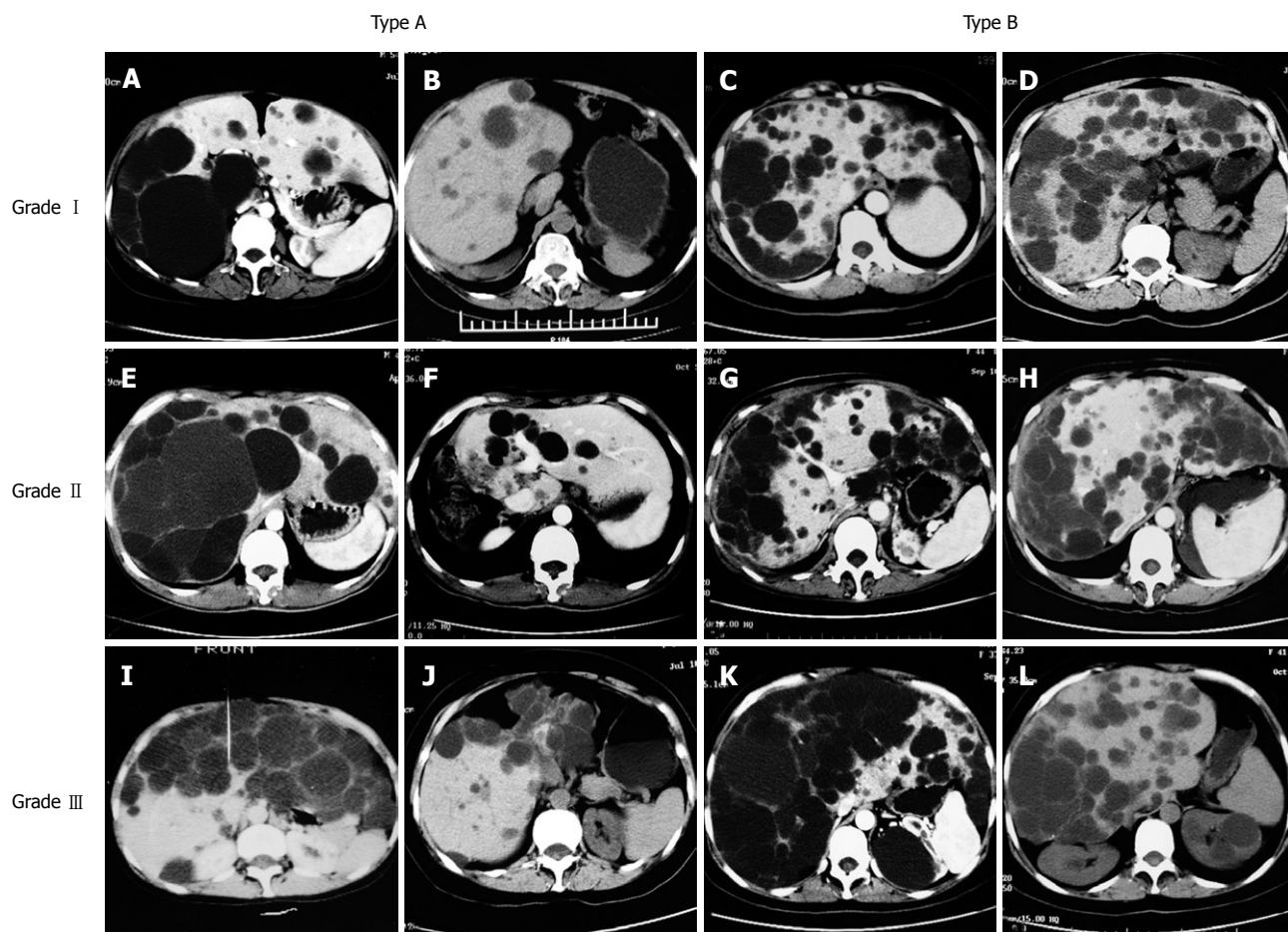


Figure 1 CT examinations of our classification of APLD. **A** and **B**: Type A-I, preoperative and postoperative CT examinations; **C** and **D**: Type B-I, preoperative and postoperative CT examinations; **E** and **F**: Type A-II, preoperative and postoperative CT examinations; **G** and **H**: Type B-II, preoperative and postoperative CT examinations; **I** and **J**: Type A-III, preoperative and postoperative CT examinations; **K** and **L**: Type B-III, preoperative and postoperative CT examinations.

mean duration of 7.54 d (median, 4 d; range, 3-24 d). Eight patients were successfully managed with diuretics and drainage was achieved within one week. Nine patients had pleural effusion, of which 6 patients needed thoracentesis due to chest distress. Bile leakage occurred in two patients. Postoperative hemorrhage occurred in one patient. The overall morbidity rate was 76.2%. There was a morbidity rate of 38.1% for complications that required special treatment. These included severe ascites, bile leakage, hemorrhage, and pleural effusion. The mean follow-up duration was 60.7 mo (median, 59; range, 10-155 mo). Two patients died of renal failure due to polycystic kidney disease at 137 and 85 mo after operation. Three patients had recurrence of the symptoms at 81, 68 and 43 mo after operation with a recurrence rate of (3/21) 14.3%. Total bilirubin was slightly elevated in two patients. The symptoms (occasional abdominal swelling and abdominal pain) of three patients were not severe, therefore they received outpatient treatment.

Follow-up CT data were available in 19 patients, and lost in the remaining two patients who died. Six patients were classified as Type A, including three with Grade I, one with Grade II and two with Grade III. Thirteen patients were classified as Type B APLD, including one with Grade I, eight with Grade II and four with

Grade III. The mean age, mode of presentation, duration of symptoms, mean operation time, intra-operative component transfusion and hospital stay were not significantly different between the two types.

Of the six patients with Type A in our series, three had mild ascites and one had pleural effusion after operation. None of the patients with Type A had severe complications. In patients with Type B in our series, one with Grade II who received laparoscopic treatment 4 years earlier had massive hemorrhage after operation. Biliary complications occurred in two patients, including one with Grade II and one with Grade III. Severe ascites occurred in three patients with Grade III and one patient with Grade II. Eight patients had pleural effusion, including one with Grade I, six with Grade II, and one with Grade III. Eleven patients had mild ascites, including two with Grade I, seven with Grade II, and two with Grade III. Symptoms reoccurred in three patients with Type B, including one with Grade I, and two patients with Grade II. The follow-up ranged from 12 mo to 155 mo with a mean of 61.2 mo for Type A patients, and from 10 mo to 141 mo with a mean of 58.2 mo for Type B patients. There was no significant difference in follow-up duration between the two types. Postoperative complications and symptom recurrence based on our APLD classification are presented in Table 1.

Table 1 Postoperative complications and symptom recurrence based on our APLD classification

Classification		<i>n</i>	Severe ascites	Pleural effusion	Bile leakage	Mild ascites	Hemorrhage	Recurrence
Type A	I	3	-	1	-	1	-	-
	II	1	-	-	-	1	-	-
	III	2	-	-	-	1	-	-
Type B	I	1	-	-	-	1	-	1
	II	8	1	6	1	6	1	2
	III	4	3	1	1	1	-	-
Total		19	4	8	2	11	1	3

Table 2 Review of the literature: mortality, morbidity and outcome of patients with APLD treated by combined hepatic resection and cystic fenestration

Authors ^{ref}	Number of patients	Mortality (%)	Morbidity (%)	Mean follow-up (mo)	Rate of symptom recurrence (%)	Re-operation (%)
Turnage ^[18]	3	2 (67)	2 (67)	9.6	33	0
Vauthey ^[19]	5	0	5 (100)	14	0	0
Henne-Bruns ^[35]	8	0	3 (38)	15	50	0
Que ^[20]	31	1 (3)	18 (58)	28	3	0
Soravia ^[36]	10	1 (10)	2 (20)	68	33	11
Koperna ^[11]	5	0	NR	NR	0	0
Ours	21	0	16 (76)	60.7	14	0

NR: No report.

DISCUSSION

APLD is a rare disorder usually associated with autosomal dominant kidney disease^[7,29]. An increasing prevalence is associated with age and female sex^[30]. Symptoms usually arise from liver enlargement and compression of adjacent organs. Most symptomatic patients complained of an increasing abdominal girth and chronic abdominal dull pain. Liver enlargement may cause early satiety, respiration compromise, and physical disability. Complications such as portal hypertension, pleural effusion, esophageal varices, obstructive jaundice, hepatic failure and malignant degeneration are rare^[31-33]. In patients with APLD, the optimal treatment is still under dispute. Percutaneous aspiration with alcohol sclerotherapy seems valuable for solitary cysts but not for patients with APLD because cyst collapse may not be sufficient^[9,10]. In 1968, Lin *et al*^[15] reported the use of a more extensive cyst fenestration procedure in three patients in whom successively deeper cysts were unroofed and drained through more superficial ones, resulting in a long-term favorable outcome. Kabbej *et al*^[13] reported in a recent study that 13 patients with APLD underwent laparoscopic fenestration, with a symptom recurrence rate of 72% during a mean follow-up of 26 mo. In patients with the majority of cysts in segments VI, VII, VIII, and in patients with deeply seated cysts that are difficult to visualize and fenestrate with laparoscopy, the postoperative recurrence rate is usually high due to inadequate fenestration of all cysts^[12,14,34]. Armitage *et al*^[27] described a patient with APLD who was treated by partial hepatic resection and cyst fenestration in 1984. This procedure allowed for excision of most prominent cysts with minimal resection of the liver tissue, and the liver parenchyma was preserved as much

as possible. Other reports have shown the feasibility of such an approach^[11,18-20,35,36] (Table 2).

We have already reported seven patients with APLD who were treated by hepatic resection and cyst fenestration during a follow-up of 20.4 mo^[22]. All patients were relieved of the symptoms after operation. Mild symptoms recurred in three patients, and symptoms were relieved after treatment in the ambulatory clinic at 6-mo intervals. The long-term benefit of combined hepatic resection and fenestration depends on whether there is a progressive increase in size of deep residual untreated liver cysts rather than new cyst development^[1]. Our experience with the treatment of Type B patients also supports this conclusion. Current data of the natural history of autosomal dominant polycyst kidney disease (APKD) and APLD suggest that progression of cystic disease is slow, affording the possibility of prolonged benefit. Our experience with combined hepatic resection and fenestration shows that some patients with massive polycystic liver benefit markedly from this procedure. No patients with polycystic kidney disease had kidney failure during operation. Two patients in our series died of renal failure during the follow-up period due to polycystic kidney disease. Whether this operation technique affects renal function is still unknown.

According to our classification of APLD patients with Type A seemed less likely to have severe complications after operation. None in Type A had severe ascites or bile leakage in our studies. Patients in every grade with Type A, had more cysts to be resected than cysts to be fenestrated during operation. In addition, their cysts in the liver parenchyma were relatively superficial, and could be treated easily. After fenestration there was little difference in cyst epithelium areas exposed to the abdominal cavity in each grade of patients with Type

A, so their ascites and pleural effusion occurrence rates were seemingly no different after operation. Some Type A patients had small bile leakage or hemorrhage during the operation, but these were found easily during operation. In different grades, operative technical difficulties to repair these leakages and hemorrhages were different. Patients in Grade III had large numbers of cysts to be resected or fenestrated, and vascular and biliary radicals coursing through the cyst septa were more difficult to recognize than those of patients in Grade II or Grade I. Operative risk factors increased with increasing grades. Vascular and biliary radicals should be recognized and protected during operation to avoid injury, especially for patients in Grade III.

In Type B patients, a proportion of cysts needed resection, but most cysts in the liver parenchyma could not be resected in order to preserve liver parenchyma as much as possible. Therefore, Type B patients had more cysts requiring fenestration, and cyst epithelium areas that were exposed to the abdominal cavity were also larger. Since cystic epithelium functions in secretion^[37], severe ascites occur more in Type B. Severe ascites was found in four patients in Type B, including three with Grade III and one with Grade II. Patients with Grade III had more cysts to be fenestrated than patients with Grade II, and patients with Grade II more than patients with Grade I during operation. Patients with Grade III also had larger cyst epithelium areas exposed to the abdominal cavity than Grade II, and patients with Grade II more than patients with Grade I after operation. We presume that patients with Grade III are more likely to develop ascites than patients with Grade II, and patients with Grade II are more likely to develop ascites than patients with Grade I. Bile leakage occurred in two patients in our series with Type B, including one with Grade III and one with Grade II. Patients with Type B had more cysts in the deep liver parenchyma. We attempted to fenestrate the cysts when possible, though it was dangerous to fenestrate deep interseptal cysts without sufficient exposure. Two risk factors may contribute to biliary complications. One is the possible injury to small biliary radicals on the surface of the cyst lining, when the cyst lining was fulgurated by argon beam coagulation to ablate secretory epithelium. The other is that biliary ducts distorted in polycystic liver anatomy are usually difficult to identify, and likely to be injured within cystic septa during a fenestration procedure especially of deep cysts^[1]. These two patients with peritoneal closed suction drainage had spontaneous resolution 27 d and 56 d after operation as identified by subsequent radiologic examination. Therefore we recommend a clearly routine examination on the wound surface to avoid missing the biliary ducts and veins which are possibly injured by the end of the operation.

Our classification of APLD applied the postoperative course which was uncomplicated in six patients with Type A, including three patients with mild ascites and one patient with pleural effusion. No patient in Type A had symptom recurrence in the follow-up period. In Type B, two patients had bile leakage, four had severe ascites,

seven had pleural effusion, and three had symptom recurrence. Type A APLD patients may have good immediate and long-term outcomes, so we recommend a combined hepatic resection and fenestration. Symptom recurrence was related to a progressive increase in size of deep residual untreated liver cysts. Patients in Grade I and in Grade II with Type B had more cysts in deep sites within the liver parenchyma, which could not be treated during operation, therefore those patients had a high rate of symptom recurrence. Cysts in Grade III patients can be resected or fenestrated effectively during operation, leading to less symptom recurrence. So we recommend a new classification to predict the postoperative complications and long-term outcome of patients with APLD. This classification still needs to be validated in the future.

We had two patients who received laparotomic fenestration and one patient received laparoscopic fenestration previously. They had symptom reoccurrence 99, 67 and 53 mo after operation, and received combined liver resection and fenestration. They are living well asymptotically. But in these patients, more intense intra-abdominal adhesions posed technical difficulties^[28]. Their complications were severe after operation, including one that had abdominal hemorrhage, and one that had severe ascites and bile leakage. The patient who underwent laparoscopic fenestration previously had an abdominal hemorrhage in the right lobe, due to tight adhesion of the cyst wall with the diaphragm, where a small artery was not ligated after stripping. Hemorrhage occurred when blood pressure was returned to normal after operation. For these patients, combined fenestration with resection still can be considered as the choice of treatment, but their operation should be performed by experienced surgical teams due to their severe postoperative complications. Liver transplantation as a treatment for APLD may be another good way to treat APLD, but it has a limited role due to the shortage of liver donors and severe postoperative complications. Two large studies reported by Lang *et al*^[24] and Pirenne *et al*^[25] reported the outcomes of liver transplantation in 17 and 16 patients respectively. The former reported 5 deaths (29%) and the latter reported 2 deaths (12.5%). The mortality they reported is higher than that in patients who received combined fenestration procedures. Patients with APLD who receive liver transplantation are placed on immune suppression therapy, and therefore do not have a "normal immune system." Immune suppressants have many side effects on patients with liver transplantation, and after operation they still need much attention to sustain the state of immune suppression to avoid graft rejection. Starzl and his colleagues described the "syndrome of lethal exhaustion" as the major indication to consider when offering transplantation to these patients^[38]. We fully agree that liver transplantation should be used for patients with cachexia, weight loss, portal hypertension, refractory ascites, liver insufficiency or associated with severe kidney disease^[24,25,39,40]. Liver resection and fenestration of the remnant liver are more effective than

fenestration and less invasive than liver transplantation, combined liver resection and fenestration should be considered as the choice for treatment for APLD.

COMMENTS

Background

Autosomal dominant polycyst liver disease (APLD) is a rare disorder usually associated with autosomal dominant kidney disease with an increasing prevalence associated with age and female sex. Symptoms usually arise from liver enlargement and compression of adjacent organs. Surgical therapies include laparoscopic fenestration, open fenestration, liver resection and fenestration, and liver transplantation, what is the optimal treatment is still under dispute.

Research frontiers

The study analyzed and summarized the author's clinical experiences in recent 12 years in the treatment of APLD and in an attempt to propose some practicable guidelines, and suggested a new classification to presume postoperative complications and long outcome of each patient.

Innovations and breakthroughs

Combined hepatic resection-fenestration is a good choice for the treatment of highly symptomatic adult polycystic liver disease. According to the author's classification, postoperative complications and long outcome of each patient can be predicted before surgery.

Applications

The study provides some practicable guidelines for the treatment of APLD, and according to the author's classification, postoperative complications and long outcome of each patient can be predicted before surgery.

Peer review

The paper analyzed and summarized some practicable experience for the treatment of APLD and recommended a new classification. It is valuable to see the actual results from various therapies and the new classification by the authors over the last 12 years.

REFERENCES

- Gigot JF, Jadoul P, Que F, Van Beers BE, Etienne J, Horsmans Y, Collard A, Geubel A, Pringot J, Kestens PJ. Adult polycystic liver disease: is fenestration the most adequate operation for long-term management? *Ann Surg* 1997; **225**: 286-294
- Grimm PC, Crocker JF, Malatjalian DA, Ogborn MR. The microanatomy of the intrahepatic bile duct in polycystic disease: comparison of the cpk mouse and human. *J Exp Pathol* (Oxford) 1990; **71**: 119-131
- Ramos A, Torres VE, Holley KE, Offord KP, Rakela J, Ludwig J. The liver in autosomal dominant polycystic kidney disease. Implications for pathogenesis. *Arch Pathol Lab Med* 1990; **114**: 180-184
- Perrone RD, Grubman SA, Rogers LC, Lee DW, Moy E, Murray SL, Torres VE, Jefferson DM. Continuous epithelial cell lines from ADPKD liver cysts exhibit characteristics of intrahepatic biliary epithelium. *Am J Physiol* 1995; **269**: G335-G345
- Milutinovic J, Fialkow PJ, Rudd TG, Agodoa LY, Phillips LA, Bryant JI. Liver cysts in patients with autosomal dominant polycystic kidney disease. *Am J Med* 1980; **68**: 741-744
- Levine E, Cook LT, Grantham JJ. Liver cysts in autosomal-dominant polycystic kidney disease: clinical and computed tomographic study. *AJR Am J Roentgenol* 1985; **145**: 229-233
- D'Agata ID, Jonas MM, Perez-Atayde AR, Guay-Woodford LM. Combined cystic disease of the liver and kidney. *Semin Liver Dis* 1994; **14**: 215-228
- Comfort MW, Gray HK, Dahlin DC, Whitesell FB Jr. Polycystic disease of the liver: a study of 24 cases. *Gastroenterology* 1952; **20**: 60-78
- Kairaluoma MI, Leinonen A, Stahlberg M, Paivansalo M, Kiviniemi H, Siniluoto T. Percutaneous aspiration and alcohol sclerotherapy for symptomatic hepatic cysts. An alternative to surgical intervention. *Ann Surg* 1989; **210**: 208-215
- Tikkakoski T, Makela JT, Leinonen S, Paivansalo M, Merikanto J, Karttunen A, Siniluoto T, Kairaluoma MI. Treatment of symptomatic congenital hepatic cysts with single-session percutaneous drainage and ethanol sclerosis: technique and outcome. *J Vasc Interv Radiol* 1996; **7**: 235-239
- Koperna T, Vogl S, Satzinger U, Schulz F. Nonparasitic cysts of the liver: results and options of surgical treatment. *World J Surg* 1997; **21**: 850-854; discussion 854-855
- Morino M, De Giuli M, Festa V, Garrone C. Laparoscopic management of symptomatic nonparasitic cysts of the liver. Indications and results. *Ann Surg* 1994; **219**: 157-164
- Kabbej M, Sauvanet A, Chauveau D, Farges O, Belghiti J. Laparoscopic fenestration in polycystic liver disease. *Br J Surg* 1996; **83**: 1697-1701
- Martin IJ, McKinley AJ, Currie EJ, Holmes P, Garden OJ. Tailoring the management of nonparasitic liver cysts. *Ann Surg* 1998; **228**: 167-172
- Lin TY, Chen CC, Wang SM. Treatment of non-parasitic cystic disease of the liver: a new approach to therapy with polycystic liver. *Ann Surg* 1968; **168**: 921-927
- van Erpecum KJ, Janssens AR, Terpstra JL, Tjon A, Tham RT. Highly symptomatic adult polycystic disease of the liver. A report of fifteen cases. *J Hepatol* 1987; **5**: 109-117
- Sanchez H, Gagner M, Rossi RL, Jenkins RL, Lewis WD, Munson JL, Braasch JW. Surgical management of nonparasitic cystic liver disease. *Am J Surg* 1991; **161**: 113-118; discussion 118-119
- Turnage RH, Eckhauser FE, Knol JA, Thompson NW. Therapeutic dilemmas in patients with symptomatic polycystic liver disease. *Am Surg* 1988; **54**: 365-372
- Vauthey JN, Maddern GJ, Blumgart LH. Adult polycystic disease of the liver. *Br J Surg* 1991; **78**: 524-527
- Que F, Nagorney DM, Gross JB Jr, Torres VE. Liver resection and cyst fenestration in the treatment of severe polycystic liver disease. *Gastroenterology* 1995; **108**: 487-494
- Vons C, Chauveau D, Martinod E, Smadja C, Capron F, Grunfeld JP, Franco D. [Liver resection in patients with polycystic liver disease] *Gastroenterol Clin Biol* 1998; **22**: 50-54
- Yang GS, Li QG, Lu JH, Yang N, Zhang HB, Zhou XP. Combined hepatic resection with fenestration for highly symptomatic polycystic liver disease: A report on seven patients. *World J Gastroenterol* 2004; **10**: 2598-2601
- Kirchner GI, Rifai K, Cantz T, Nashan B, Terkamp C, Becker T, Strassburg C, Barg-Hock H, Wagner S, Luck R, Klempnauer J, Manns MP. Outcome and quality of life in patients with polycystic liver disease after liver or combined liver-kidney transplantation. *Liver Transpl* 2006; **12**: 1268-1277
- Lang H, von Woellwarth J, Oldhafer KJ, Behrend M, Schlitt HJ, Nashan B, Pichlmayr R. Liver transplantation in patients with polycystic liver disease. *Transplant Proc* 1997; **29**: 2832-2833
- Pirenne J, Aerts R, Yoong K, Gunson B, Koshiba T, Fournau I, Mayer D, Buckels J, Mirza D, Roskams T, Elias E, Nevens F, Fevery J, McMaster P. Liver transplantation for polycystic liver disease. *Liver Transpl* 2001; **7**: 238-245
- Demirci G, Becker T, Nyibata M, Lueck R, Bektas H, Lehner F, Tusch G, Strassburg C, Schwarz A, Klempnauer J, Nashan B. Results of combined and sequential liver-kidney transplantation. *Liver Transpl* 2003; **9**: 1067-1078
- Armitage NC, Blumgart LH. Partial resection and fenestration in the treatment of polycystic liver disease. *Br J Surg* 1984; **71**: 242-244
- Newman KD, Torres VE, Rakela J, Nagorney DM. Treatment of highly symptomatic polycystic liver disease. Preliminary experience with a combined hepatic resection-fenestration procedure. *Ann Surg* 1990; **212**: 30-37

- 29 **Feldman M**. Polycystic disease of the liver. *Am J Gastroenterol* 1958; **29**: 83-86
- 30 **Gabow PA**, Johnson AM, Kaehny WD, Manco-Johnson ML, Duley IT, Everson GT. Risk factors for the development of hepatic cysts in autosomal dominant polycystic kidney disease. *Hepatology* 1990; **11**: 1033-1037
- 31 **Ratcliffe PJ**, Reeders S, Theaker JM. Bleeding oesophageal varices and hepatic dysfunction in adult polycystic kidney disease. *Br Med J (Clin Res Ed)* 1984; **288**: 1330-1331
- 32 **Wittig JH**, Burns R, Longmire WP Jr. Jaundice associated with polycystic liver disease. *Am J Surg* 1978; **136**: 383-386
- 33 **Washburn WK**, Johnson LB, Lewis WD, Jenkins RL. Liver transplantation for adult polycystic liver disease. *Liver Transpl Surg* 1996; **2**: 17-22
- 34 **Marks J**, Mouiel J, Katkhouda N, Gugenheim J, Fabiani P. Laparoscopic liver surgery. A report on 28 patients. *Surg Endosc* 1998; **12**: 331-334
- 35 **Henne-Bruns D**, Klomp HJ, Kremer B. Non-parasitic liver cysts and polycystic liver disease: results of surgical treatment. *Hepatogastroenterology* 1993; **40**: 1-5
- 36 **Soravia C**, Mentha G, Giostra E, Morel P, Rohner A. Surgery for adult polycystic liver disease. *Surgery* 1995; **117**: 272-275
- 37 **Everson GT**, Emmett M, Brown WR, Redmond P, Thickman D. Functional similarities of hepatic cystic and biliary epithelium: studies of fluid constituents and in vivo secretion in response to secretin. *Hepatology* 1990; **11**: 557-565
- 38 **Starzl TE**, Reyes J, Tzakis A, Miele L, Todo S, Gordon R. Liver transplantation for polycystic liver disease. *Arch Surg* 1990; **125**: 575-577
- 39 **Swenson K**, Seu P, Kinkhabwala M, Maggard M, Martin P, Goss J, Busuttil R. Liver transplantation for adult polycystic liver disease. *Hepatology* 1998; **28**: 412-415
- 40 **Russell RT**, Pinson CW. Surgical management of polycystic liver disease. *World J Gastroenterol* 2007; **13**: 5052-5059

S- Editor Zhong XY L- Editor Alpini GD E- Editor Yin DH